2a Kinesiology:
Names and Locations of Bones and Posterior Muscles

2a Kinesiology:

Names and Locations of Bones and Posterior Muscles Class Outline

	Reminders (10 minutes before class display the reminders slide)
5 minutes	Attendance and Breath of Arrival
15 minutes	AOIs: Trapezius
25 minutes	Lecture: Axial versus Appendicular (Packet E-17)
15 minutes	Muscles of the Posterior Upper and Lower Body
60 minutes	Total Class Time

2a Kinesiology:

Names and Locations of Bones and Posterior Muscles Reminders

Assignments:

- 3a Student Handbook Review Questions (A: 115-118)
- 4a Autobiography and Photo (B-4)
- 7a Review Questions (A: 119-130)

Quizzes:

- 5b Kinesiology Quiz (A: 73, and 75-80)
  - 25 multiple-choice questions in 20 minutes
  - Study terms on packet page A-51
  - AOIs for deltoid, traps, lats, teres major, rhomboids, triceps, and erectors

Preparation for upcoming classes:

- 3a Self-Care: Health, Wellness, Nutrition, and Stress Reduction
  - Trail Guide: latissimus dorsi and teres major
  - Salvo: Chapter 4
  - Packet H: 1-6
  - Packet A: 122-123

- 3b Body Mechanics, Client Positioning, and Draping
  - Salvo: Chapter 7, Packet F: 17-24, and Packet A: 124-125
  - Wear close-fitting clothing to allow for better draping practice
  - Bring a twin sheet set including 2 pillow cases and a blanket

Classroom Rules

Punctuality - everybody's time is precious

- Be ready to learn at the start of class; we'll have you out of here on time
- Tardiness: arriving late, returning late after breaks, leaving during class, leaving early

The following are not allowed:

- Bare feet
- Side talking
- Lying down
- Inappropriate clothing
- Food or drink except water
- Phones that are visible in the classroom, bathrooms, or internship

You will receive one verbal warning, then you'll have to leave the room.

Classroom Rules

Cell Phones – Turn it off!

And put it away!

Trapezius

Trail Guide, Page 68

Posterior View

Trapezius is a superficial muscle of the upper back and neck.

It comes from a Greek word meaning “little table” or “trapezoid shape”.

When do you use trapezius?

Trapezius

Trail Guide, Page 68

Posterior View

Trapezius is used to:

- Extend your neck over the handlebars of a bicycle
- Hold a phone between your ear and shoulder
- Carry articles strapped over your shoulder
- Pull your shoulders back in a military fashion

What actions are performed by the upper fibers of trapezius?

Actions of trapezius upper fibers

Extension of the head and neck



Lateral flexion of the head and neck

Rotation of the head and neck to the **opposite** side

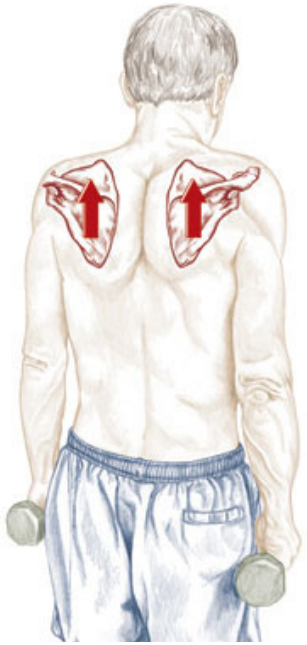

Elevation of the scapula

Upward rotation of the scapula

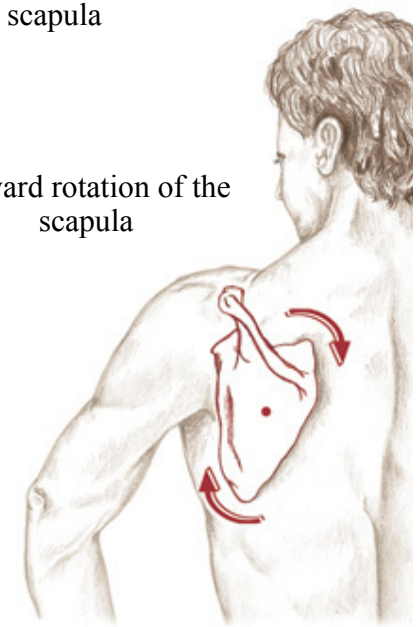

Actions of trapezius middle fibers

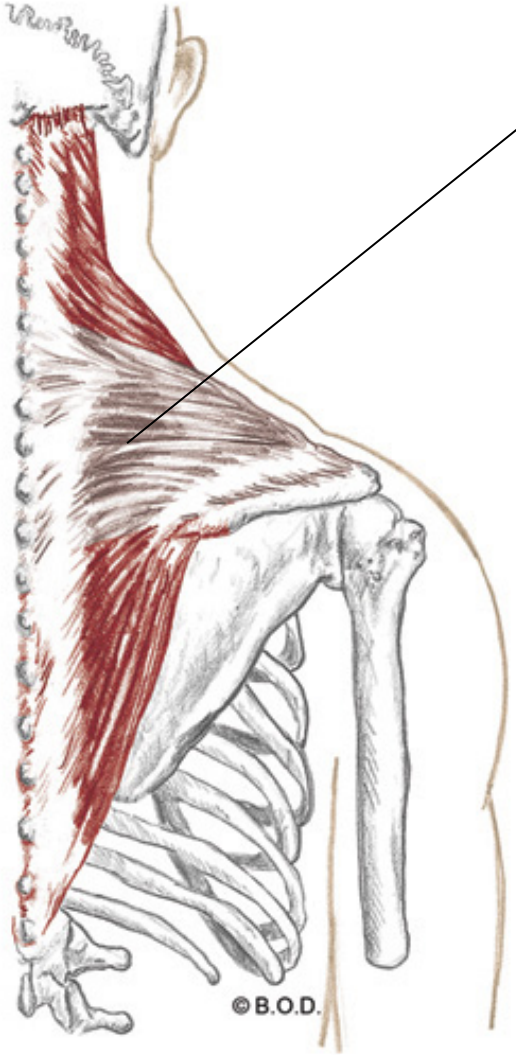

Adduction of the scapula.

Also called retraction of the scapula!

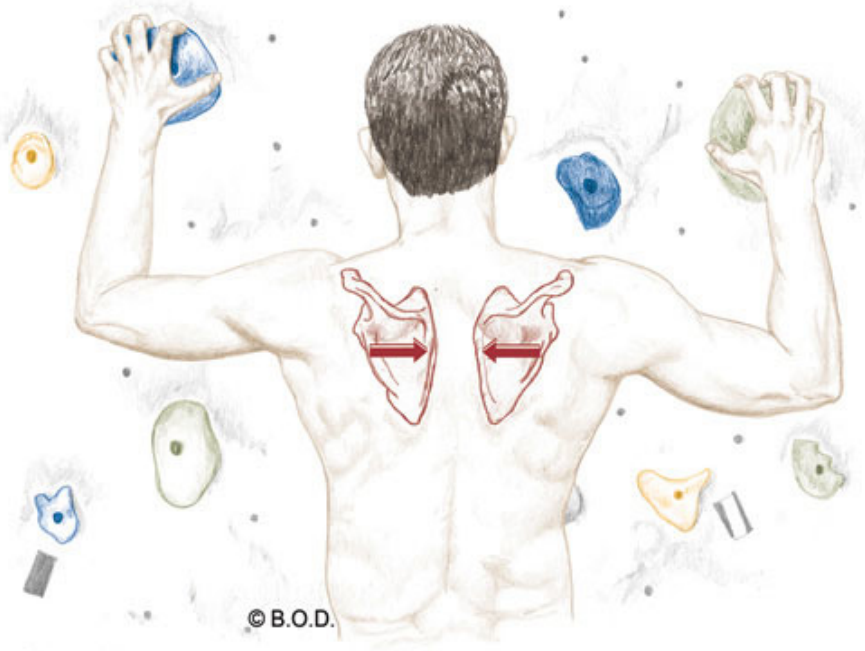

Middle fibers of trapezius are also responsible for stabilizing the scapula so that it remains in a fixed position.

Actions of trapezius lower fibers

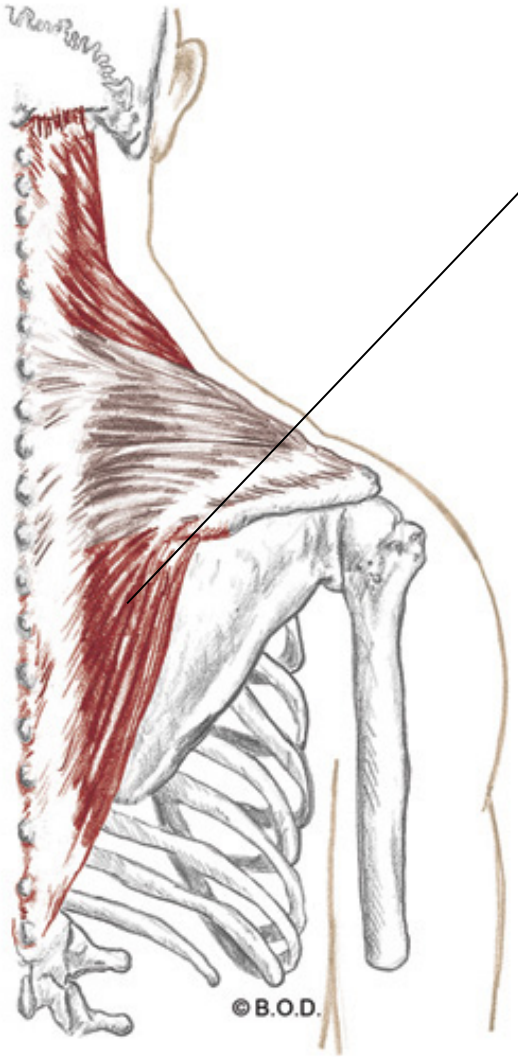

Depression of the scapula

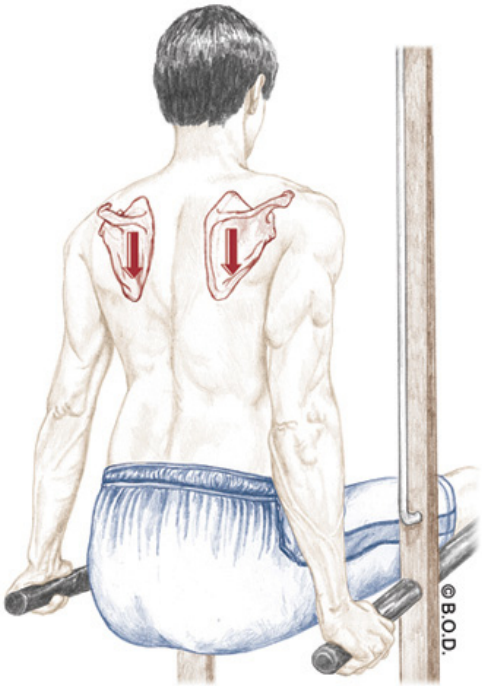

Upward rotation of the scapula

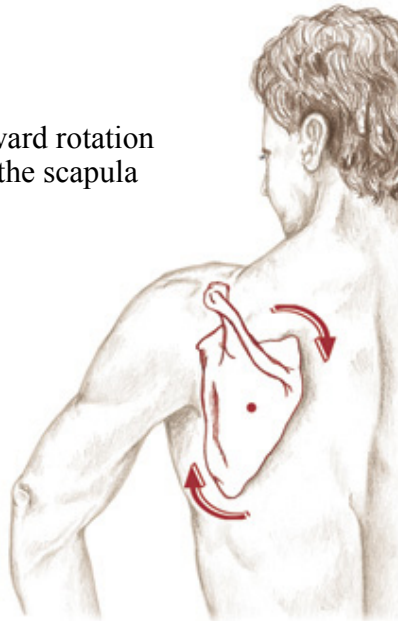

Trapezius

A *Upper fibers:*

Bilaterally

Extend the head and neck

Unilaterally

Laterally flex the head and neck to the same side

Rotate the head and neck to the opposite side

Elevate the scapula (scapulothoracic joint)

Upwardly rotate the scapula (S/T joint)

Middle fibers:

Adduct the scapula (S/T joint)

Stabilize the scapula (S/T joint)

Lower fibers:

Depress the scapula (S/T joint)

Upwardly rotate the scapula (S/T joint)

O External occipital protuberance

Medial portion of superior nuchal line

Ligamentum nuchae

Spinous processes of C-7 through T-12

I Lateral one-third of clavicle

Acromion

Spine of scapula

Trapezius

A *Upper fibers:*

Bilaterally

Extend the head and neck

Unilaterally

Laterally flex the head and neck to the same side

Rotate the head and neck to the opposite side

Elevate the scapula (scapulothoracic joint)

Upwardly rotate the scapula (S/T joint)

Middle fibers:

Adduct the scapula (S/T joint)

Stabilize the scapula (S/T joint)

Lower fibers:

Depress the scapula (S/T joint)

Upwardly rotate the scapula (S/T joint)

O External occipital protuberance

Medial portion of superior nuchal line

Ligamentum nuchae

Spinous processes of C-7 through T-12

I Lateral one-third of clavicle

Acromion

Spine of scapula

Trapezius

A *Upper fibers:*

Bilaterally

Extend the head and neck

Unilaterally

Laterally flex the head and neck to the same side

Rotate the head and neck to the opposite side

Elevate the scapula (scapulothoracic joint)

Upwardly rotate the scapula (S/T joint)

Middle fibers:

Adduct the scapula (S/T joint)

Stabilize the scapula (S/T joint)

Lower fibers:

Depress the scapula (S/T joint)

Upwardly rotate the scapula (S/T joint)

O External occipital protuberance

Medial portion of superior nuchal line

Ligamentum nuchae

Spinous processes of C-7 through T-12

I Lateral one-third of clavicle

Acromion

Spine of scapula

Trapezius

A *Upper fibers:*

Bilaterally

Extend the head and neck

Unilaterally

Laterally flex the head and neck to the same side

Rotate the head and neck to the opposite side

Elevate the scapula (scapulothoracic joint)

Upwardly rotate the scapula (S/T joint)

Middle fibers:

Adduct the scapula (S/T joint)

Stabilize the scapula (S/T joint)

Lower fibers:

Depress the scapula (S/T joint)

Upwardly rotate the scapula (S/T joint)

O External occipital protuberance

Medial portion of superior nuchal line

Ligamentum nuchae

Spinous processes of C-7 through T-12

I Lateral one-third of clavicle

Acromion

Spine of scapula

Trapezius

A *Upper fibers:*

Bilaterally

Extend the head and neck

Unilaterally

Laterally flex the head and neck to the same side

Rotate the head and neck to the opposite side

Elevate the scapula (scapulothoracic joint)

Upwardly rotate the scapula (S/T joint)

Middle fibers:

Adduct the scapula (S/T joint)

Stabilize the scapula (S/T joint)

Lower fibers:

Depress the scapula (S/T joint)

Upwardly rotate the scapula (S/T joint)

O External occipital protuberance

Medial portion of superior nuchal line

Ligamentum nuchae

Spinous processes of C-7 through T-12

I Lateral one-third of clavicle

Acromion

Spine of scapula

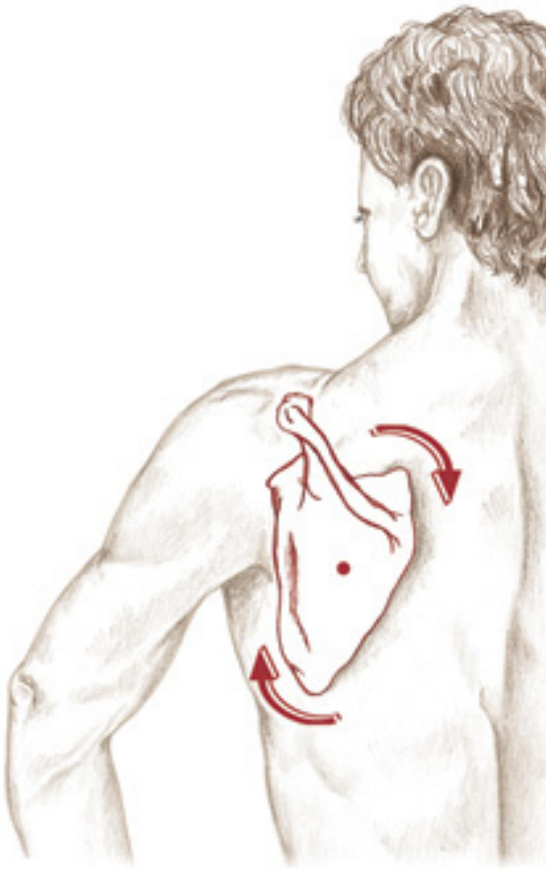

Trapezius

A *Upper fibers:*

Bilaterally

Extend the head and neck

Unilaterally

Laterally flex the head and neck to the same side

Rotate the head and neck to the opposite side

Elevate the scapula (scapulothoracic joint)

Upwardly rotate the scapula (S/T joint)

Middle fibers:

Adduct the scapula (S/T joint)

Stabilize the scapula (S/T joint)

Lower fibers:

Depress the scapula (S/T joint)

Upwardly rotate the scapula (S/T joint)

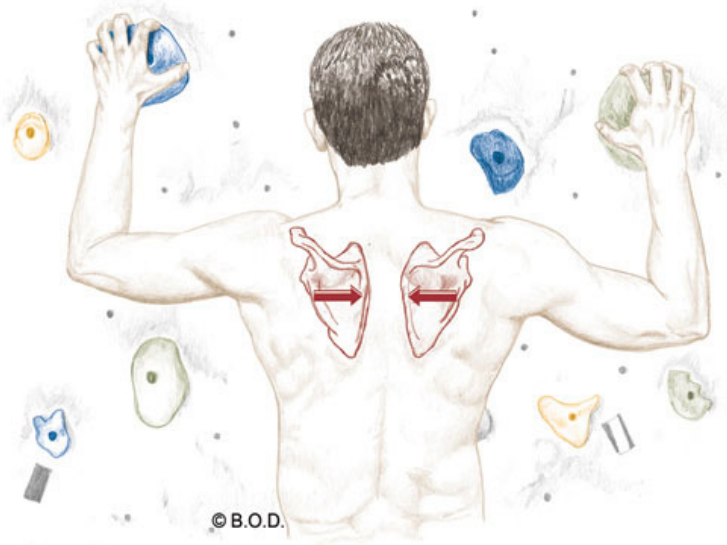

O External occipital protuberance

Medial portion of superior nuchal line

Ligamentum nuchae

Spinous processes of C-7 through T-12

I Lateral one-third of clavicle

Acromion

Spine of scapula

Trapezius

A *Upper fibers:*

Bilaterally

Extend the head and neck

Unilaterally

Laterally flex the head and neck to the same side

Rotate the head and neck to the opposite side

Elevate the scapula (scapulothoracic joint)

Upwardly rotate the scapula (S/T joint)

Middle fibers:

Adduct the scapula (S/T joint)

Stabilize the scapula (S/T joint)

Lower fibers:

Depress the scapula (S/T joint)

Upwardly rotate the scapula (S/T joint)

O External occipital protuberance

Medial portion of superior nuchal line

Ligamentum nuchae

Spinous processes of C-7 through T-12

I Lateral one-third of clavicle

Acromion

Spine of scapula

Trapezius

A *Upper fibers:*

Bilaterally

Extend the head and neck

Unilaterally

Laterally flex the head and neck to the same side

Rotate the head and neck to the opposite side

Elevate the scapula (scapulothoracic joint)

Upwardly rotate the scapula (S/T joint)

Middle fibers:

Adduct the scapula (S/T joint)

Stabilize the scapula (S/T joint)

Lower fibers:

Depress the scapula (S/T joint)

Upwardly rotate the scapula (S/T joint)

O External occipital protuberance

Medial portion of superior nuchal line

Ligamentum nuchae

Spinous processes of C-7 through T-12

I Lateral one-third of clavicle

Acromion

Spine of scapula

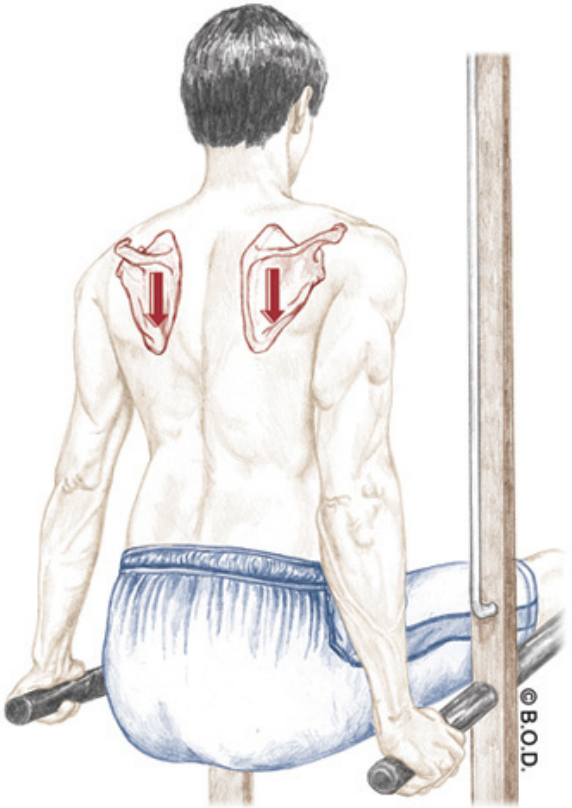

Trapezius

A *Upper fibers:*

Bilaterally

Extend the head and neck

Unilaterally

Laterally flex the head and neck to the same side

Rotate the head and neck to the opposite side

Elevate the scapula (scapulothoracic joint)

Upwardly rotate the scapula (S/T joint)

Middle fibers:

Adduct the scapula (S/T joint)

Stabilize the scapula (S/T joint)

Lower fibers:

Depress the scapula (S/T joint)

Upwardly rotate the scapula (S/T joint)

O External occipital protuberance

Medial portion of superior nuchal line

Ligamentum nuchae

Spinous processes of C-7 through T-12

I Lateral one-third of clavicle

Acromion

Spine of scapula

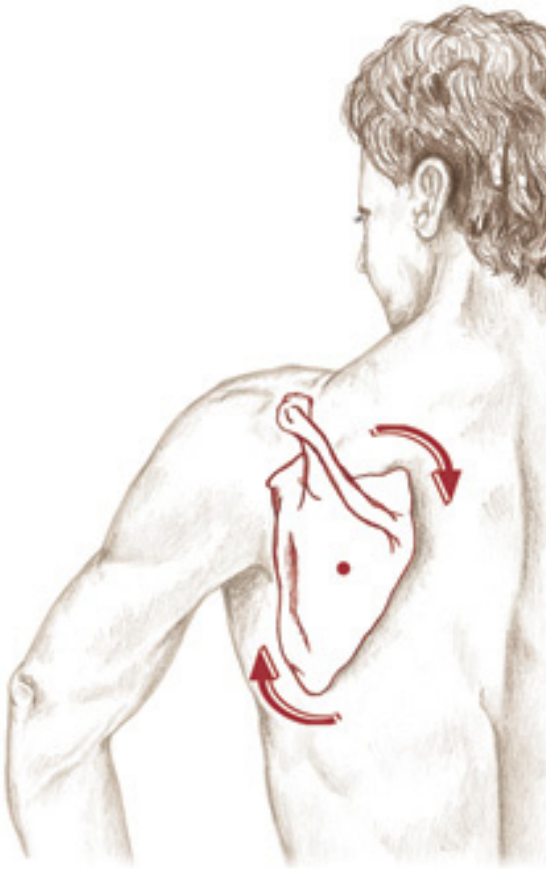

Trapezius

A *Upper fibers:*

Bilaterally

Extend the head and neck

Unilaterally

Laterally flex the head and neck to the same side

Rotate the head and neck to the opposite side

Elevate the scapula (scapulothoracic joint)

Upwardly rotate the scapula (S/T joint)

Middle fibers:

Adduct the scapula (S/T joint)

Stabilize the scapula (S/T joint)

Lower fibers:

Depress the scapula (S/T joint)

Upwardly rotate the scapula (S/T joint)

O External occipital protuberance

Medial portion of superior nuchal line

Ligamentum nuchae

Spinous processes of C-7 through T-12

I Lateral one-third of clavicle

Acromion

Spine of scapula

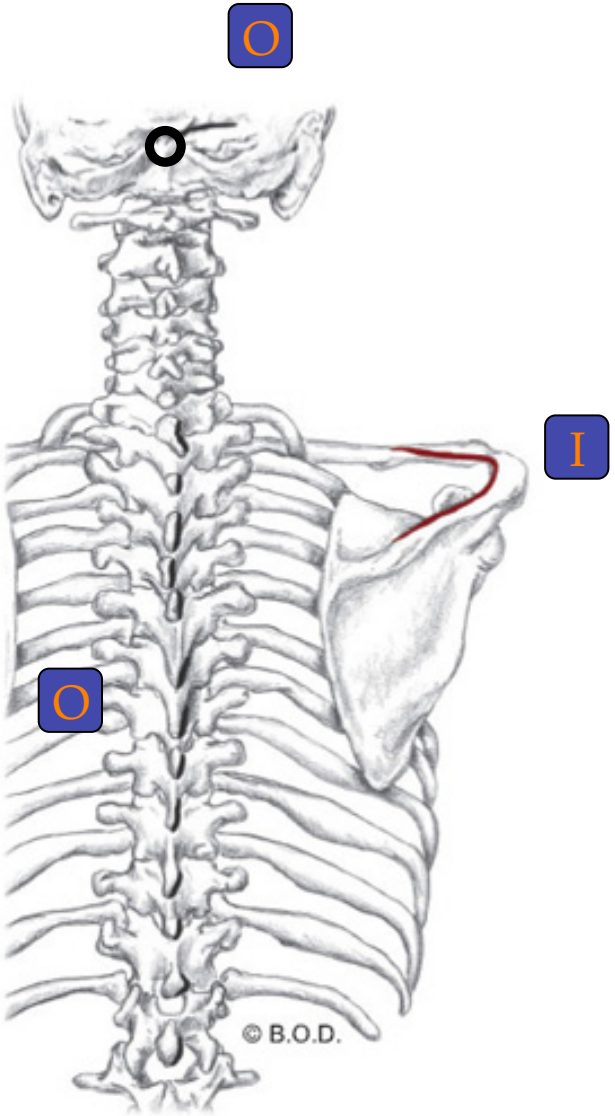

Trapezius

A *Upper fibers:*

Bilaterally

Extend the head and neck

Unilaterally

Laterally flex the head and neck to the same side

Rotate the head and neck to the opposite side

Elevate the scapula (scapulothoracic joint)

Upwardly rotate the scapula (S/T joint)

Middle fibers:

Adduct the scapula (S/T joint)

Stabilize the scapula (S/T joint)

Lower fibers:

Depress the scapula (S/T joint)

Upwardly rotate the scapula (S/T joint)

O External occipital protuberance

Medial portion of superior nuchal line

Ligamentum nuchae

Spinous processes of C-7 through T-12

I Lateral one-third of clavicle

Acromion

Spine of scapula

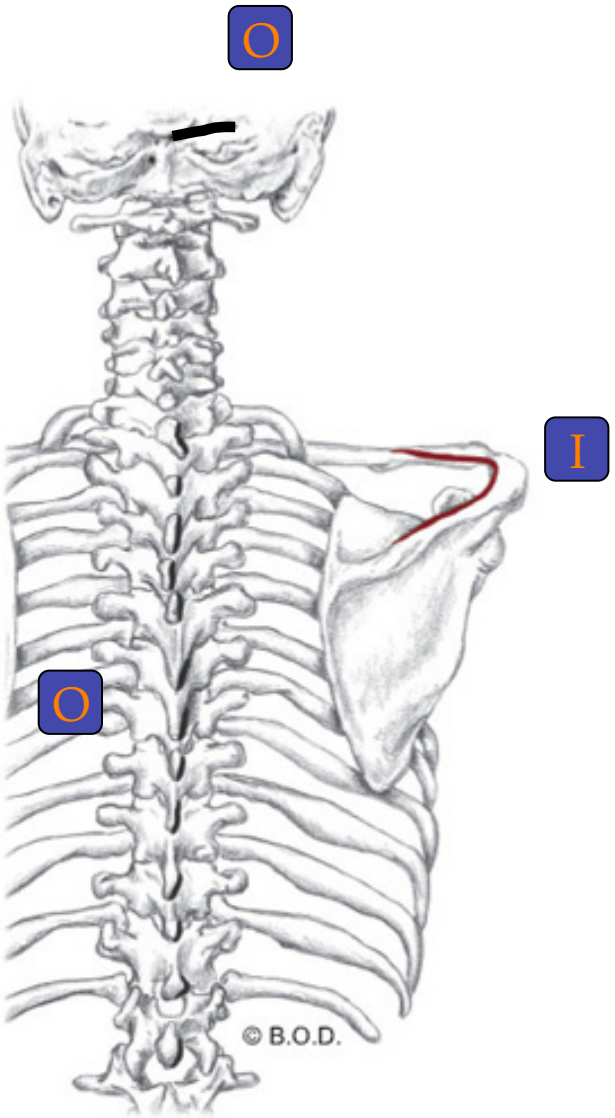

Trapezius

A *Upper fibers:*

Bilaterally

Extend the head and neck

Unilaterally

Laterally flex the head and neck to the same side

Rotate the head and neck to the opposite side

Elevate the scapula (scapulothoracic joint)

Upwardly rotate the scapula (S/T joint)

Middle fibers:

Adduct the scapula (S/T joint)

Stabilize the scapula (S/T joint)

Lower fibers:

Depress the scapula (S/T joint)

Upwardly rotate the scapula (S/T joint)

O External occipital protuberance

Medial portion of superior nuchal line

Ligamentum nuchae

Spinous processes of C-7 through T-12

I Lateral one-third of clavicle

Acromion

Spine of scapula

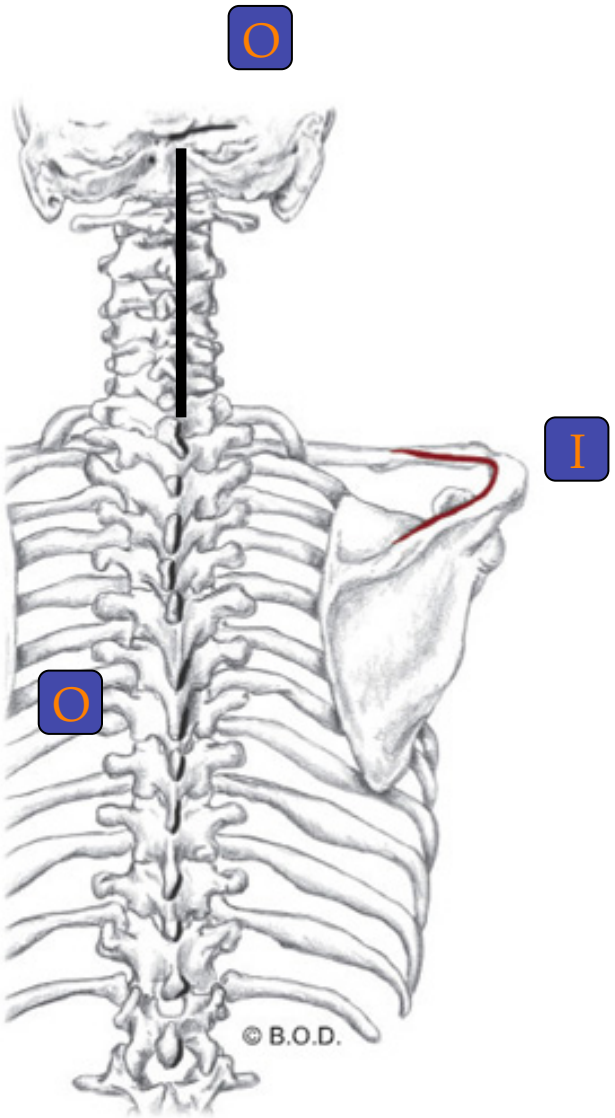

Trapezius

A *Upper fibers:*

Bilaterally

Extend the head and neck

Unilaterally

Laterally flex the head and neck to the same side

Rotate the head and neck to the opposite side

Elevate the scapula (scapulothoracic joint)

Upwardly rotate the scapula (S/T joint)

Middle fibers:

Adduct the scapula (S/T joint)

Stabilize the scapula (S/T joint)

Lower fibers:

Depress the scapula (S/T joint)

Upwardly rotate the scapula (S/T joint)

O External occipital protuberance

Medial portion of superior nuchal line

Ligamentum nuchae

Spinous processes of C-7 through T-12

I Lateral one-third of clavicle

Acromion

Spine of scapula

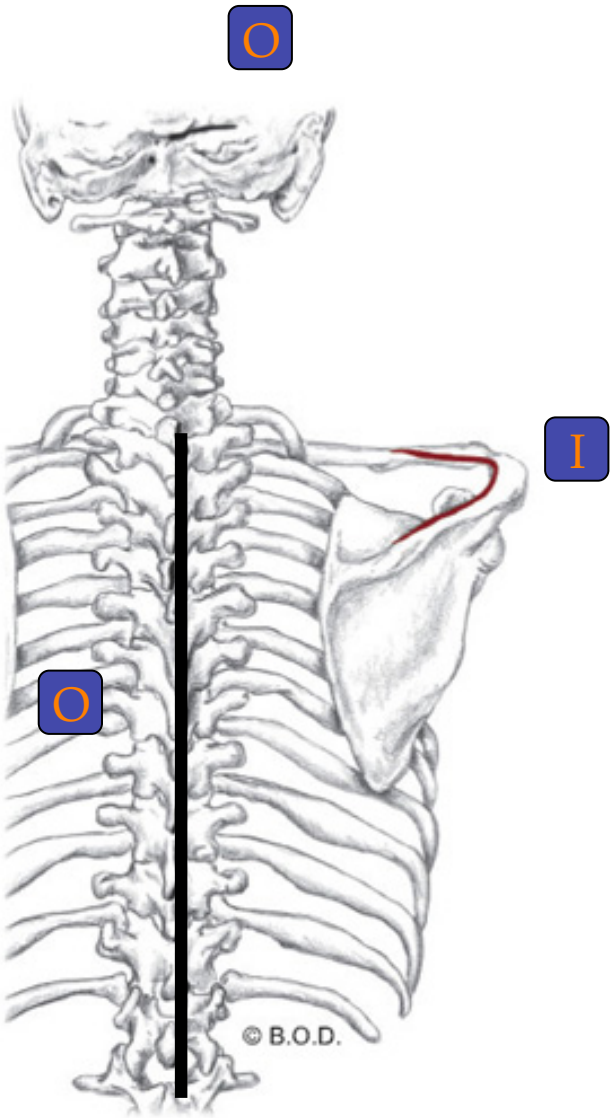

Trapezius

A *Upper fibers:*

Bilaterally

Extend the head and neck

Unilaterally

Laterally flex the head and neck to the same side

Rotate the head and neck to the opposite side

Elevate the scapula (scapulothoracic joint)

Upwardly rotate the scapula (S/T joint)

Middle fibers:

Adduct the scapula (S/T joint)

Stabilize the scapula (S/T joint)

Lower fibers:

Depress the scapula (S/T joint)

Upwardly rotate the scapula (S/T joint)

O External occipital protuberance

Medial portion of superior nuchal line

Ligamentum nuchae

Spinous processes of C-7 through T-12

I Lateral one-third of clavicle

Acromion

Spine of scapula

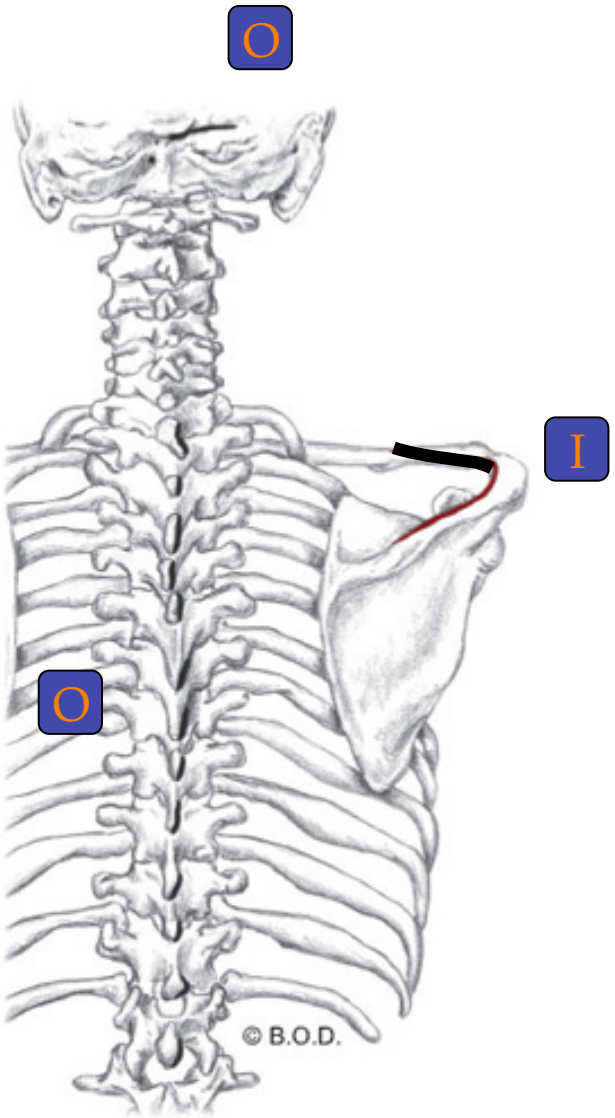

Trapezius

A *Upper fibers:*
Bilaterally
Extend the head and neck
Unilaterally
Laterally flex the head and neck to the same side
Rotate the head and neck to the opposite side
Elevate the scapula (scapulothoracic joint)
Upwardly rotate the scapula (S/T joint)

Middle fibers:
Adduct the scapula (S/T joint)
Stabilize the scapula (S/T joint)

Lower fibers:
Depress the scapula (S/T joint)
Upwardly rotate the scapula (S/T joint)

O External occipital protuberance
Medial portion of superior nuchal line
Ligamentum nuchae
Spinous processes of C-7 through T-12

I Lateral one-third of clavicle
Acromion
Spine of scapula

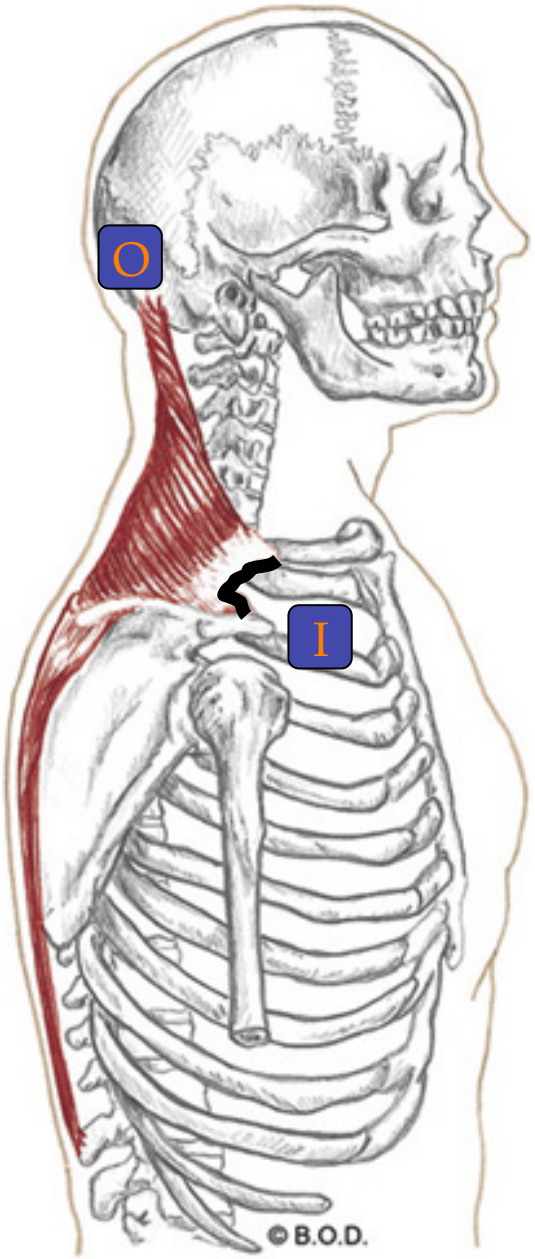

Trapezius

A *Upper fibers:*

Bilaterally

Extend the head and neck

Unilaterally

Laterally flex the head and neck to the same side

Rotate the head and neck to the opposite side

Elevate the scapula (scapulothoracic joint)

Upwardly rotate the scapula (S/T joint)

Middle fibers:

Adduct the scapula (S/T joint)

Stabilize the scapula (S/T joint)

Lower fibers:

Depress the scapula (S/T joint)

Upwardly rotate the scapula (S/T joint)

O External occipital protuberance

Medial portion of superior nuchal line

Ligamentum nuchae

Spinous processes of C-7 through T-12

I Lateral one-third of clavicle

Acromion

Spine of scapula

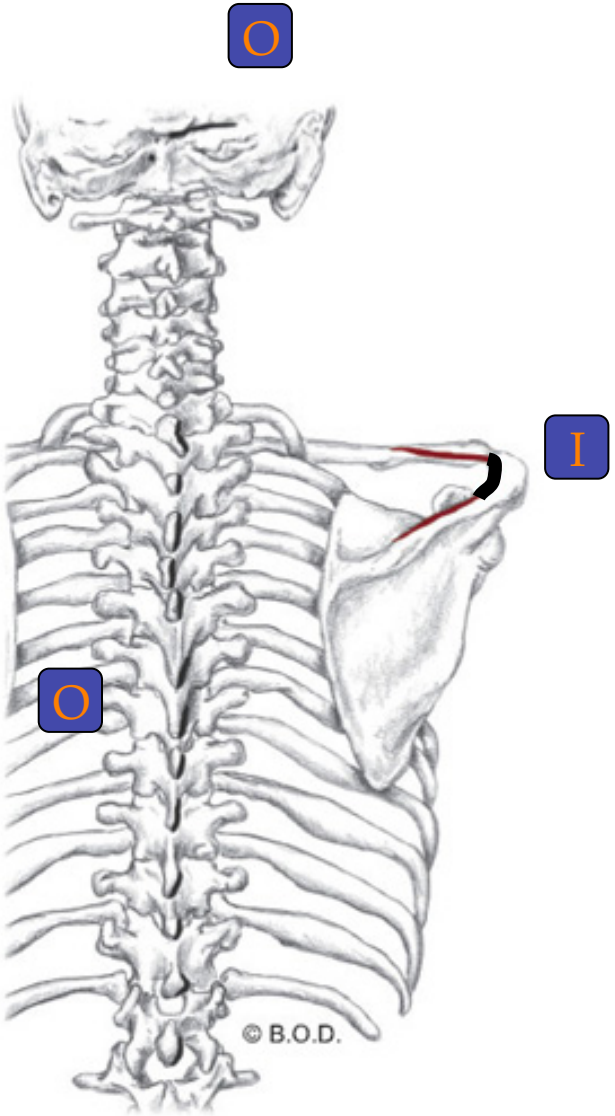

Trapezius

A *Upper fibers:*

Bilaterally

Extend the head and neck

Unilaterally

Laterally flex the head and neck to the same side

Rotate the head and neck to the opposite side

Elevate the scapula (scapulothoracic joint)

Upwardly rotate the scapula (S/T joint)

Middle fibers:

Adduct the scapula (S/T joint)

Stabilize the scapula (S/T joint)

Lower fibers:

Depress the scapula (S/T joint)

Upwardly rotate the scapula (S/T joint)

O External occipital protuberance

Medial portion of superior nuchal line

Ligamentum nuchae

Spinous processes of C-7 through T-12

I Lateral one-third of clavicle

Acromion

Spine of scapula

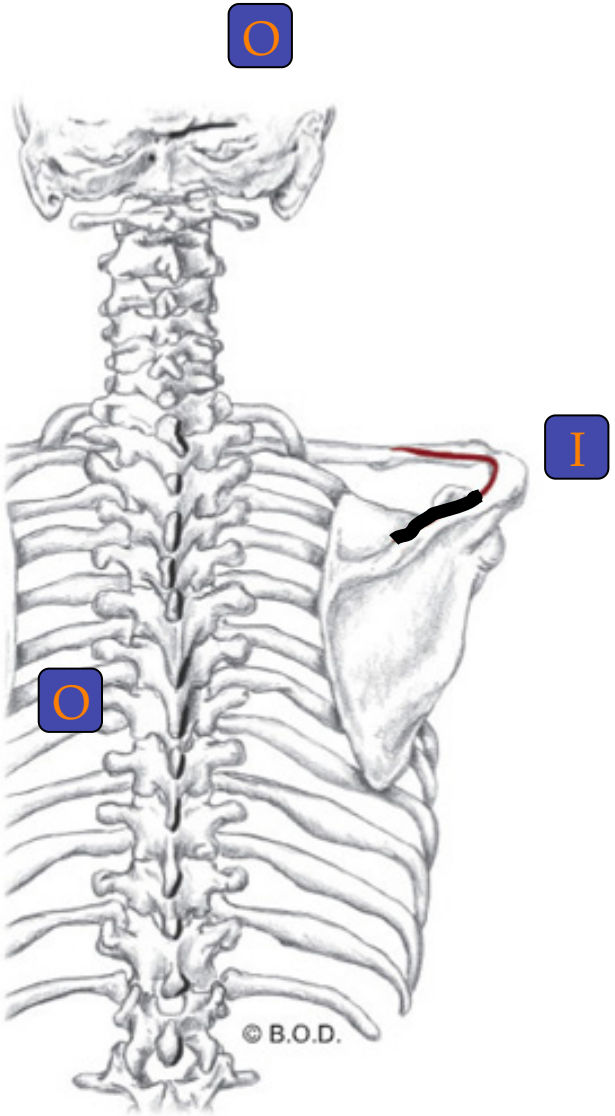

2a Kinesiology:
Names and Locations of Bones and Posterior Muscles
E - 17

Divisions of the Skeletal System

Adult Human	206 bones total
Axial Skeleton	80 bones
Appendicular Skeleton	126 bones

Divisions of the Skeletal System

80 Axial Skeleton

- The skeleton that a snake would have
- No arms or legs

126 Appendicular Skeleton

- The shoulder girdle and arms
- The pelvic girdle and legs

Axial Skelton in BLUE (80 bones)

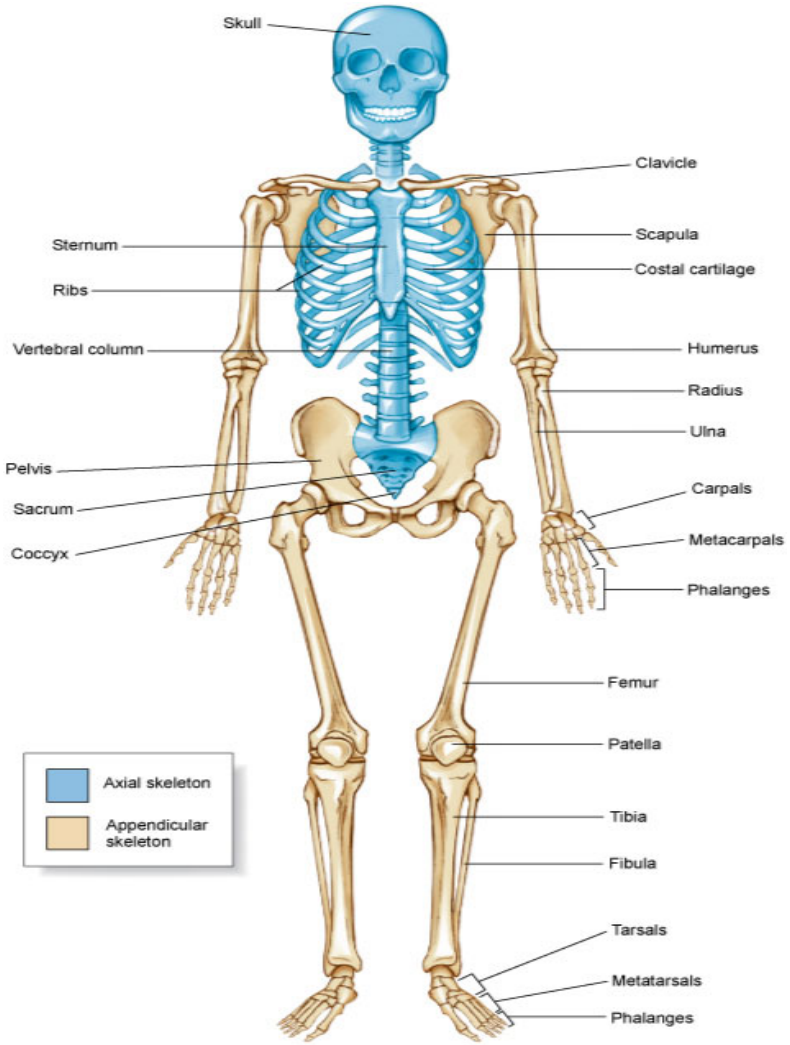

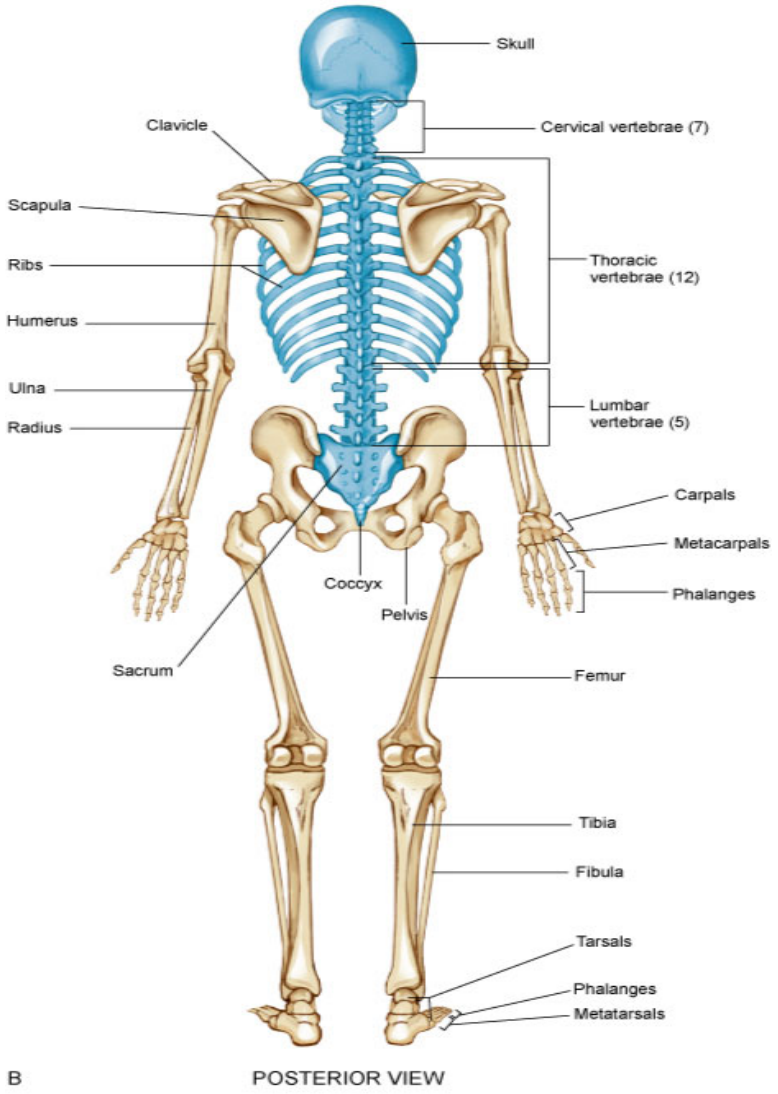

Appendicular Skeleton in WHITE (126 bones)

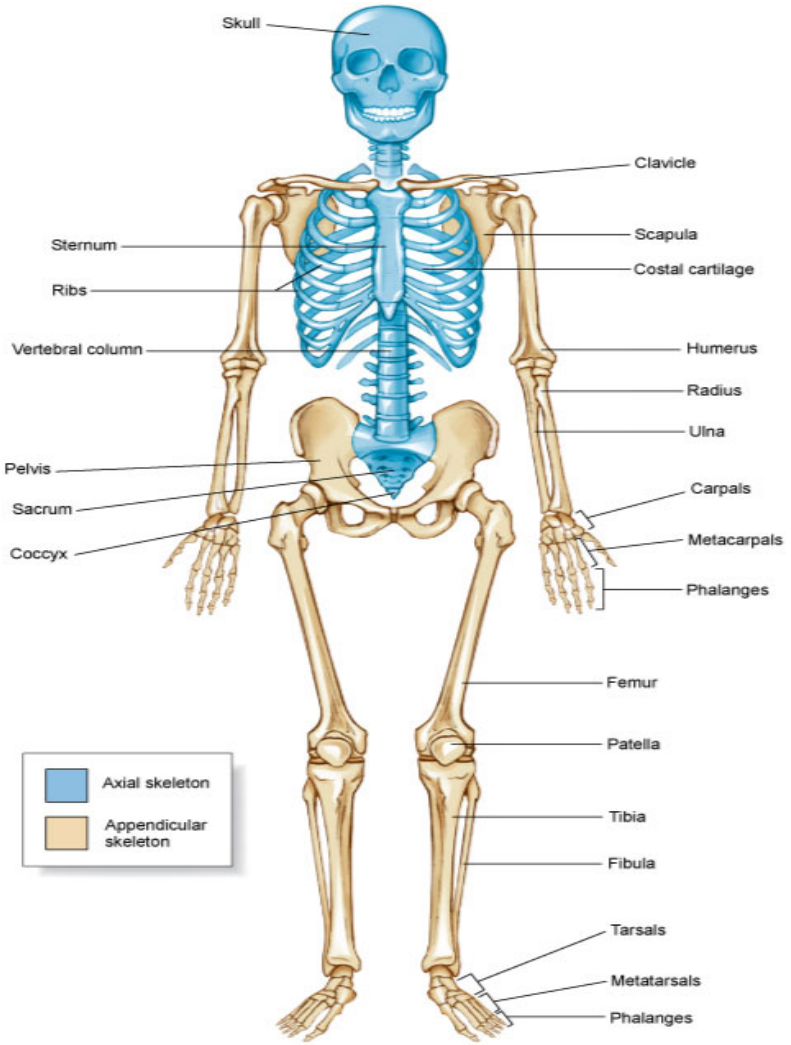

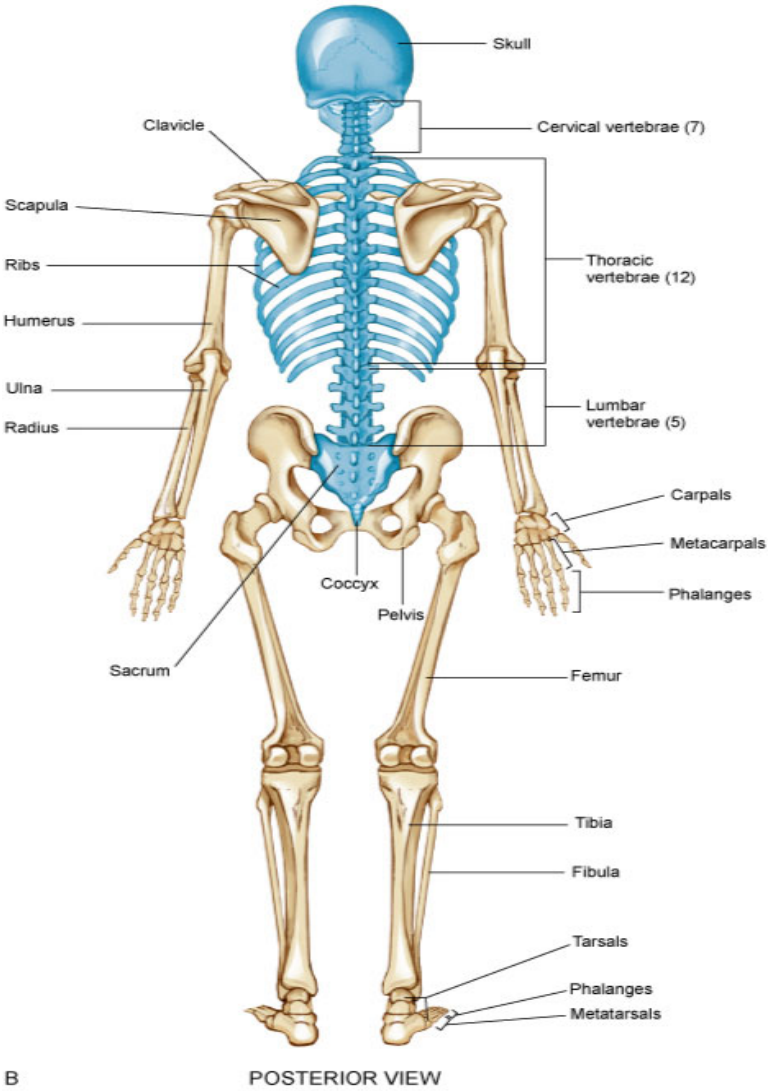

Human Skeleton (206 bones)

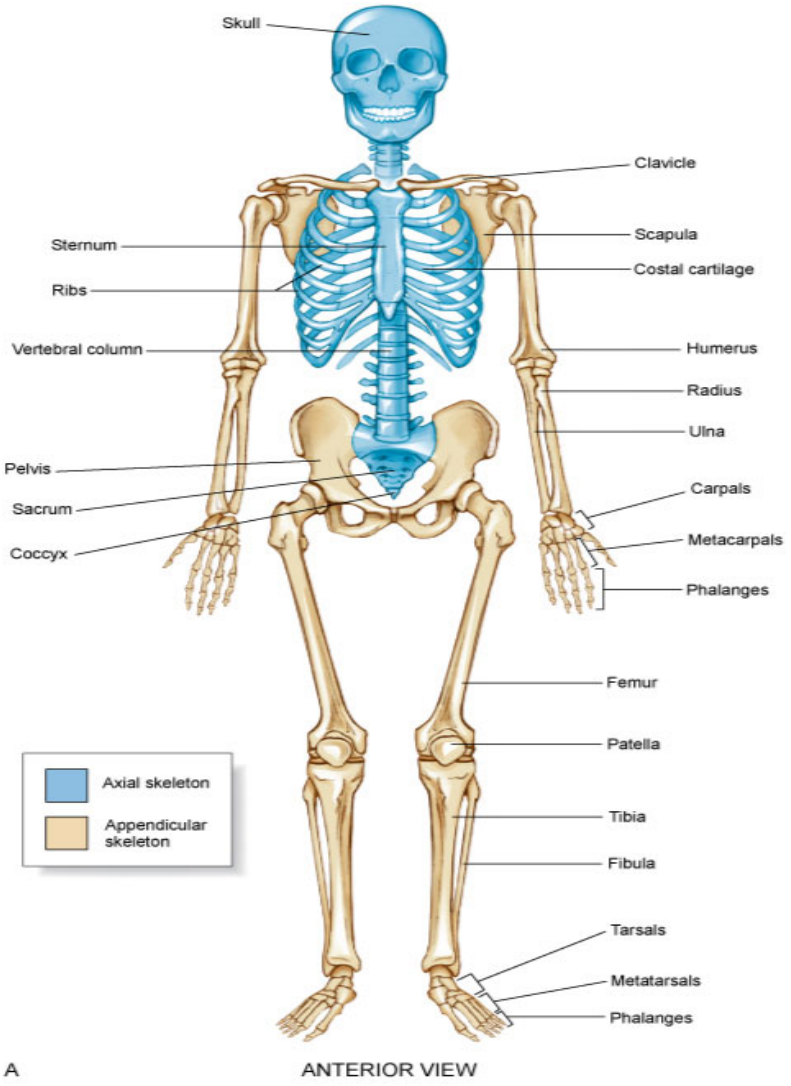

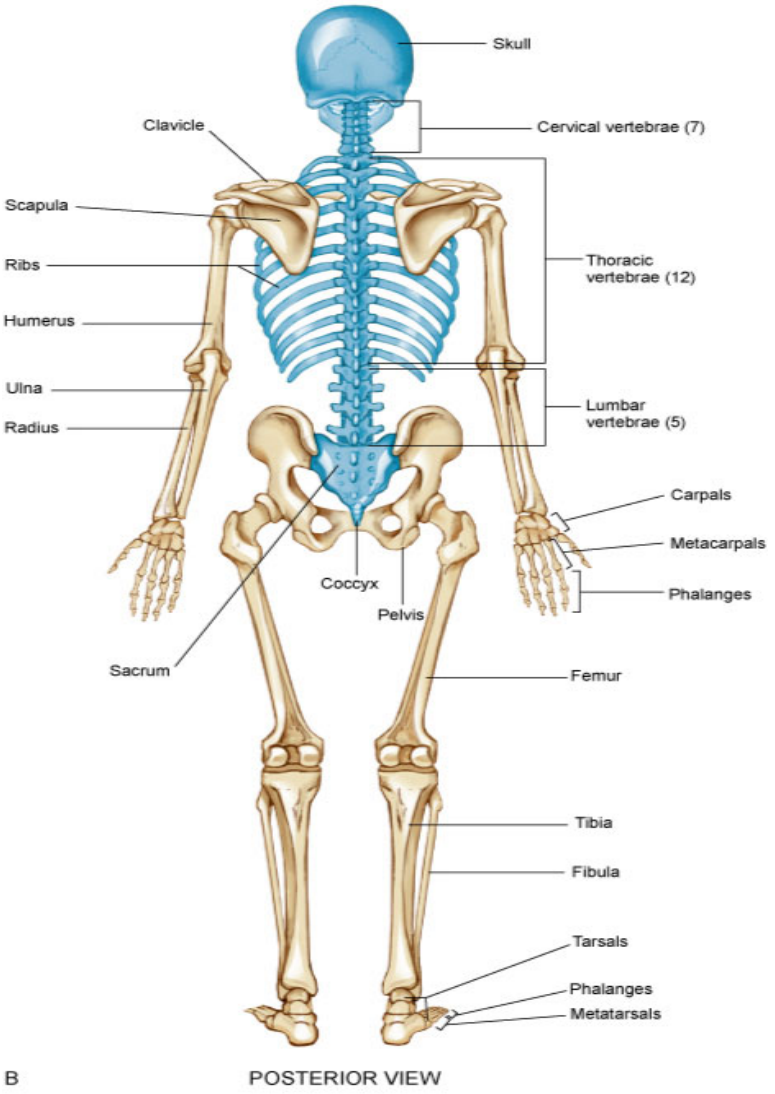

80 Axial Skeleton

80 Axial Skeleton

29 Skull
26 Vertebral column
1 Sternum
24 Ribs
80 Total

80 Axial Skeleton

29 Skull

8 Cranium

14 Face

6 Ear

1 Hyoid

80 Axial Skeleton

8 Cranium

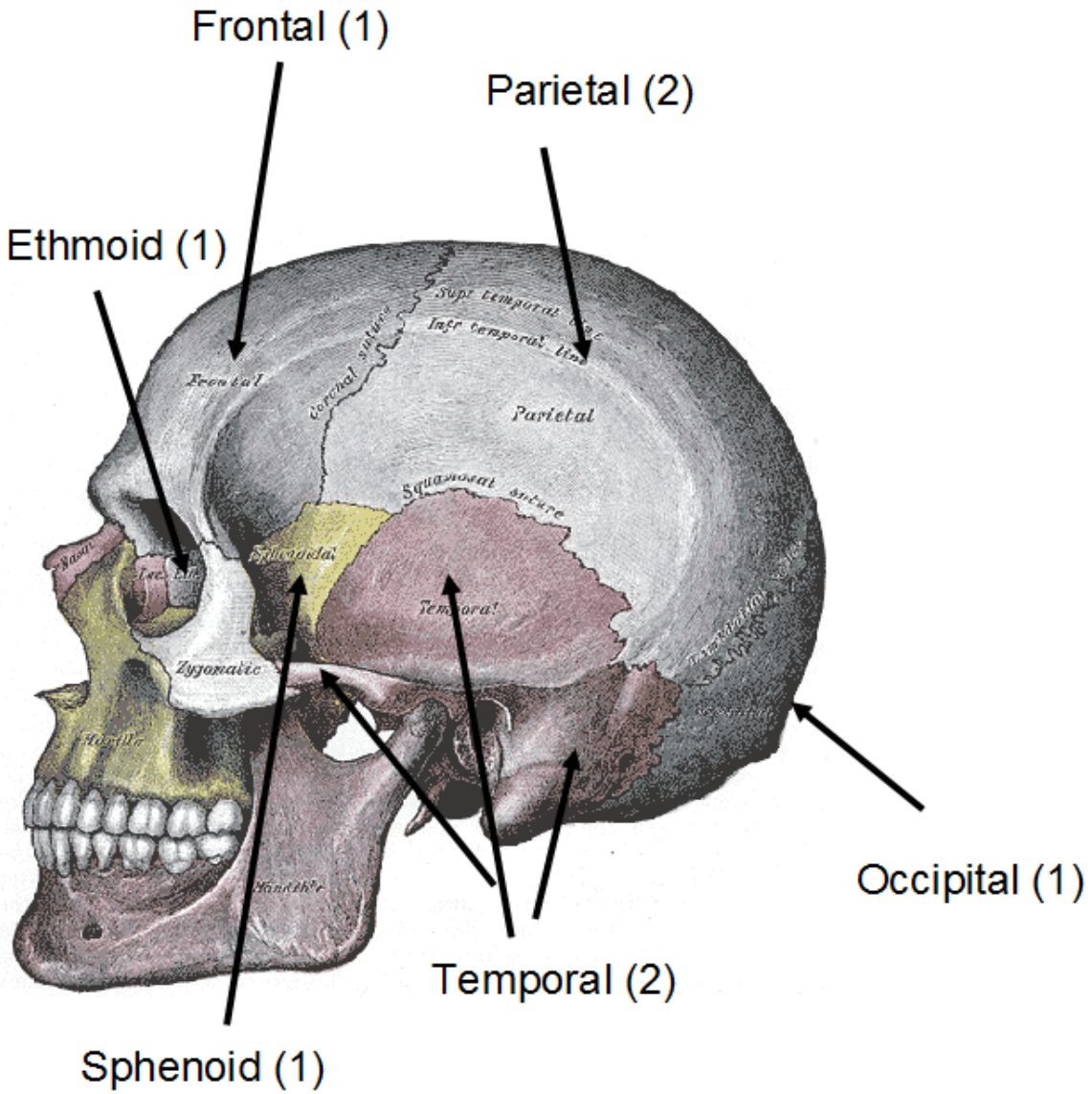

80 Axial Skeleton

1 Sphenoid

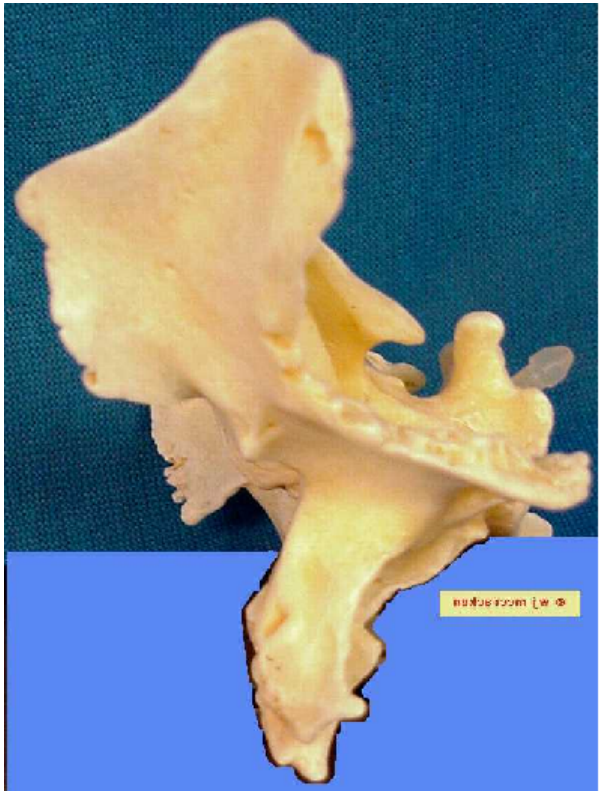

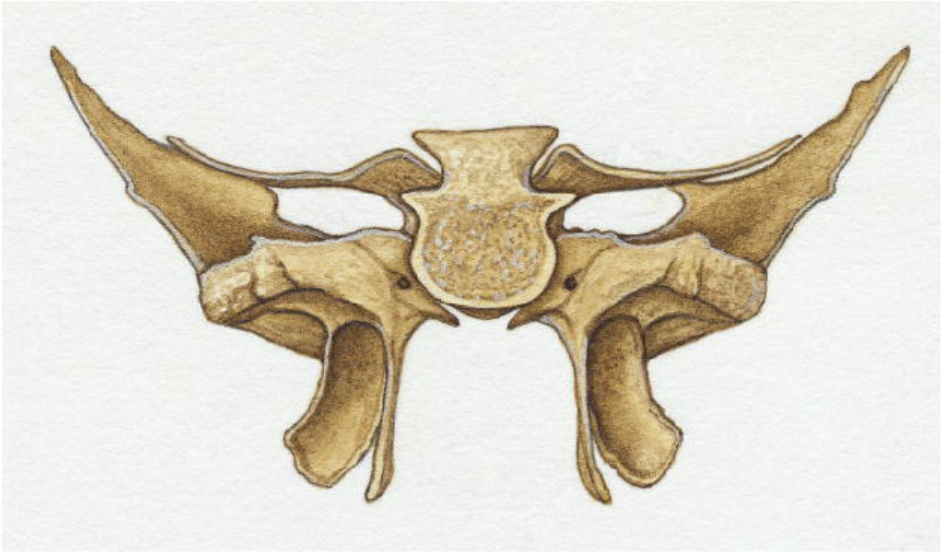

80 Axial Skeleton

14 Face

zygomatic 2

mandible 1

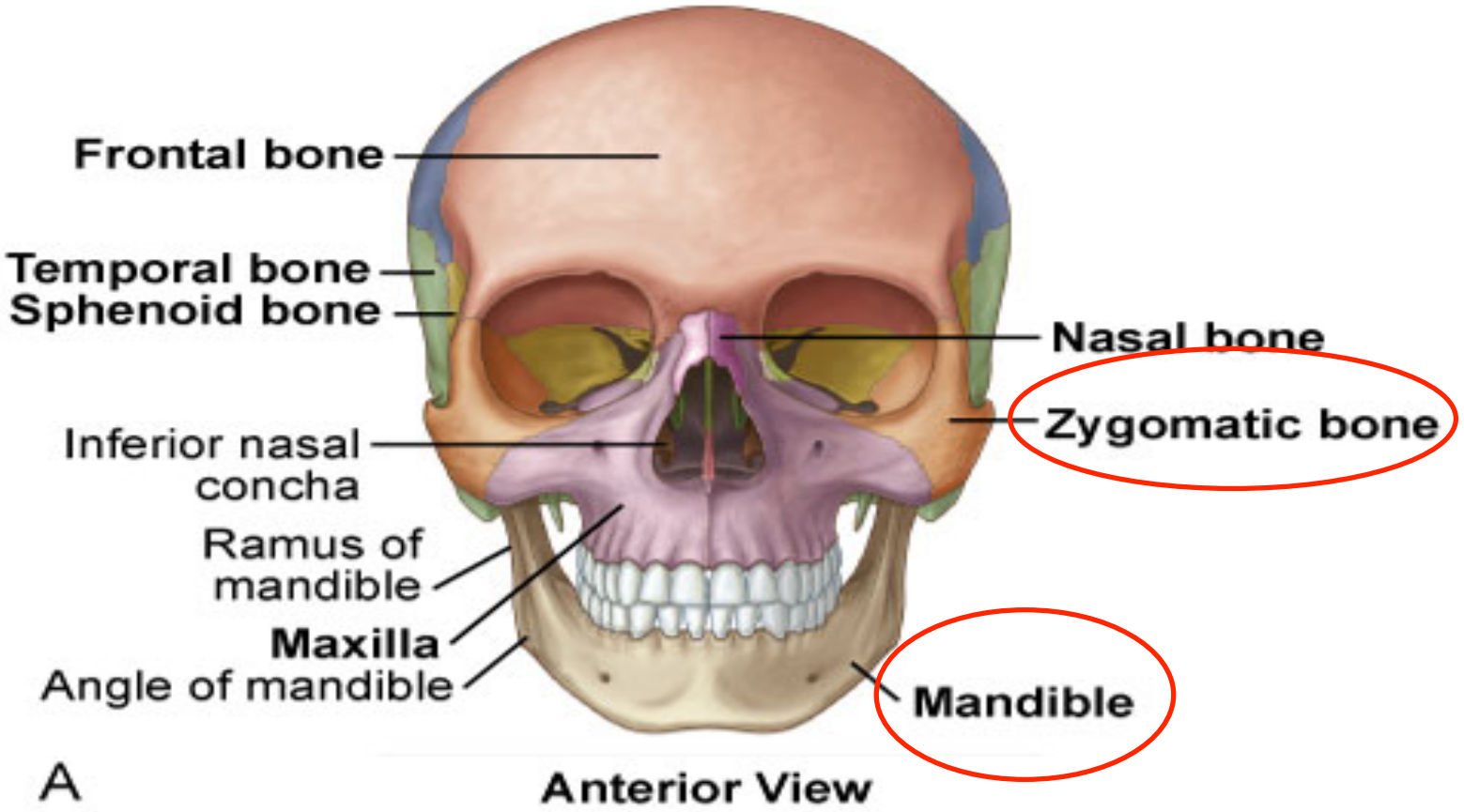

80 Axial Skeleton

14 Face

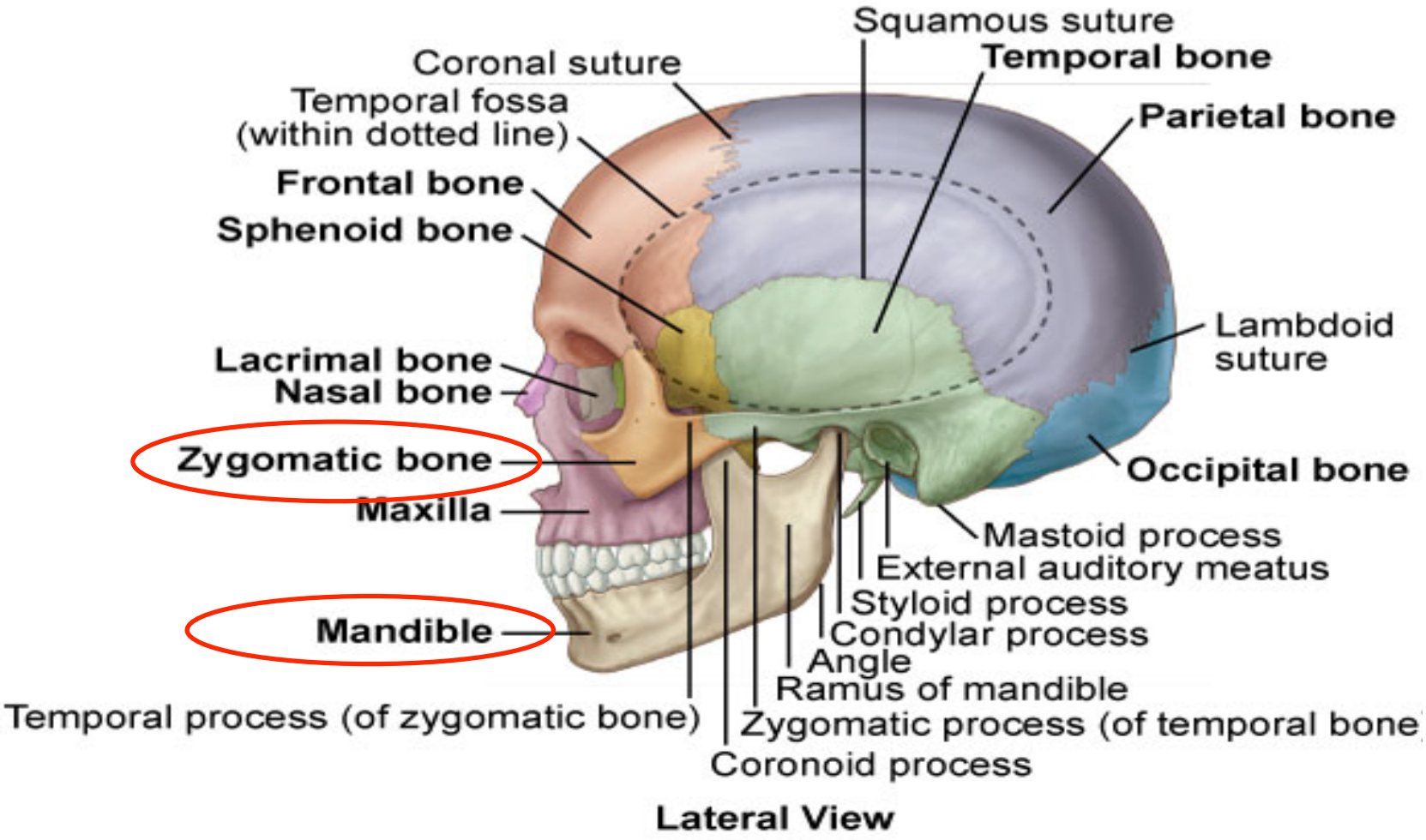

80 Axial Skeleton

6 Ear

2 malleus (hammer)
2 incus (anvil)
2 stapes (stirrup)

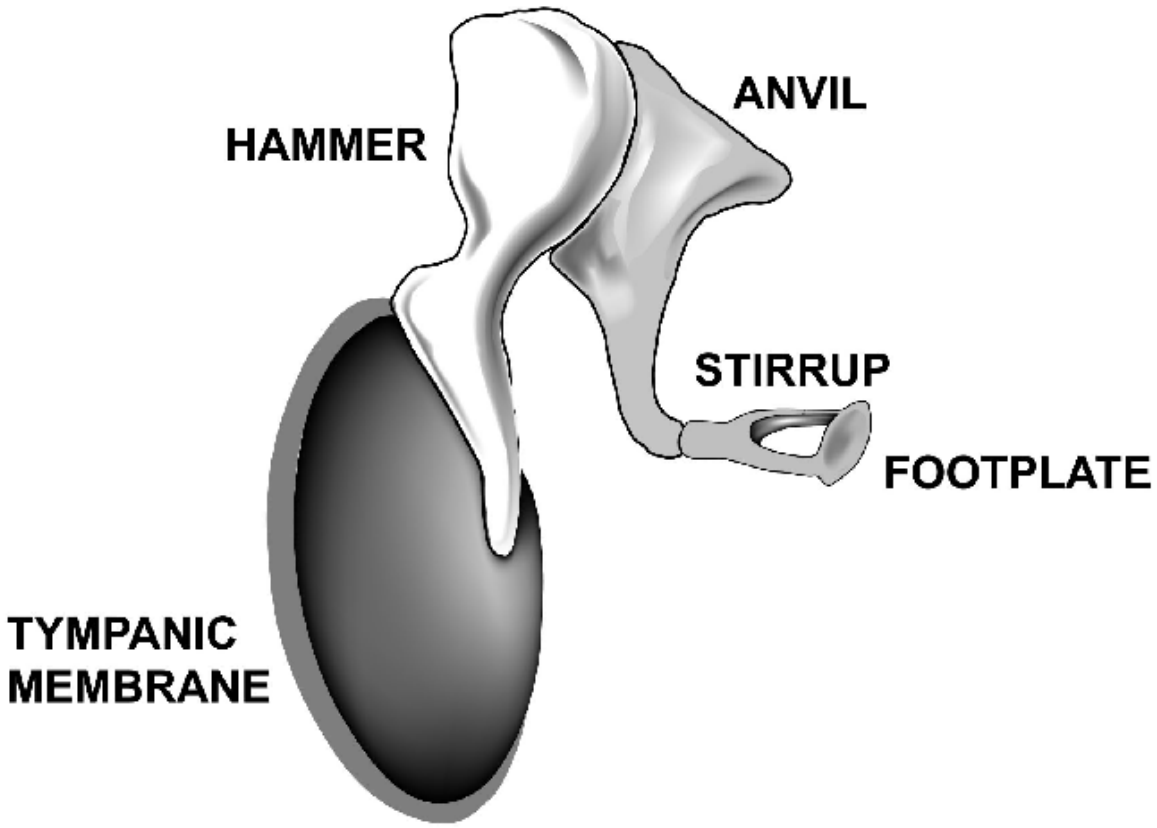

80 Axial Skeleton

6 Ear

2 malleus (hammer)

2 incus (anvil)

2 stapes (stirrup)

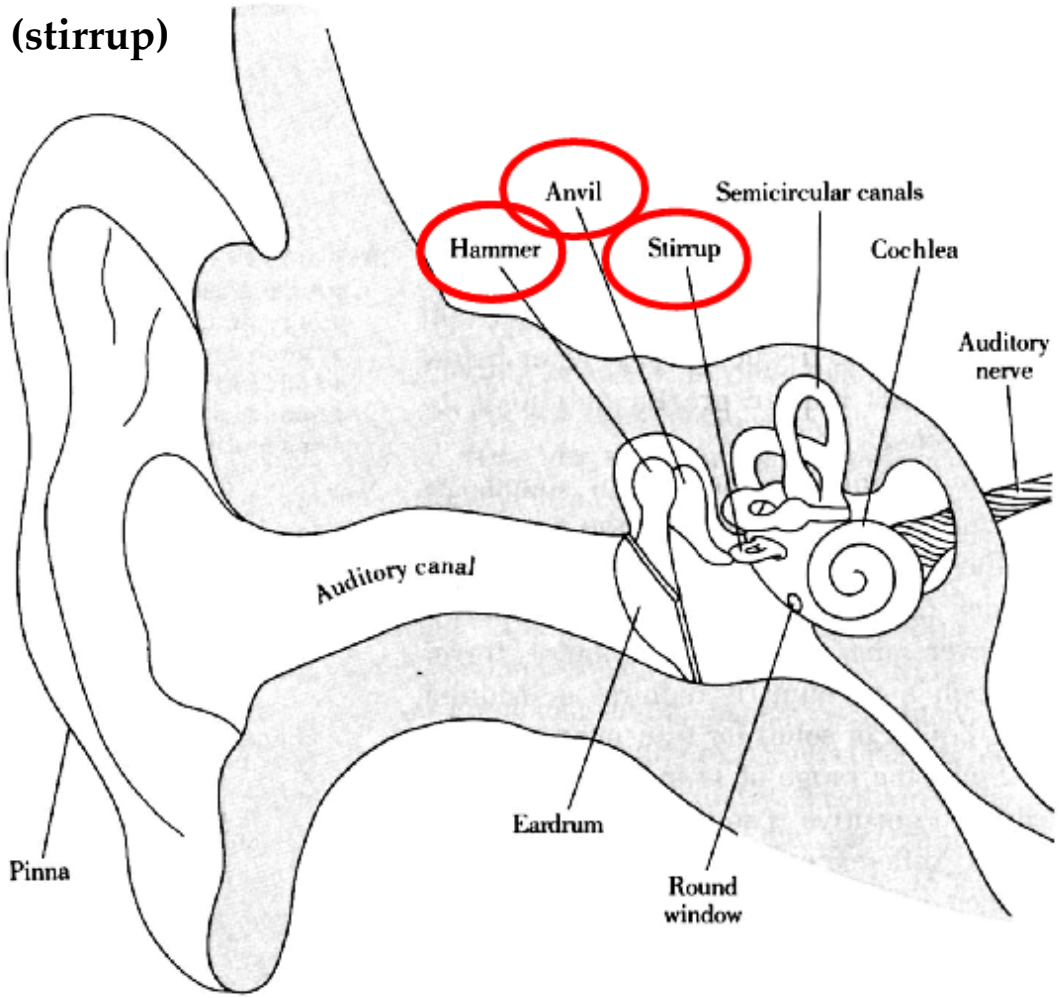

80 Axial Skeleton

1 Hyoid

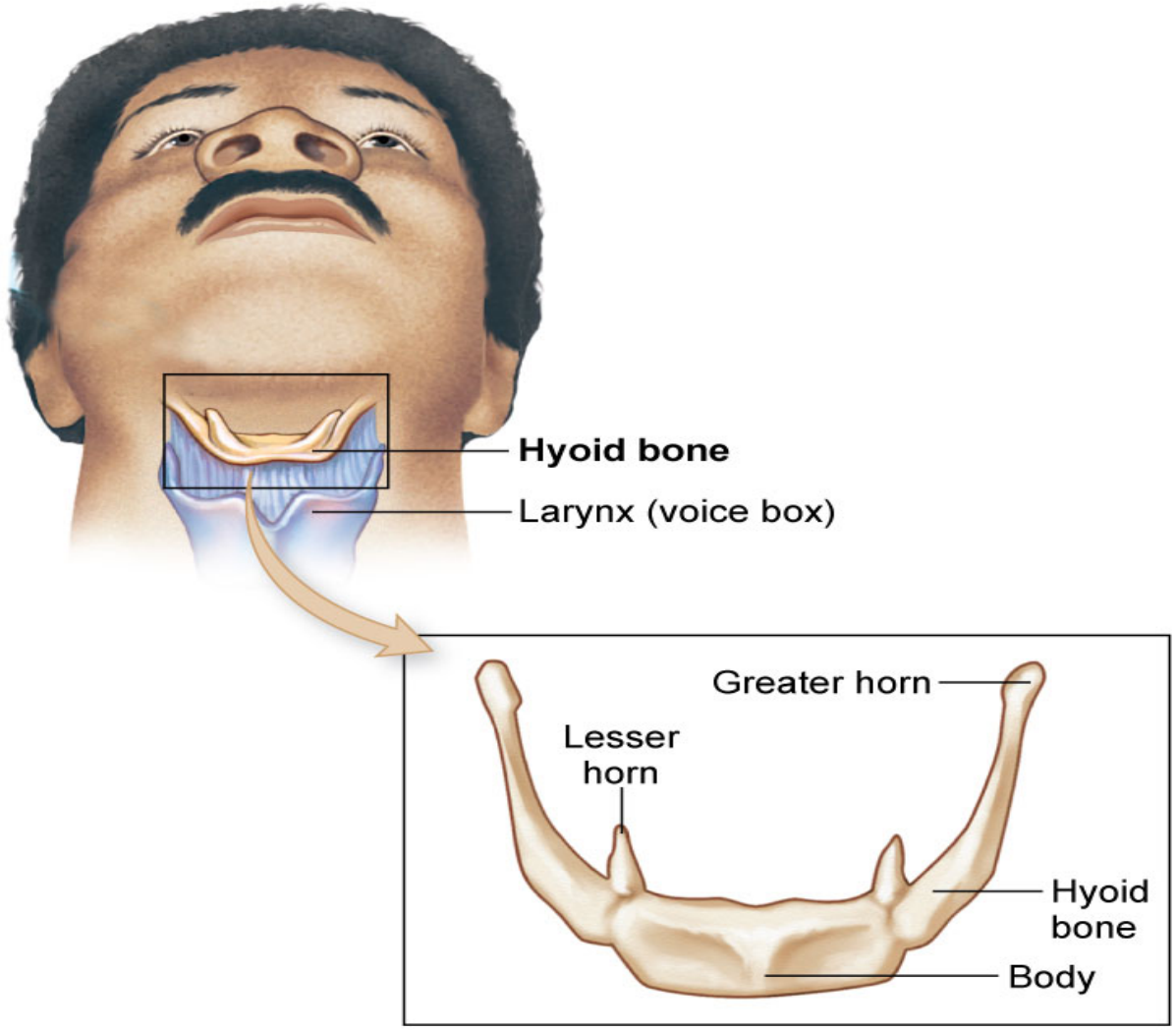

From Patton KT, Thibodeau GA: *Anatomy & physiology,* ed 7, St. Louis, 2010, Mosby.

Fig. 21-19. Hyoid bone, anterior view.

80 Axial Skeleton

29 Skull

8 Cranium

14 Face

6 Ear

1 Hyoid

80 Axial Skeleton

26 Vertebral Column

- 7 Cervical
- 12 Thoracic
- 5 Lumbar
- 1 Sacrum
- 1 Coccyx

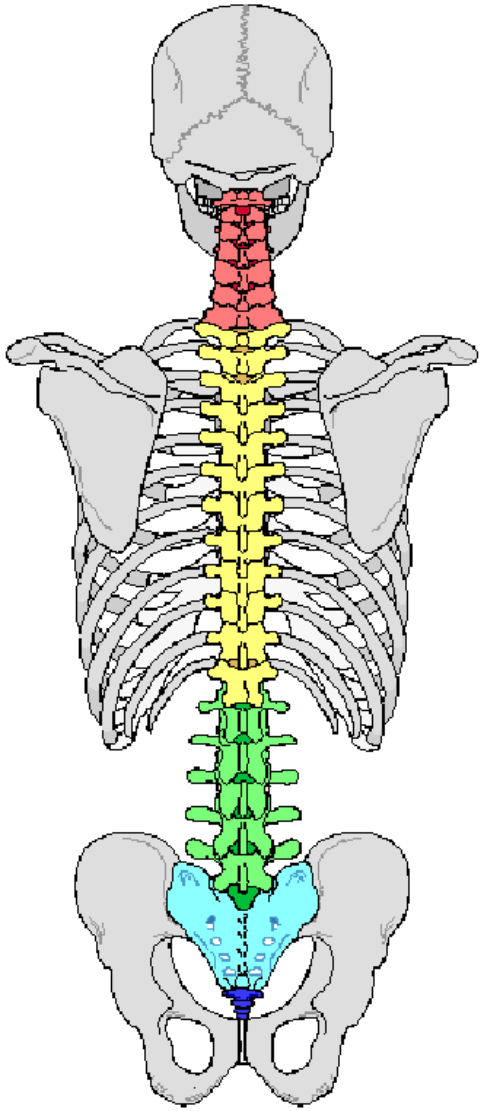

80 Axial Skeleton

<u>26 Vertebral Column</u>

7 Cervical

12 Thoracic

5 Lumbar

1 Sacrum

1 Coccyx

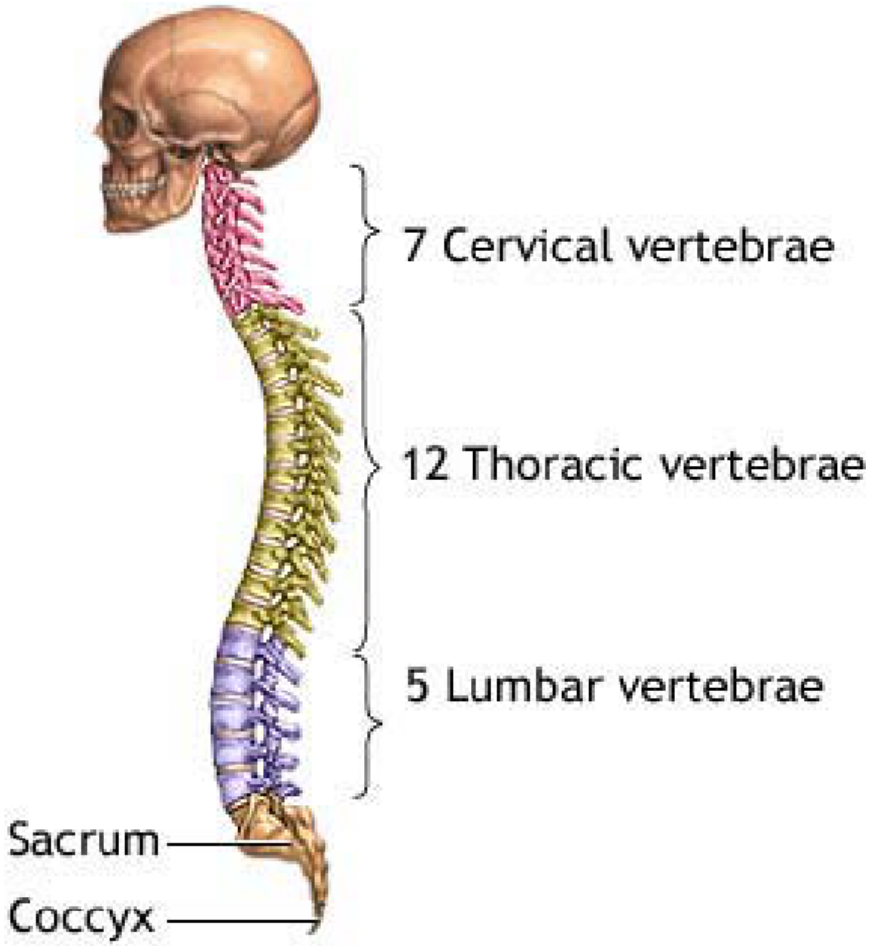

80 Axial Skeleton

1 Sternum

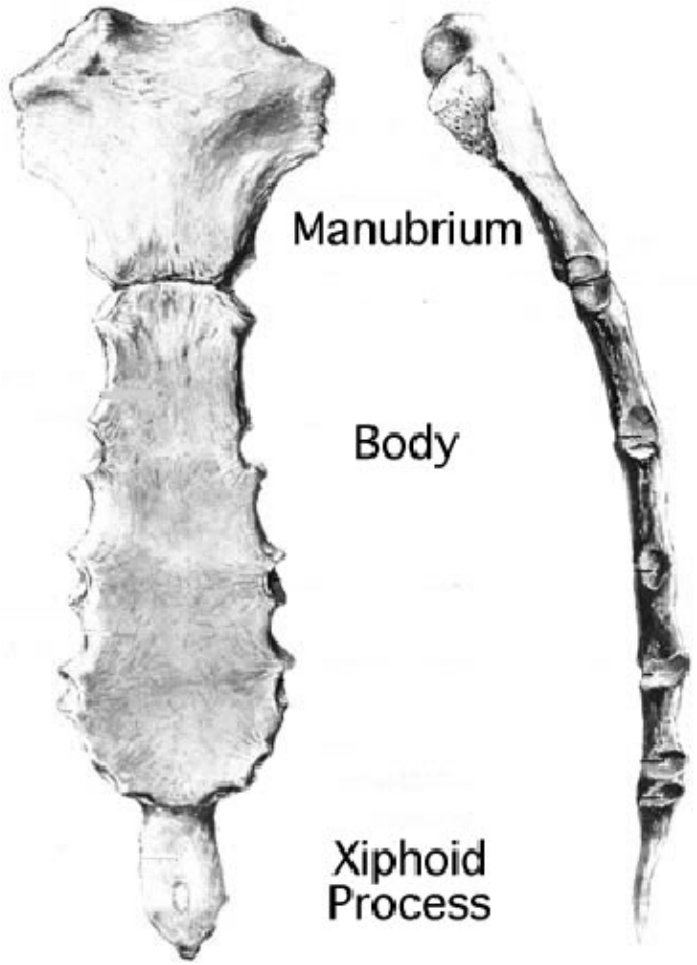

80 Axial Skeleton

<u>24 Ribs</u>

14 True ribs	Directly attaching to the sternum by way of cartilage.
6 False ribs	Not *directly* attached to the sternum.
4 Floating ribs	Not attached to the sternum at all.

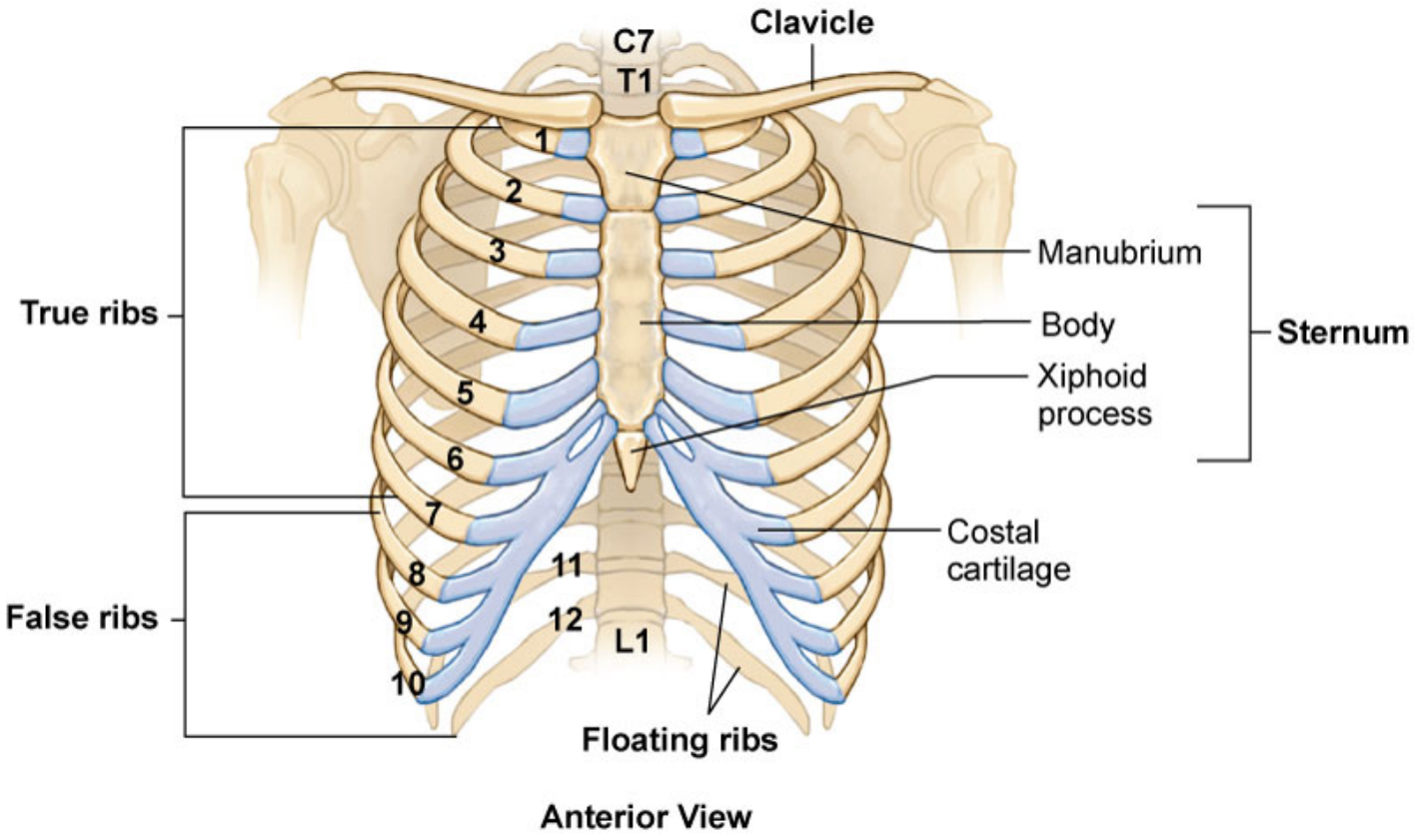



126 Appendicular Skeleton

126 Appendicular Skeleton

4 Shoulder Girdle
60 Upper Extremity
2 Pelvic Girdle
60 Lower Extremity

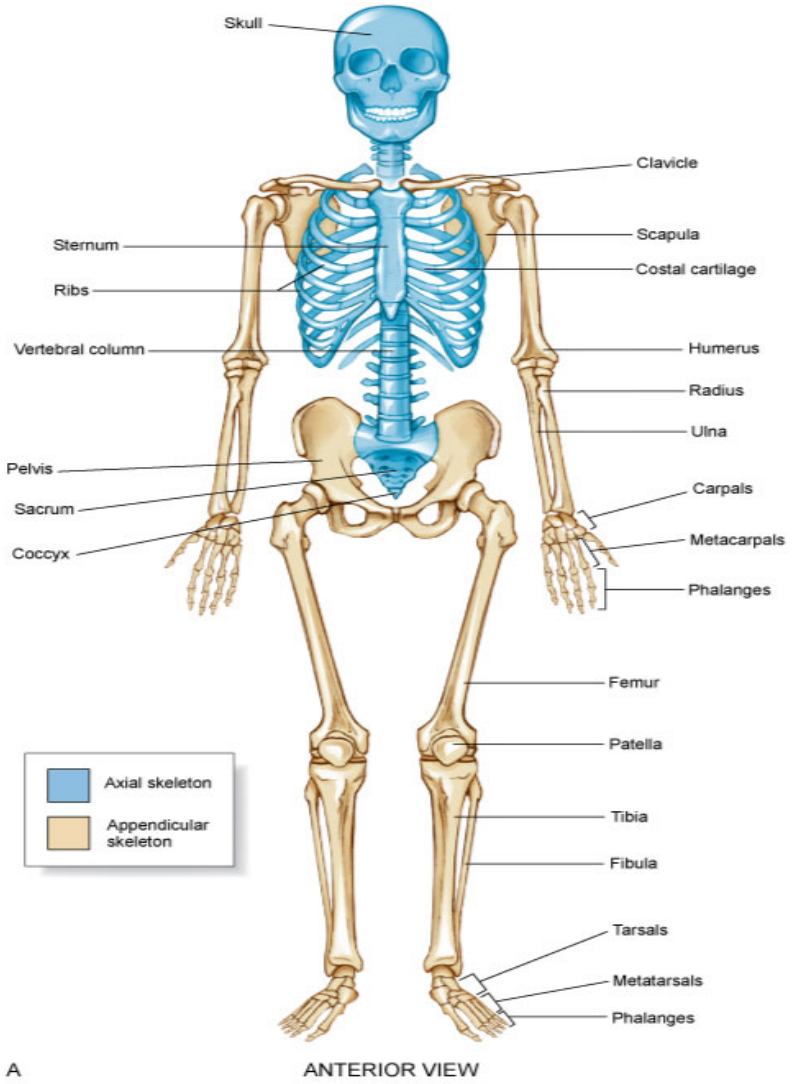

126 Appendicular Skeleton

4 Shoulder Girdle

clavicle 2

scapula 2

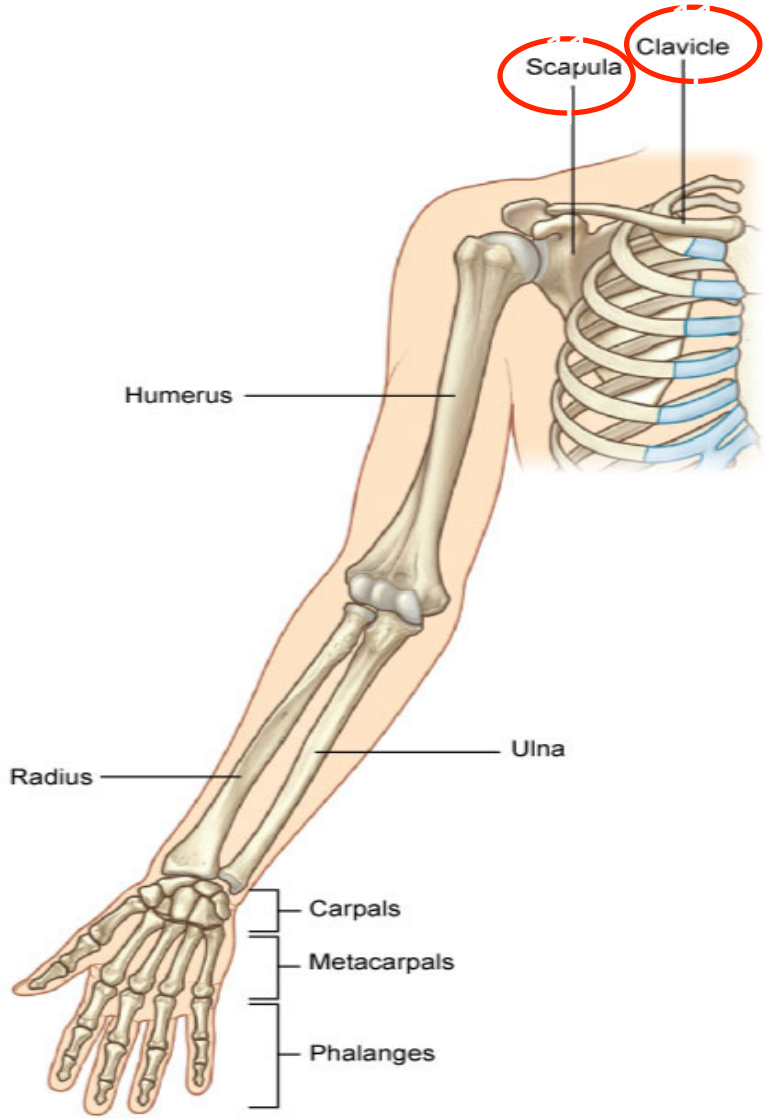

126 Appendicular Skeleton

60 Upper Extremity

- **humerus 2**
- **radius 2**
- **ulna 2**
- **carpals 16**
- **metacarpals 10**
- **phalanges 28**

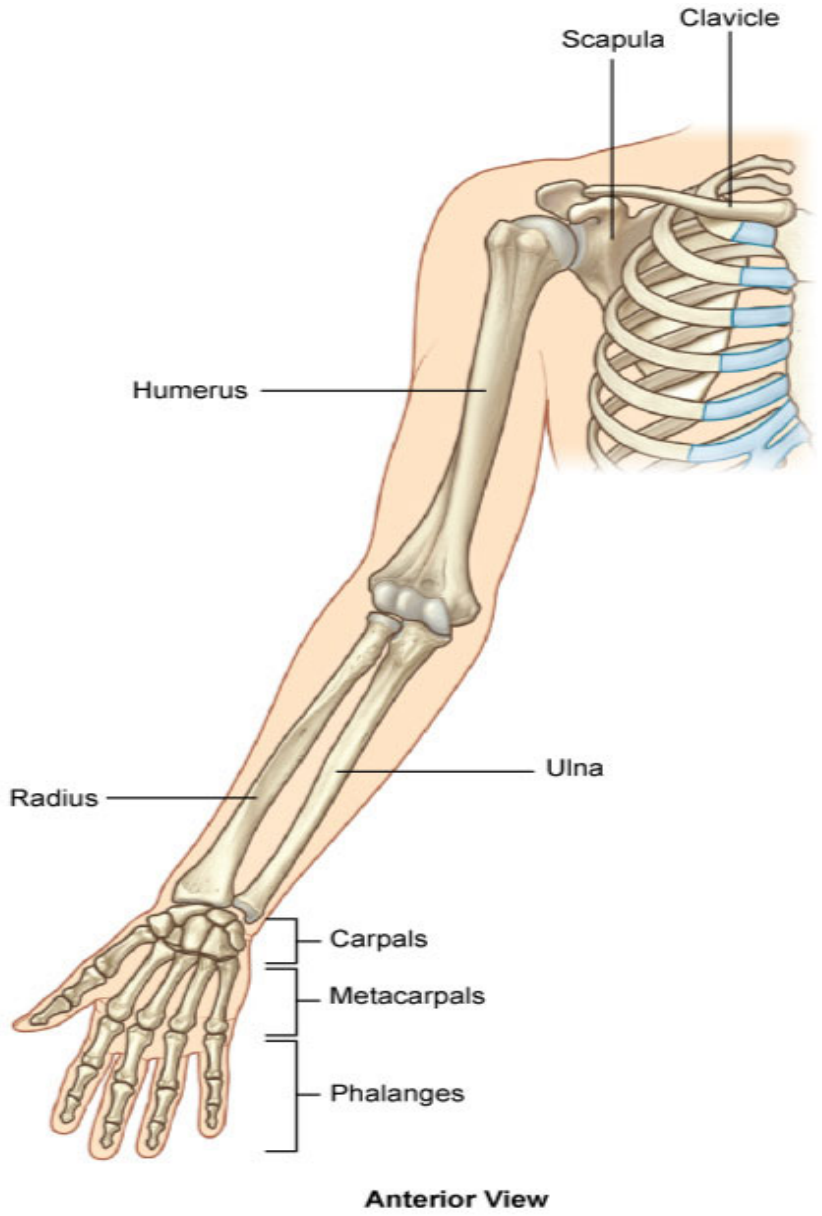

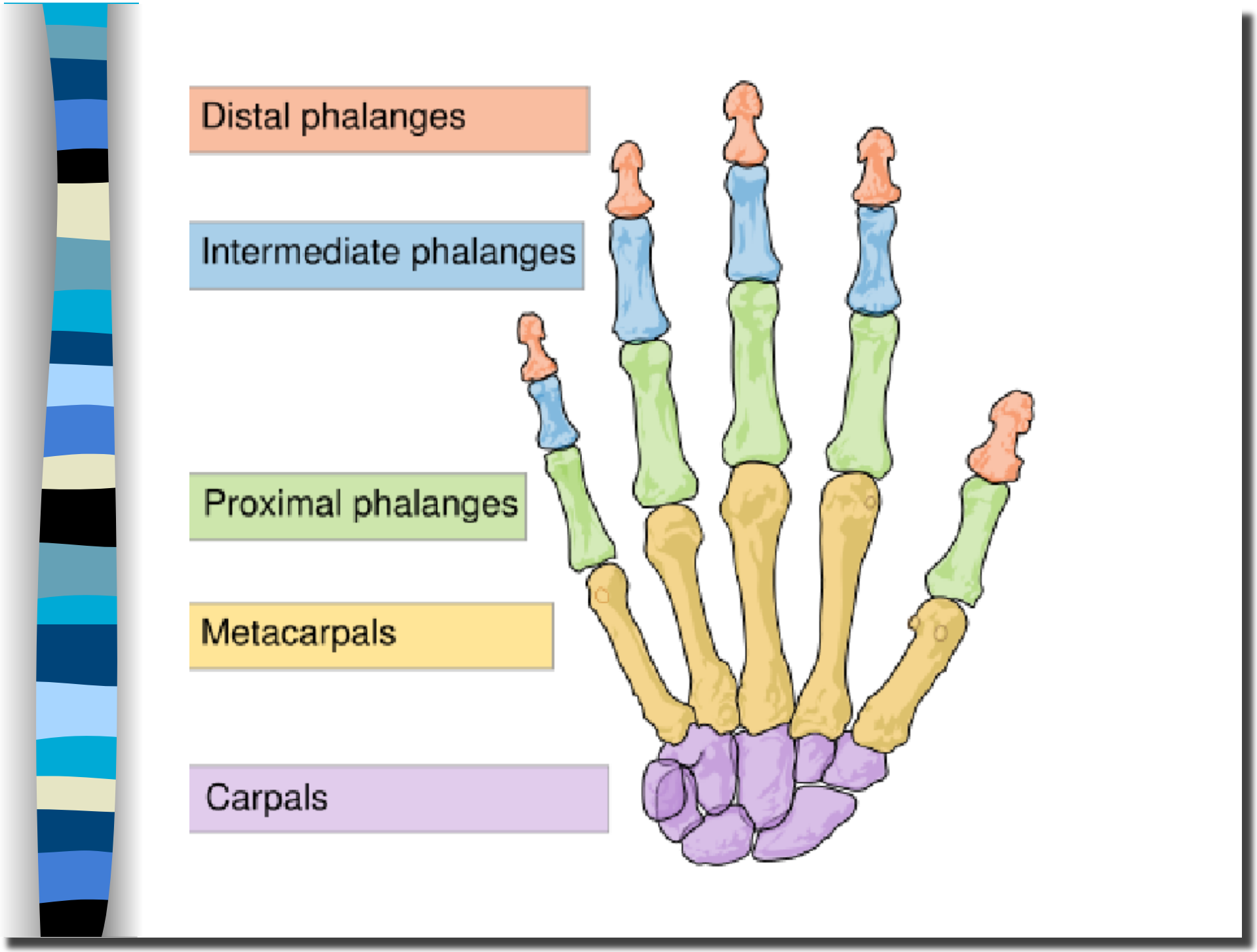
Distal phalanges
Intermediate phalanges
Proximal phalanges
Metacarpals
Carpals

126 Appendicular Skeleton

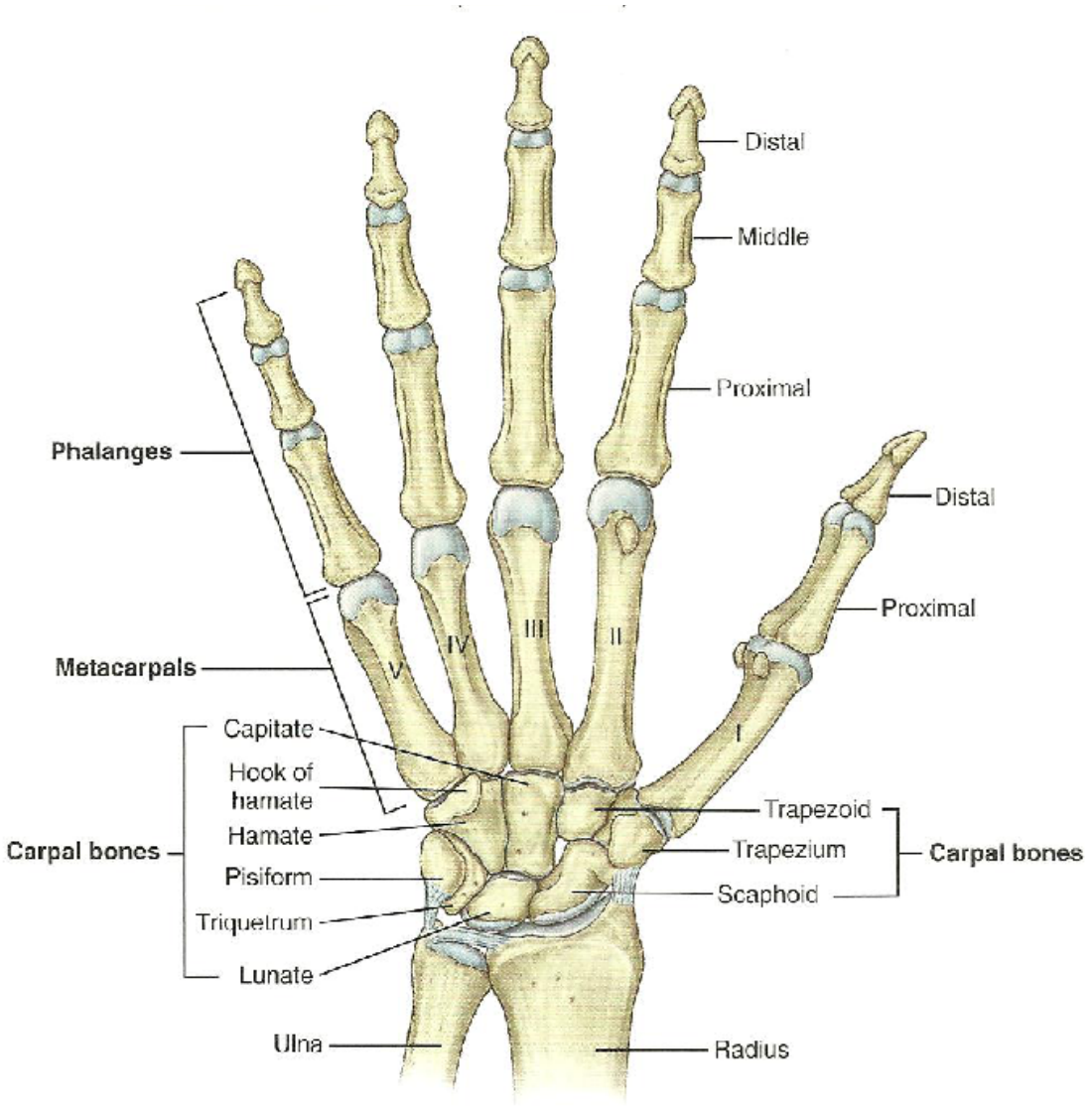

Posterior View

126 Appendicular Skeleton

2 Pelvic Girdle

pelvic bone

AKA: innominate bone

AKA: os coxae or coxal bone

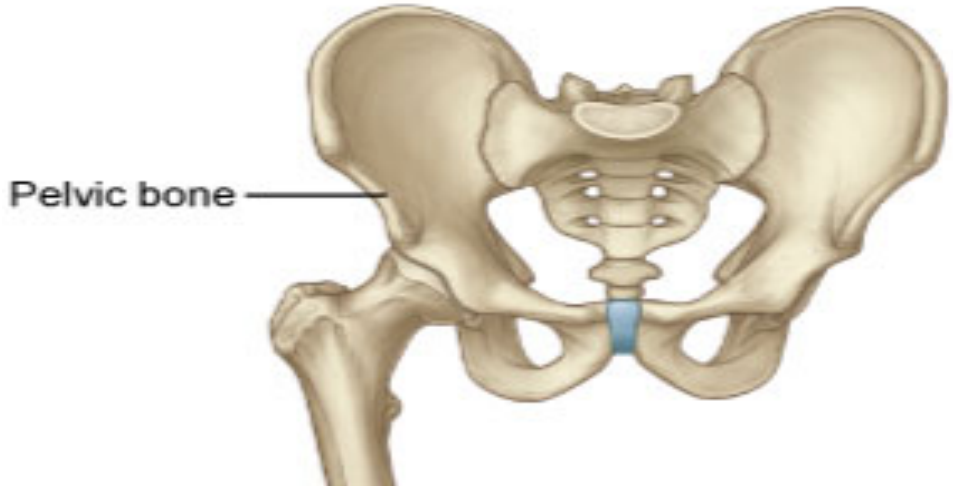

126 Appendicular Skeleton

2 Pelvic Girdle

pelvic bone

ilium

ischium

pubis

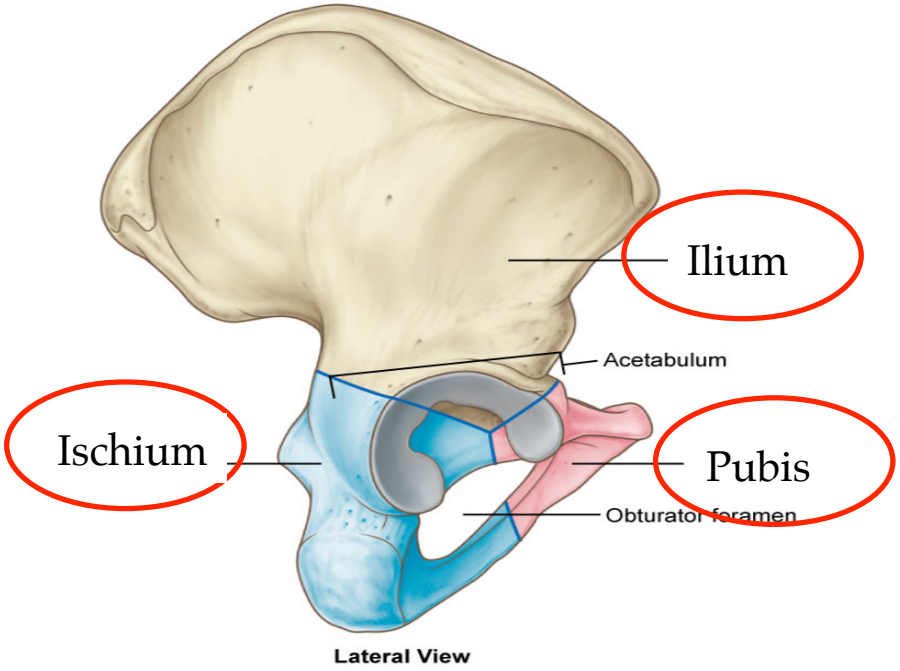

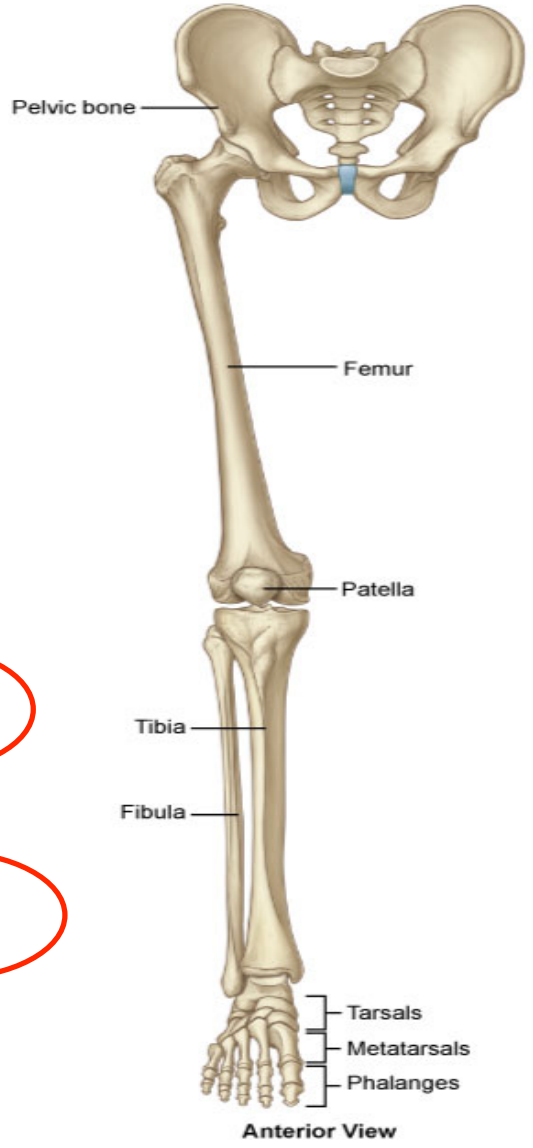

126 Appendicular Skeleton

60 Lower Extremity

- **femur 2**
- **patella 2**
- **tibia 2**
- **fibula 2**
- **tarsals 14**
- **metatarsals 10**
- **phalanges 28**

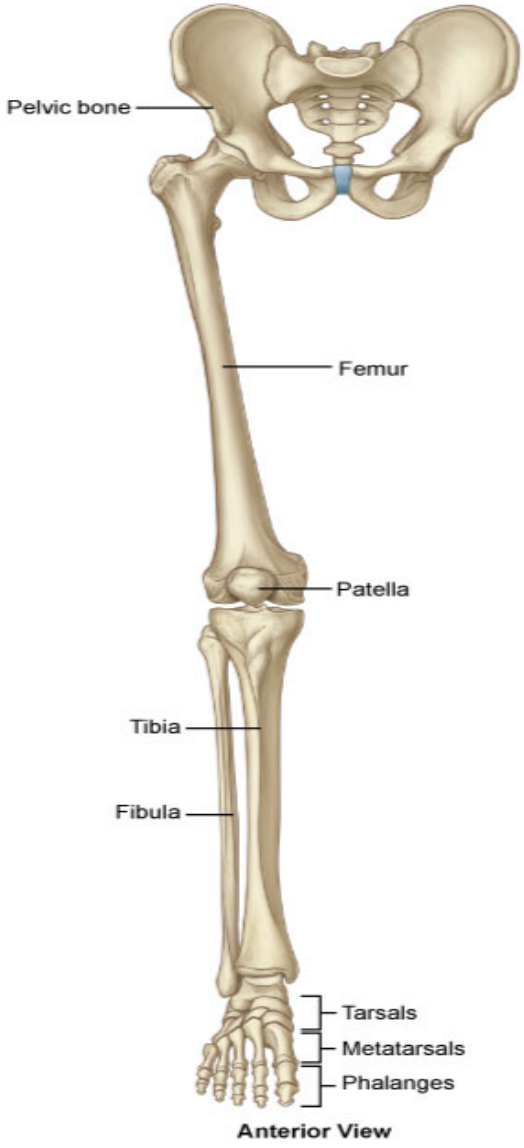

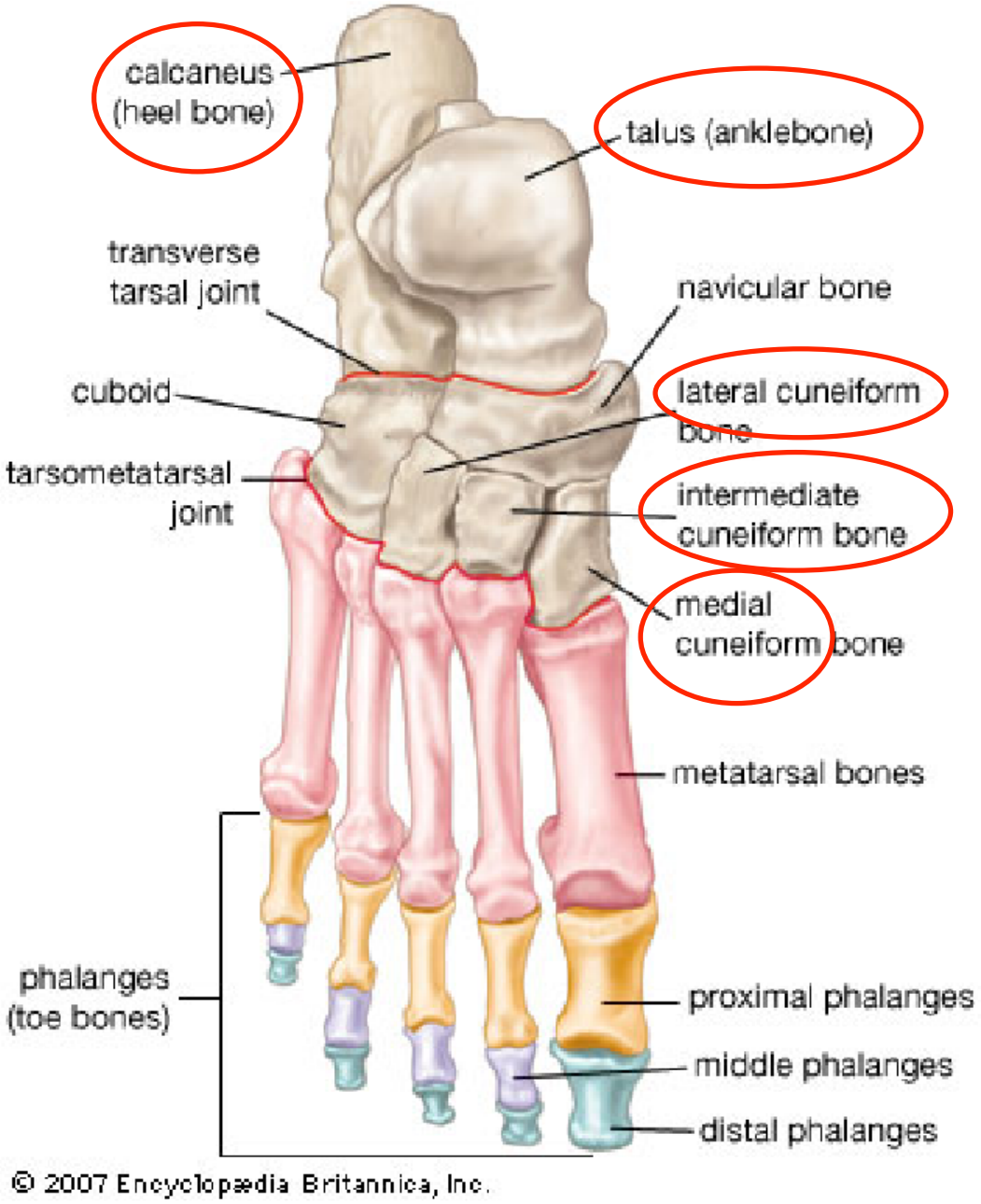
calcaneus (heel bone)
talus (anklebone)
transverse tarsal joint
navicular bone
cuboid
lateral cuneiform bone
tarsometatarsal joint
intermediate cuneiform bone
medial cuneiform bone
metatarsal bones
phalanges (toe bones)
proximal phalanges
middle phalanges
distal phalanges
© 2007 Encyclopædia Britannica, Inc.

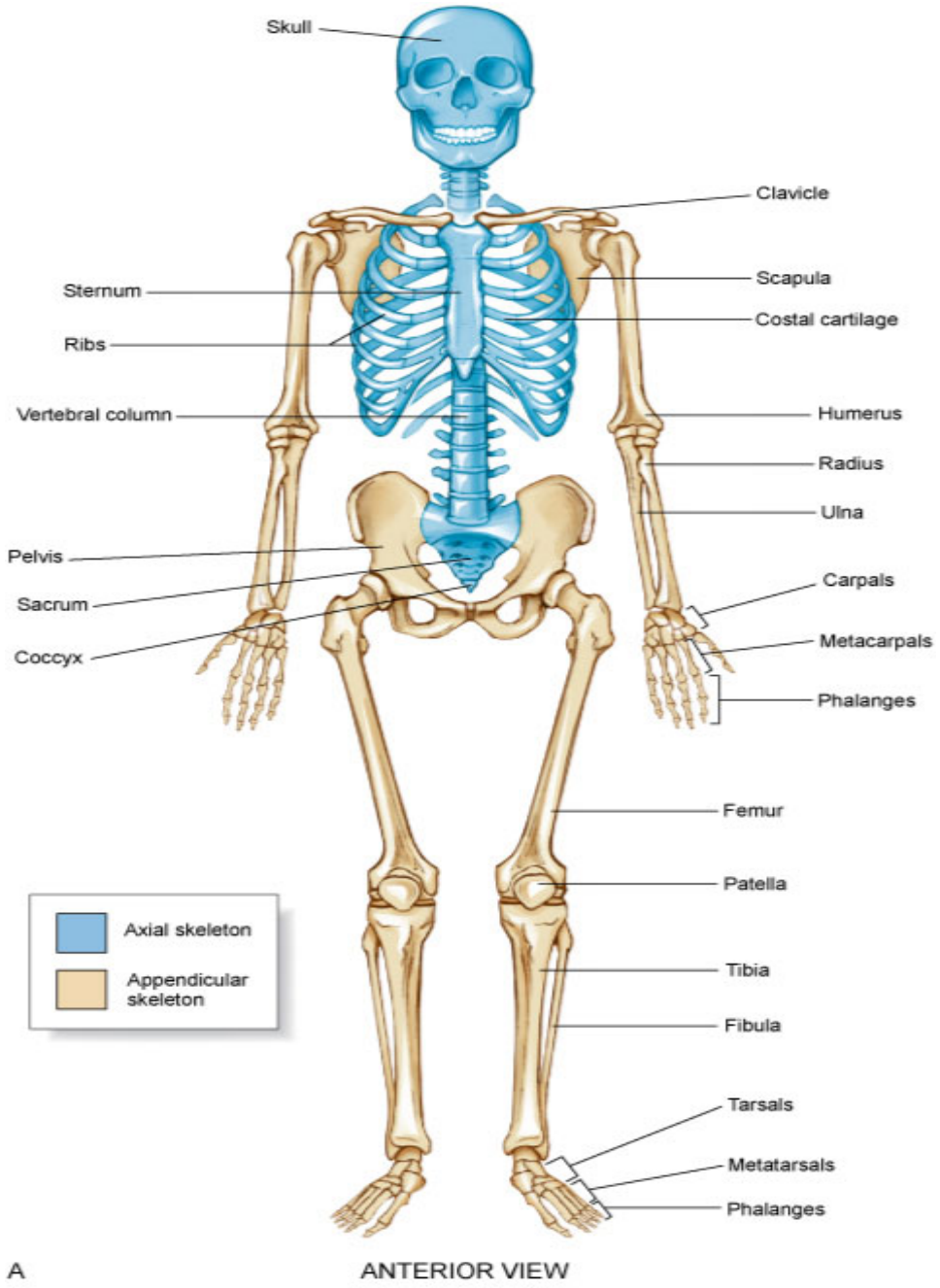
Skull
Clavicle
Sternum
Scapula
Costal cartilage
Ribs
Vertebral column
Humerus
Radius
Ulna
Pelvis
Carpals
Sacrum
Metacarpals
Coccyx
Phalanges
Femur
Patella
Axial skeleton
Appendicular skeleton
Tibia
Fibula
Tarsals
Metatarsals
Phalanges
A
ANTERIOR VIEW



Trail Guide, Page 61

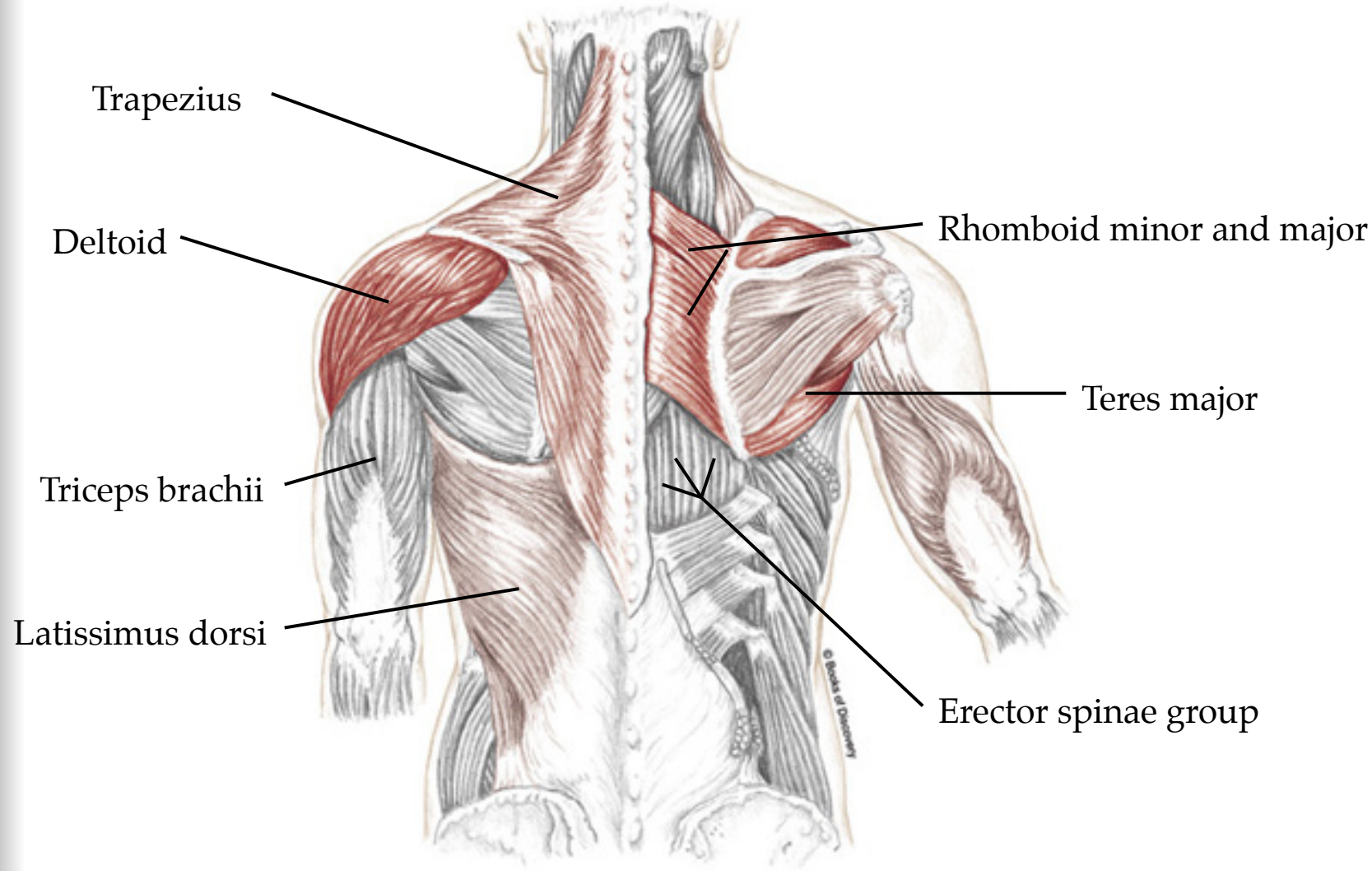

Posterior View

Trail Guide, Page 297

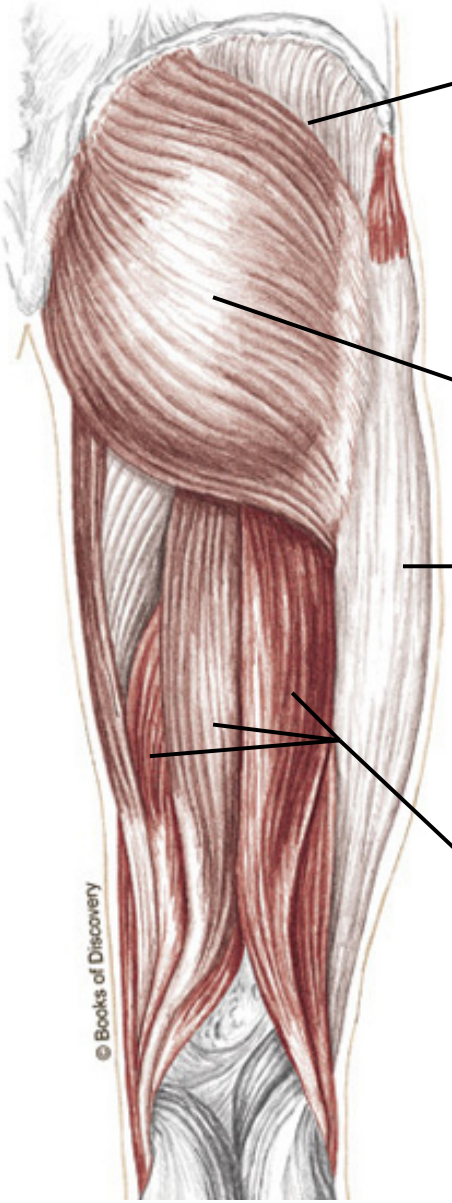

Gluteus medius
(and gluteus minimus deep to it!)

Gluteus maximus

Iliotibial tract
(NOT A MUSCLE)

Hamstrings

Posterior View

Trail Guide, Page 366

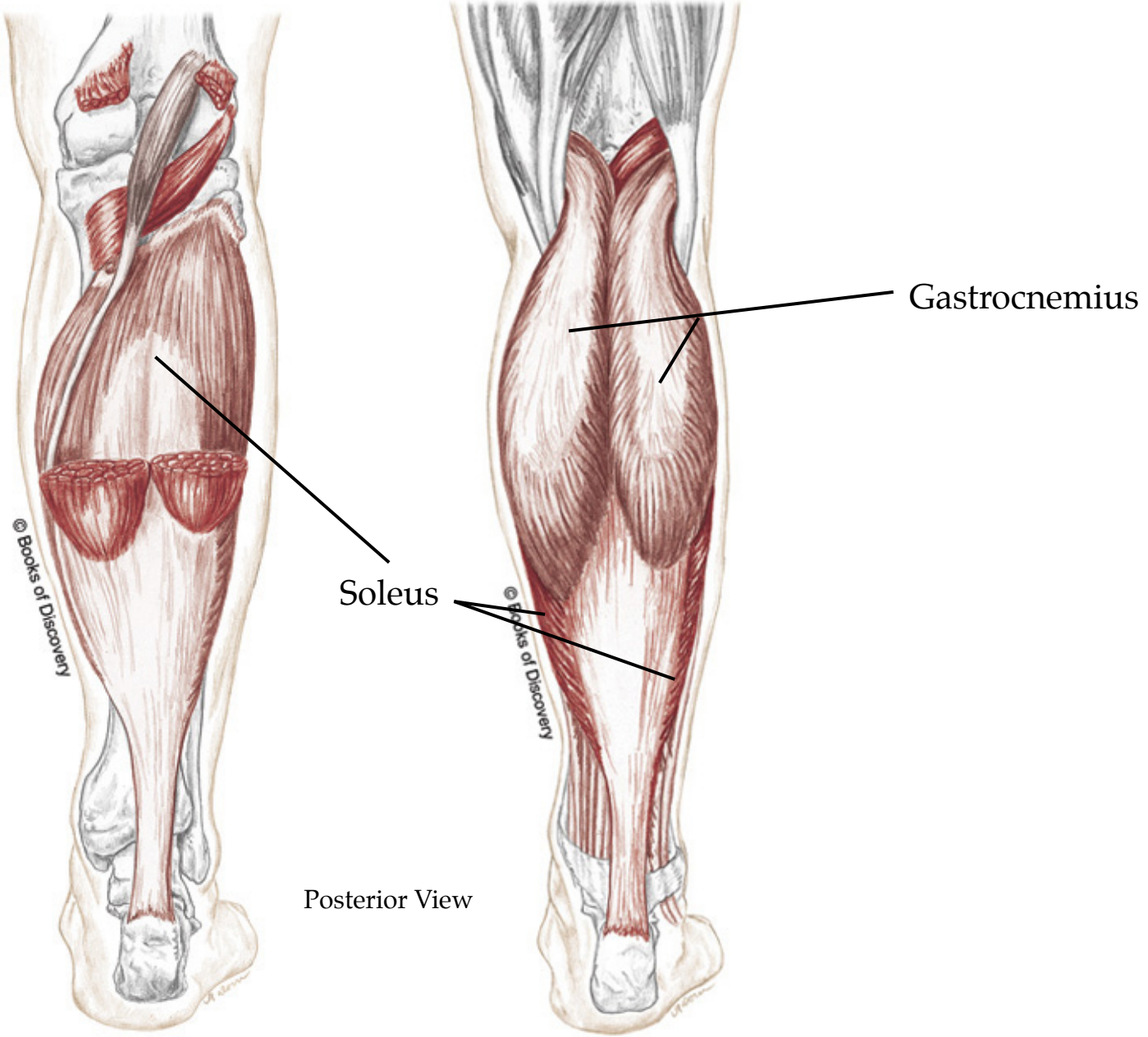

Posterior View

Trail Guide, Page 36

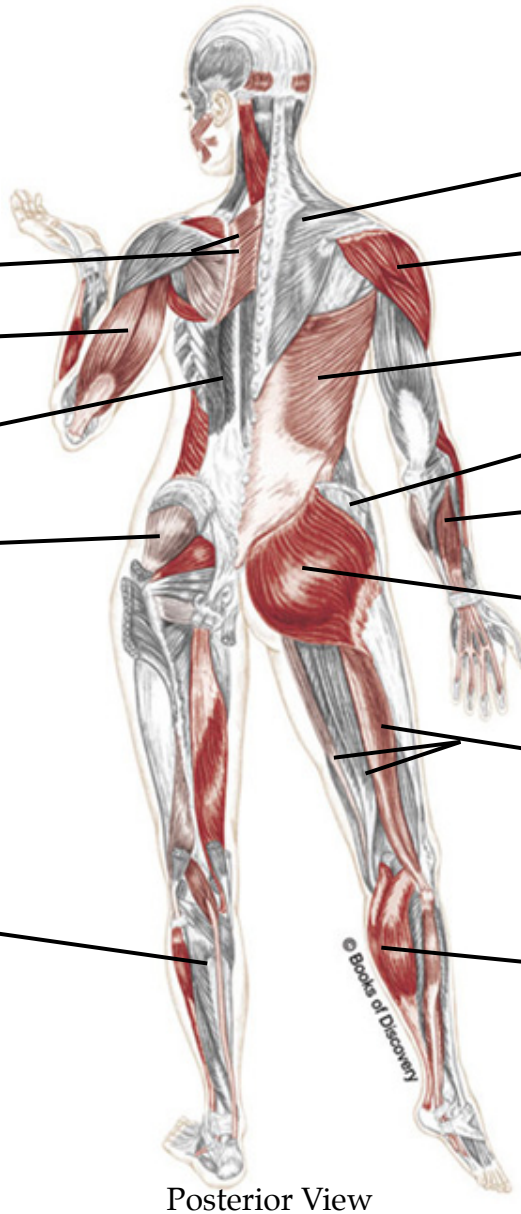

Posterior View

Trapezius

Deltoid

Rhomboid minor and major

Triceps brachii

Latissimus dorsi

Gluteus medius

Erector spinae group

Wrist and finger extensors

Gluteus minimus
(note: this is mislabeled
in your Trail Guide

Gluteus maximus

Hamstrings

Soleus

Gastrocnemius

Active Study Skills

Engage in active studying of this new material using:

- Trail Guide (pages 36, 61, 297, 366, and any others that help you)
- Your body (link the muscles in the book with those on your body)
- Movement (touch the muscle as you contract it and say its name out loud)
- Drawings (draw the basic shapes of the muscles and label them)
- Drilling (with a partner, name or write the muscle as they point at it
- Writing (write the names of all of the muscles)
- Speaking (name all of the muscles)

Review

Write the name of the muscle for each number

Trail Guide, Page 61

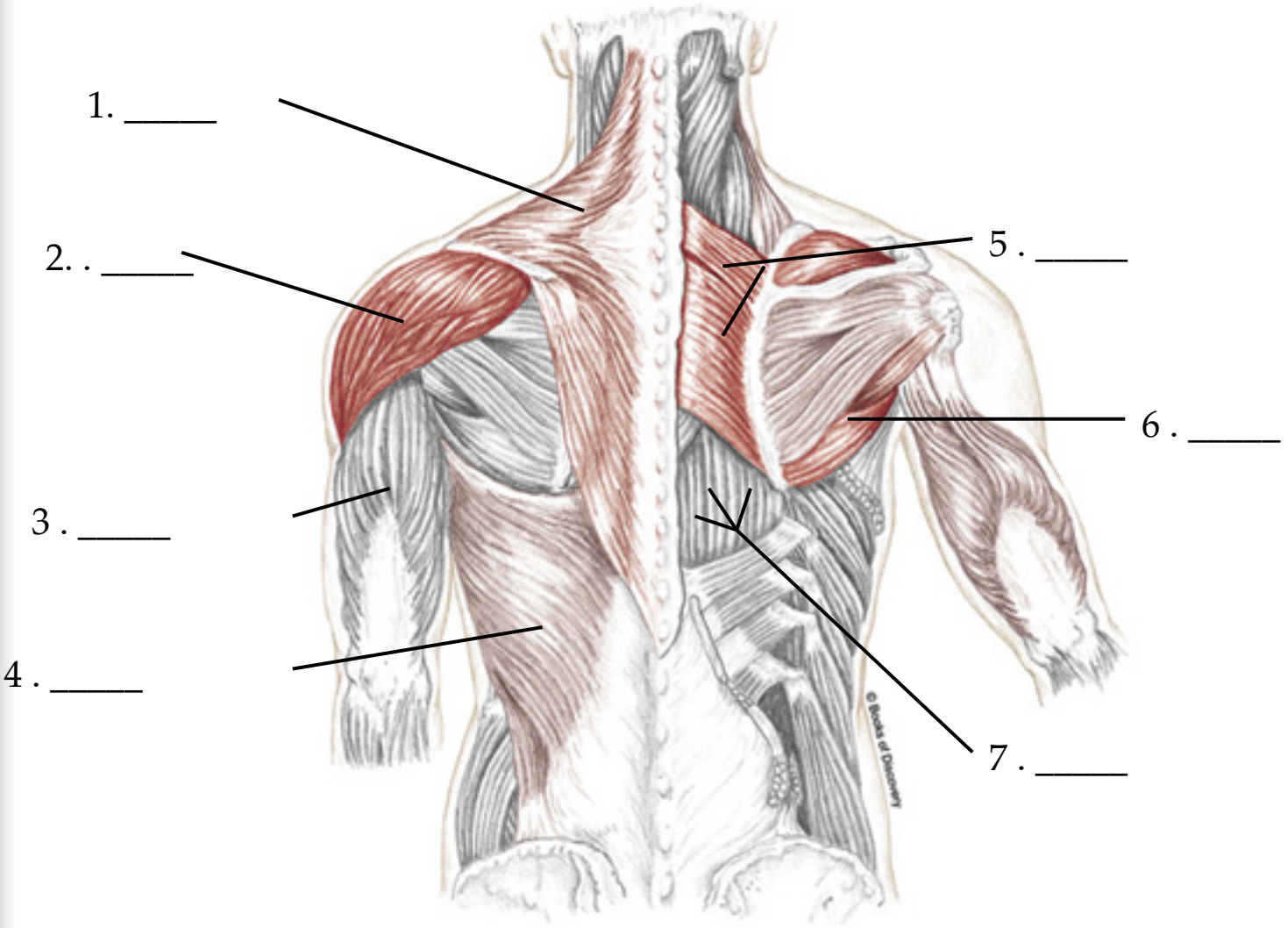

Posterior View

Trail Guide, Page 297

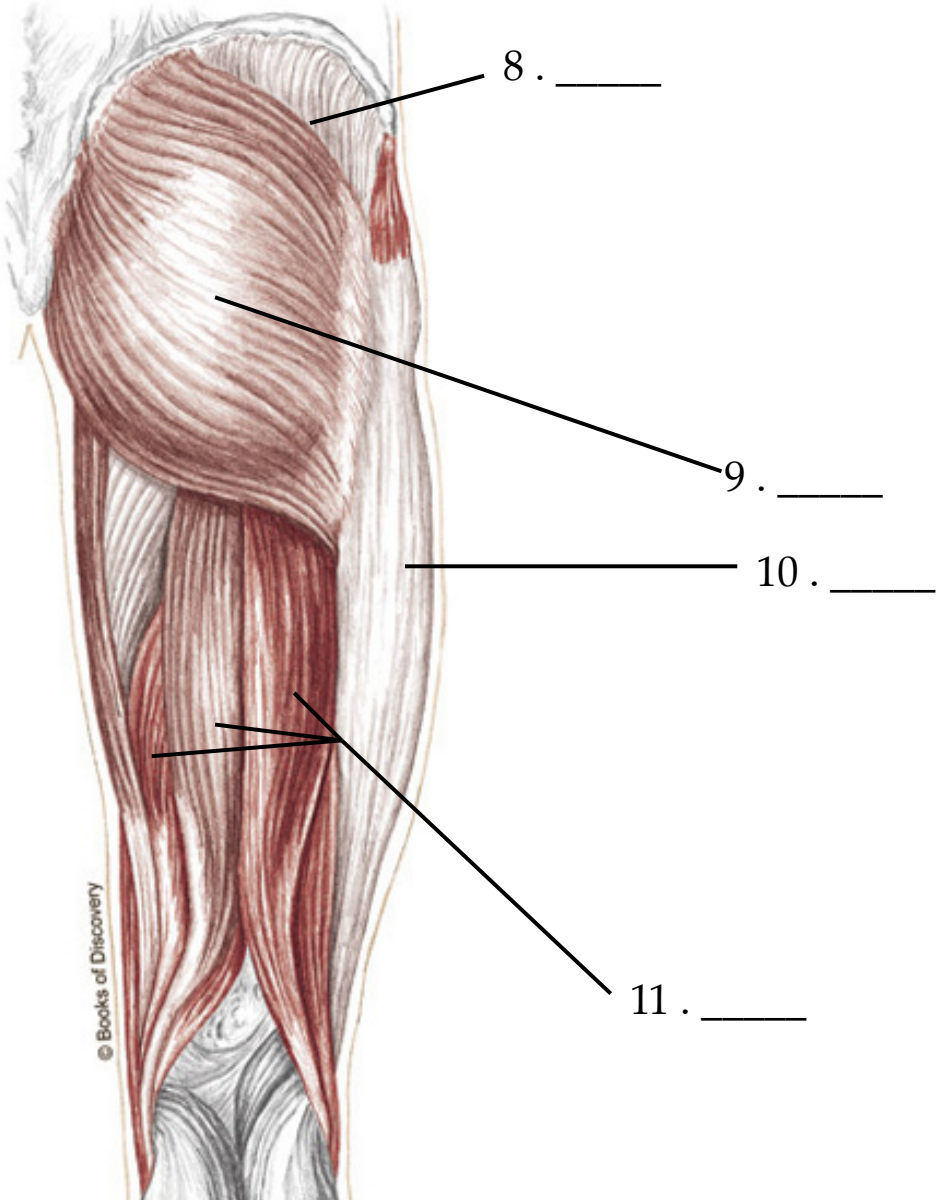

Posterior View

Trail Guide, Page 366

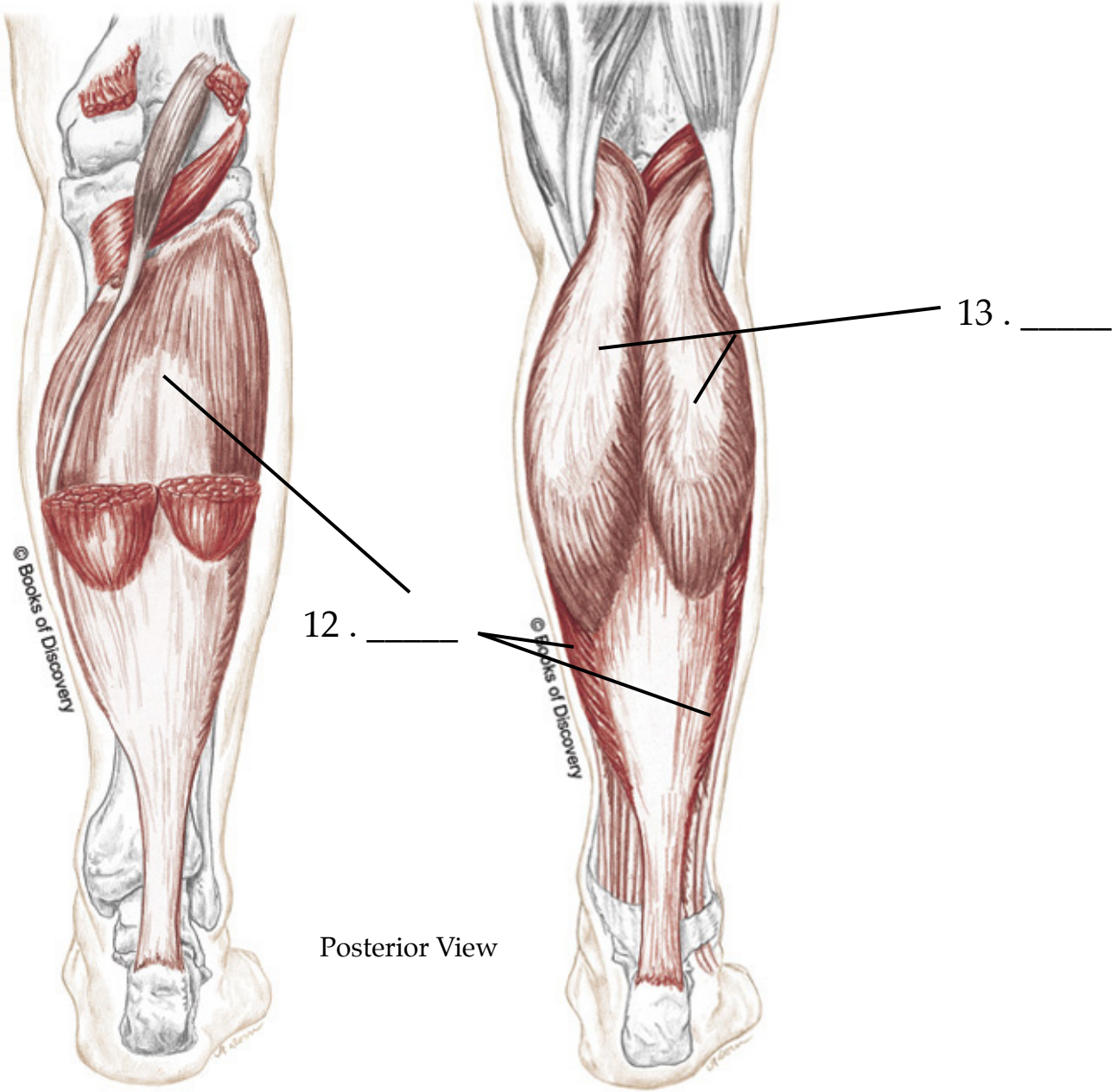

Posterior View

Check your answers



Trail Guide, Page 61

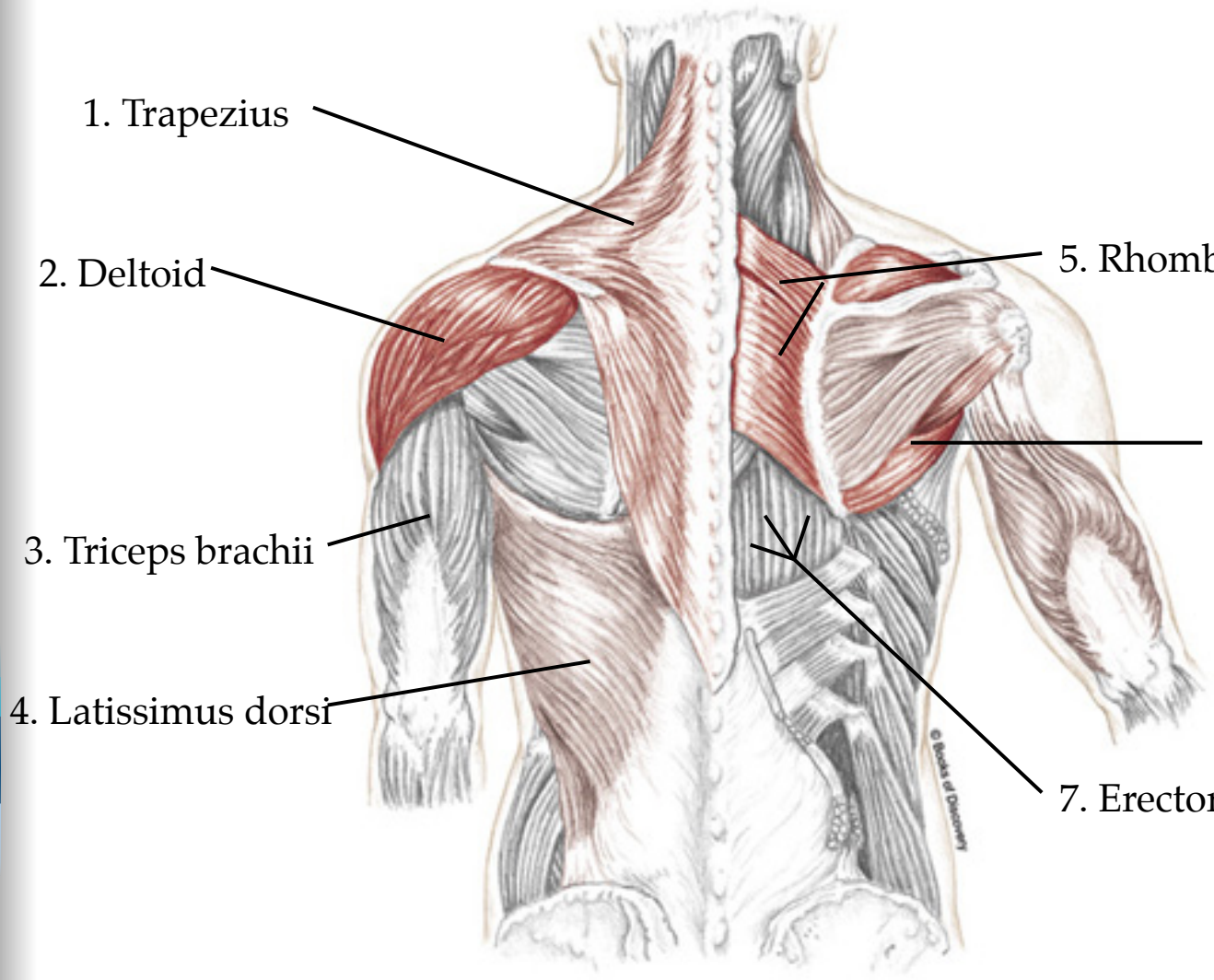

Posterior View

Trail Guide, Page 297

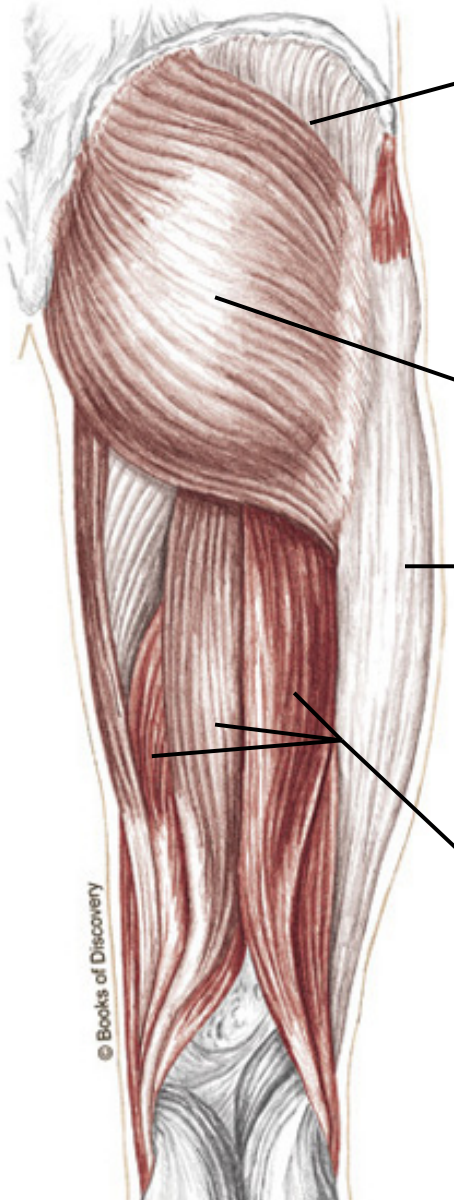

8. Gluteus medius
(and gluteus minimus deep to it!)

9. Gluteus maximus

10. Iliotibial tract
(NOT A MUSCLE)

11. Hamstrings

Posterior View

Trail Guide, Page 366

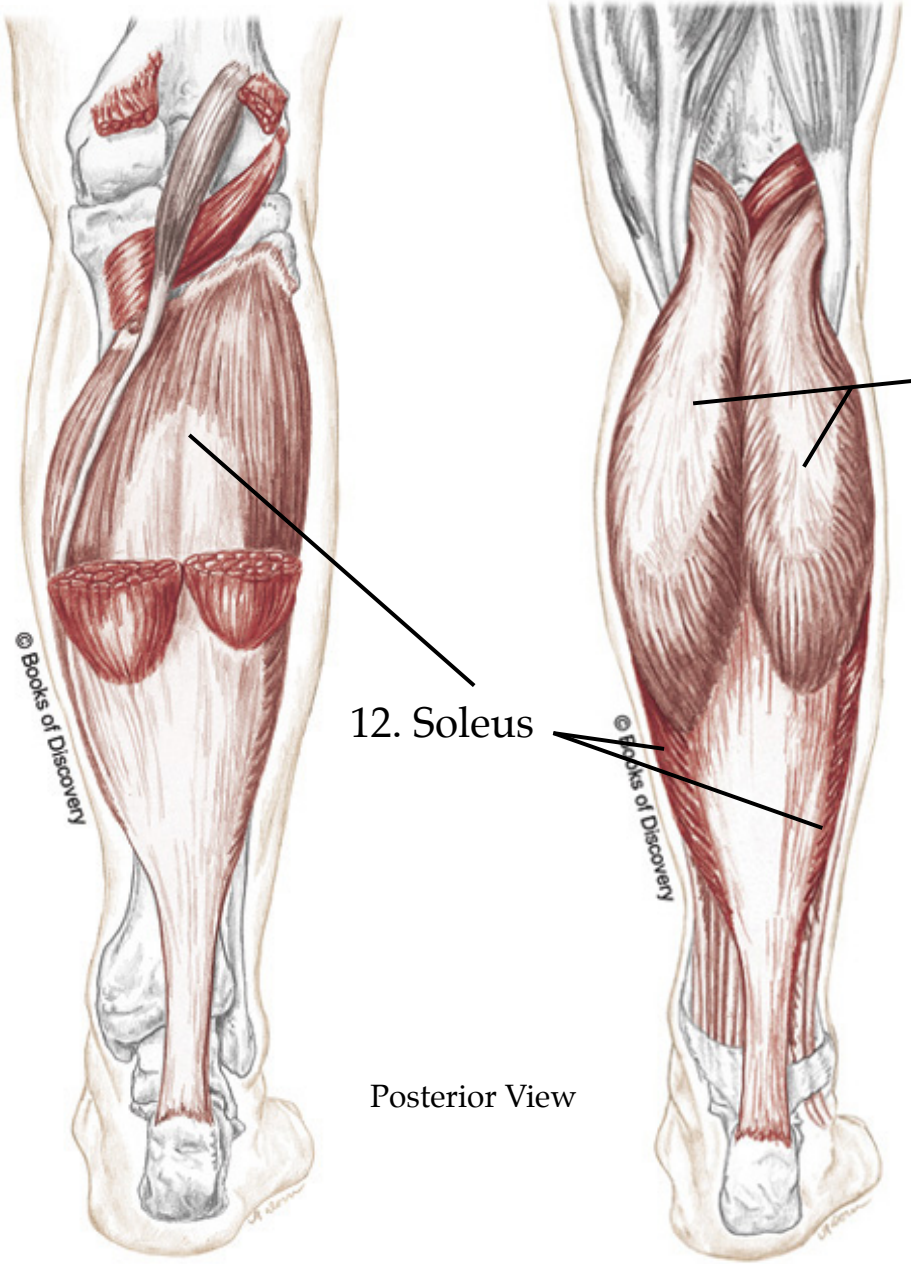

13. Gastrocnemius

12. Soleus

Posterior View

Trail Guide, Page 36

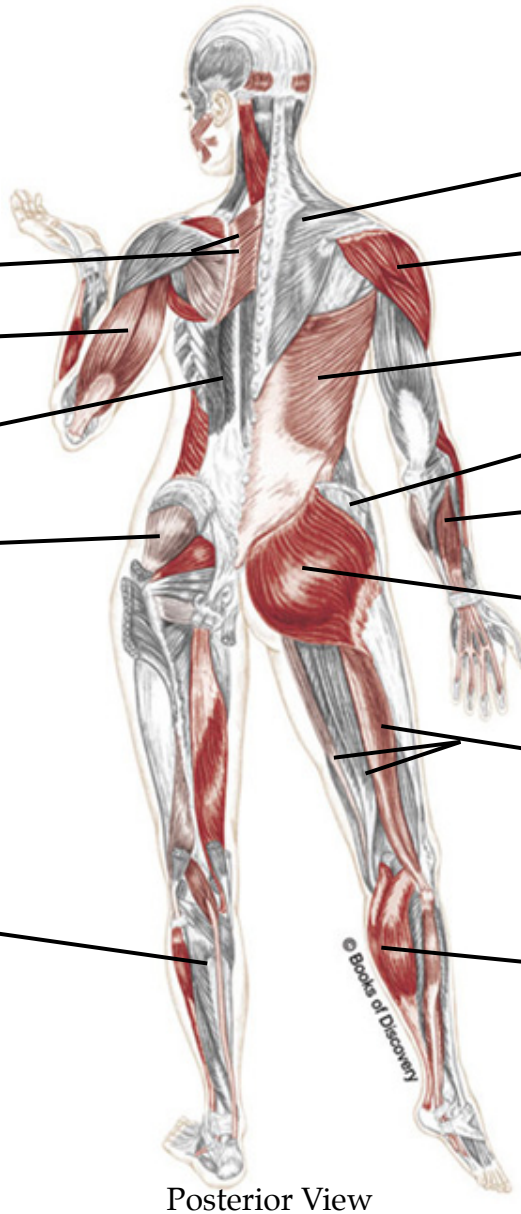

Posterior View

Trapezius

Deltoid

Rhomboid minor and major

Triceps brachii

Latissimus dorsi

Gluteus medius

Erector spinae group

Wrist and finger extensors

Gluteus minimus
(note: this is mislabeled
in your Trail Guide

Gluteus maximus

Hamstrings

Soleus

Gastrocnemius

2a Kinesiology:
Names and Locations of Bones and Posterior Muscles