



## 13b Kinesiology: AOIs - Anterior Lower Body and Upper Torso



## 13b Kinesiology: AOIs - Anterior Lower Body and Upper Torso

10 minutes	<b>Break</b> Announce the return time and write it on the board.
5 minutes	<b>Attendance</b> Also project the “Class Reminders” slide.
20 minutes	<b>Cadaver Video:</b> Acland’s DVD Atlas of Human Anatomy
55 minutes	<b>Anatomy in Clay</b>
20 minutes	<b>Break</b> Announce the return time and write it on the board.
30 minutes	<b>13b Kinesiology Quiz</b>
60 minutes	<b>Palpation</b>
<u>10 minutes</u>	<u><b>Break down, clean up, and circle up</b></u>
3h 30m	<b>Total Class Time</b>



# 13b Kinesiology: AOIs - Anterior Lower Body and Upper Torso

## **Assignments:**

- 17a Review Questions (A: 131-140)

## **Quizzes and Exams:**

- 13b Kinesiology Quiz **NOW!**
- 17b Kinesiology Quiz
- 17a Quiz
- 19a Quiz
  
- 21a Exam

## **Preparation for upcoming classes:**

- 14a 14a H&H: Compassionate Care for All People
  - Trail Guide: biceps brachii and coracobrachialis
  - Packet H: 55-64
  
- 14b Swedish: Technique Review and Practice - Feet, Anterior Lower Body, and Abs
  - Packet F: 45-46, and 58



# Classmarker

## Grading your Quiz/Exam

- Classmarker will automatically grade your assignment and email you a copy of your completed test.
- Retakes. If you did not pass a test you may reserve space in the make-up room. If you are not making up hours, your time there will be at no cost. Retakes may be done at anytime before a student graduates. You may retake it for a grade up to a 70. These are done on paper copies.
- Please refer to your assignment grid on pages A: 29-32.



# Cadaver Video

- [Tibialis Anterior](#)
- [Peroneals / Fibularis \(longus, brevis, and tertius\)](#)
- [Quads](#)
- [Abdominals](#)
- [Pectoralis Major](#)



# Anatomy in Clay

Write this list on the board and turn the projector off for now:

- Tibialis anterior
- Fibularis longus
- Fibularis brevis
- Rectus femoris
- Vastus lateralis
- Vastus medialis
- Vastus intermedius
- Rectus abdominis
- Pectoralis major



# Palpation

## Set Up by the Students

- Students form groups of 3.
- Each group sets up a table and gets 1 face cradle, 1 bolster, and 2 chairs.
- Receivers must remain clothed.
- There will be no need of sheets except for a face cradle cover.

## Demo and Practice

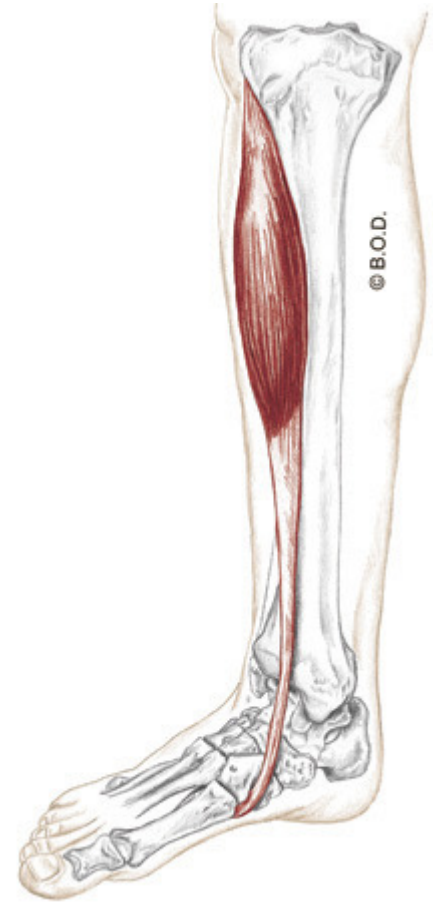
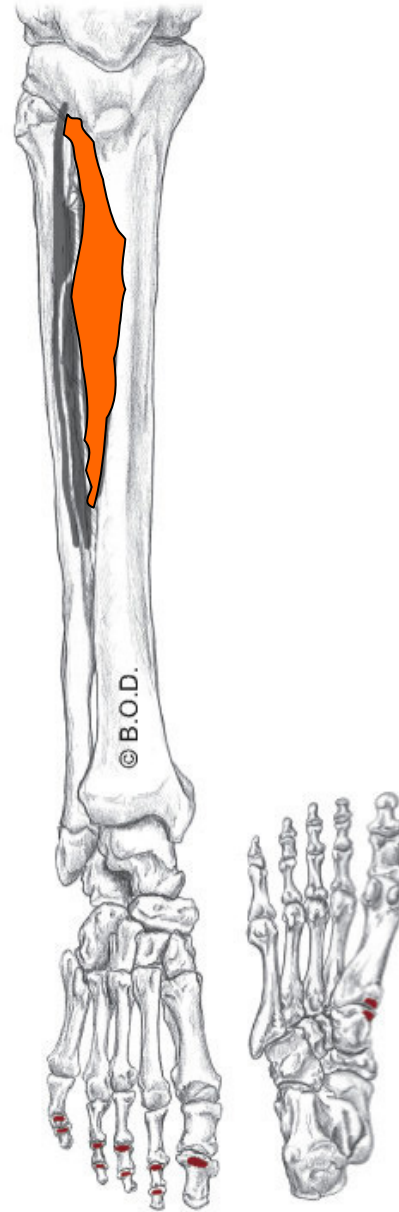
- All of the students come to a central table to watch a brief demonstration of how to palpate one of the focus muscles:
  - List and identify the bony landmarks, especially origins and insertions.
  - List and identify the muscle bellies and tendons.
  - List and explain the actions.
  - Demo how to palpate the muscle while simultaneously offer resistance to the action, “Contract, relax. Contract, relax.”
  - The students go back to their table to practice the palpation.
  - 2 students palpate the third student collaboratively.
  - The instructor and assistant circulate to offer guidance and touch comparisons:
- This process repeats for each muscle that will be palpated.
- Once all the focus muscles have been palpated on the first student, repeat the process so that each student will palpate twice and be palpated once.

# Tibialis Anterior, page 379

**A** **Invert** the foot  
**Dorsiflex** the ankle (talocrural joint)

**O** Lateral condyles of tibia  
Proximal, lateral surface of tibia  
Interosseous membrane

**I** Medial cuneiform  
Base of the first metatarsal



Anteromedial View

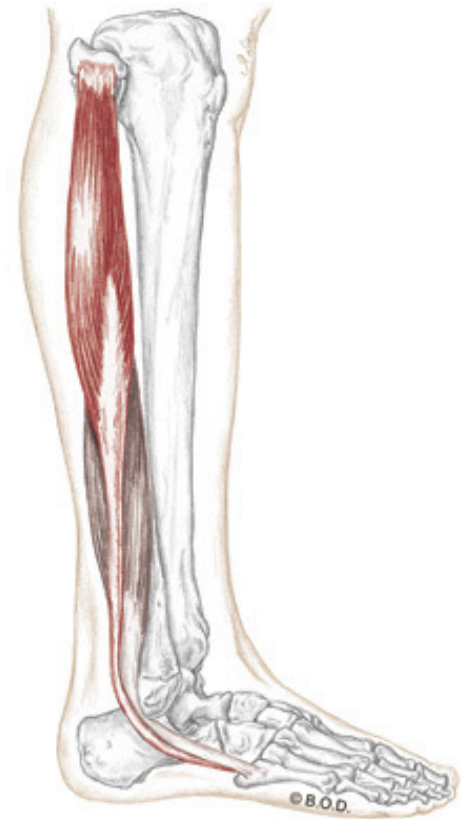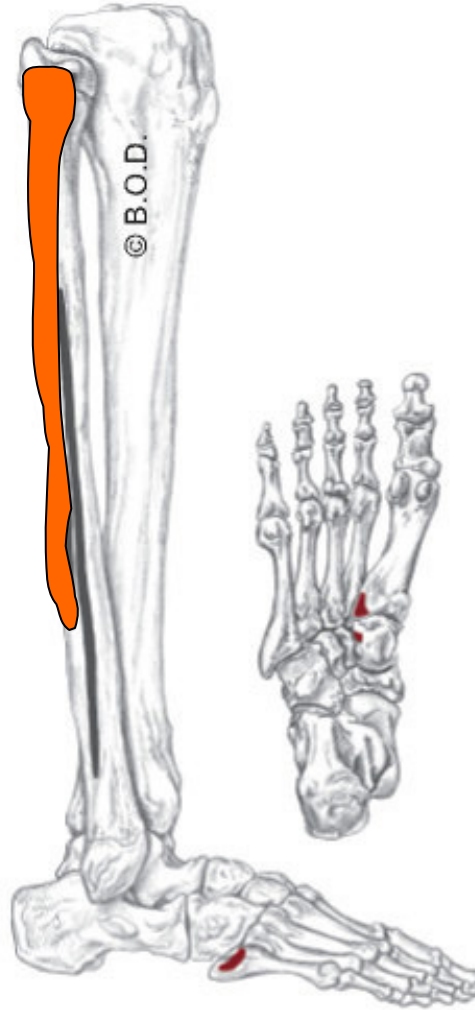


# Fibularis Longus, page 376

**A** **Evert** the foot  
Assist to **plantar flex** the ankle (talocrural joint)

**O** Head of fibula  
Proximal two-thirds of lateral fibula

**I** Medial cuneiform  
Base of the first metatarsal



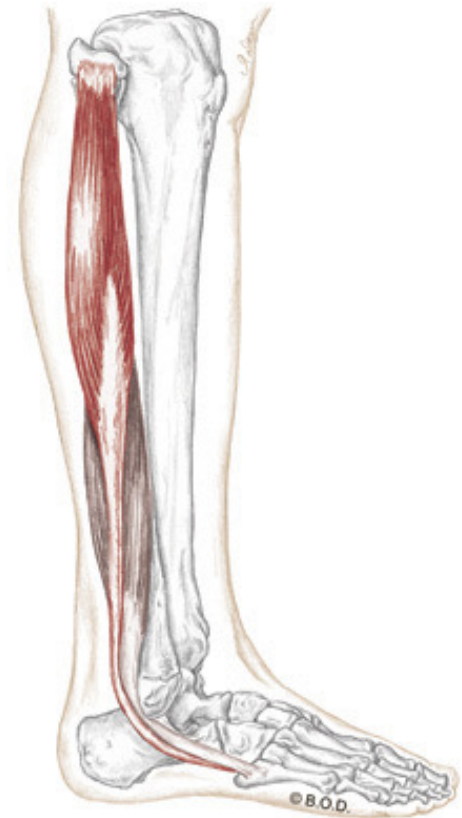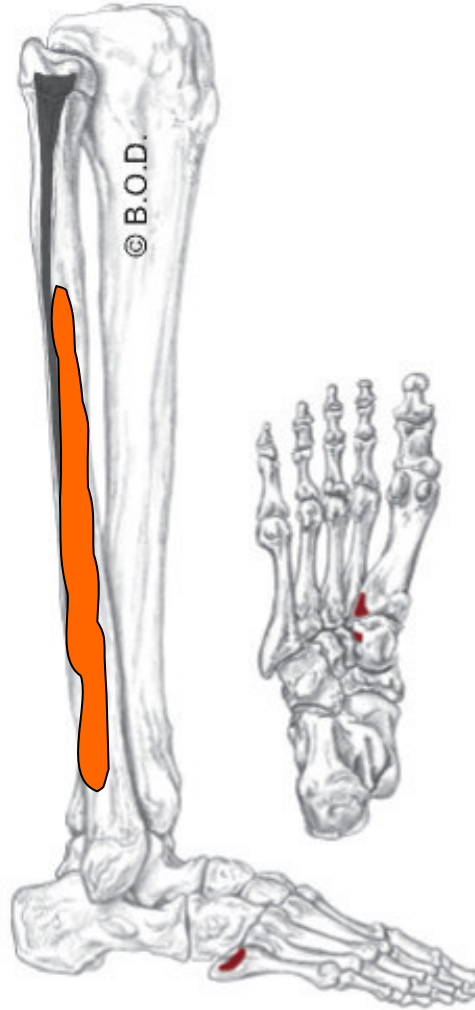
Anteromedial View

# Fibularis Brevis, page 376

**A** **Evert** the foot  
Assist to **plantar flex** the ankle (talocrural joint)

**O** Distal two-thirds of lateral fibula

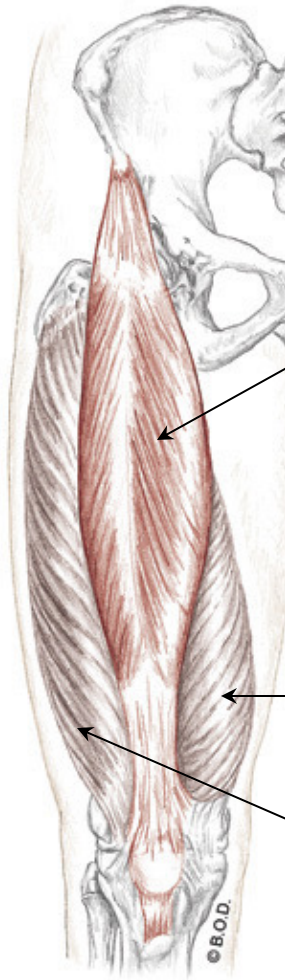
**I** Tuberosity of the fifth metatarsal



Anteromedial View

# Quadriceps Femoris

## Trail Guide, Page 306



Anterior View

The **quads** primarily extend the tibiofemoral joint.

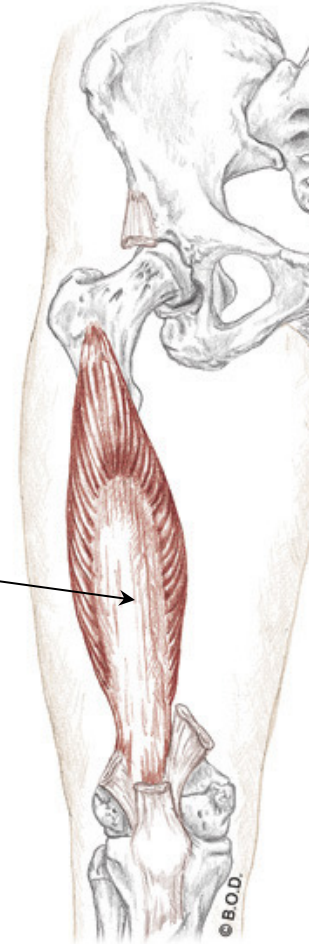
**Rectus femoris** is cylindrical, superficial, and the only quadricep muscle that also crosses the .

**Vastus intermedius** is deep to the rectus femoris.

**Vastus medialis** forms a teardrop shape at the distal portion of the medial thigh.

**Vastus lateralis** is the sole muscle of the lateral thigh.

When do you use trapezius?



Anterior View

# Rectus Abdominis, page 210

A

**Flex** the vertebral column

**Tilt** the pelvis posteriorly

O

Pubic crest

Pubic symphysis

I

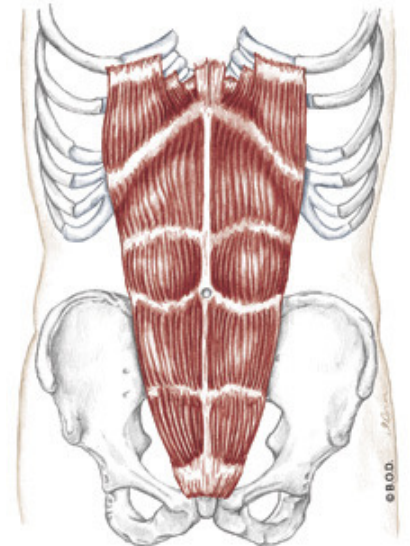
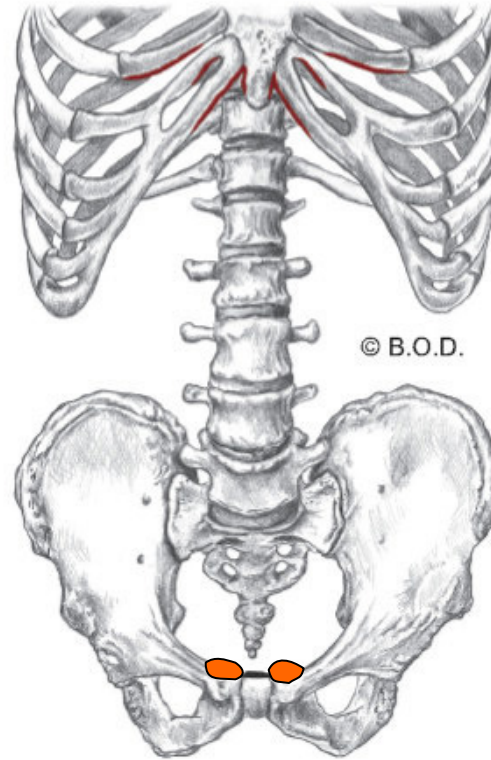
Cartilage of 5th, 6th, and 7th ribs

Xiphoid process

Ilium

Pubis

Ischium



Anterior View

# Pectoralis Major, page 89

**A** All fibers:

**Adduct** the glenohumeral joint

**Medially rotate** the glenohumeral joint

Assist to **elevate** the thorax during forced inhalation (with the arm fixed)

*Upper fibers:*

**Flex** the glenohumeral joint

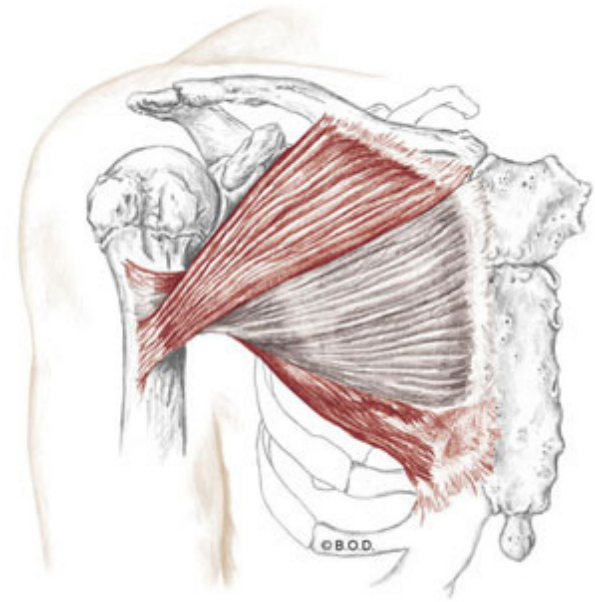
**Horizontally adduct** the glenohumeral joint

*Lower fibers:*

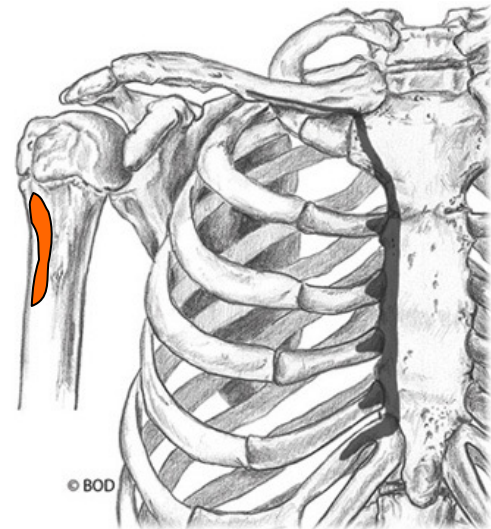
**Extend** the glenohumeral joint

**O** Medial half of the clavicle  
Sternum  
Cartilage of ribs 1-6

**I** Crest of greater tubercle of humerus



Anterior View





## 13b Kinesiology: AOIs - Posterior Lower Body