



## 29a Pathology - Integumentary System



## 29a Pathology - Integumentary System Class Outline

5 minutes	Attendance, Breath of Arrival, and Reminders
10 minutes	Lecture:
25 minutes	Lecture:
15 minutes	Active study skills:
60 minutes	Total

# 29a Pathology - Integumentary System

## Class Reminders

### Quizzes:

- 29b Kinesiology Quiz **TODAY!!!**
  - Supraspinatus, infraspinatus, teres minor, subscapularis, pec minor, & serratus anterior
- 31a Quiz (20a, 20b, 21b, 22a, 23a, 24b, 29b, and 30a)
- 32a Quiz (24a, 25a, 26a, 27a, 28a, 29a, 30b, and 31b)

### Assignments:

- 30a Review Questions
  - Packet A: 141-158

### Exams:

- 34a Exam  
(1b, 2a, 2b, 3a, 3b, 4a, 5a, 6a, 7a, 8b, 9a, 9b, 11a, 12a, 13a, 13b, 15a, 16a, 17a, 17b, 18a, 20a, 20b, 21b, 22a, 23a, 24a, 24b, 25a, 26a, 27a, 28a, 29a, 30a, 30b, and 31b)

### Preparation for upcoming classes:

- 30a Kinesiology: Synergists - Glenohumeral and Scapulothoracic Joints
  - Trail Guide: Pages 63-66
  - RQ Packet A: 155-156
- 30b Passive Stretches: Technique Demo and Practice - Upper Body
  - Packet F: 65-70
  - RQ Packet A-157
- 33b Chair Massage: This class cannot be made up in the make-up room. To schedule a sit-in, please contact the Student Administrator.



# Classroom Rules

**Punctuality** - everybody's time is precious

- Be ready to learn at the start of class; we'll have you out of here on time
- Tardiness: arriving late, returning late after breaks, leaving during class, leaving early

**The following are not allowed:**

- Bare feet
- Side talking
- Lying down
- Inappropriate clothing
- Food or drink except water
- Phones that are visible in the classroom, bathrooms, or internship

*You will receive one verbal warning, then you'll have to leave the room.*



## 29a Pathology - Integumentary System

E - 59



# Lesions

**Lesion** Wound or injury. Pathogenic change in tissues.

“If the skin is not intact, the client is susceptible to infection.”



## Common Skin Lesions

**Laceration** Rip or tear.

**Incision** Cut.

**Excoriation** Scratch.

**Papule** Firm raised areas, like pimples.

**Vesicle** Blister.

**Pustule** Vesicle filled with pus, like a whitehead.

**Puncture** Hole.

**Avulsion** Something that has been ripped off.

**Abrasion** Scrape.

**Ulcer** Sore with dead tissue. Doesn't go through a normal healing process.



## Contagious Skin Disorders

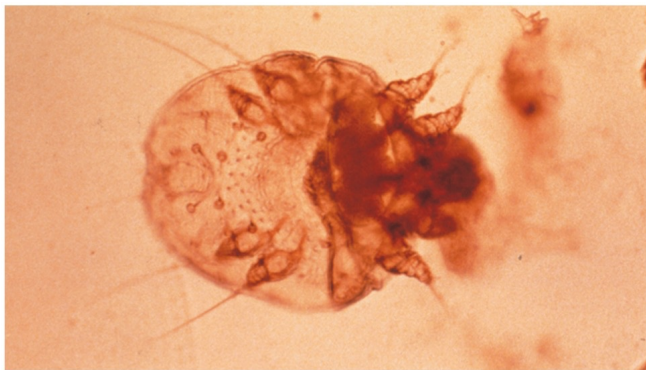
**Animal parasite** Animal that lives in/on humans or their clothing, and draws nutrients from a host. All types contraindicate massage.

- Mites
- Head lice
- Body lice
- Pubic lice
- Pediculosis

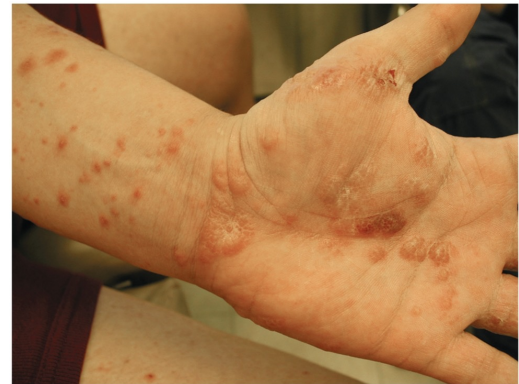

# Contagious Skin Disorders

- **Mites** Cause skin lesions called scabies. Prefer warm, moist places such as the axillae or between fingers. Leave itchy trails or nodules where they burrow under the skin.



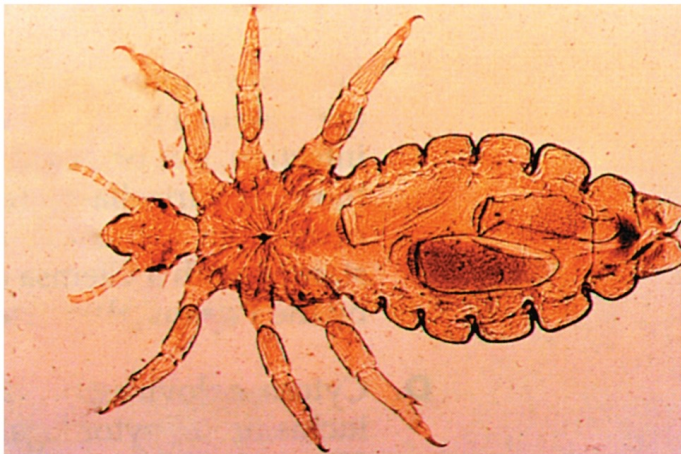
Copyright © 2013 Wolters Kluwer Health | Lippincott Williams & Wilkins



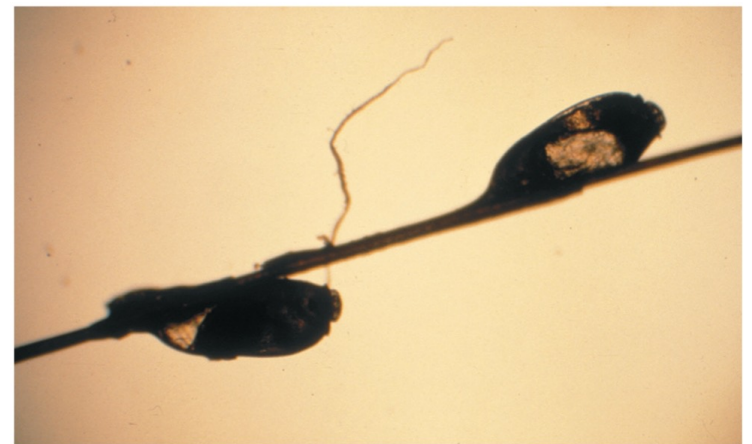Copyright © 2013 Wolters Kluwer Health | Lippincott Williams & Wilkins

# Contagious Skin Disorders

**Head lice** Wingless insects that live in head hair and suck blood from the scalp.



Copyright © 2013 Wolters Kluwer Health | Lippincott Williams & Wilkins



Copyright © 2013 Wolters Kluwer Health | Lippincott Williams & Wilkins




# Contagious Skin Disorders

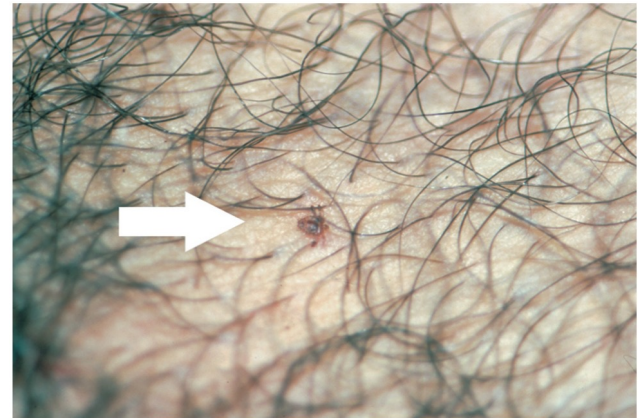
**Body lice** Wingless insects that live in the seams of host's clothing.

# Contagious Skin Disorders

**Pubic lice** Tiny crab-like insects that live in pubic and armpit hair, mustaches, beards, eyebrows, and eyelashes.



Copyright © 2013 Wolters Kluwer Health | Lippincott Williams & Wilkins



Copyright © 2013 Wolters Kluwer Health | Lippincott Williams & Wilkins



# Contagious Skin Disorders

**Pediculosis** Infestation of lice.

Lice is plural.

Louse is singular.

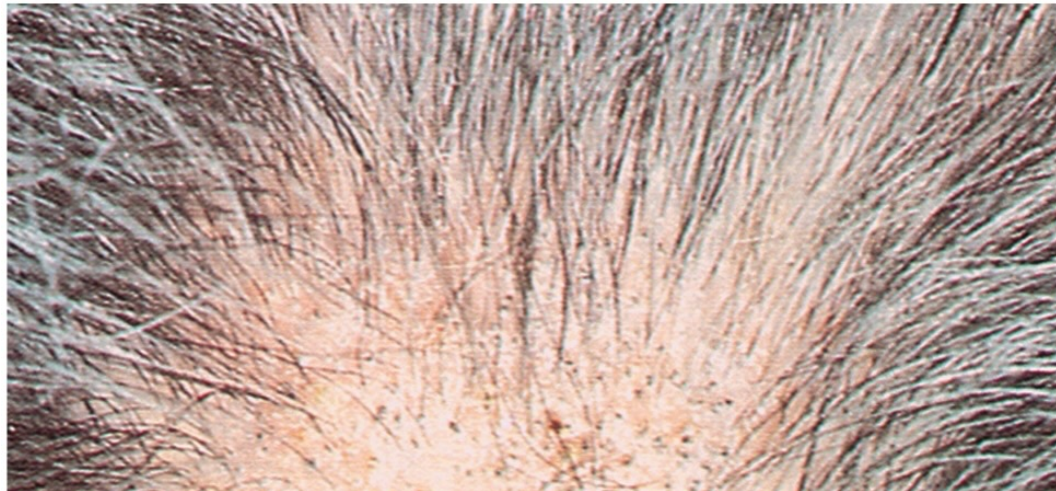


## Contagious Skin Disorders

**Mycoses (AKA: dermatophytoses)** Fungal infections of human skin caused by several different types of fungi called dermatophytes. Result in lesions called tinea. Locally contraindicates massage.

# Contagious Skin Disorders

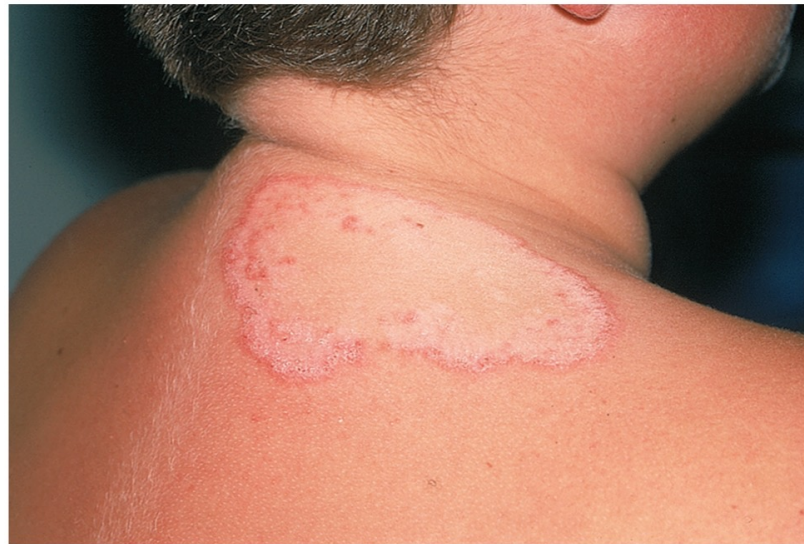- **Tinea capitis** Fungal infection of the scalp.





# Contagious Skin Disorders

- **Tinea corporis (AKA: body ringworm)** Fungal infection that typically develops on the trunk or extremities as red circles or rings.

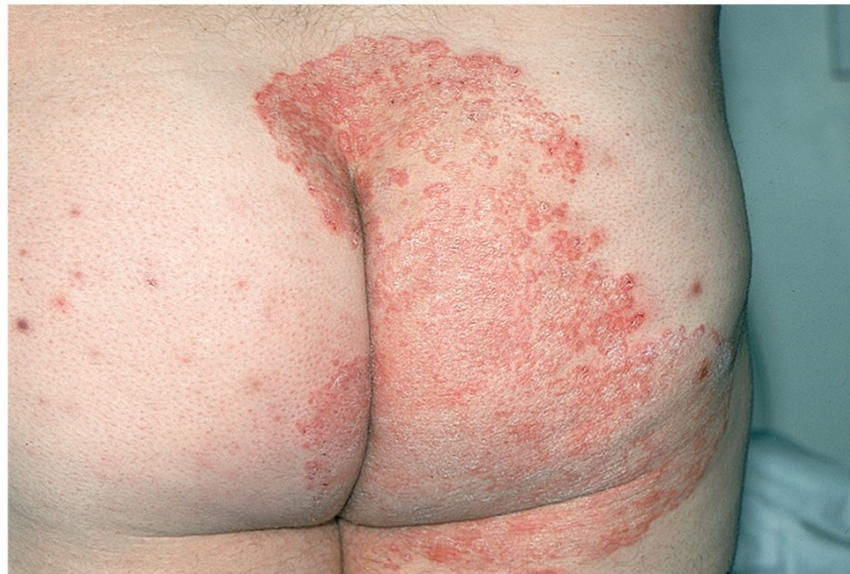

Copyright © 2013 Wolters Kluwer Health | Lippincott Williams & Wilkins



# Contagious Skin Disorders

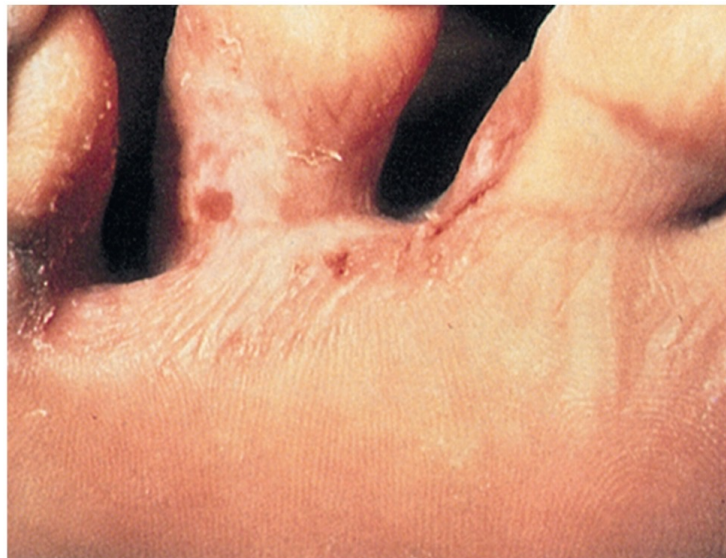- **Tinea cruris (AKA: jock itch)** Fungal infection of the groin area.



Copyright © 2013 Wolters Kluwer Health | Lippincott Williams & Wilkins

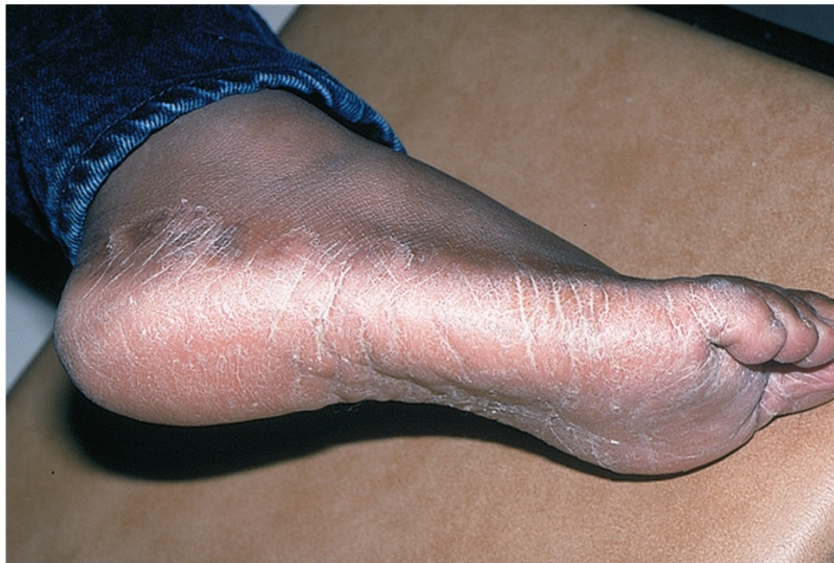# Contagious Skin Disorders

- **Tinea pedis (AKA: athlete's foot)** Fungal infection of the feet.  
(between the toes)



# Contagious Skin Disorders

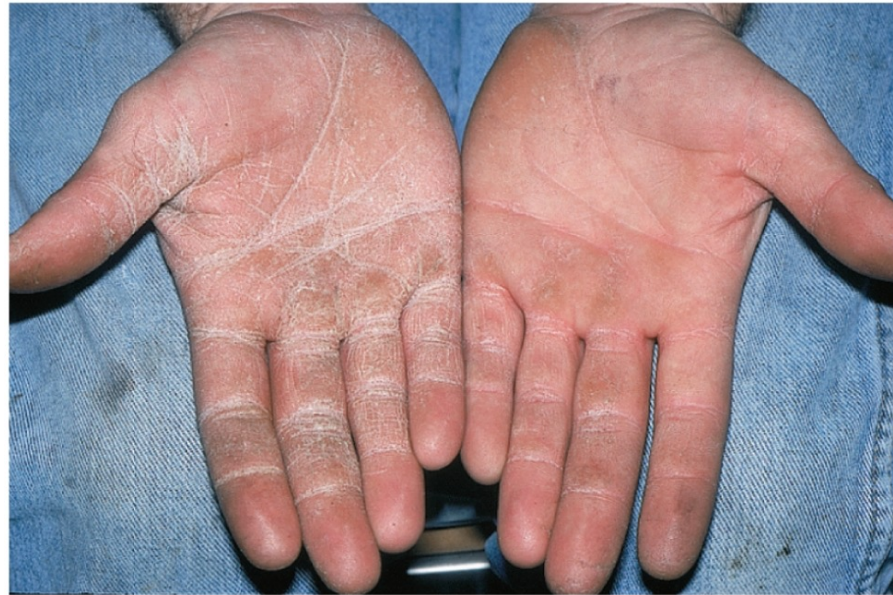- **Tinea pedis (AKA: athlete's foot)** Fungal infection of the feet.  
(moccasin distribution)



Copyright © 2013 Wolters Kluwer Health | Lippincott Williams & Wilkins

# Contagious Skin Disorders

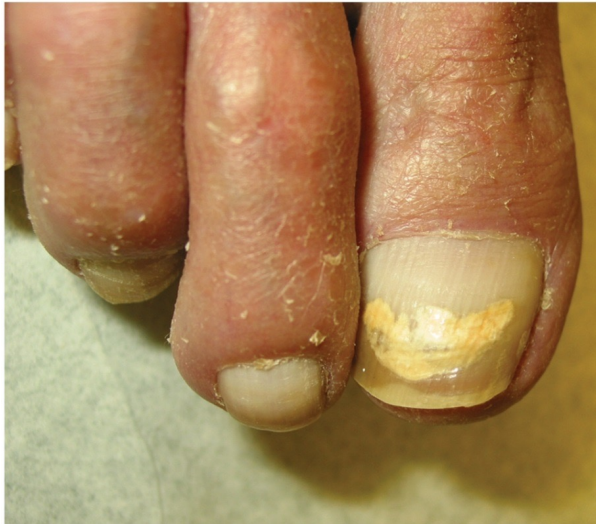- **Tinea manuum** Fungal infection of the hands.



Copyright © 2013 Wolters Kluwer Health | Lippincott Williams & Wilkins

# Contagious Skin Disorders

- **Onychomycosis (AKA: tinea unguium)** Fungal infection of the fingernails or toenails.



Copyright © 2013 Wolters Kluwer Health | Lippincott Williams & Wilkins



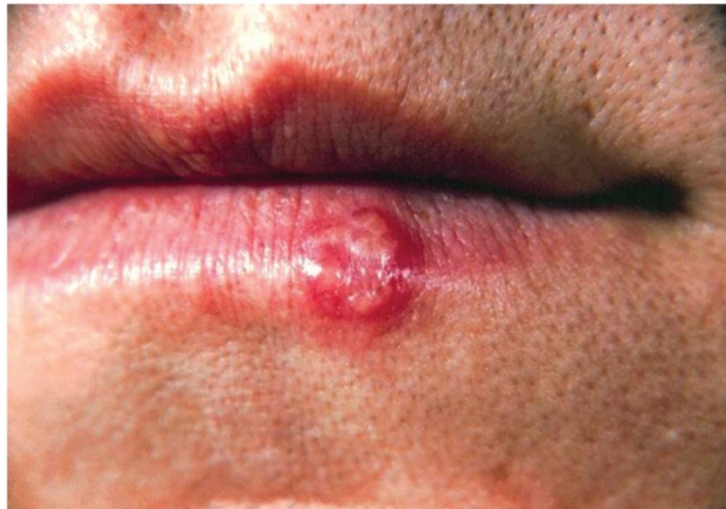## Contagious Skin Disorders

**Herpes simplex** Contagious viral infection resulting in painful blisters on a red base. Locally contraindicates massage during the acute stage.



# Contagious Skin Disorders

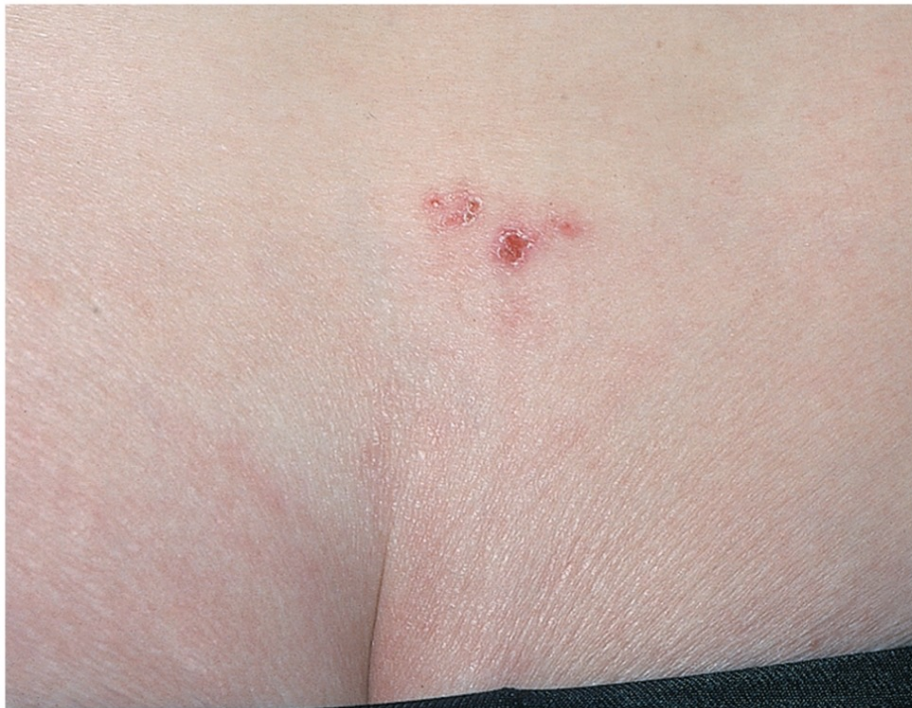- **Herpes simplex virus type 1 (AKA: HSV-1)** Viral infection associated with lesions around the mouth.



Copyright © 2013 Wolters Kluwer Health | Lippincott Williams & Wilkins

# Contagious Skin Disorders

- **Herpes simplex virus type 2 (AKA: HSV-2)** Viral infection associated with lesions in the genital area.





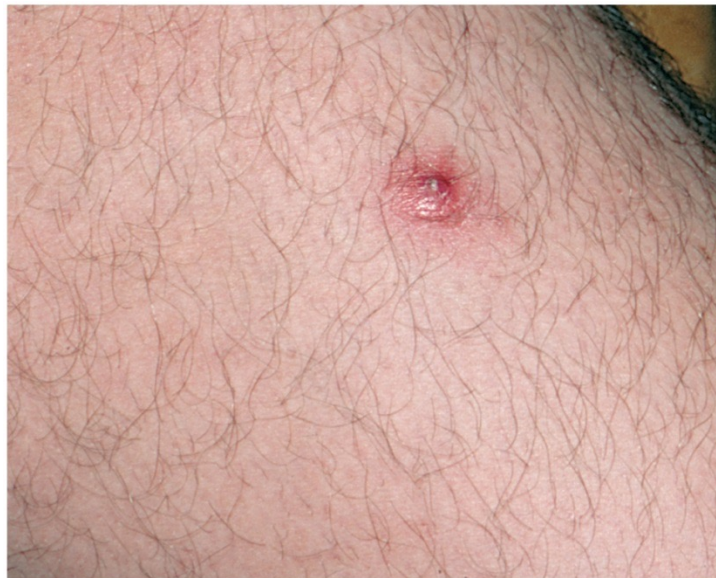

## Contagious Skin Disorders

**Staphylococcal infections (AKA: staph)** Variety of localized infections caused by a common group of bacteria that is known for colonizing human skin and nasal passages. Locally contraindicate massage.

# Contagious Skin Disorders

- **Boils (AKA: furuncles)** Local staph infection of the skin that occur one at a time. Has a lot in common with acne, but is a virulent and aggressive bacterium that actively attacks healthy tissue.



Copyright © 2013 Wolters Kluwer Health | Lippincott Williams & Wilkins

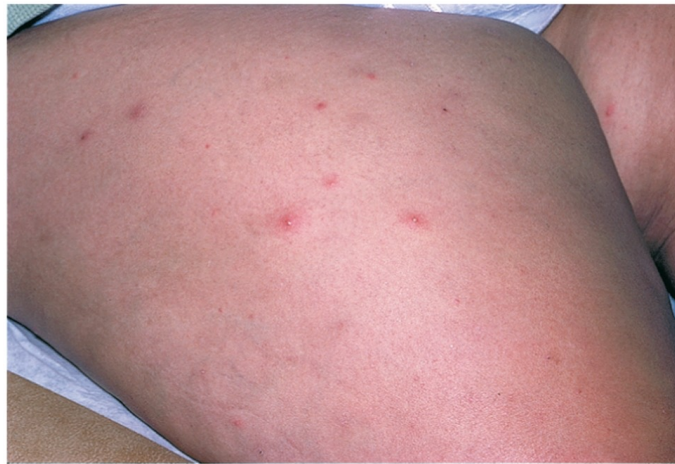

## Contagious Skin Disorders

- **Carbuncle** Group of boils connected by channels under the skin.
- **MRSA (AKA: methicillin-resistant staphylococcus aureus)**  
Group of infection-causing staph bacteria associated with healthcare facilities and high-density, low-hygiene settings.

# Contagious Skin Disorders

- **Folliculitis** Multiple boils in close proximity usually affecting hair follicles. Outbreak occurs in a predictable diamond-shaped pattern. Frequently accompanied by mild fever and headache.

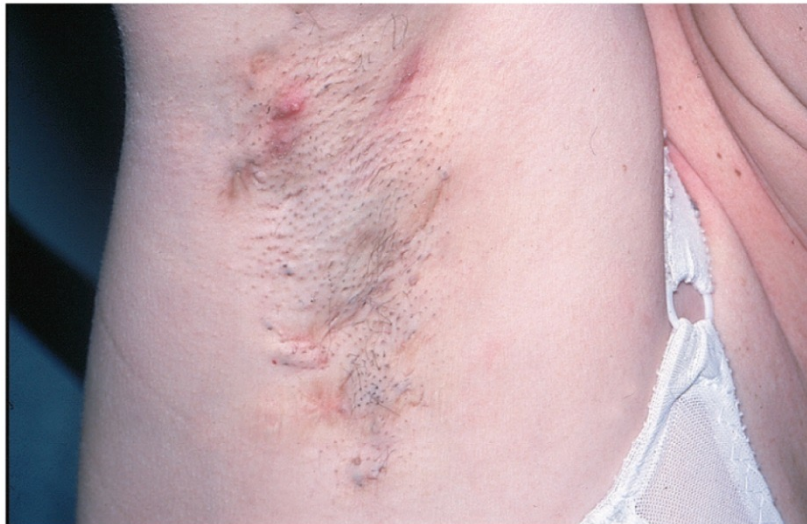


Copyright © 2013 Wolters Kluwer Health | Lippincott Williams & Wilkins

- **Sty** Version of folliculitis that affects hair follicles of an eyelash.

# Contagious Skin Disorders

- **Pilonidal cyst** Large staph infection within a cyst in the gluteal cleft.
- **Hidradentis suppurativa** Boils that occur in the axillae or groin



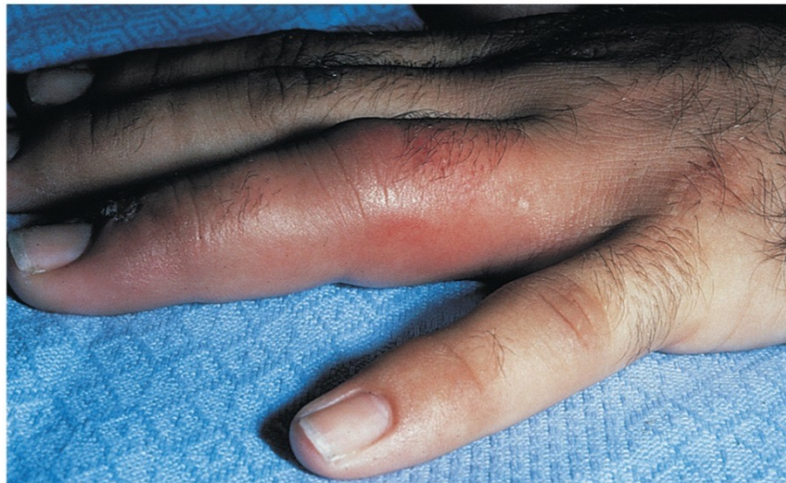

## Contagious Skin Disorders

**Streptococcal infections (AKA: strep)** Group of skin infections that involve one of the group A class of streptococcus bacteria. Absolutely contraindicates massage.

# Contagious Skin Disorders

**Cellulitis** Streptococcal infection of deep layers of the skin. It is a common complication of simple injuries such as a scraped knee or a contaminated blister from athlete's foot.



Copyright © 2013 Wolters Kluwer Health | Lippincott Williams & Wilkins



## Contagious Skin Disorders

- **Necrotizing fasciitis** Flesh-eating bacteria infection most commonly caused by streptococcus bacteria that can cause circulatory shock and death. Can progress from a minor skin wound to a life-threatening infection in a matter of hours.



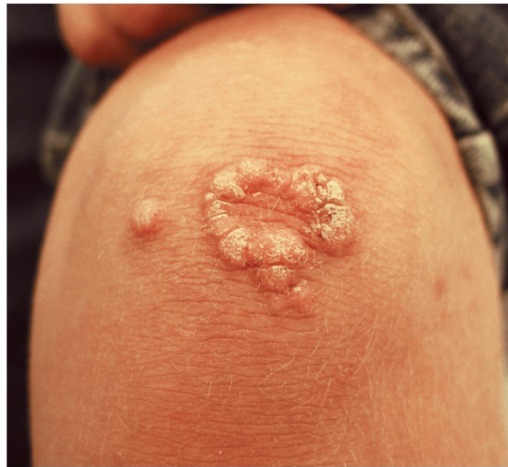

## Contagious Skin Disorders

- **Warts** Small, benign growths caused by varieties of human papillomavirus (HPV) that invade keratinocytes deep in the stratum germinativum of the skin and some mucous membranes. Locally contraindicated.

# Contagious Skin Disorders

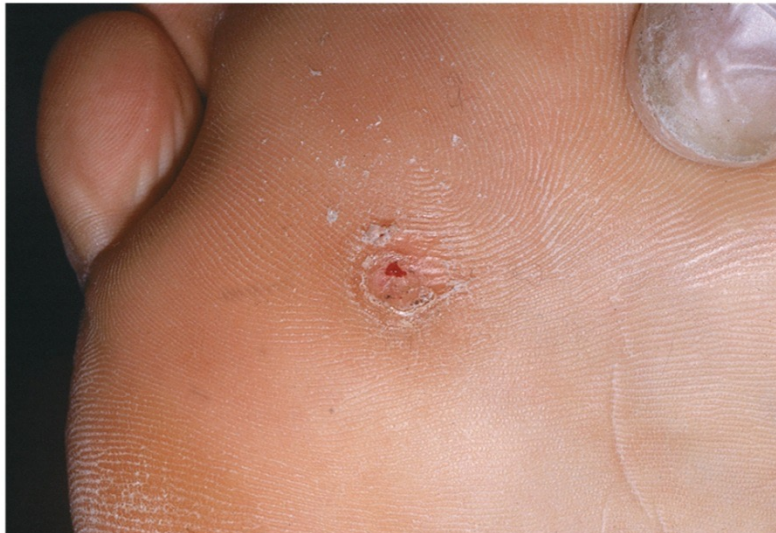- **Common warts (AKA: verruca vulgaris)** Hard, flaky nodules on the hands, knees, and elbows that vary in size.



Copyright © 2013 Wolters Kluwer Health | Lippincott Williams & Wilkins

# Contagious Skin Disorders

- **Plantar warts (AKA: myrmecia)** Warts on the soles of the feet that protrude and can be easily mistaken for a callus.
- **Cystic warts** Warts on the soles of the feet that are smooth and soft.





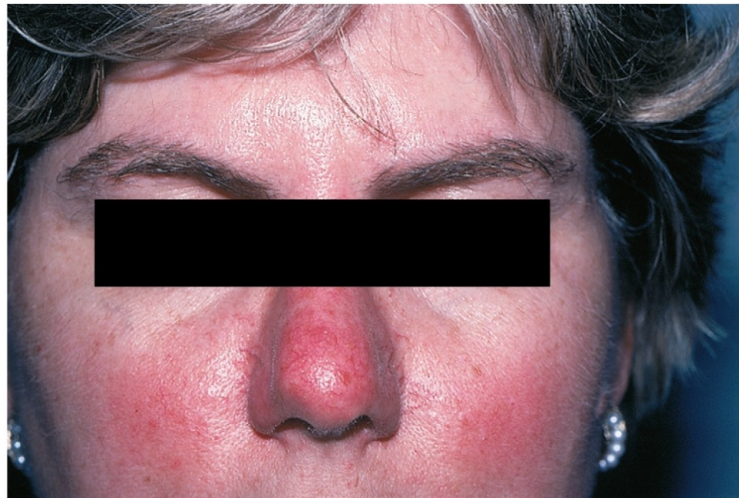## Contagious Skin Disorders

- **Plane warts (AKA: flat warts)** Small, brown, smooth warts. Commonly found on the hands, face, and shins and may be spread during shaving.
- **Genital warts** Sexually transmitted infection caused by several varieties of HPV. Most come and go with no symptoms, but others may trigger cellular activity leading to cervical cancer.



# Non-Contagious Inflammatory Skin Disorders

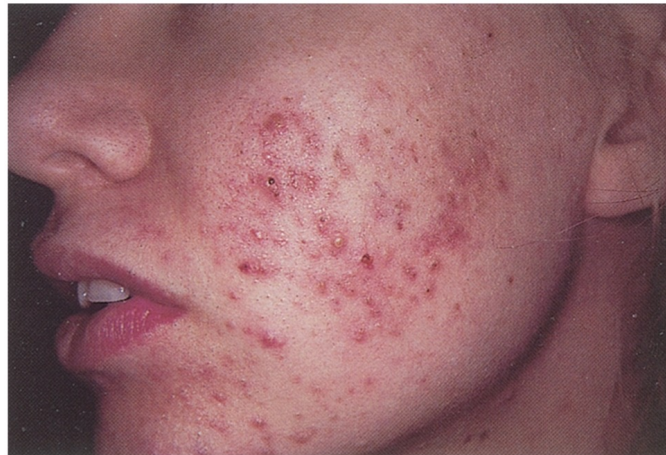**Acne rosacea** Idiopathic chronic inflammatory condition involving facial skin and eyes. Massage may exacerbate this condition.



Copyright © 2013 Wolters Kluwer Health | Lippincott Williams & Wilkins

# Non-Contagious Inflammatory Skin Disorders

**Acne vulgaris** Small, localized skin lesions that usually affecting sebaceous glands on the face, neck, and upper back. Closely associated with adolescence, but can persist well into adulthood. Locally contraindicates massage.



Copyright © 2013 Wolters Kluwer Health | Lippincott Williams & Wilkins



# Non-Contagious Inflammatory Skin Disorders

**Dermatitis** Umbrella term meaning non-infectious skin inflammation.



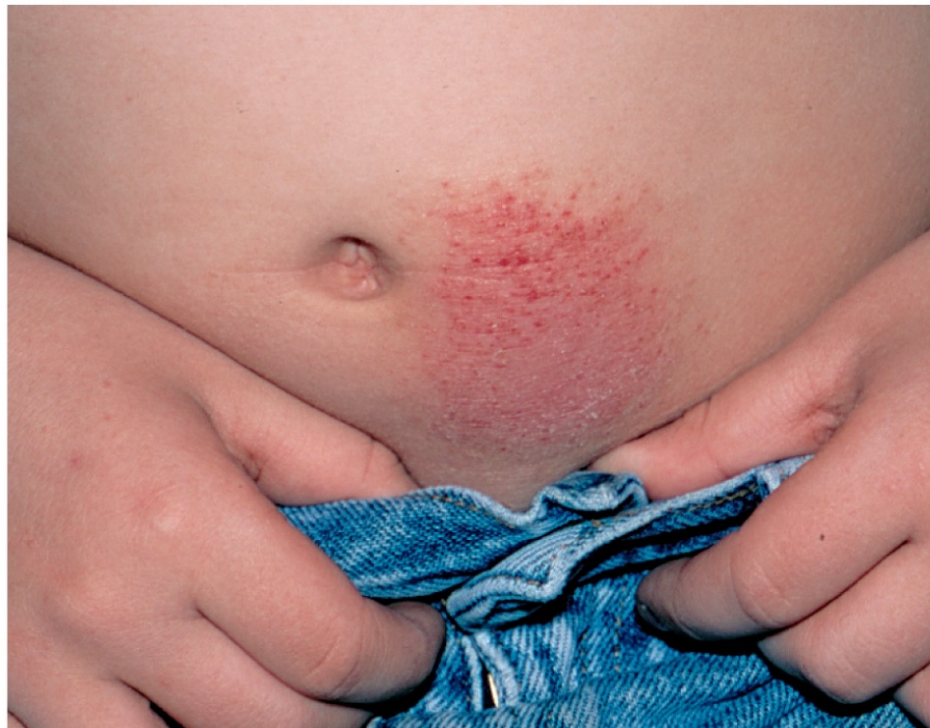

## Non-Contagious Inflammatory Skin Disorders

**Eczema** Non-contagious skin rash brought about by a systemic hypersensitivity reaction. Commonly seen along with allergic sinusitis (hay fever) and asthma.

# Non-Contagious Inflammatory Skin Disorders

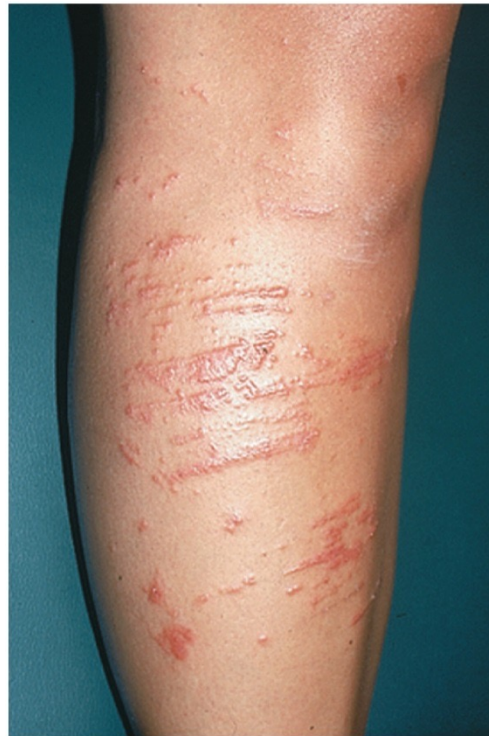**Contact dermatitis** Skin inflammation caused by an externally applied irritant or allergen such as poison ivy, metals, soaps, dyes, or latex.



Copyright © 2013 Wolters Kluwer Health | Lippincott Williams & Wilkins

# Non-Contagious Inflammatory Skin Disorders

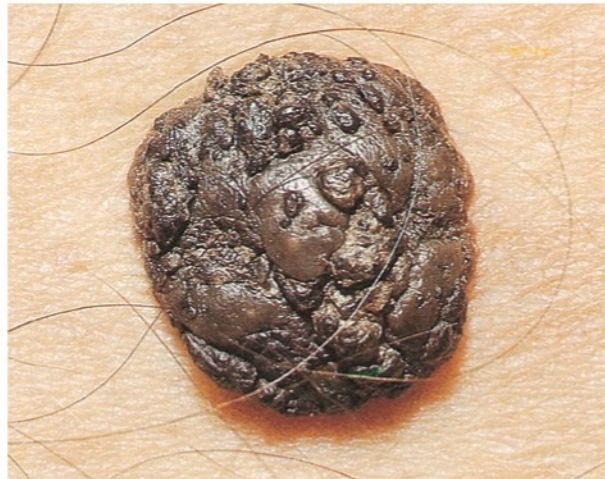**Contact dermatitis** Skin inflammation caused by an externally applied irritant or allergen such as poison ivy, metals, soaps, dyes, or latex.



Copyright © 2013 Wolters Kluwer Health | Lippincott Williams & Wilkins

# Neoplastic Skin Disorders

**Seborrheic keratosis (SK)** Common non-contagious condition involving single or multiple benign skin growths that usually affect mature adults. Local caution if they itch or bleed. May be irritated by friction.



Copyright © 2013 Wolters Kluwer Health | Lippincott Williams & Wilkins



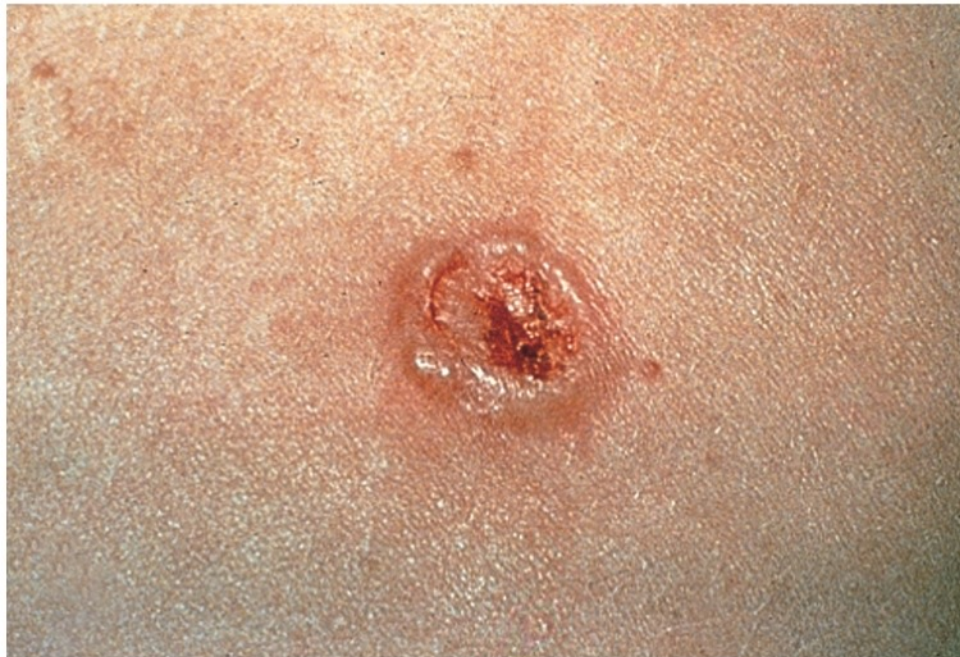## Neoplastic Skin Disorders

**Skin cancer** Group of diseases involving potentially malignant changes in epidermal cells. Undiagnosed skin lesions are locally contraindicated.

- Basal cell carcinoma
- Squamous cell carcinoma
- Melanoma

# Neoplastic Skin Disorders

**Basal cell carcinoma (BCC)** Most common type of skin cancer. Slow-growing tumor of stratum germinativum cells on the face or head.

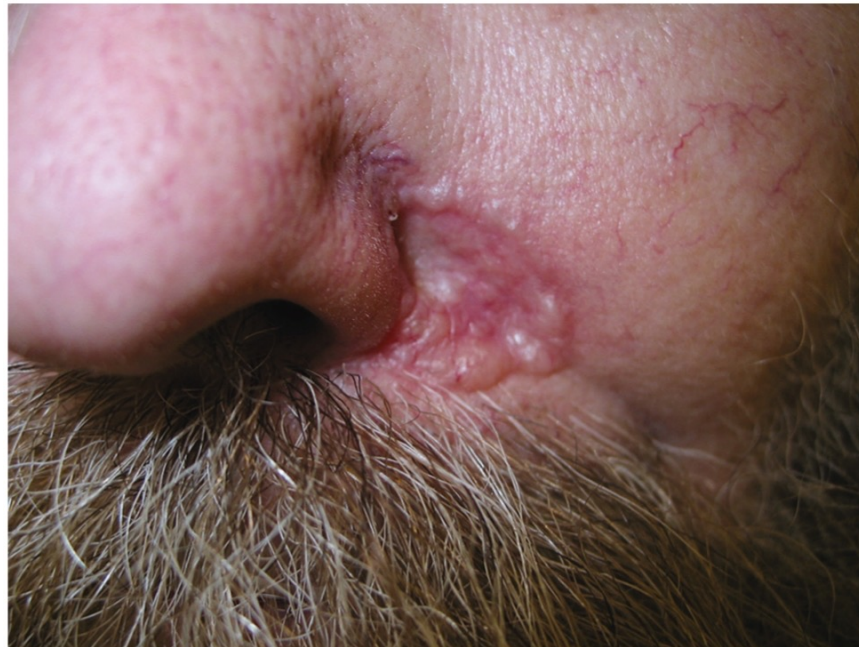

Courtesy of American Cancer Society.



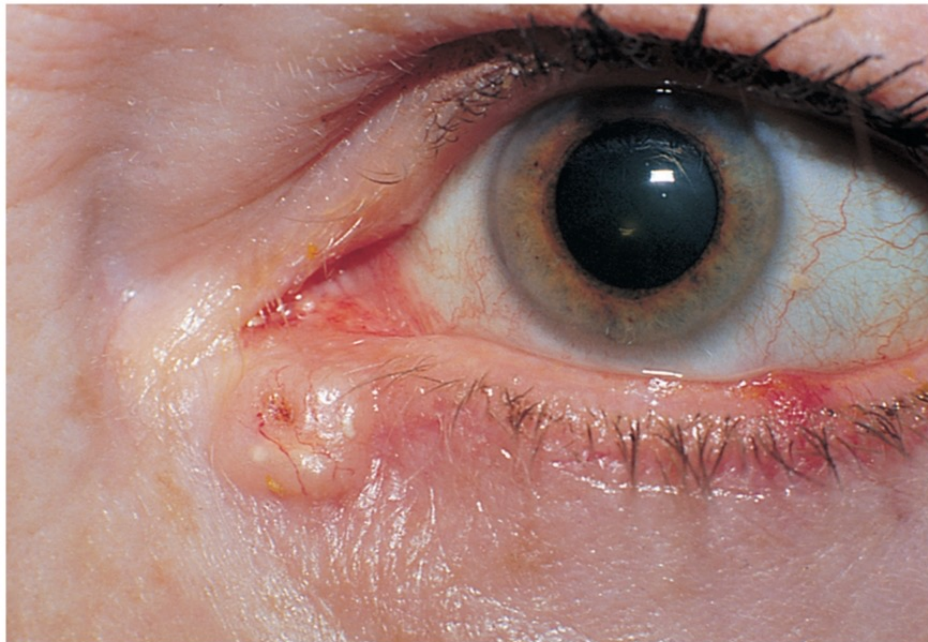
# Neoplastic Skin Disorders

**Basal cell carcinoma (BCC)** Most common type of skin cancer.  
Slow-growing tumor of stratum germinativum cells on the face or head.



# Neoplastic Skin Disorders

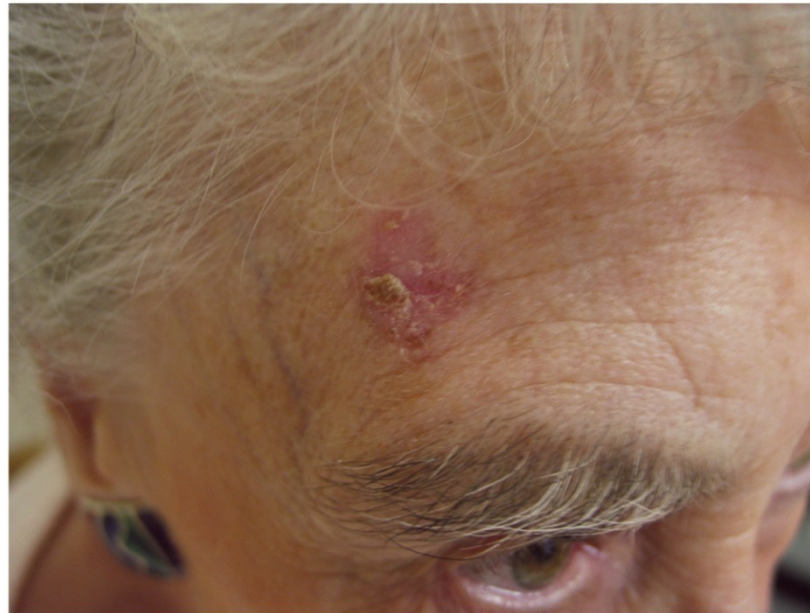**Basal cell carcinoma (BCC)** Most common type of skin cancer.  
Slow-growing tumor of stratum germinativum cells on the face or head.





# Neoplastic Skin Disorders

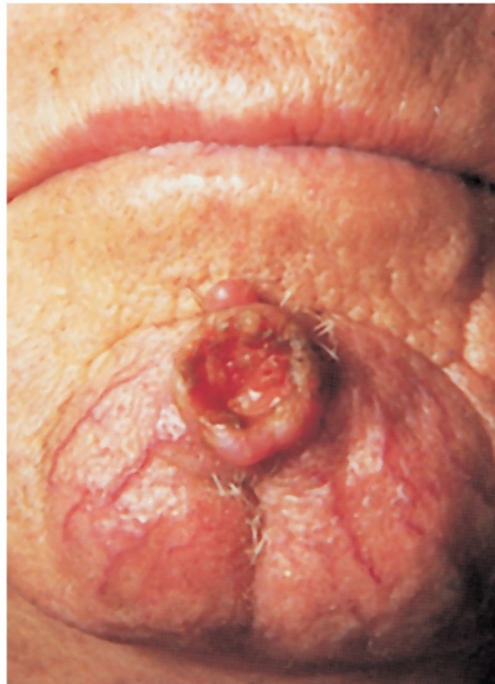**Squamous cell carcinoma** Skin cancer that arises in keratinocytes that are superficial to the stratum germinativum.



Copyright © 2013 Wolters Kluwer Health | Lippincott Williams & Wilkins

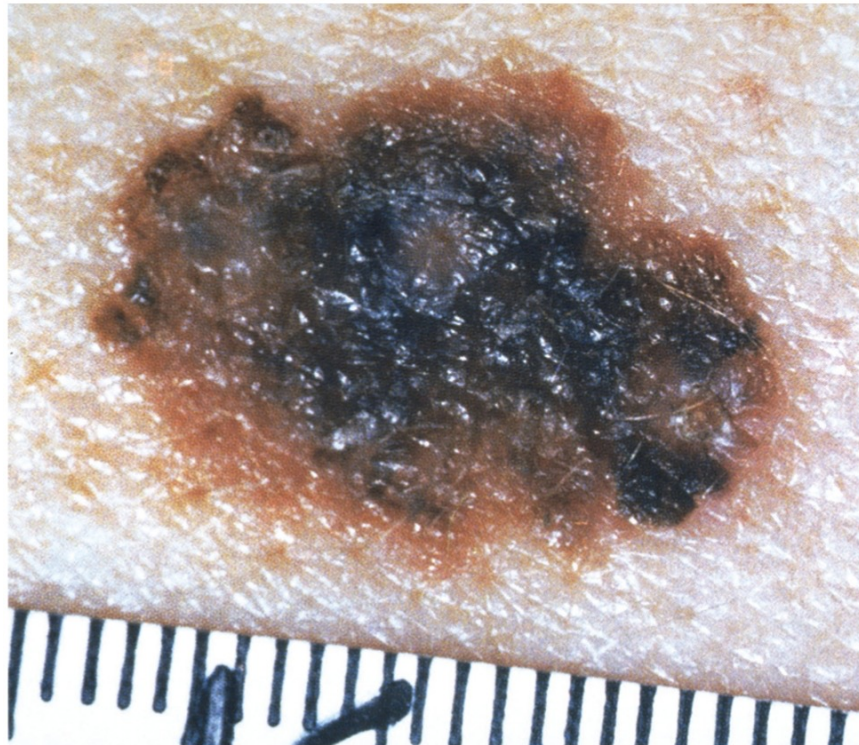
# Neoplastic Skin Disorders

**Squamous cell carcinoma** Skin cancer that arises in keratinocytes that are superficial to the stratum germinativum.



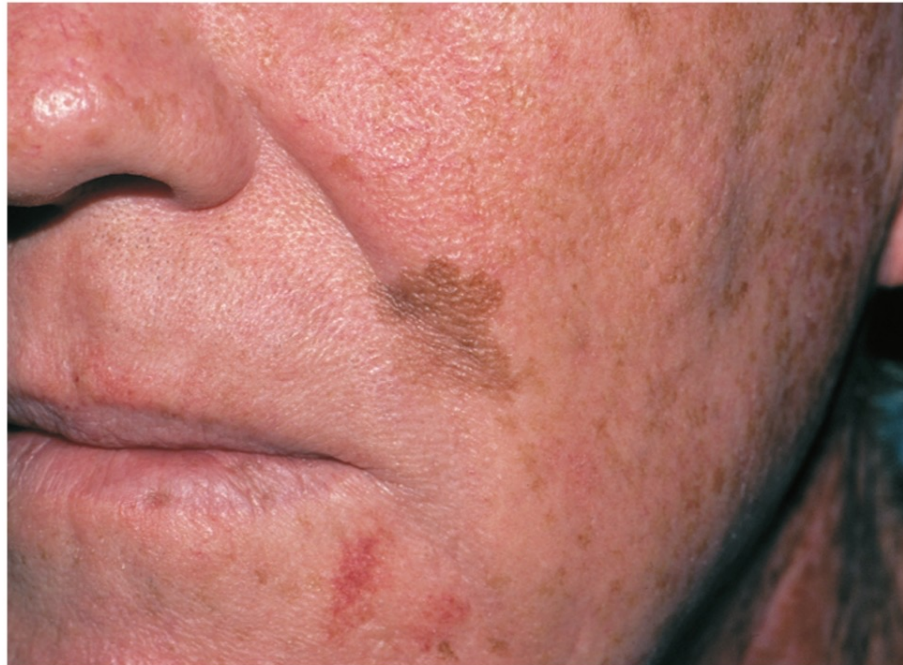# Neoplastic Skin Disorders

**Melanoma** Cancer of the pigment cells deep in the epidermis. Metastasizes readily and is the leading cause of death by skin cancer.



# Neoplastic Skin Disorders

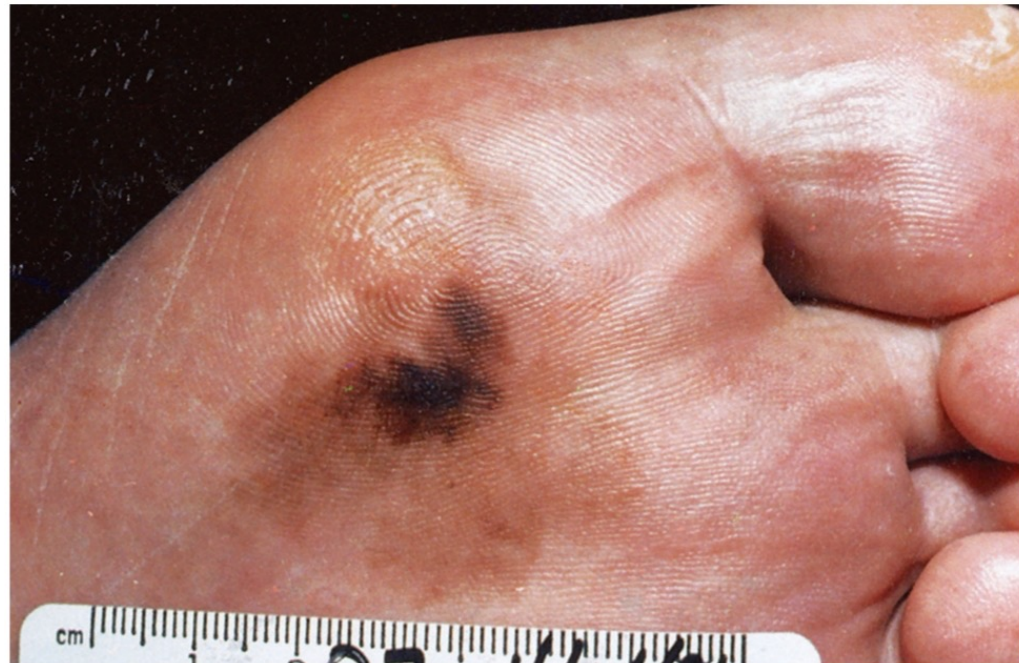
**Melanoma** Cancer of the pigment cells deep in the epidermis. Metastasizes readily and is the leading cause of death by skin cancer.





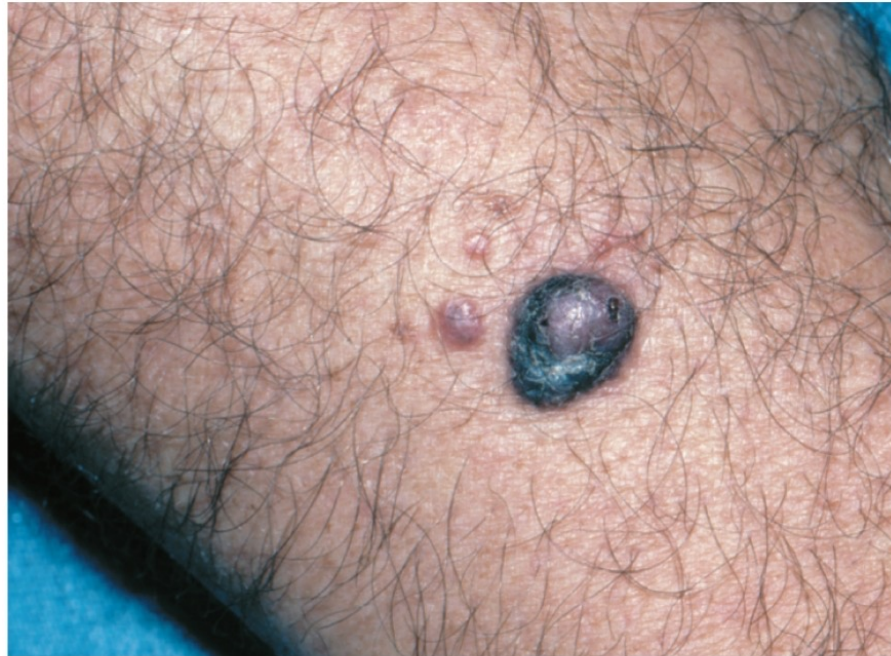# Neoplastic Skin Disorders

**Melanoma** Cancer of the pigment cells deep in the epidermis. Metastasizes readily and is the leading cause of death by skin cancer.



# Neoplastic Skin Disorders

**Melanoma** Cancer of the pigment cells deep in the epidermis. Metastasizes readily and is the leading cause of death by skin cancer.

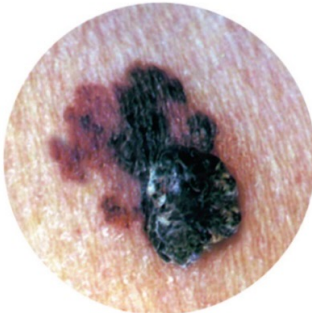


# Neoplastic Skin Disorders

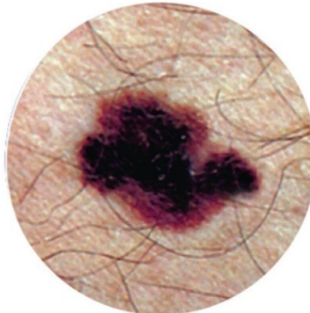
ABCs of recognizing malignant melanoma:

- » Asymmetrical: irregular in shape
- » Border: inconsistent
- » Color: multicolored.
- » Diameter: greater than 6mm (1 / 4 of an inch)
- » Elevated or Evolving

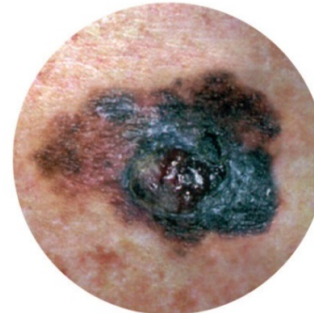
**A**symmetry



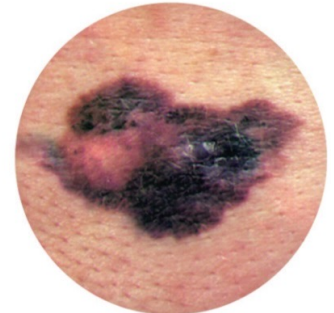**B**orders



**C**olor



**D**iameter





## Skin Injuries

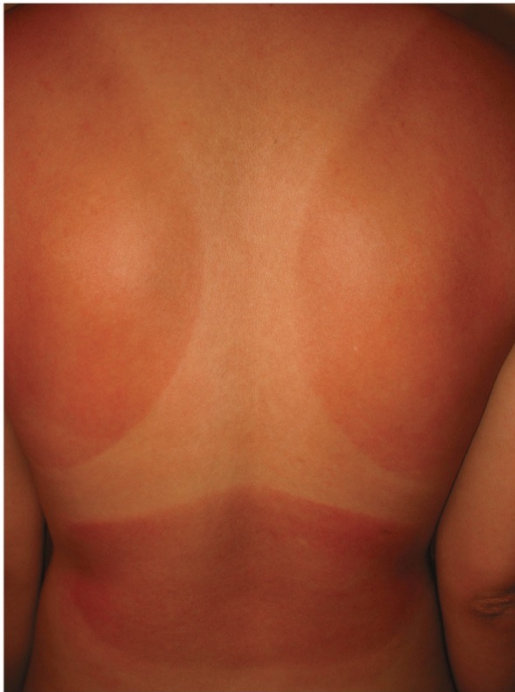**Burns** Damage to skin caused by heat, radiation, corrosive chemicals, and electricity. Contraindicate massage due to risk of infection and pain.

- First degree or superficial burn
- Second degree or partial thickness burn
- Third degree or full thickness burn

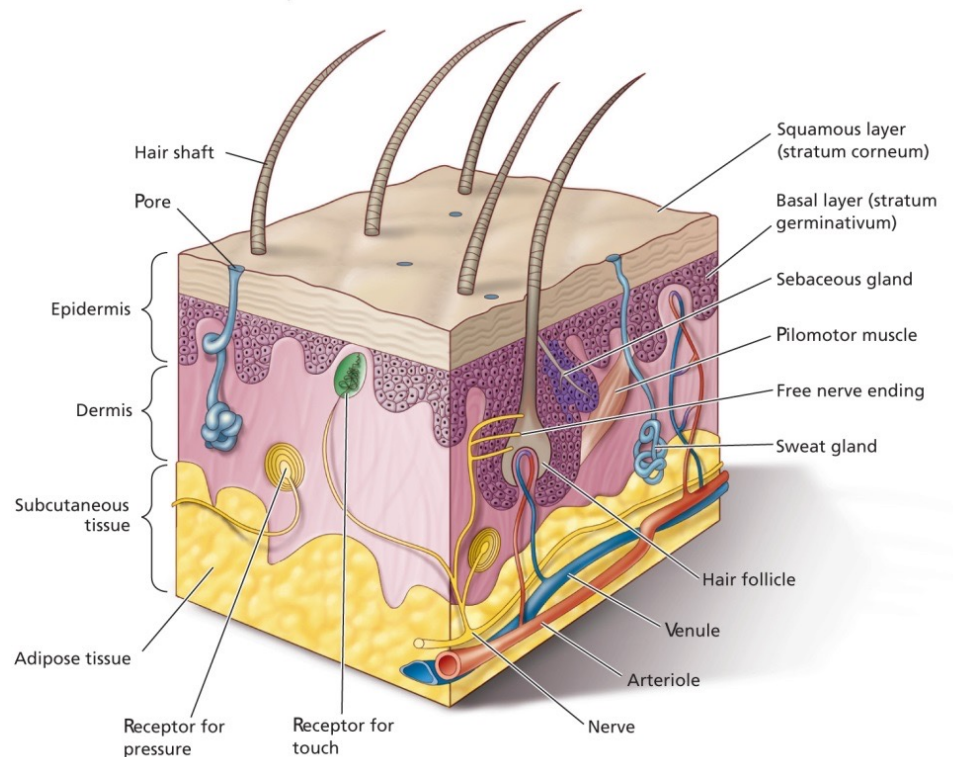


# Skin Injuries

- **First degree or superficial burn** Burn involving mild but painful irritation of the superficial epidermis. Red without blisters. Example: sunburn.



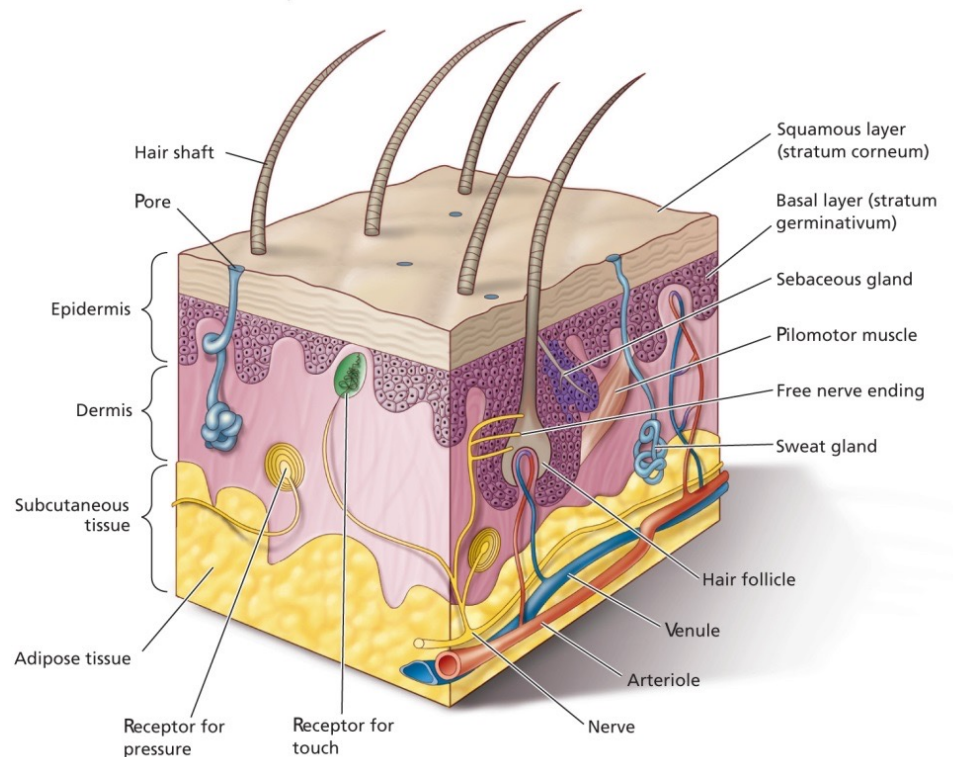
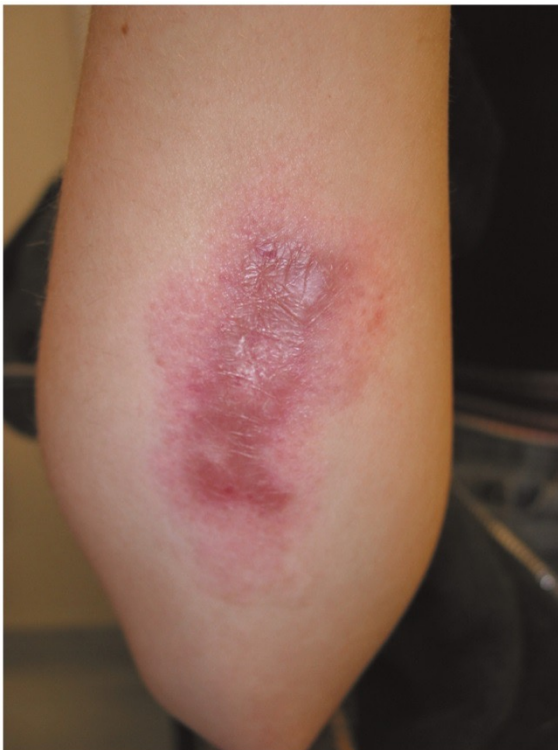Copyright © 2013 Wolters Kluwer Health | Lippincott Williams & Wilkins



Copyright © 2013 Wolters Kluwer Health | Lippincott Williams & Wilkins

# Skin Injuries

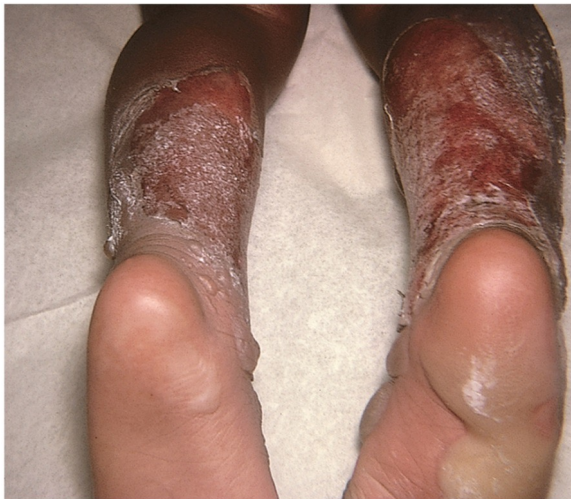- **Second degree or partial thickness burn** Burn involving damage to deeper layers of the epidermis. Redness, blisters, and a permanent scar.



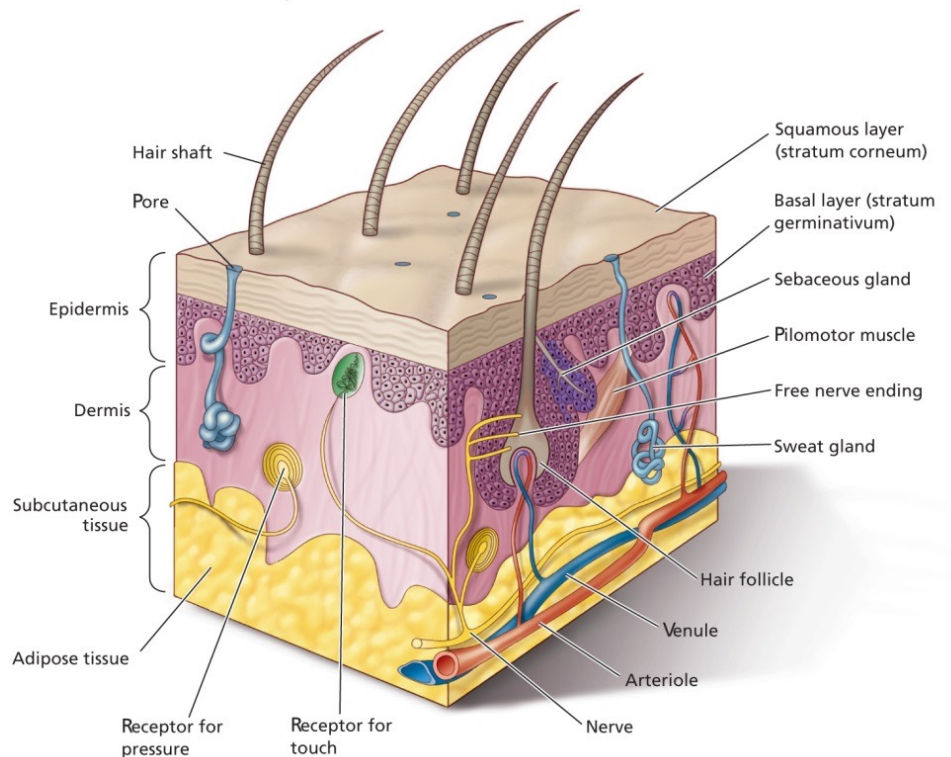
Copyright © 2013 Wolters Kluwer Health | Lippincott Williams & Wilkins

# Skin Injuries

- **Third degree or full thickness burn** Burn that penetrates down to the dermis or deeper damaging glands, hair shafts, nerve endings, and muscle tissues.



Copyright © 2013 Wolters Kluwer Health | Lippincott Williams & Wilkins

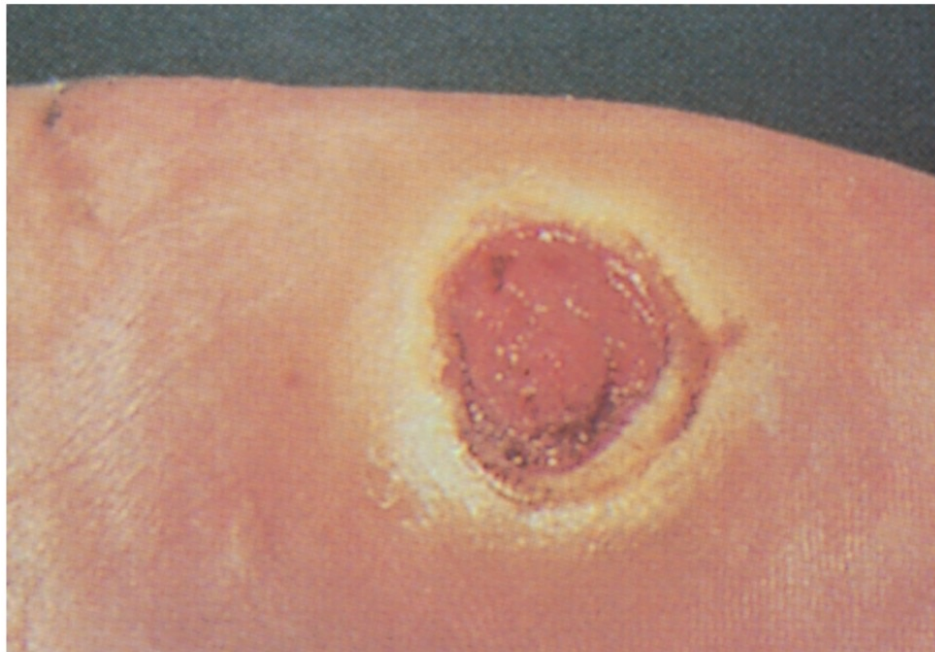

Copyright © 2013 Wolters Kluwer Health | Lippincott Williams & Wilkins



# Skin Injuries

**Decubitus ulcer (AKA: bedsores, or pressure sores)** Lesions caused by impaired circulation to the skin because of external pressure. Leads to localized cell death. High risk of secondary infection contraindicates massage.





## Skin Injuries

**Scar tissue** Development of new cells and extracellular matrix after an injury, infection, or surgery. Contraindicates massage if still injured and not yet healed.



## 29a Pathology - Integumentary System