



36a A&P: Cardiovascular System - Blood Vessel and Paths of Circulation



36a A&P: Cardiovascular System - Blood Vessels and Paths of Circulation

Class Outline

5 minutes	Attendance, Breath of Arrival, and Reminders
10 minutes	Lecture:
25 minutes	Lecture:
15 minutes	Active study skills:
60 minutes	Total



36a A&P: Cardiovascular System - Blood Vessels and Paths of Circulation

Class Reminders

Assignments:

- 36b State Law Review Questions (Packet A: 159-164)
- 41a Review Questions (Packet A: 165-178)
- 43a Swedish: Outside Massages (Packet A: 57-62)

Quizzes and Exams:

- 42a Quiz (35a, 36a, 37a, 38a, 39a, 40a, and 41a)
- 42b Kinesiology Quiz
 - (adductor magnus, gracilis, iliopsoas, sartorius, TFL, piriformis, quadratus femoris)
- 44a Quiz (33b, 37b, 41b, 42b, and 43a)
- 46a Exam

Preparation for upcoming classes:

- 37a Pathology: Circulatory System
 - Werner: Chapter 5
 - Packet E: 73-74
 - RQ Packet A-169
- 37b Business: State Massage Law and Find a Job
 - Business Mastery: Chapters 7-11
 - Packet B: 33-36
 - RQ Packet A-170



Classroom Rules

Punctuality - everybody's time is precious

- Be ready to learn at the start of class; we'll have you out of here on time
- Tardiness: arriving late, returning late after breaks, leaving during class, leaving early

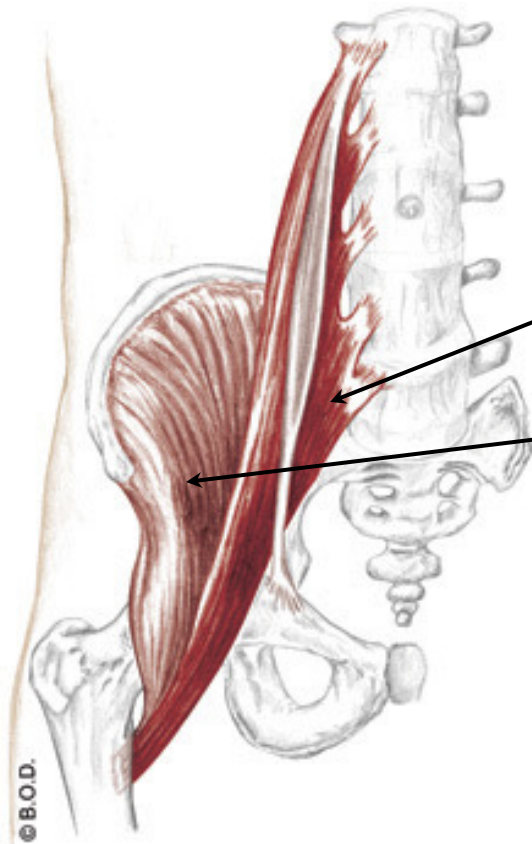
The following are not allowed:

- Bare feet
- Side talking
- Lying down
- Inappropriate clothing
- Food or drink except water
- Phones that are visible in the classroom, bathrooms, or internship

You will receive one verbal warning, then you'll have to leave the room.

Iliopsoas

Trail Guide, Page 332



Iliopsoas is the combination of psoas major and iliacus.

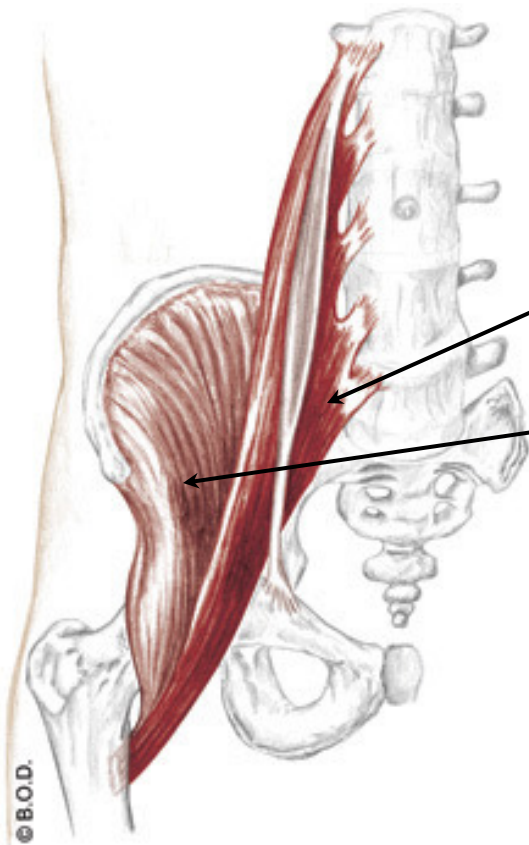
Psoas major stretches from the lumbar vertebrae to the lesser trochanter.

Iliacus is stockier. It begins in the iliac fossa and also inserts on the lesser trochanter.

Anterior View

Iliopsoas

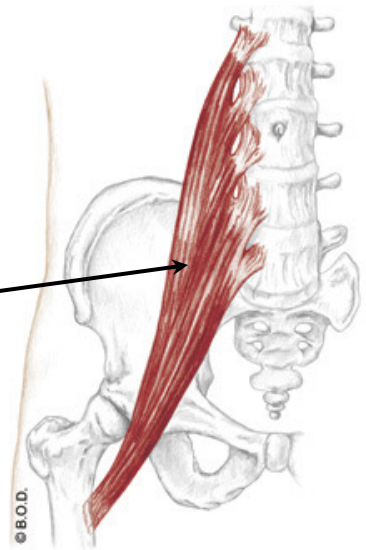
Trail Guide, Page 332



Anterior View

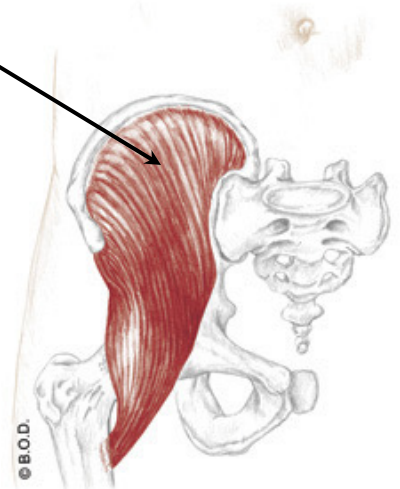Psoas major

Iliacus



Anterior View

Iliopsoas, what does it do?



Anterior View

Psoas Major, page 332

A *With the origin fixed:*

Flex the hip (coxal joint)

May **laterally rotate** the hip (coxal joint)

With the insertion fixed:

Flex the trunk toward the thigh

Tilt the pelvis anteriorly

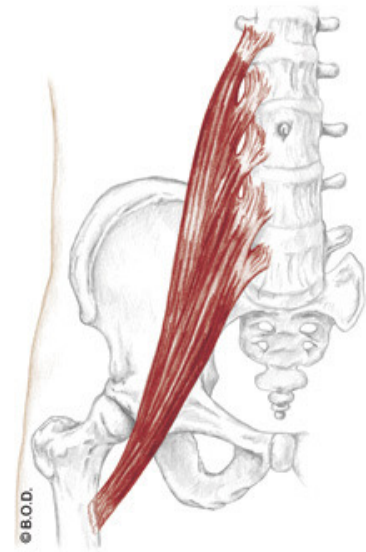
Unilaterally:

Assist to **laterally flex** the lumbar spine

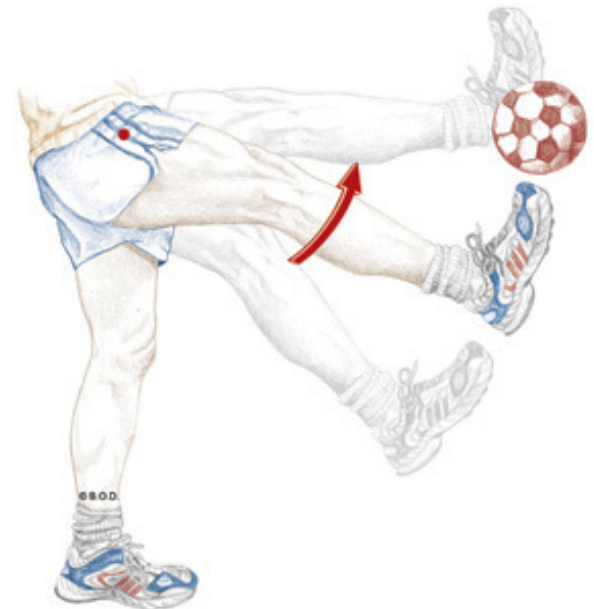O Bodies of lumbar vertebrae

Transverse processes of lumbar vertebrae

I Lesser trochanter



Anterior View



Psoas Major, page 332

A *With the origin fixed:*
Flex the hip (coxal joint)

May **laterally rotate** the hip (coxal joint)

With the insertion fixed:
Flex the trunk toward the thigh

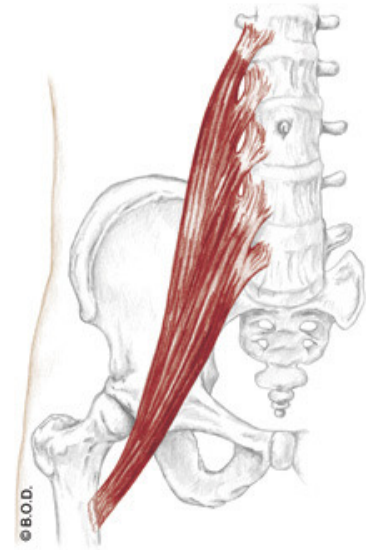
Tilt the pelvis anteriorly

Unilaterally:
Assist to **laterally flex** the lumbar spine

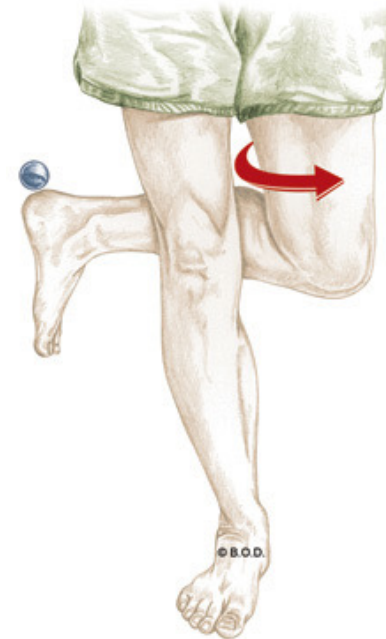
O Bodies of lumbar vertebrae

Transverse processes of lumbar vertebrae

I Lesser trochanter



Anterior View



Psoas Major, page 332

A *With the origin fixed:*
Flex the hip (coxal joint)

May **laterally rotate** the hip (coxal joint)

With the insertion fixed:

Flex the trunk toward the thigh

Tilt the pelvis anteriorly

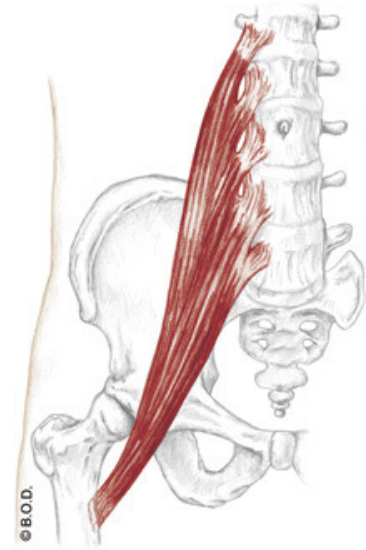
Unilaterally:

Assist to **laterally flex** the lumbar spine

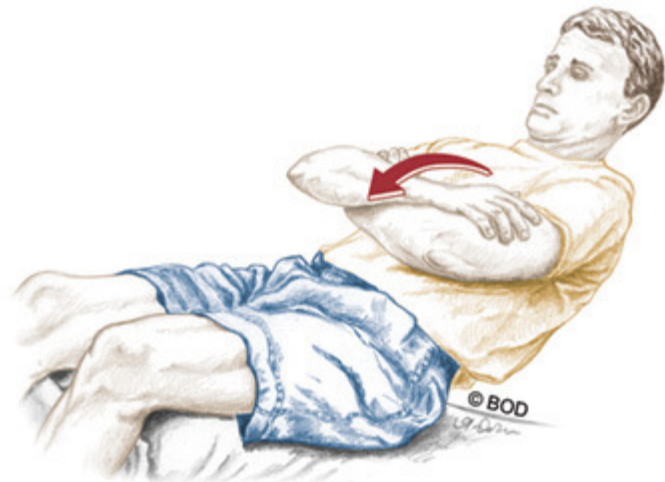O Bodies of lumbar vertebrae

Transverse processes of lumbar vertebrae

I Lesser trochanter



Anterior View



Psoas Major, page 332

A *With the origin fixed:*
Flex the hip (coxal joint)

May **laterally rotate** the hip (coxal joint)

With the insertion fixed:
Flex the trunk toward the thigh

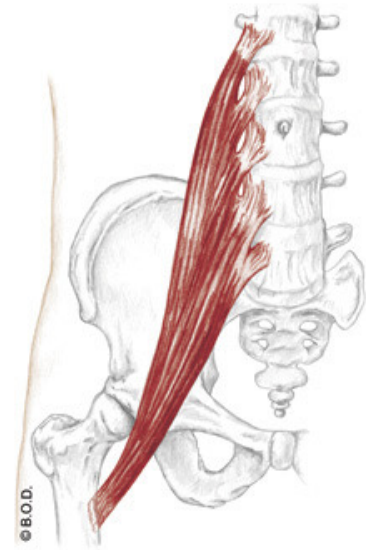
Tilt the pelvis anteriorly

Unilaterally:
Assist to **laterally flex** the lumbar spine

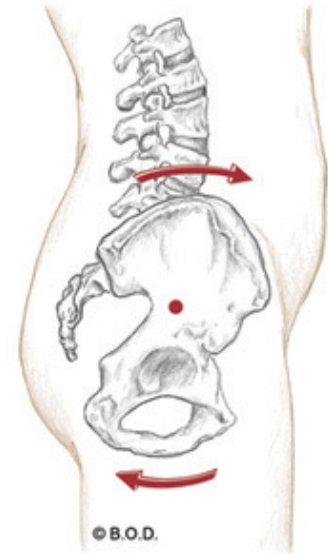
O Bodies of lumbar vertebrae

Transverse processes of lumbar vertebrae

I Lesser trochanter



Anterior View



Lateral View

Psoas Major, page 332

A *With the origin fixed:*
Flex the hip (coxal joint)

May **laterally rotate** the hip (coxal joint)

With the insertion fixed:
Flex the trunk toward the thigh

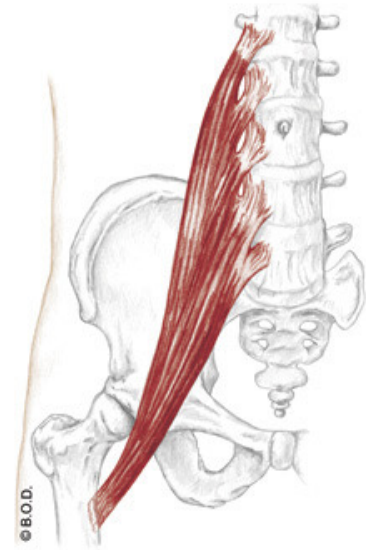
Tilt the pelvis anteriorly

Unilaterally:
Assist to **laterally flex** the lumbar spine

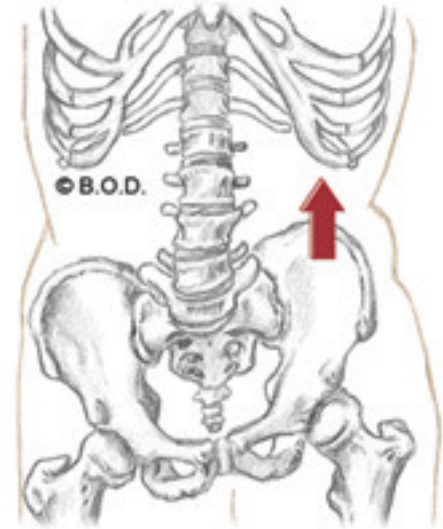
O Bodies of lumbar vertebrae

Transverse processes of lumbar vertebrae

I Lesser trochanter



Anterior View



Psoas Major, page 332

A *With the origin fixed:*
Flex the hip (coxal joint)

May **laterally rotate** the hip (coxal joint)

With the insertion fixed:
Flex the trunk toward the thigh

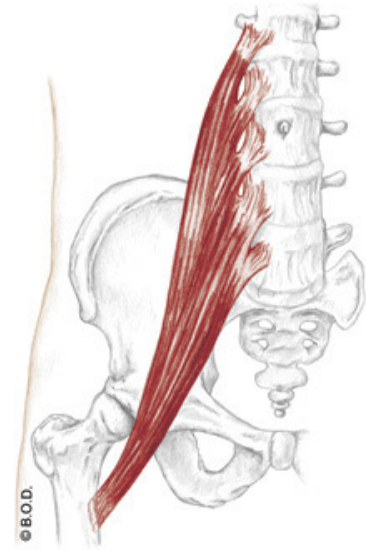
Tilt the pelvis anteriorly

Unilaterally:
Assist to **laterally flex** the lumbar spine

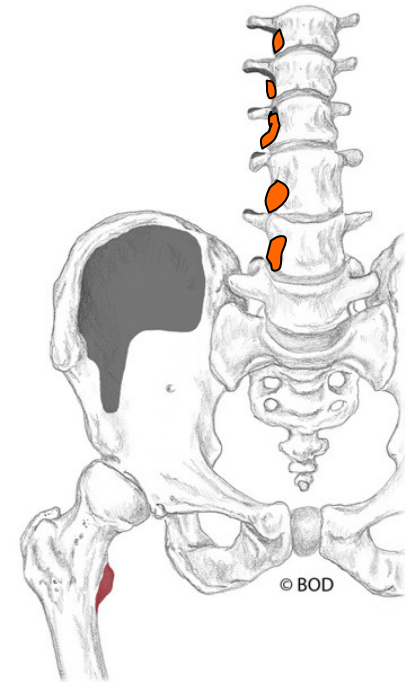
O Bodies of lumbar vertebrae

Transverse processes of lumbar vertebrae

I Lesser trochanter



Anterior View



Psoas Major, page 332

A *With the origin fixed:*
Flex the hip (coxal joint)

May **laterally rotate** the hip (coxal joint)

With the insertion fixed:
Flex the trunk toward the thigh

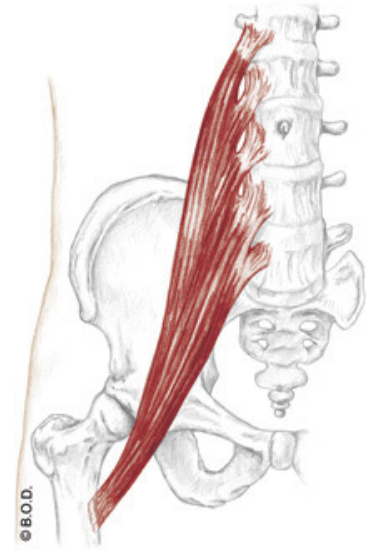
Tilt the pelvis anteriorly

Unilaterally:
Assist to **laterally flex** the lumbar spine

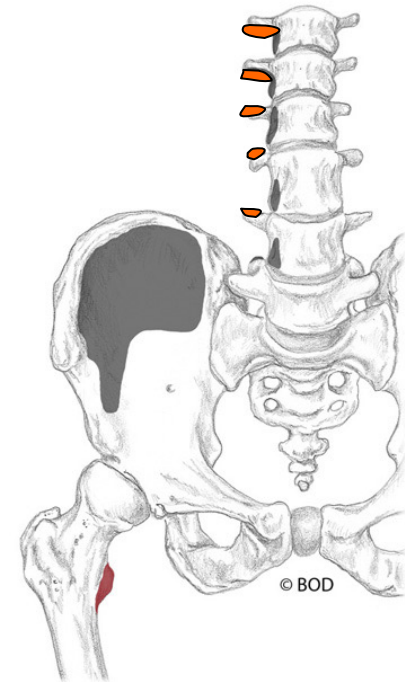
O Bodies of lumbar vertebrae

Transverse processes of lumbar vertebrae

I Lesser trochanter



Anterior View



Psoas Major, page 332

A *With the origin fixed:*
Flex the hip (coxal joint)

May **laterally rotate** the hip (coxal joint)

With the insertion fixed:
Flex the trunk toward the thigh

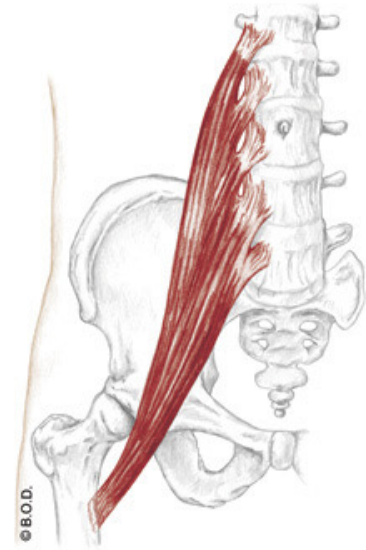
Tilt the pelvis anteriorly

Unilaterally:
Assist to **laterally flex** the lumbar spine

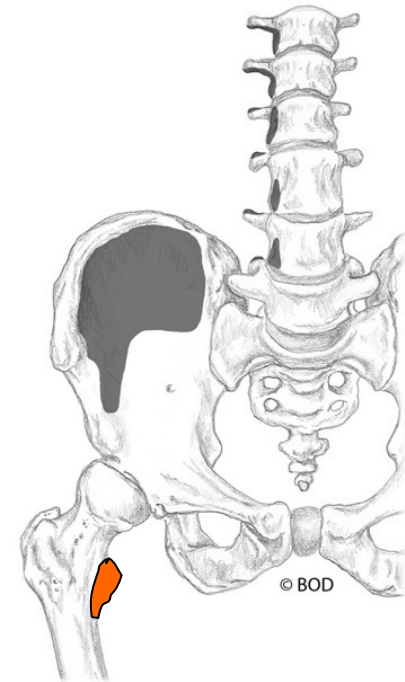
O Bodies of lumbar vertebrae

Transverse processes of lumbar vertebrae

I Lesser trochanter



Anterior View



Time to shift gears



From psoas major to iliacus . . .

Iliacus, page 332

A *With the origin fixed:*

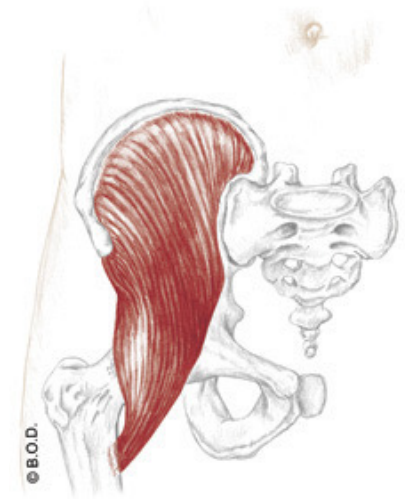
Flex the hip (coxal joint)

May **laterally rotate** the hip (coxal joint)

With the insertion fixed:

Flex the trunk toward the thigh

Tilt the pelvis anteriorly



Anterior View

O Iliac fossa

I Lesser trochanter



Iliacus, page 332

A *With the origin fixed:*
Flex the hip (coxal joint)

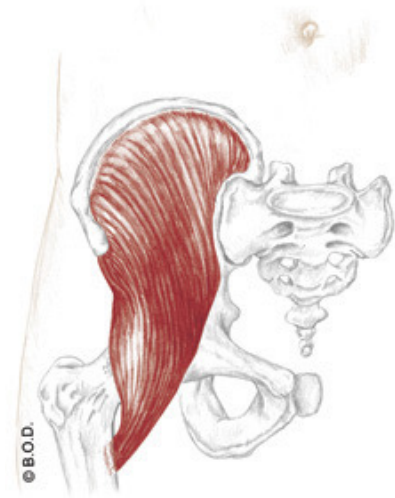
May **laterally rotate** the hip (coxal joint)

With the insertion fixed:
Flex the trunk toward the thigh

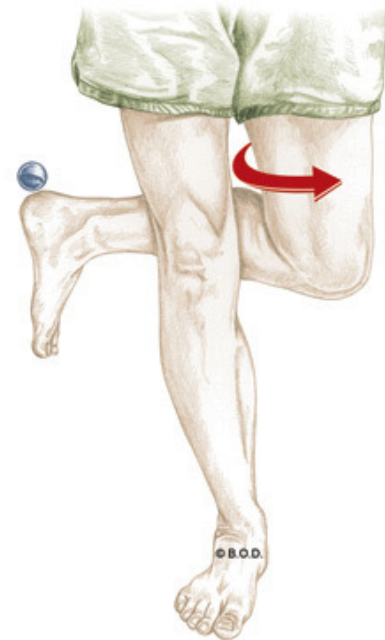
Tilt the pelvis anteriorly

O Iliac fossa

I Lesser trochanter



Anterior View



Iliacus, page 332

A *With the origin fixed:*
Flex the hip (coxal joint)

May **laterally rotate** the hip (coxal joint)

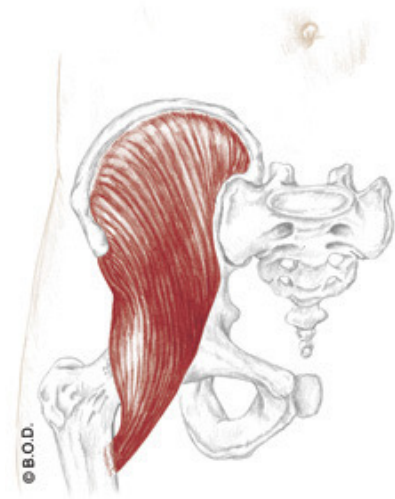
With the insertion fixed:

Flex the trunk toward the thigh

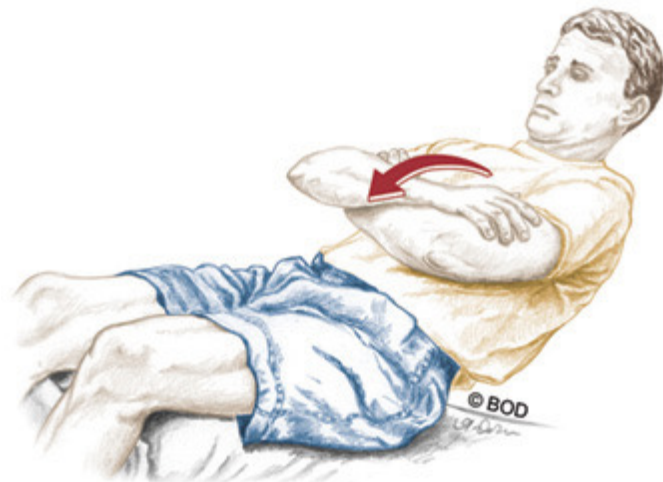Tilt the pelvis anteriorly

O Iliac fossa

I Lesser trochanter



Anterior View



Iliacus, page 332

A *With the origin fixed:*
Flex the hip (coxal joint)

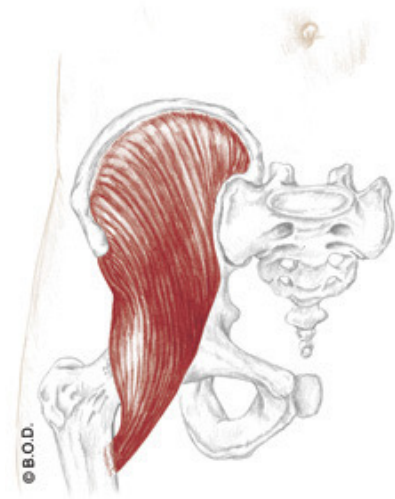
May **laterally rotate** the hip (coxal joint)

With the insertion fixed:
Flex the trunk toward the thigh

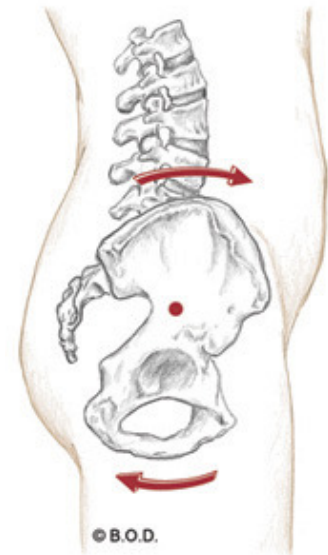
Tilt the pelvis anteriorly

O Iliac fossa

I Lesser trochanter



Anterior View



Iliacus, page 332

A *With the origin fixed:*
Flex the hip (coxal joint)

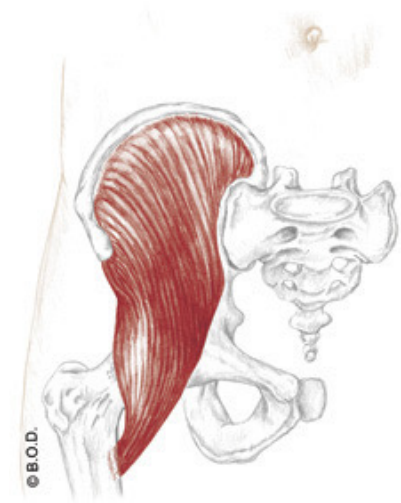
May **laterally rotate** the hip (coxal joint)

With the insertion fixed:
Flex the trunk toward the thigh

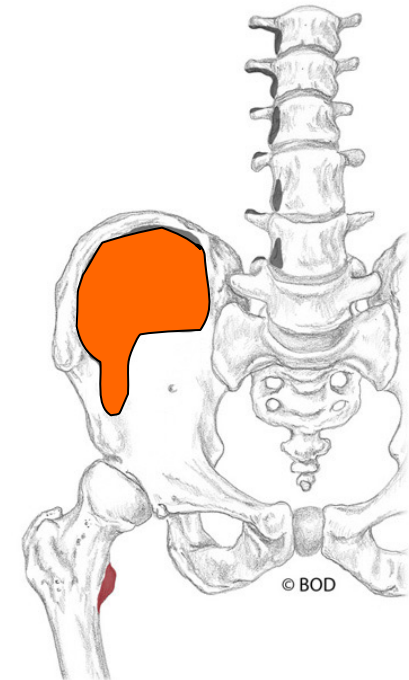
Tilt the pelvis anteriorly

O Iliac fossa

I Lesser trochanter



Anterior View



Iliacus, page 332

A *With the origin fixed:*
Flex the hip (coxal joint)

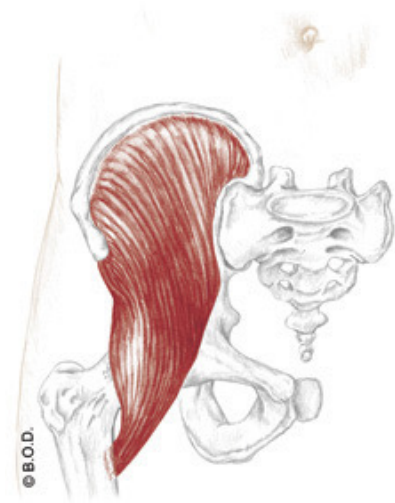
May **laterally rotate** the hip (coxal joint)

With the insertion fixed:
Flex the trunk toward the thigh

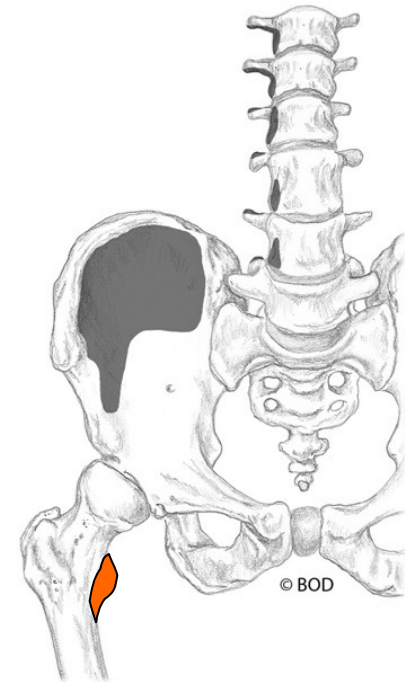
Tilt the pelvis anteriorly

O Iliac fossa

I Lesser trochanter



Anterior View





36a A&P: Cardiovascular System - Blood Vessels and Paths of Circulation

E - 69



Blood Vessels

Walls of Arteries and Veins

Arteries

Pulse

Capillary

Veins

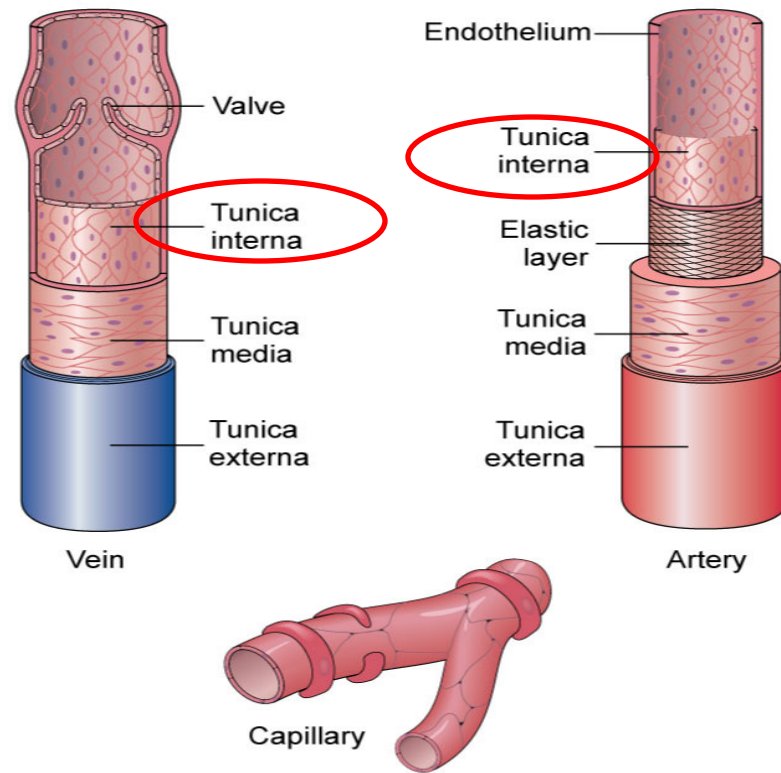
Venous Return

Walls of Arteries and Veins

Tunica interna (AKA: tunica intima) Innermost layer of a blood vessel.

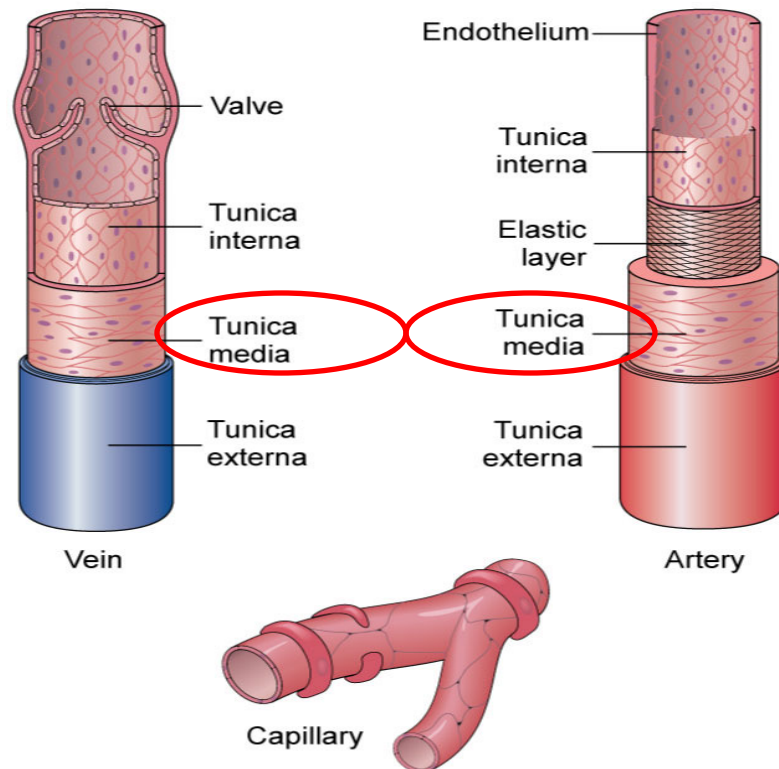
Endothelium fused with a small quantity of elastic connective tissue.

Valves assist venous return by only allowing blood to move back toward the heart.



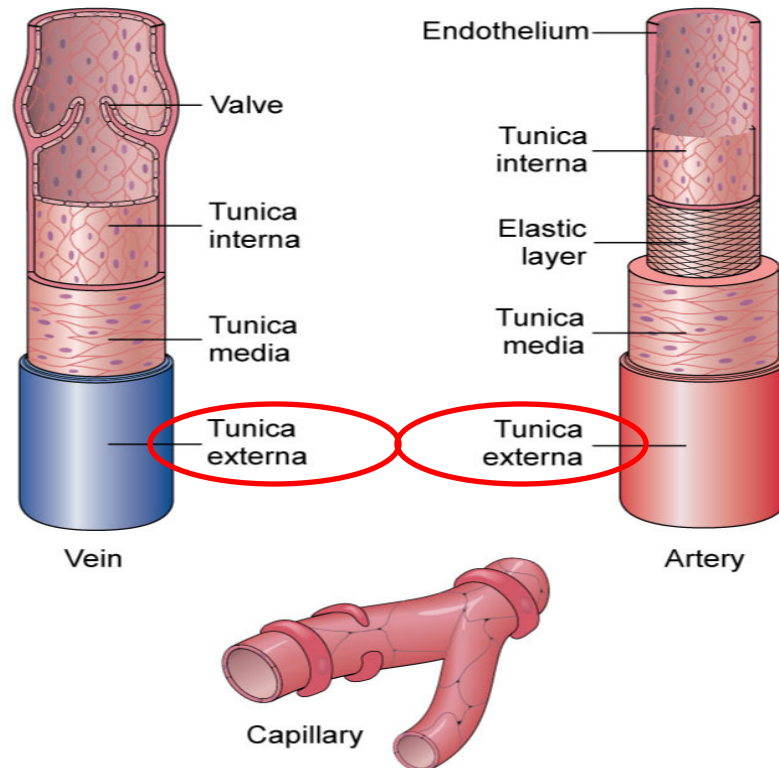
Walls of Arteries and Veins

Tunica media Middle layer of a blood vessel. Contains both connective tissue and smooth muscle.



Walls of Arteries and Veins

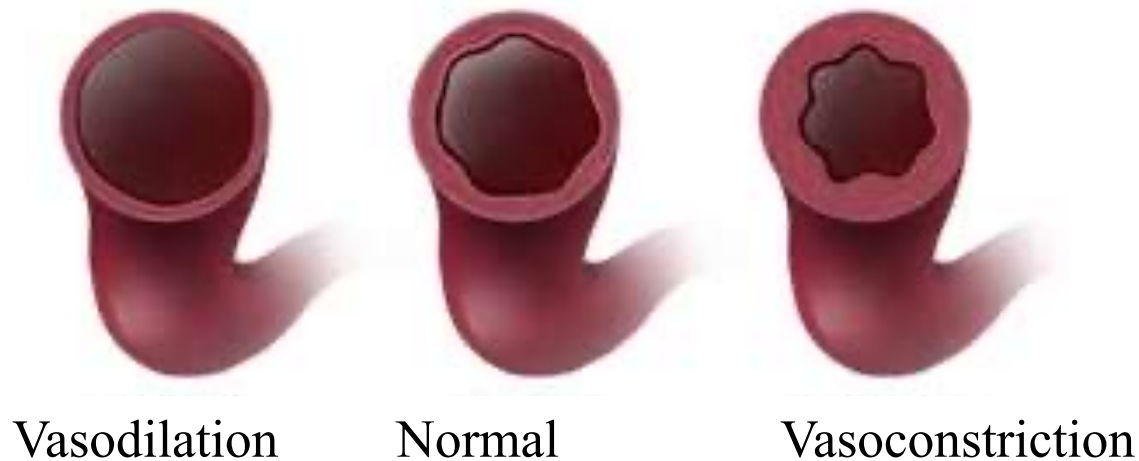
Tunica externa (AKA: tunica adventitia) Outer layer of a blood vessel. Possesses mostly dense connective tissue.



Walls of Arteries and Veins

Vasodilation Enlargement of the vascular lumen's diameter.

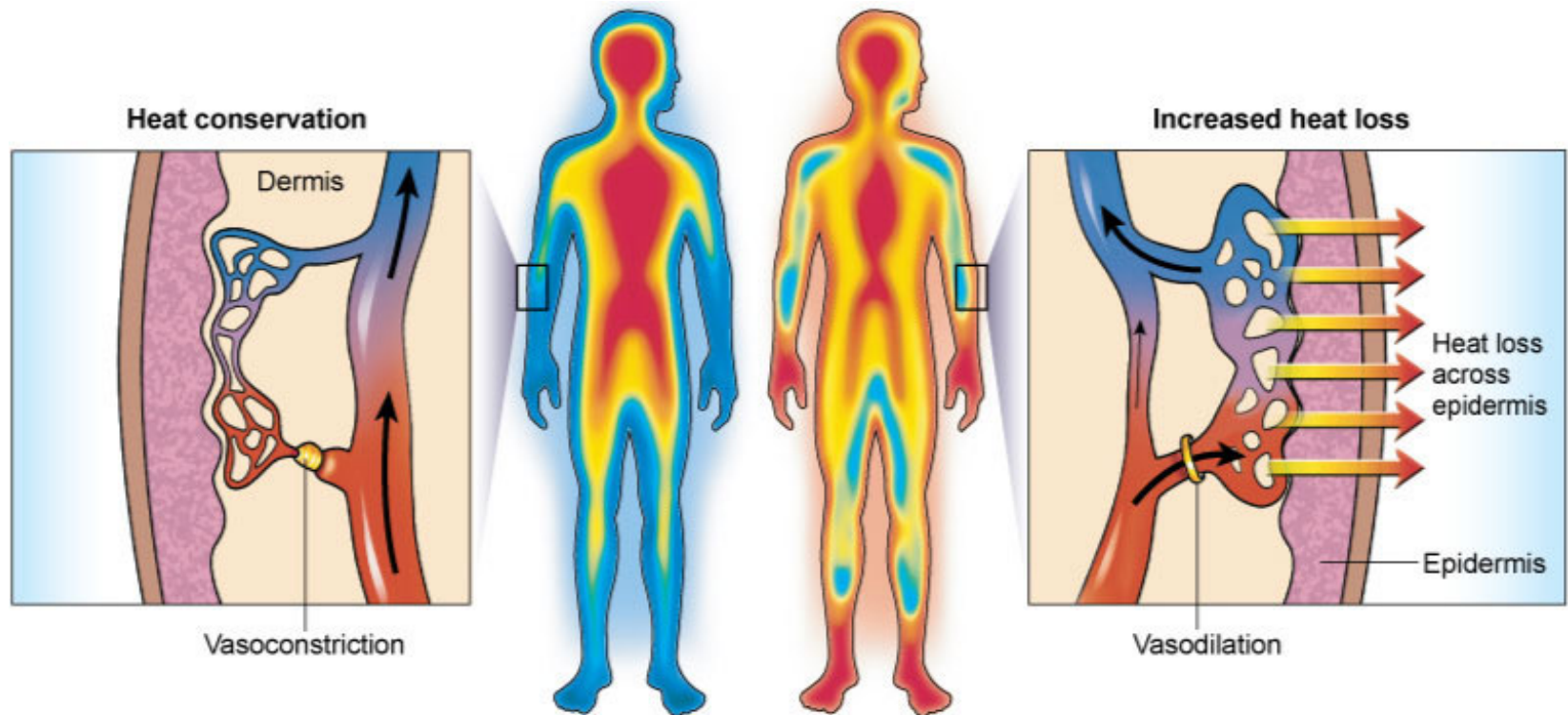
Vasoconstriction Narrowing of the vascular lumen's diameter.



Walls of Arteries and Veins

Vasodilation Enlargement of the vascular lumen's diameter.

Vasoconstriction Narrowing of the vascular lumen's diameter.





Walls of Arteries and Veins

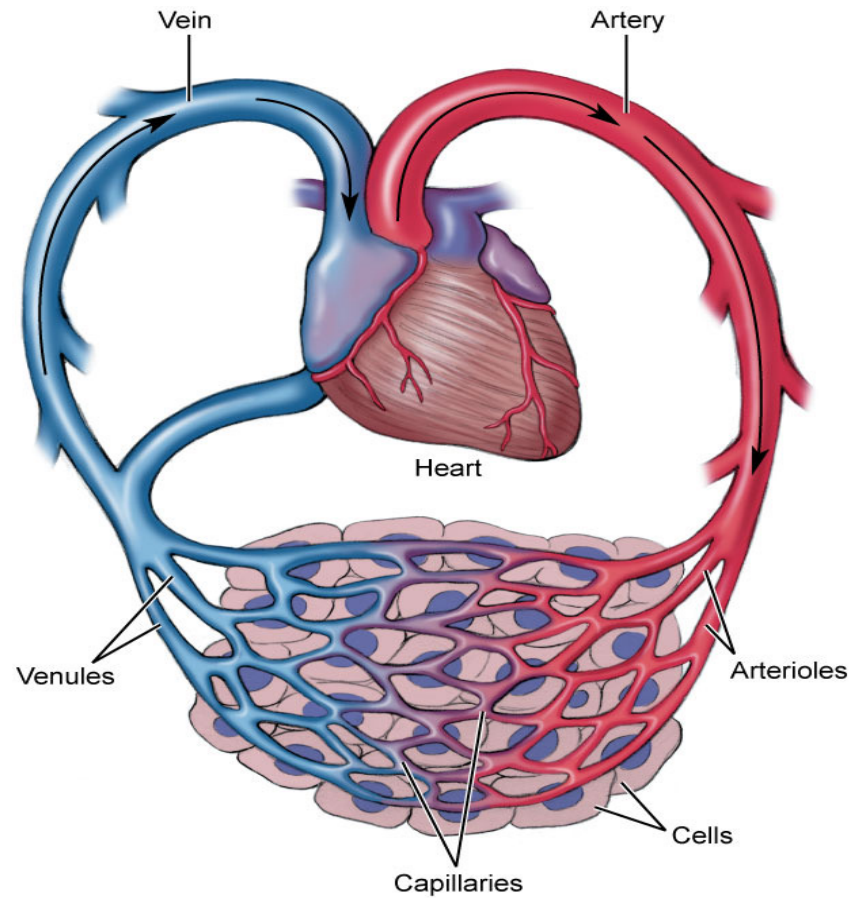
Hyperemia Increased local blood flow causing the skin to become reddened and warm.

Ischemia Local abnormal decrease in blood flow. Often marked by pain and tissue dysfunction.

Arteries

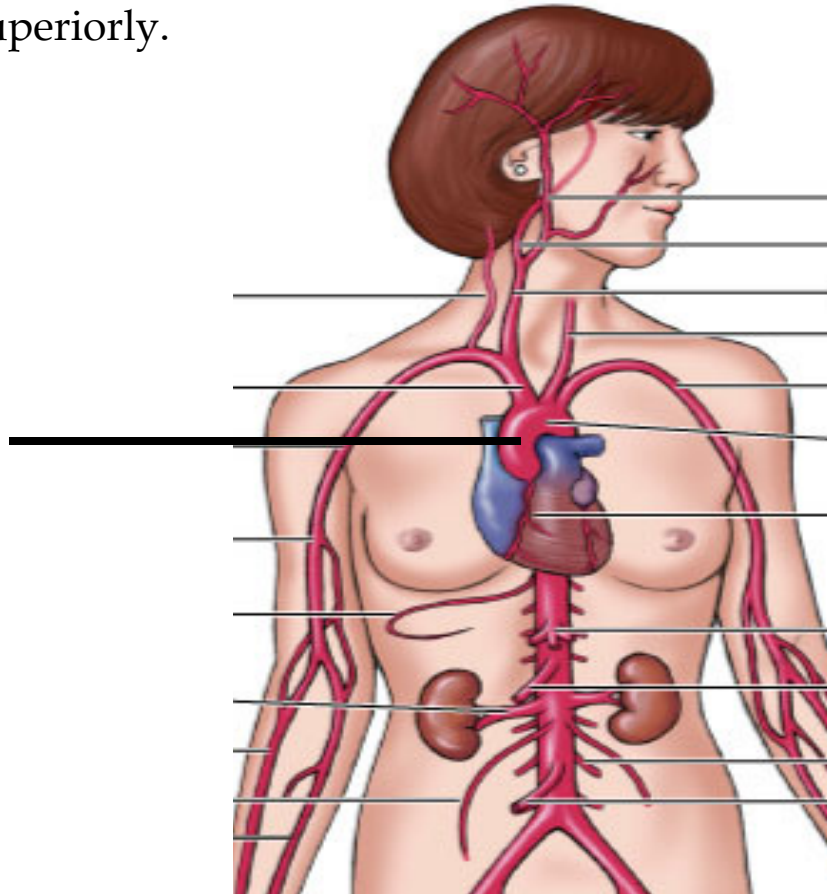
Artery Vessel that carries blood away from the heart to the tissues of the body.

Arterioles Small-sized arteries.



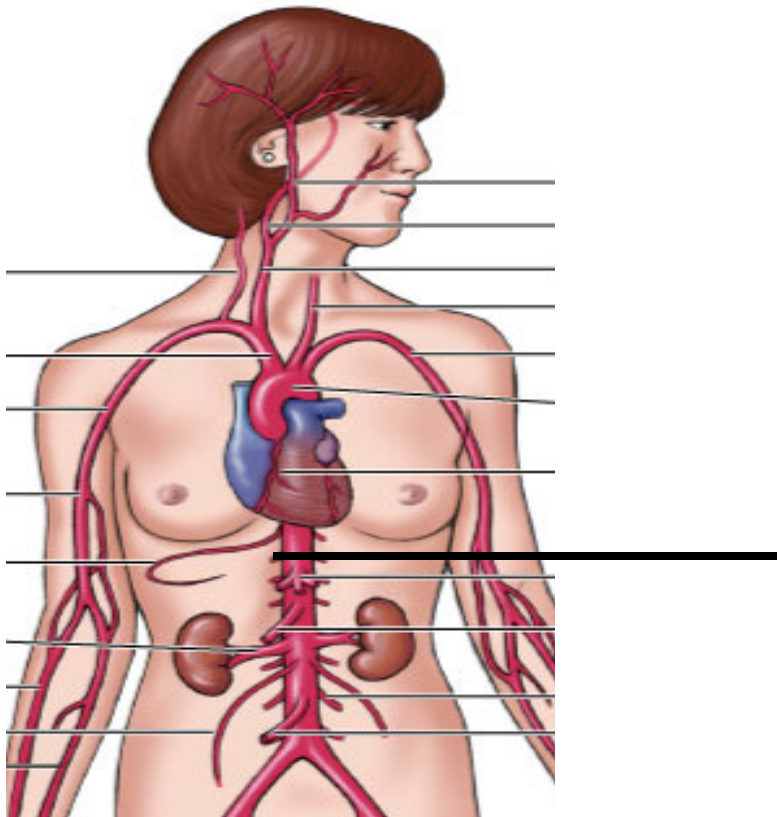
Arteries

Ascending aorta Very large artery that begins at the left ventricle and travels superiorly.



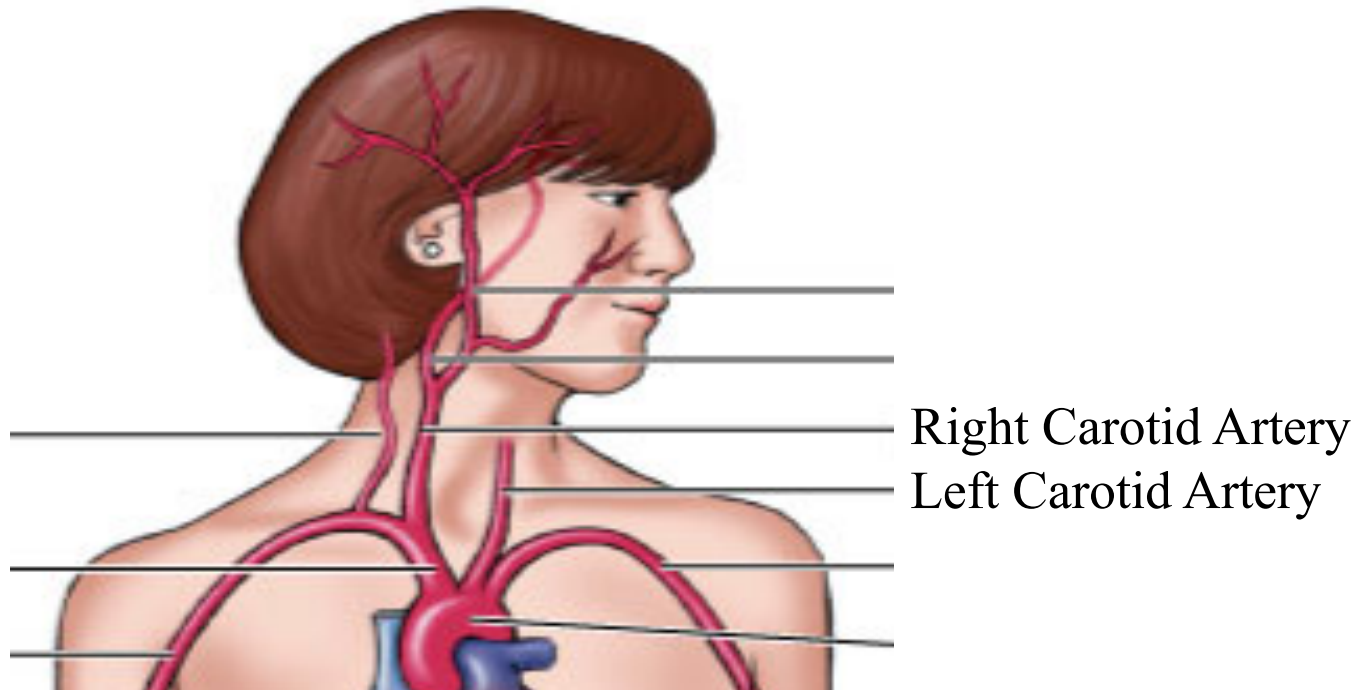
Arteries

Descending aorta Very large artery that is a continuation of the ascending aorta that branches off and travels inferiorly.



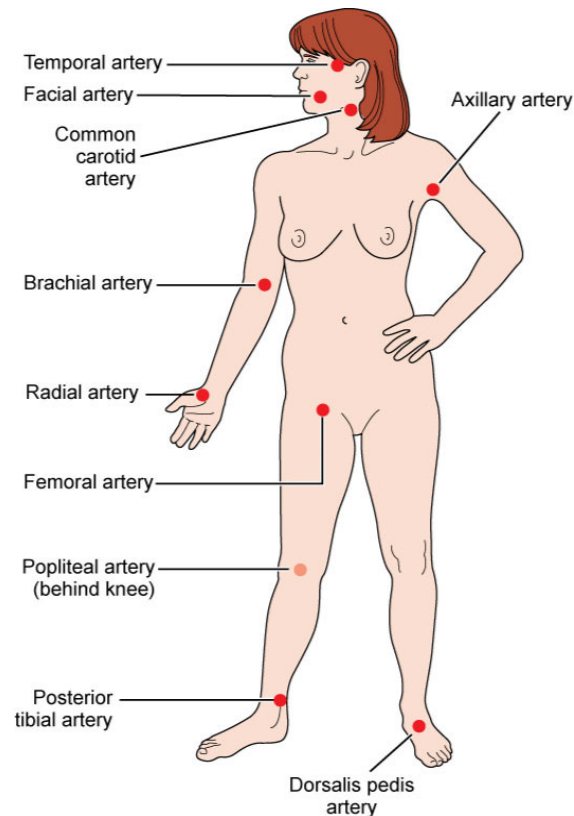
Arteries

Common carotid arteries Two arteries located in the throat.



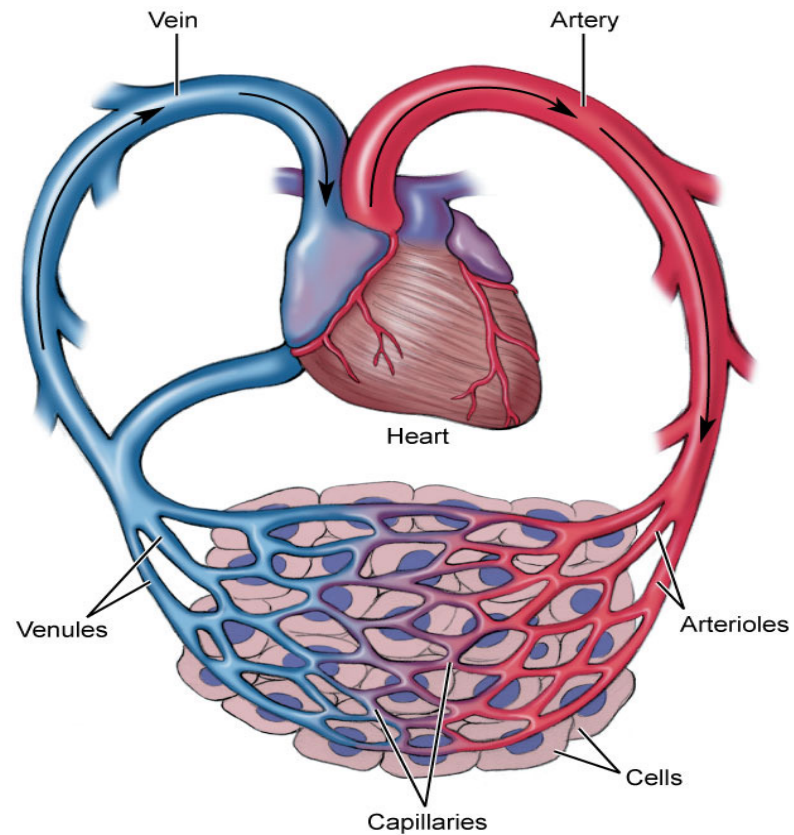
Arteries

Pulse Expansion effect of arteries that occurs when the left ventricle contracts and produces a _____ wave _____ of blood that surges through and expands arterial walls.



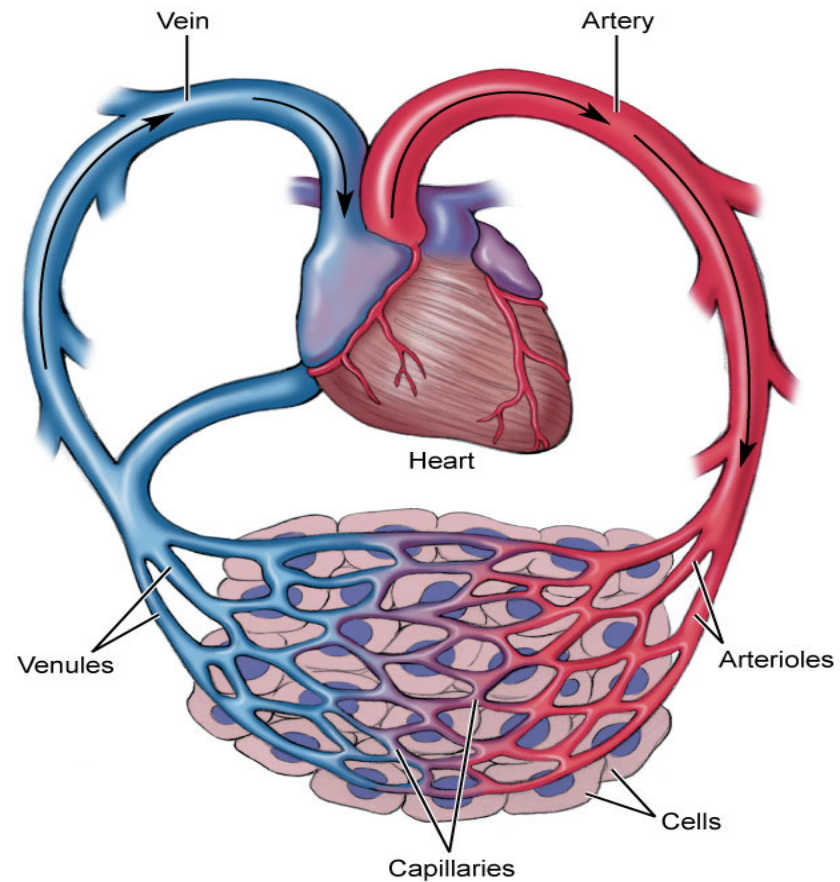
Capillaries

Capillary Vessel between an arteriole and a venule. Possesses a thin, permeable membrane for efficient gas exchange with tissues.



Capillaries

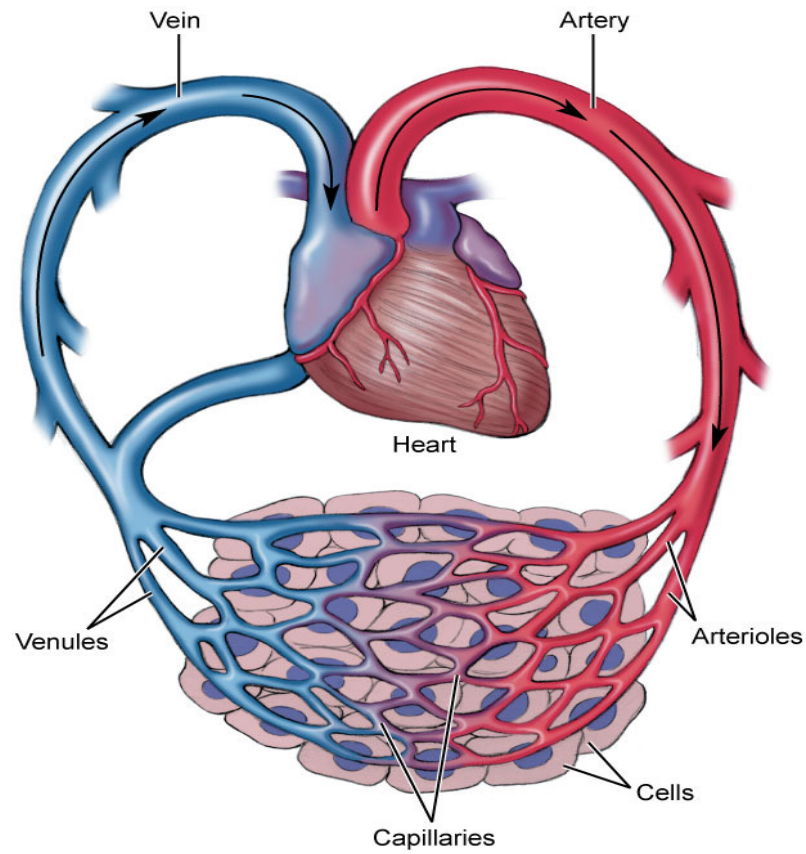
Microcirculation Flow of blood through a capillary bed.



Veins

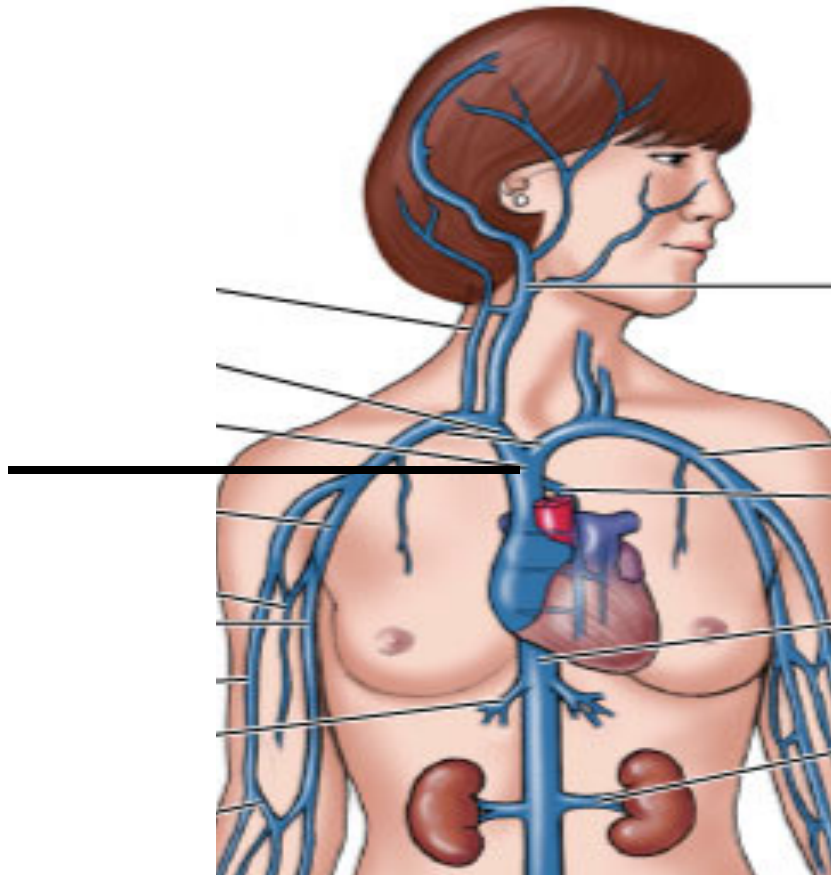
Vein Vessel that carries blood toward the heart.

Venules Small-sized vein that connects with capillaries.



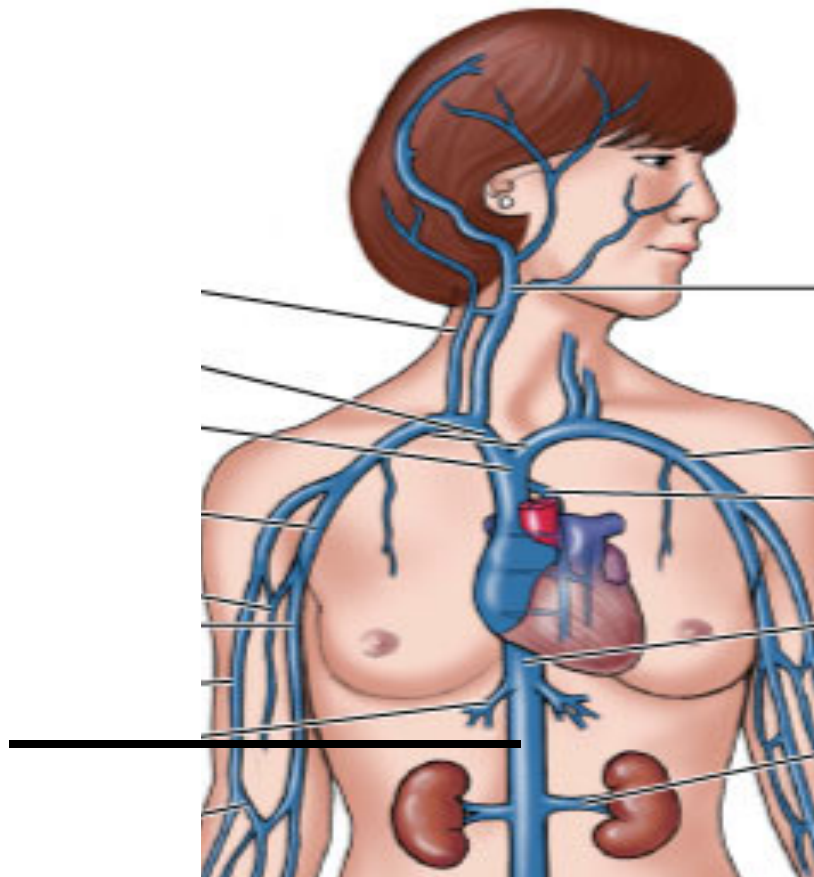
Veins

Superior vena cava Very large vein that empties blood from the head and arms into the right atrium.



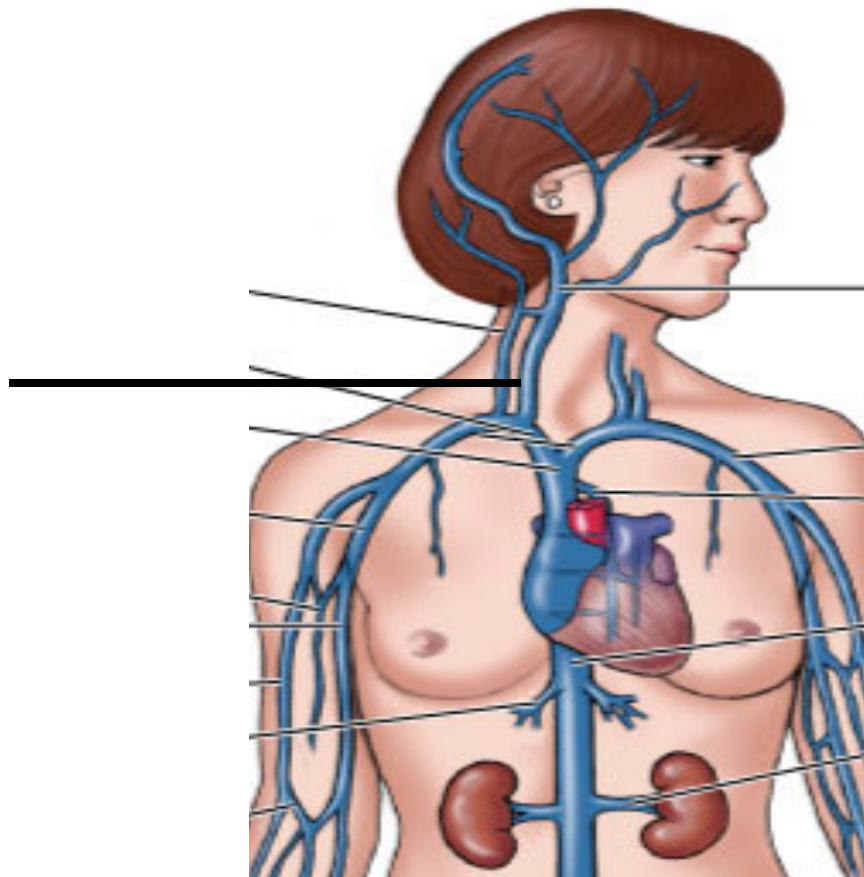
Veins

Inferior vena cava Very large vein that empties blood from the abdomen into the right atrium.



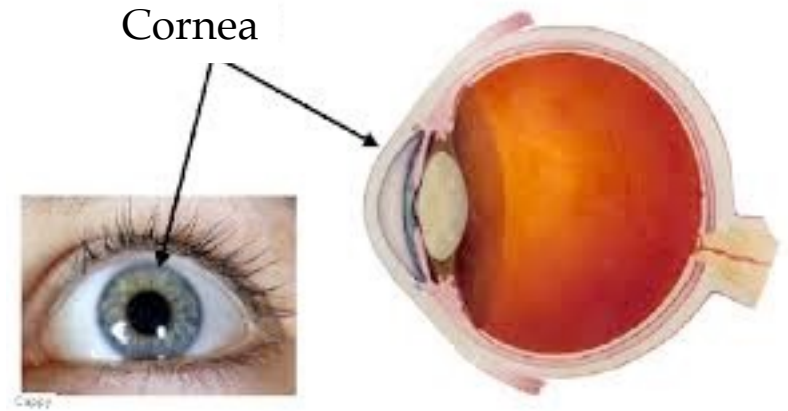
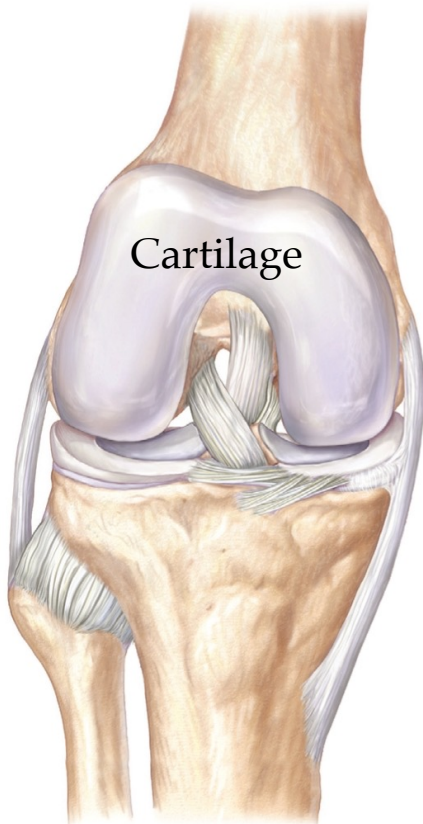
Veins

Jugular Vein in the throat that drains blood from the face, head, neck, and brain.

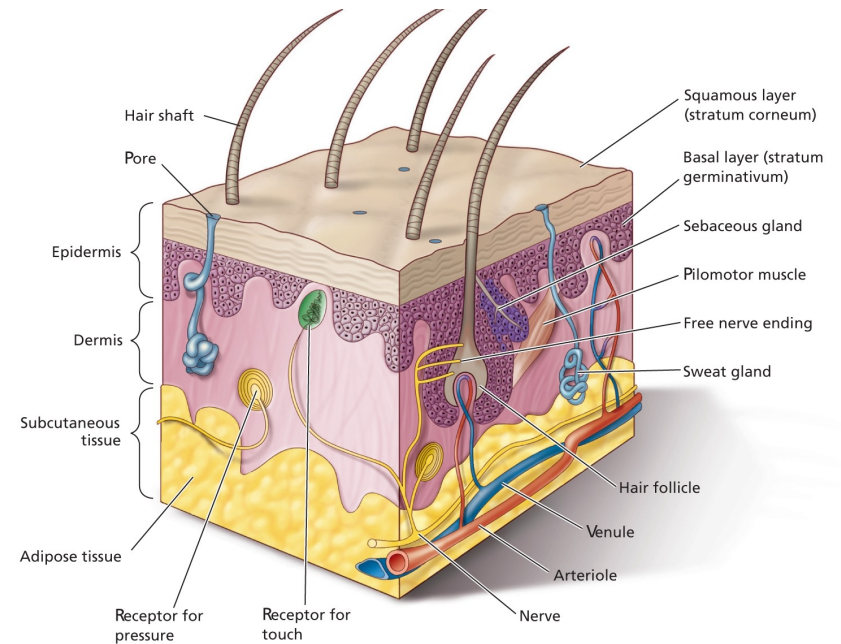


Blood Vessels

Avascular Lacking blood vessels.



Epithelial tissues of the epidermis





Venous Return

Venous return Veins return blood to the heart passively.

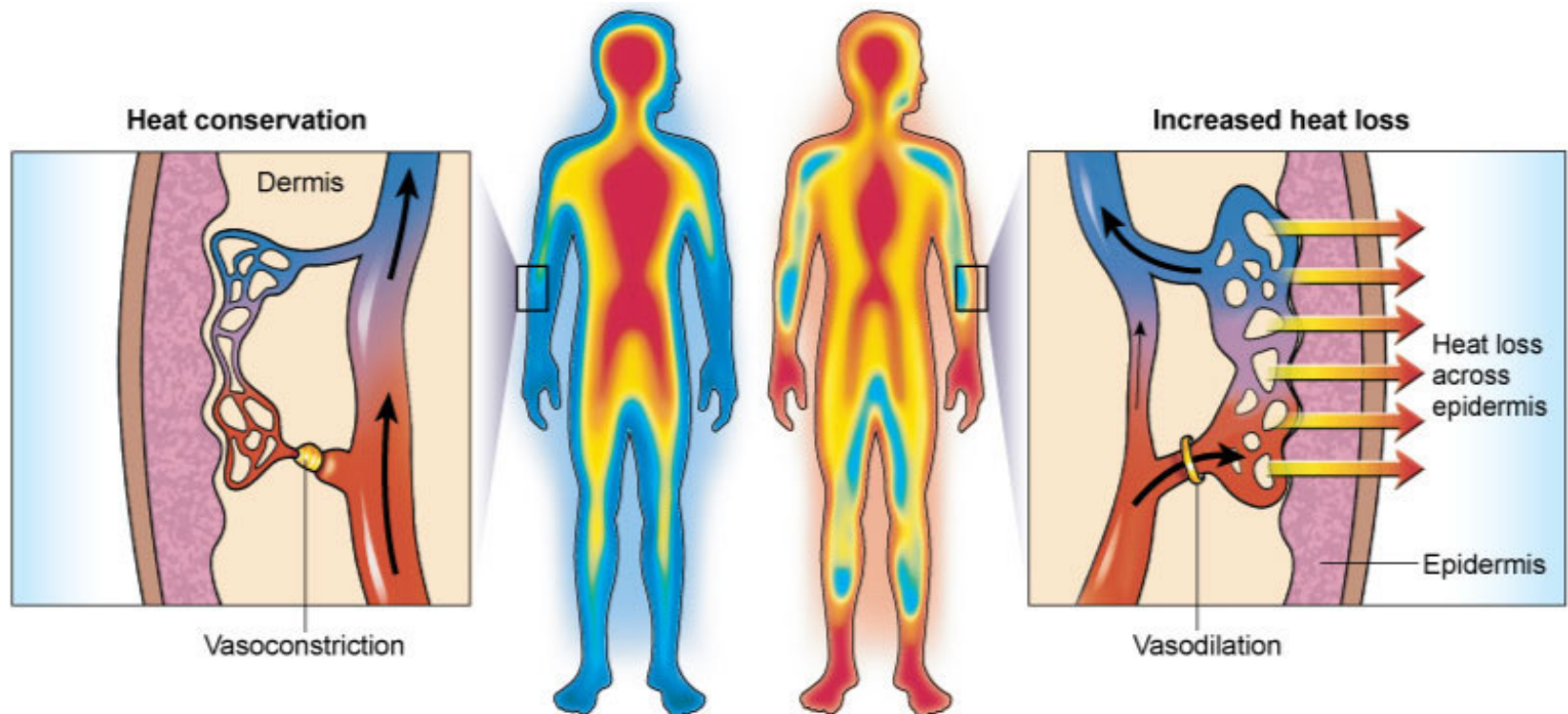
Venomotor tone

Skeletal muscle pump

Respiratory pump

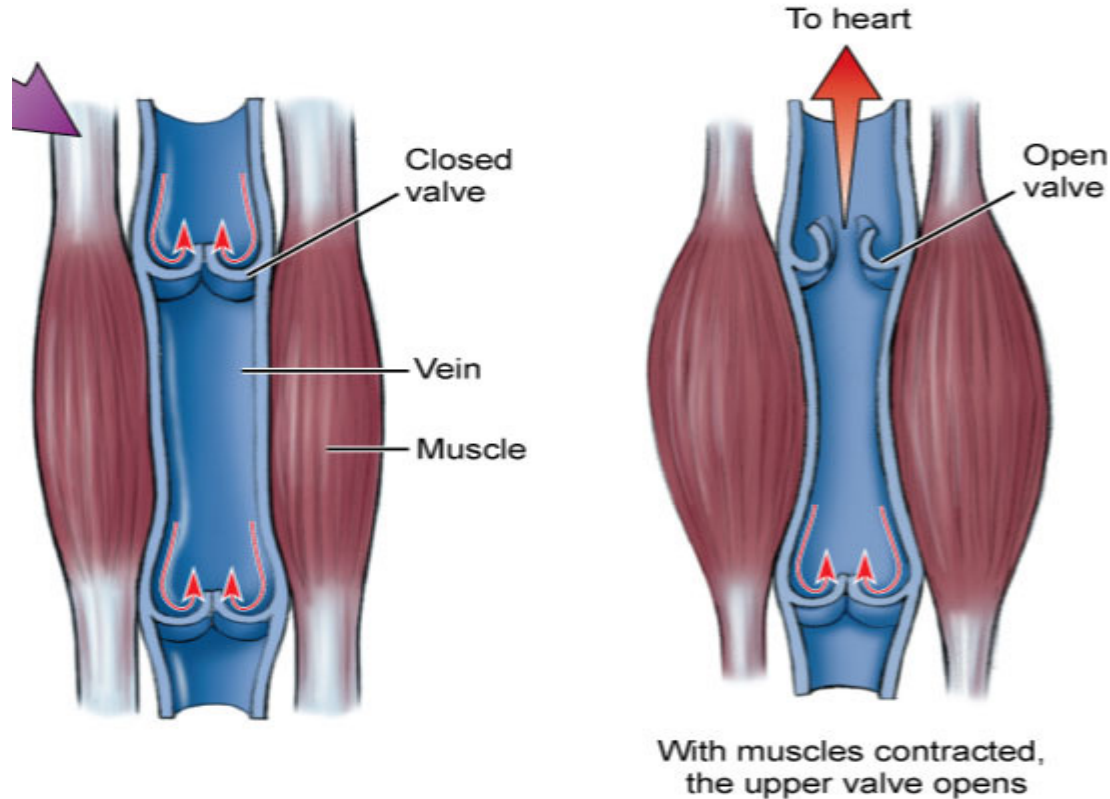
Venous Return

Venomotor tone Changes in smooth muscle tone in the walls of veins can increase or decrease venous circulation.



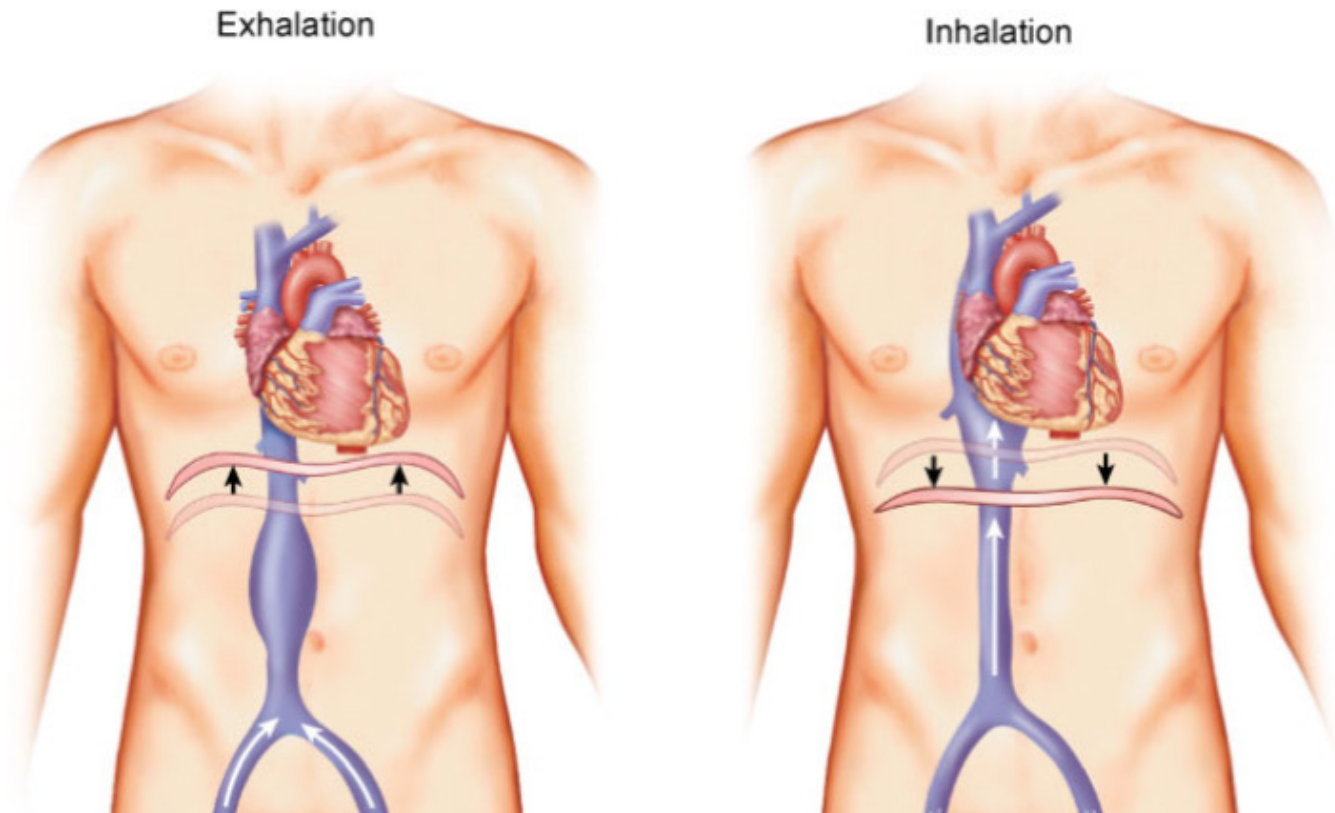
Venous Return

Skeletal muscle pump Skeletal muscle contract and squeeze venous walls which moves blood toward the heart.



Venous Return

Respiratory pump Pressure changes in the thorax and abdomen, caused by skeletal muscular contractions of breathing muscles that act as a mechanism to assist venous return.





Blood Pressure

Systolic pressure

Diastolic pressure

High blood pressure

Average blood pressure

Low blood pressure



Blood Pressure

Blood pressure Pressure exerted by blood on the blood vessel walls.

Systolic pressure Maximal pressure in blood pressure measurement.

Occurs when the left ventricle contracts.

Diastolic pressure Lowest pressure in blood pressure measurement.

Occurs when the left ventricle relaxes.



Blood Pressure

High blood pressure (AKA: hypertension) Persistently more than 140/90.

Average blood pressure 120/80.

Low blood pressure (AKA: hypotension) Persistently less than 90/60.



Paths of Circulation

Pulmonary circuit

Systemic circuit



Paths of Circulation

Pulmonary circuit Circuit that brings de-oxygenated blood from the right ventricle of the heart to the lungs to release carbon dioxide and regain oxygen, then transports the oxygenated blood to the left atrium.



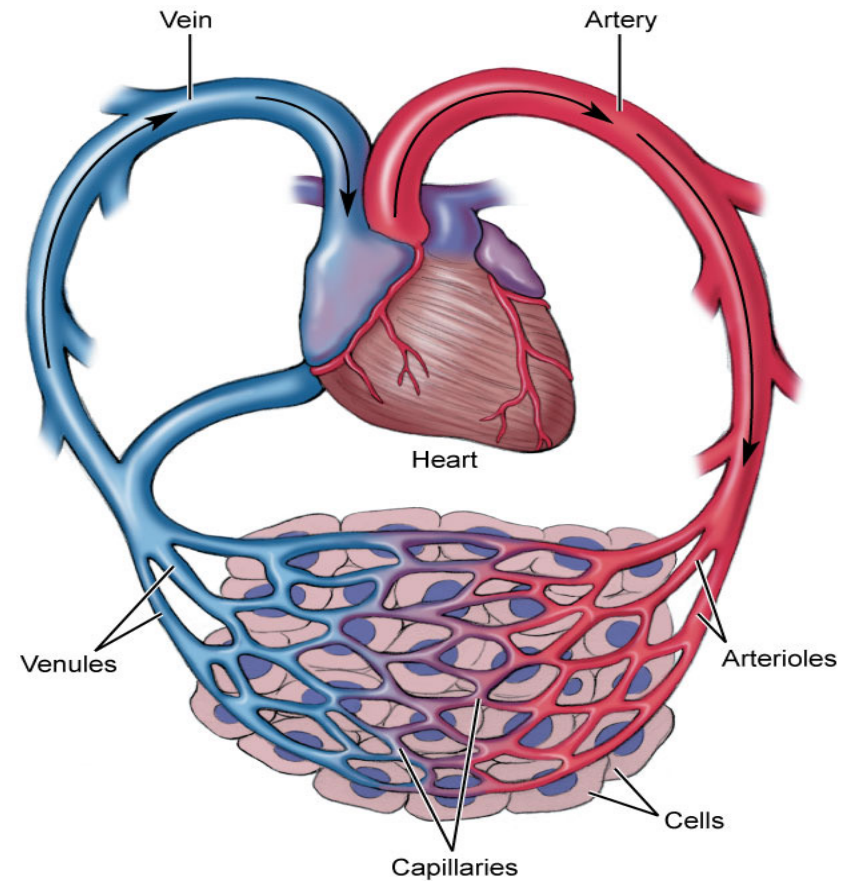
Paths of Circulation

Systemic circuit Circuit that brings oxygenated blood from the left ventricle of the heart through numerous arteries into the capillaries, then moves it through the veins and returns the now de-oxygenated blood to the right atrium of the heart.

Paths of Circulation

Systemic Circuit

1. Left ventricle
2. Aortic semilunar valve
3. Aorta
4. Ascending and descending aortae
5. Arteries
6. Arterioles
7. Capillaries
8. Venules
9. Veins
10. Inferior and superior venae cavae
11. Right atrium





36a A&P: Cardiovascular System - Blood Vessels and Paths of Circulation