




73a Orthopedic Massage: Introduction - Piriformis & Sacroiliac




73a Orthopedic Massage:

Introduction - Piriformis & Sacroiliac

Class Outline

5 minutes	Attendance, Breath of Arrival, and Reminders
10 minutes	Review of Lateral Rotators of the hip
25 minutes	Lecture: Piriformis syndrome and Sacroiliac dysfunction
15 minutes	Active study skills:
60 minutes	Total



73a Orthopedic Massage: Introduction - Piriformis & Sacroiliac Class Outline

Quizzes:

- 75a Kinesiology Quiz (gluteals, erectors, lats, biceps femoris, quadratus femoris, piriformis)
- 78a Kinesiology Quiz (erectors, lats, quadratus lumborum, multifidi, rotatores)

Spot Checks:

- 75b Orthopedic Massage: Spot Check – Piriformis and Sacroiliac **Bring your grading sheet A: 97**
- 78b Orthopedic Massage: Spot Check – Low Back Pain **Bring your grading sheet for evaluation A: 99**

Assignments:

- 85a Orthopedic Massage: Outside Messages (2 due at the start of class)

Preparation for upcoming classes:

- 74a MBLEx Prep
 - Using ABMP Exam Coach, select “Study Subjects”, and then “Massage Theory”
 - For each of the 4 Massage Theory Topics, “Take a Practice Quiz” 4 times (16 total)
 - Research any words or concepts that aren’t clear on the Internet and bring what you find to class
- 74b Orthopedic Massage: Technique Review and Practice - Piriformis and Sacroiliac
 - Packet J: 55-62 and 63-64.



Classroom Rules

Punctuality - everybody's time is precious

- Be ready to learn at the start of class; we'll have you out of here on time
- Tardiness: arriving late, returning late after breaks, leaving during class, leaving early

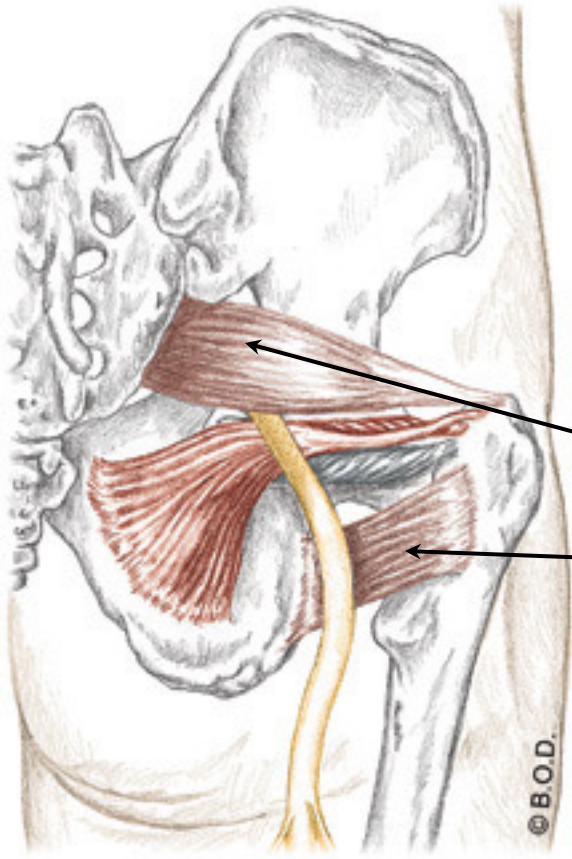
The following are not allowed:

- Bare feet
- Side talking
- Lying down
- Inappropriate clothing
- Food or drink except water
- Phones that are visible in the classroom, bathrooms, or internship

You will receive one verbal warning, then you'll have to leave the room.

Lateral Rotators of the Hip

Trail Guide, Page 328



Sometimes known as the “deep six” or the “deep lateral rotators”.

The lateral rotators are small muscles located deep to the gluteus maximus.

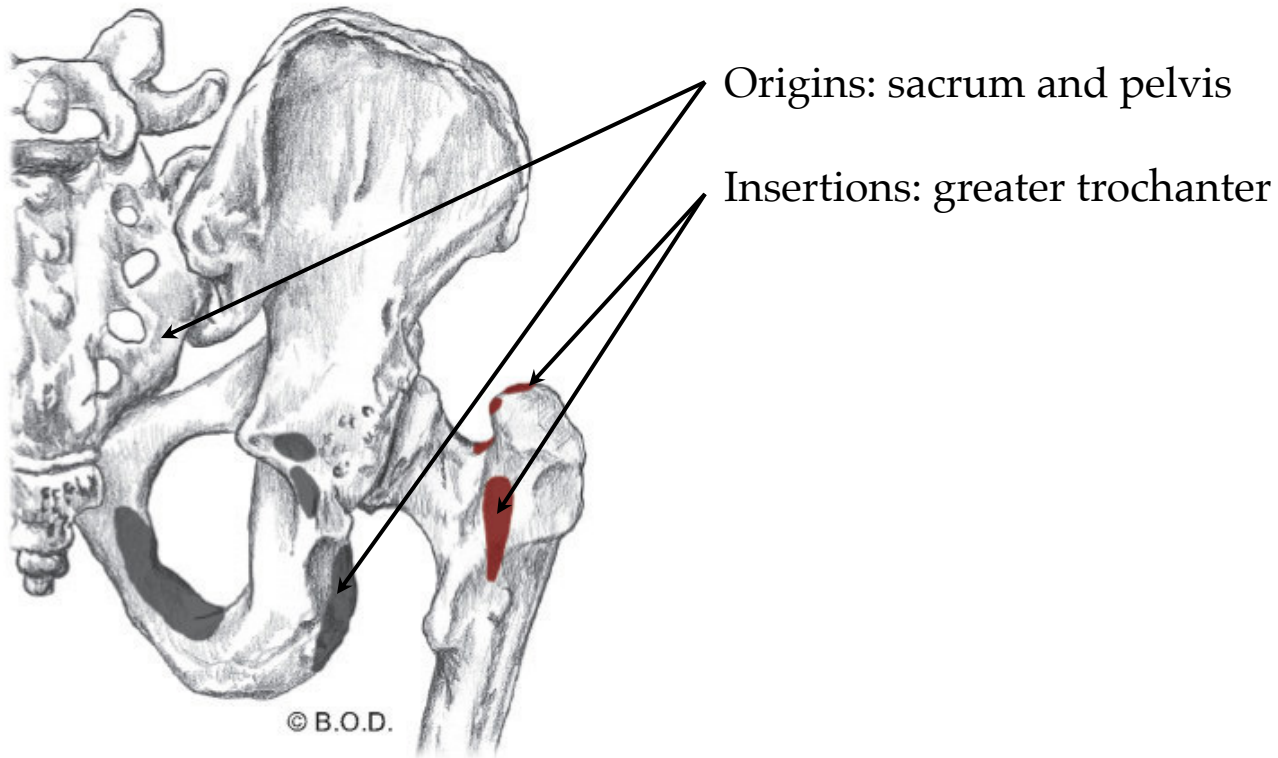
The sciatic nerve travels through the area of the deep lateral rotators.

Piriformis and **Quadratus Femoris** are the most easily palpated.

Posterior View

Lateral Rotators of the Hip

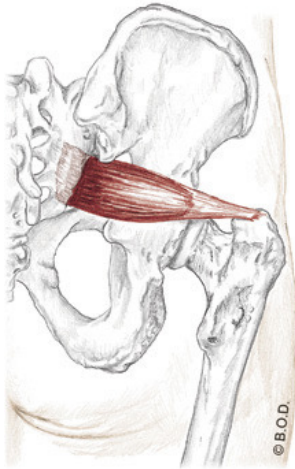
Trail Guide, Page 328



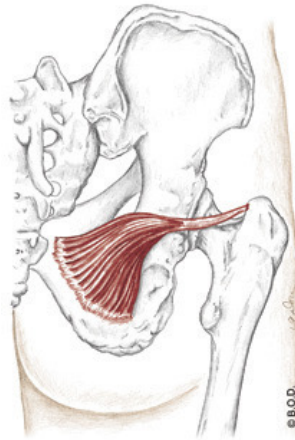
Posterior View

Lateral Rotators of the Hip

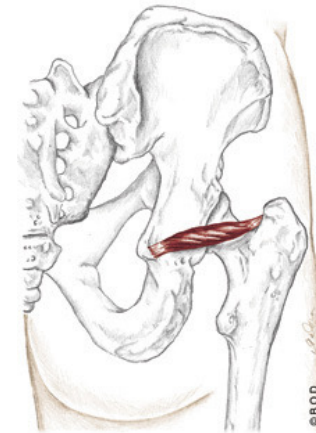Trail Guide, Page 328



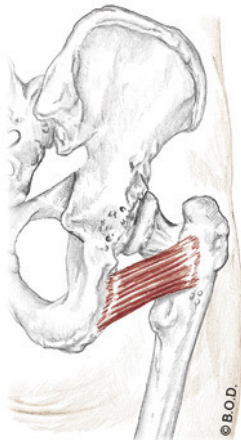
Piriformis
(posterior view)



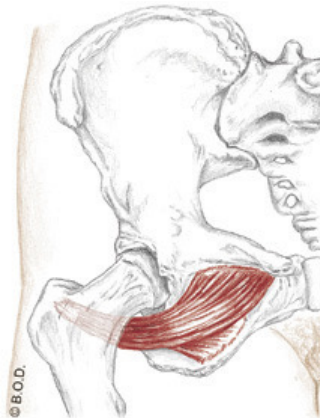
Obturator Internus
(posterior view)



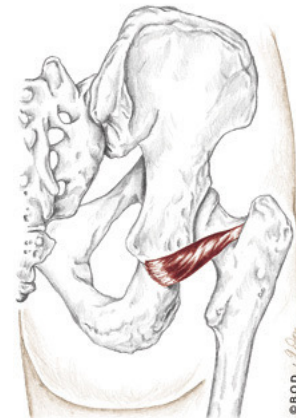Gemellus Superior
(posterior view)



Quadratus Femoris
(posterior view)



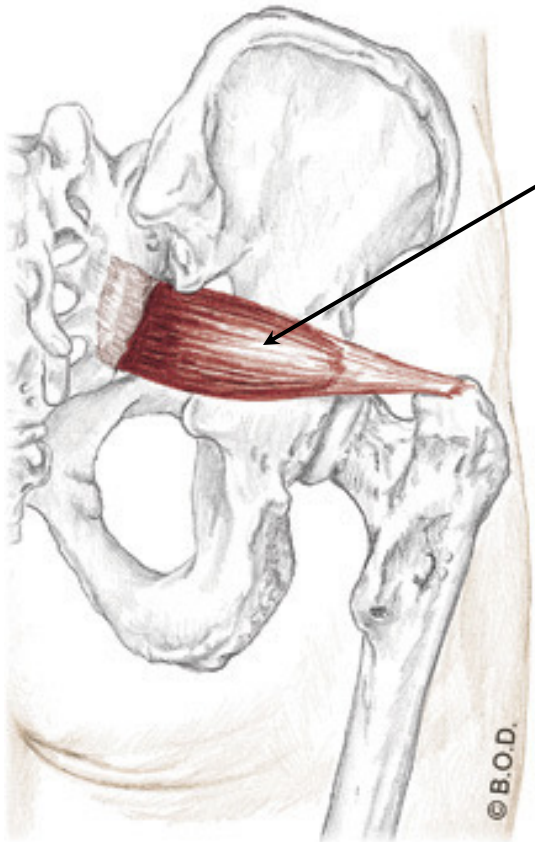
Obturator Externus
(anterior view)



Gemellus Inferior
(posterior view)

Piriformis

Trail Guide, Page 326



Piriformis originates on the anterior aspect of the sacrum.

It is often implicated in nerve pain radiating down the leg (AKA: piriformis syndrome).

Piri means *pear*.

Formis means *form of* or *shaped*.

Posterior View

Piriformis, page 328

A Laterally rotate the hip (coxal joint)

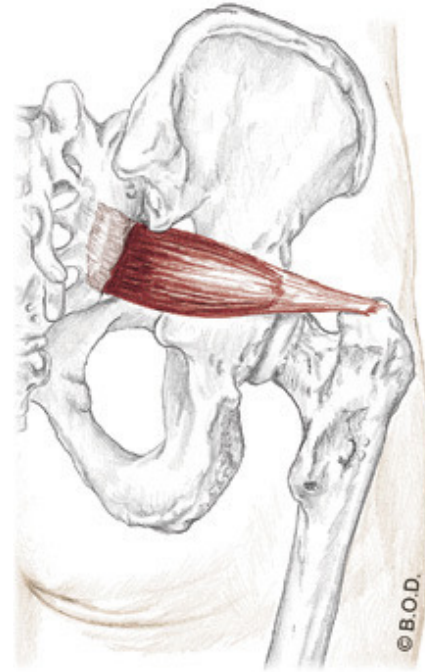
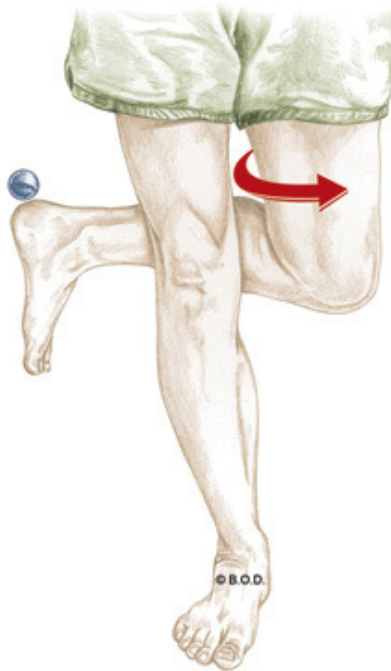
Abduct the hip (coxal joint) when it is flexed

Anterior surface of sacrum

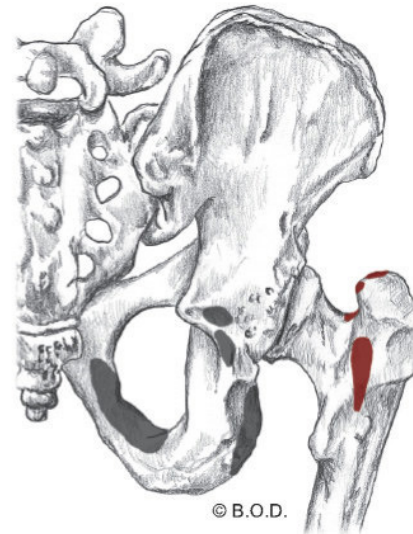O

Superior aspect of greater trochanter

I



Posterior View



Piriformis, page 328

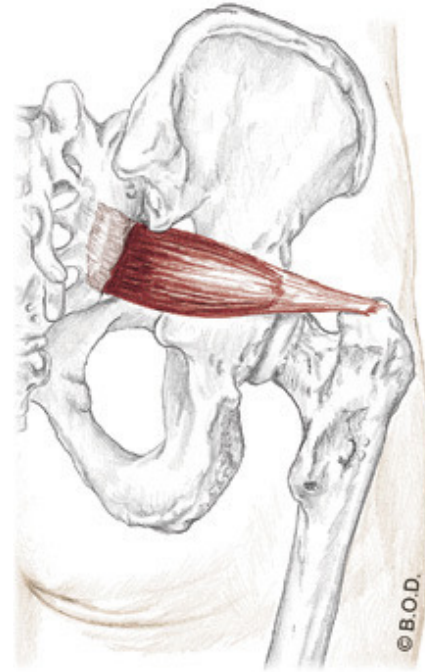
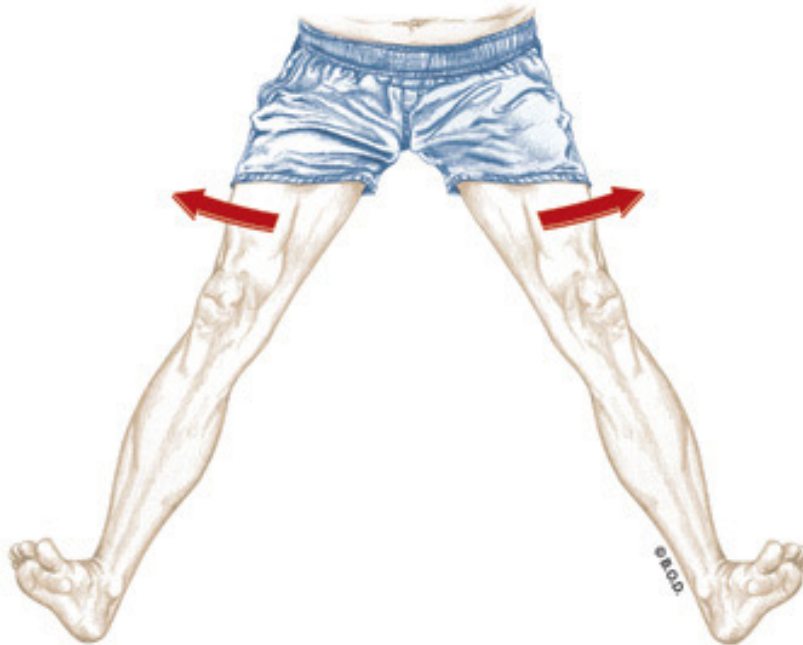A Laterally rotate the hip (coxal joint)

Abduct the hip (coxal joint) when it is flexed

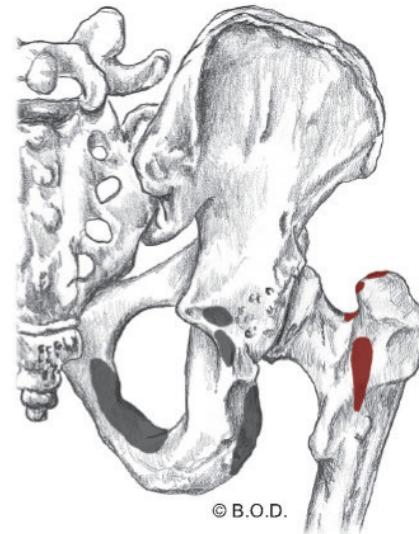
Anterior surface of sacrum

O

Superior aspect of greater trochanter



Posterior View



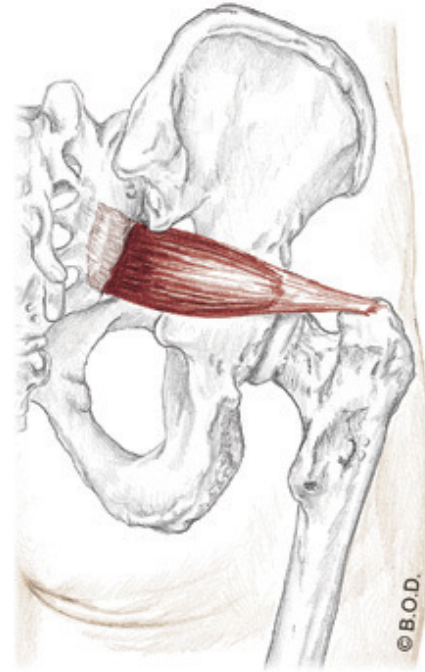
Piriformis, page 328

A Laterally rotate the hip (coxal joint)

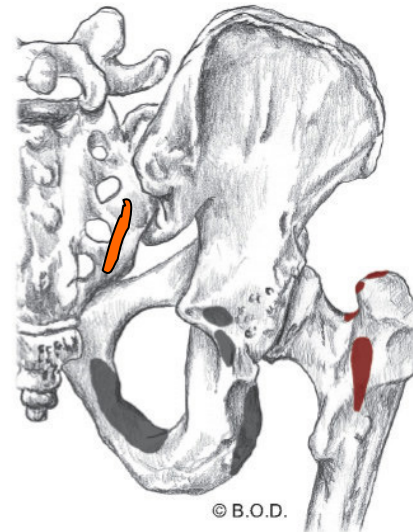
Abduct the hip (coxal joint) when it is flexed

O Anterior surface of sacrum

I Superior aspect of greater trochanter



Posterior View



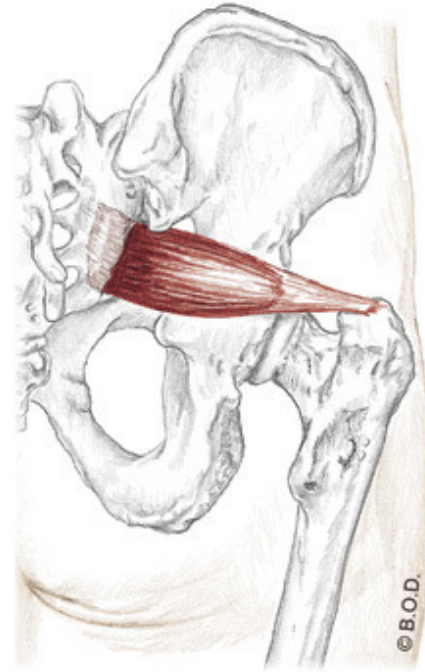
Piriformis, page 328

A Laterally rotate the hip (coxal joint)

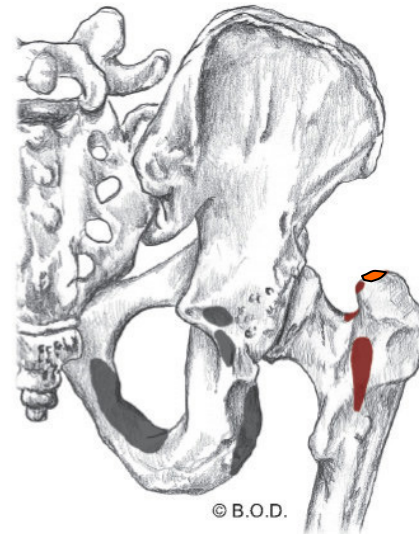
Abduct the hip (coxal joint) when it is flexed

O Anterior surface of sacrum

I Superior aspect of greater trochanter

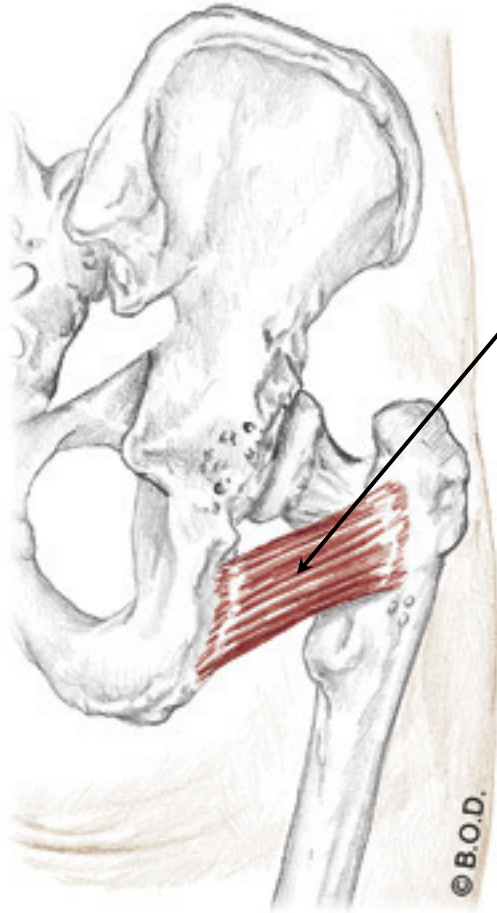


Posterior View



Quadratus Femoris

Trail Guide, Page 326



Posterior View

Quadratus Femoris originates from the lateral border of the ischial tuberosity.

Quadratus means *four-sided*.

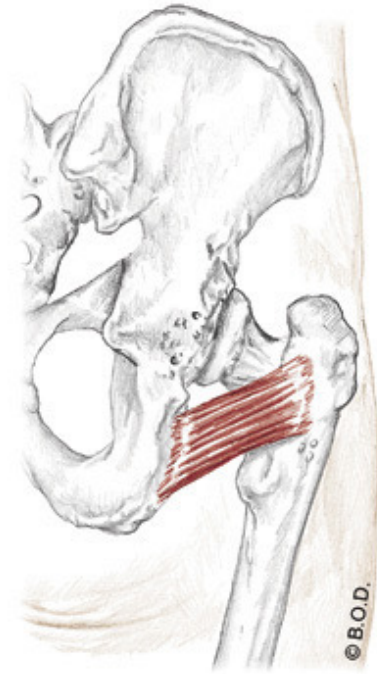
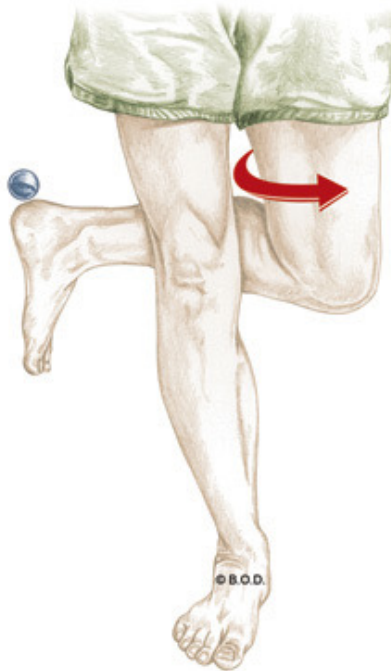
Femoris means *femur*.

Quadratus Femoris, page 328

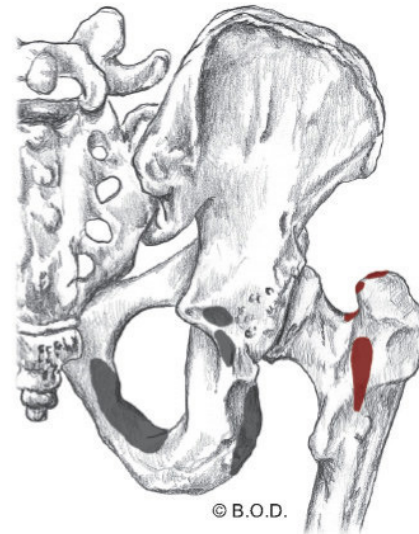
A Laterally rotate the hip (coxal joint)

O Lateral border of ischial tuberosity

I Intertrochanteric crest, between the greater and lesser trochanters



Posterior View

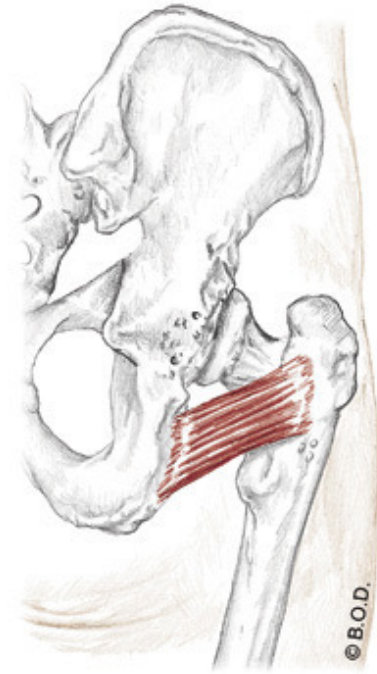


Quadratus Femoris, page 328

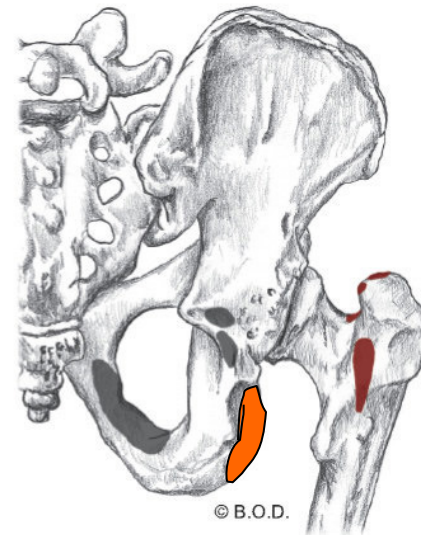
A Laterally rotate the hip (coxal joint)

O Lateral border of ischial tuberosity

I Intertrochanteric crest, between the greater and lesser trochanters



Posterior View

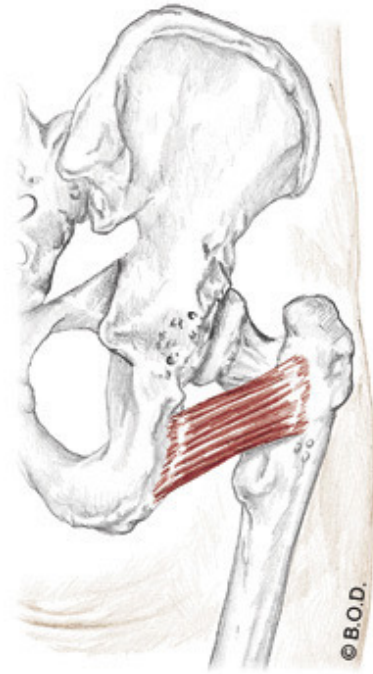


Quadratus Femoris, page 328

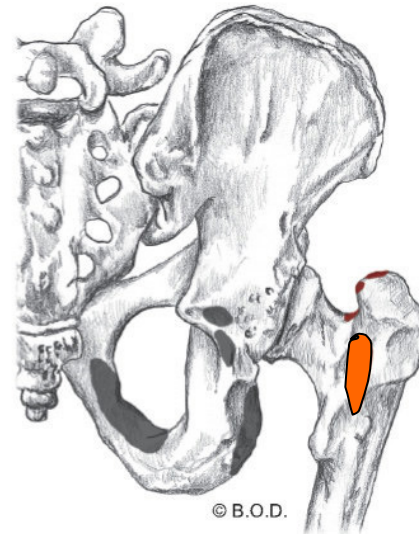
A Laterally rotate the hip (coxal joint)

O Lateral border of ischial tuberosity

I Intertrochanteric crest, between the greater and lesser trochanters



Posterior View





73a Orthopedic Massage: Introduction - Piriformis & Sacroiliac

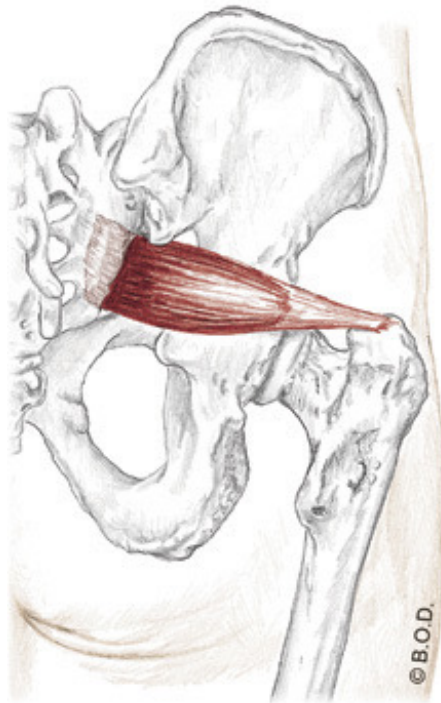
Packet J - 49



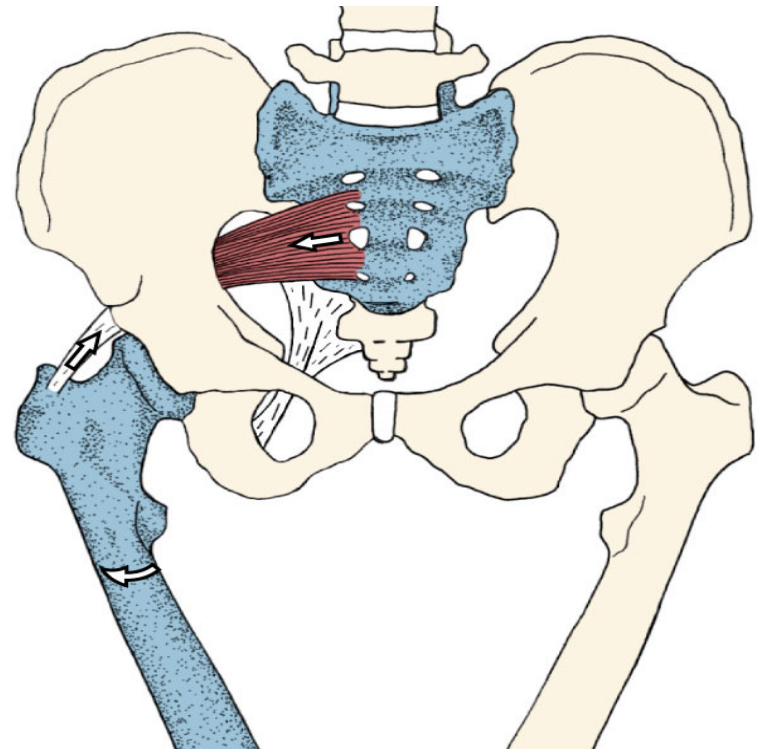
Piriformis Syndrome

Piriformis Syndrome

Piriformis syndrome Entrapment of one or both divisions of the sciatic nerve by the piriformis muscle in the gluteal region.



Posterior View

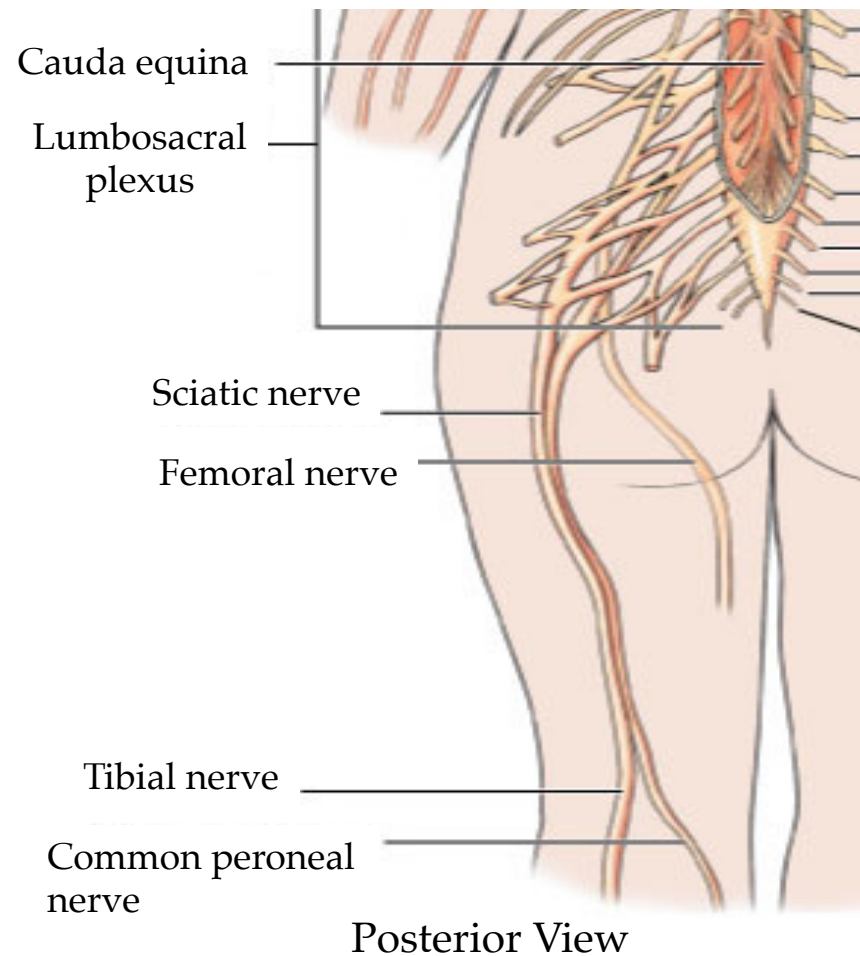


Anterior View

Piriformis Syndrome

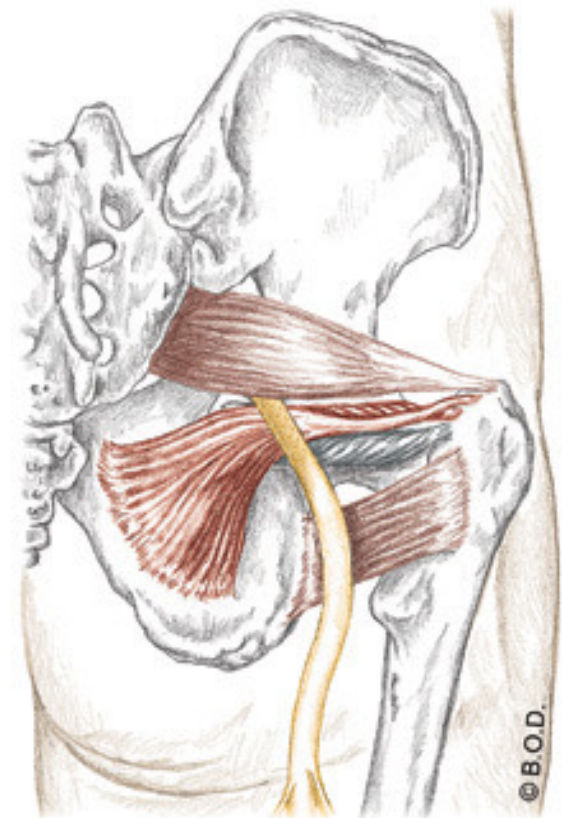
Divisions of the Sciatic Nerve

- Tibial nerve
- Peroneal nerve



Structures that Surround the Sciatic Nerve

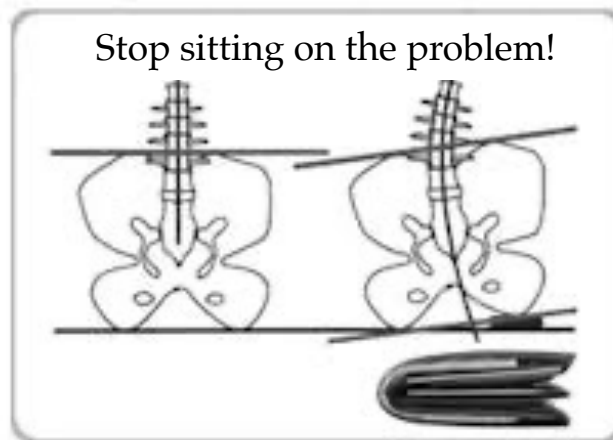
- Greater sciatic notch of the ilium (superior and lateral)
- Piriformis (superior)
- The other 5 deep lateral rotators (inferior)
 - Superior gemellus
 - Obturator internus
 - Obturator externus
 - Inferior gemellus
 - Quadratus femoris
- Sacrospinous ligament (inferior)



Posterior View

Activities That Exacerbate Piriformis Syndrome

- Sitting for long periods of time (sciatic nerve compression and local tissue ischemia)
- Sitting with a wallet in the back pocket (nerve compression)





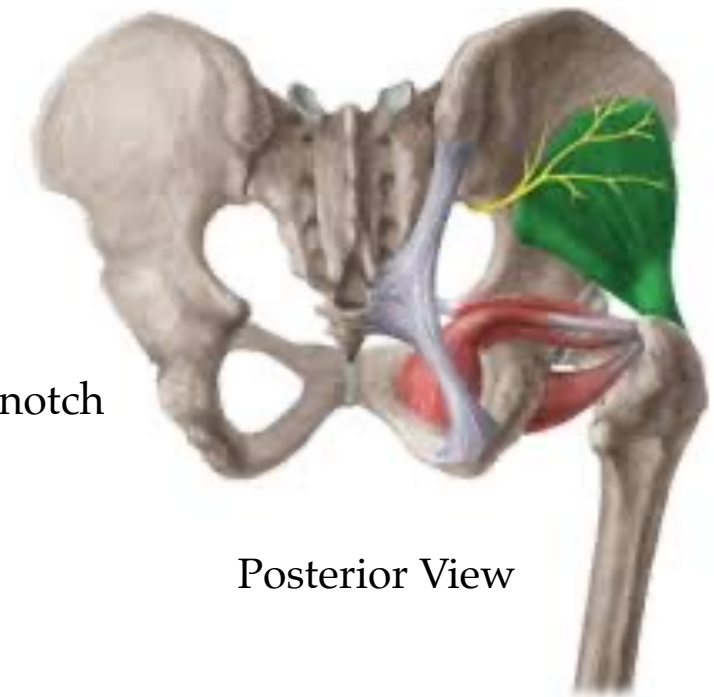
Symptoms of Piriformis Syndrome

- **Pain or paresthesia** (sensation of pins and needles) in the gluteal region that radiates down the posterior lower extremity
- **Low back pain** is also a common symptom. Treating it also is wise.

Symptoms of Piriformis Syndrome

- **Superior gluteal nerve entrapment**

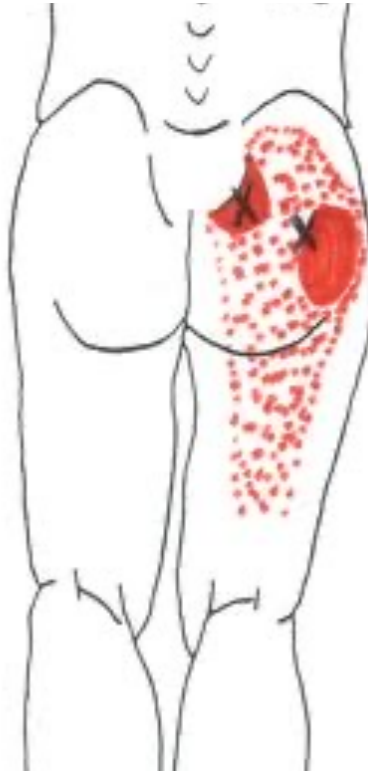- Also passes through the greater sciatic notch
- Travels superior to the piriformis
- Innervates the gluteals
- Nerve entrapment leads to aching buttock pain and weak hip abductors



Posterior View

Symptoms of Piriformis Syndrome

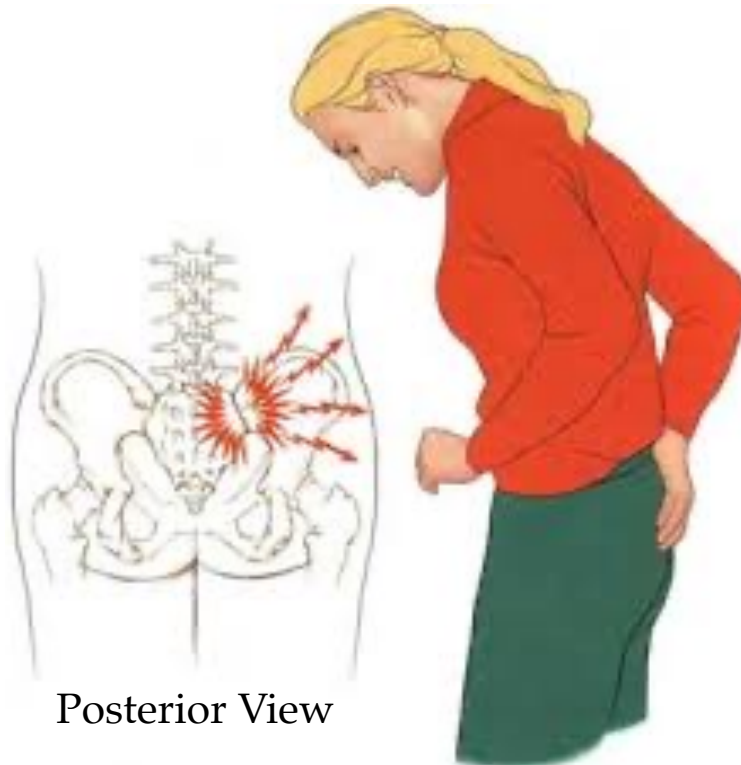
- **Myofascial trigger points in the piriformis**



Posterior View

Symptoms of Piriformis Syndrome

- **Sacroiliac joint dysfunction**
 - Similar, but no radiating pain down the lower extremity





Sciatic Nerve Anatomical Variations

- **10% of the population** One division of the sciatic nerve goes through the piriformis muscle. The other division passes inferior to the muscle.
- **2-3% of the population** One division passes superior while the other division passes inferior to the piriformis.
- **1% of the population** Both divisions pass through the piriformis.
- **Note:** It is not necessarily true that an individual with the sciatic nerve passing through the piriformis would be in serious discomfort all the time.



Sacroiliac Joint Dysfunction



Sacroiliac Joint Dysfunction

Sacroiliac joint dysfunction (S.I.) Diffused pain felt in the lumbar or sacral region.

- Caused by a number of problems at the sacroiliac joint with similar symptoms
- Pain may be referred to the groin or posterior leg
- Can be mistaken for lumbar disc pathology



Sacroiliac Joint Dysfunction Onset

- Acute injury such as an automobile accident
- Chronic dysfunctional biomechanics such as gait alteration or leg length discrepancy

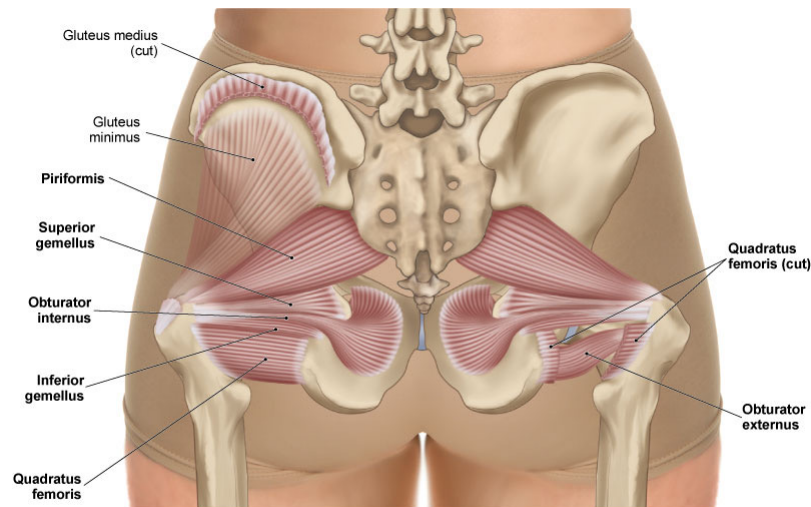


Sacroiliac Joint Dysfunction Etiology

- **Sprain** Ligament fiber damage that results in a tear or permanent elongation.
- Friction between the articular surfaces
- Joint misalignment or joint “locking”

Sacroiliac Joints

- Are the joints between the sacrum and ilia of the pelvic bones

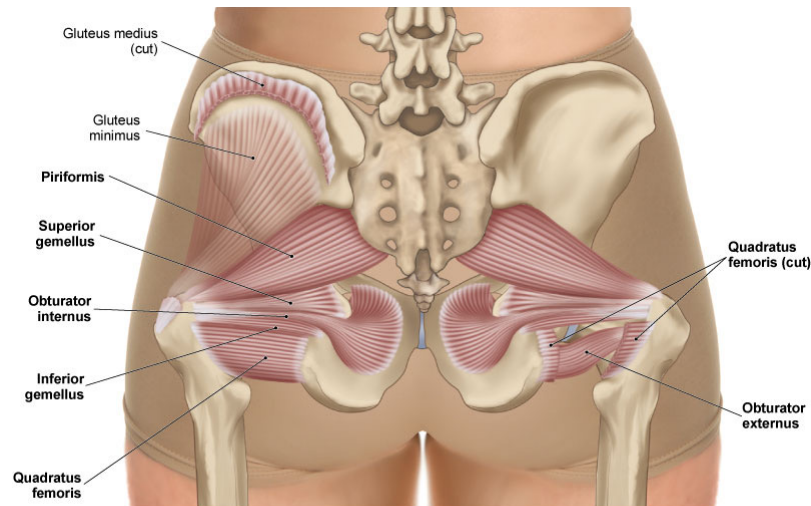


Posterior View

- Have no muscles that directly span the joints
- Use lumbosacral muscles, ligaments, and fascia to control motion
- Have rough surfaces to help produce stability

Sacrum

- Acts as a wedge between the two pelvic bones

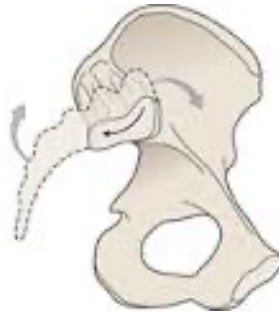

Posterior View

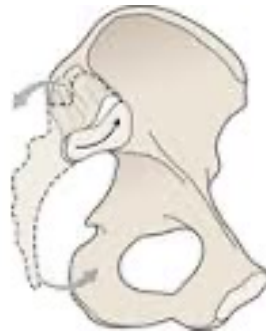- Holds the weight of the upper body
- Is held firmly in place by a tight webbing of ligaments
- Has very slight movement called nutation and counternutation

Nutation and Counternutation of the Sacrum

- **Nutation** Forward tipping of the superior surface of the sacrum.



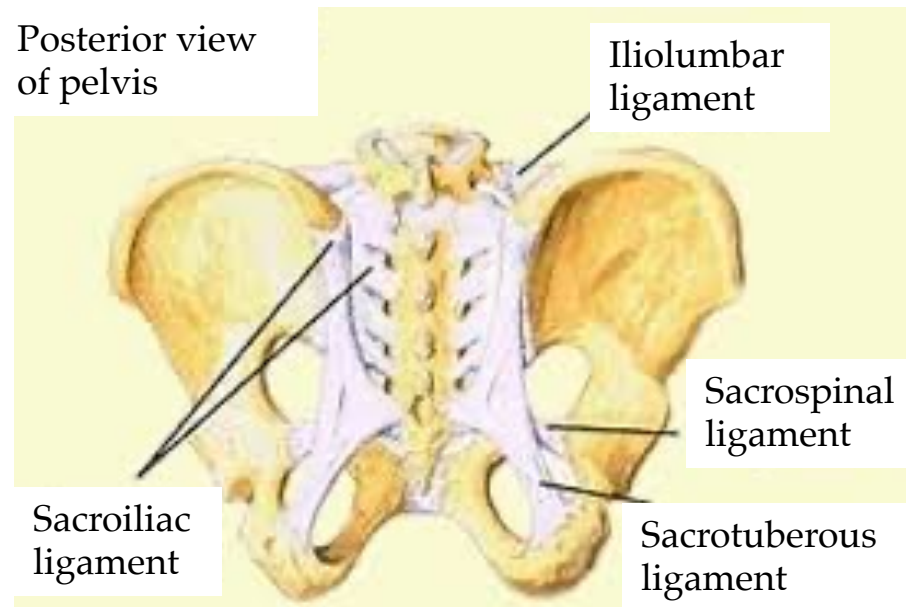
- **Counternutation** Backward tipping of the superior surface of the sacrum.



- Has a total range of 7-8 degrees in the sagittal plane
- Is essential for proper mechanics (walking, bending over, etc.)

S.I. Joint Ligaments

- Anterior sacroiliac
- Posterior sacroiliac (fascially connect to Piriformis)
- Iliolumbar
- Sacrotuberous (fascially connected to G. Max and Biceps Femoris)
- Sacrospinous





Traditional Treatments for Piriformis Syndrome and Sacroiliac Joint Dysfunction



Traditional Treatments for Piriformis Syndrome

- **Reduction or cessation of exacerbating activities**
 - Effective
- **Stretching and joint mobilization**
 - Variable effectiveness: don't take the stretch too far for too long.
- **Anti-inflammatory medication**
 - Variable effectiveness: inflammation may not be present
- **Surgery**
 - Variable effectiveness
- **Cryotherapy**
 - Variable effectiveness: only effective to a depth of 1 cm.



Traditional Treatments for S.I. Joint Dysfunction

- **Joint mobilization and manipulation**
 - Variable effectiveness: it's not clear why it reduces pain
- **Strength training and exercise programs**
 - Effective: stabilizes the joint
- **Proliferant injections**
 - Variable effectiveness: encourages growth of stabilizing fibrous tissue



Considerations and Cautions for Piriformis Syndrome and Sacroiliac Joint Dysfunction



Considerations and Cautions for Piriformis Syndrome

- Reduce exacerbating activities such as prolonged sitting or sitting with a wallet in the back pocket.
- If the client reports an exacerbation of symptoms during the treatment, modify the treatment. Treatment modification options:
 - Work near the origin and insertion to avoid compressing the site of nerve entrapment which can be in the muscle belly
 - Use Contract-Relax stretching techniques
- Completely and fully reduce hypertonicity in the gluteals prior to treating the piriformis so that treatment does not feel invasive.
- After increasing tissue pliability, stretching is key to improving flexibility and resetting the resting length for the muscles.



Considerations and Cautions for S.I. Joint Dysfunction

- Clients with S.I. joint dysfunction may need accommodations to lie comfortably on the massage table. Have several options available.
- Modify treatment if it exacerbates symptoms
- Post-treatment sensations:
 - Proprioception and joint position can change substantially when in a non-weight-bearing position after treatment.
 - Encourage clients to move slowly when getting up from the massage table.
 - Bearing weight through the S.I. joint again after treatment could be painful.



73a Orthopedic Massage: Introduction - Piriformis & Sacroiliac