



8b Kinesiology: AOIs - Posterior Lower Body



8b Kinesiology: AOIs - Posterior Lower Body Class Outline

10 minutes	Break Announce the return time and write it on the board.
5 minutes	Attendance Also project the “Class Reminders” slide.
20 minutes	Cadaver Video: Acland’s DVD Atlas of Human Anatomy
10 minutes	Break Announce the return time and write it on the board.
55 minutes	Anatomy in Clay
10 minutes	Break Announce the return time and write it on the board.
30 minutes	8b Kinesiology Quiz
60 minutes	Palpation
10 minutes	<u>Break down, clean up, and circle up</u>
3h 30m	Total Class Time



8b Kinesiology: AOIs - Posterior Lower Body Class Reminders

Quizzes and Exams:

- 8b Kinesiology Quiz **NOW!**
- 10a Exam (A-73, classes 1b, 2a, 2b, 3a, 3b, 4a, 5a, 6a, and 7a)

Preparation for upcoming classes:

- 9a H&H: Therapeutic Relationships - Introduction, Confidentiality, and Boundaries
 - Salvo: Pages 16-33
 - Packet H: 7-14
 - RQ Packet A: 132-133
- 9b Business: Introduction
 - Business Mastery, Chapters 1-3.
 - Packet B 1-30
 - Packet B-5 for assignment done in class

Classroom Rules

Cell Phones – Turn it off!



And put it away!



Classmarker

Grading your Quiz/Exam

- Classmarker will automatically grade your assignment and email you a copy of your completed test.
- Retakes. If you did not pass a test you may reserve space in the make-up room. If you are not making up hours, your time there will be at no cost. Retakes may be done at anytime before a student graduates. You may retake it for a grade up to a 70. These are done on paper copies.
- Please refer to your assignment grid on pages A: 29-32.



Cadaver Video

- [Gluteus Minimus and Medius](#)
- [Tensor Fasciae Latae and IT Tract](#)
- [Hamstrings and Gluteus Maximus](#)
- [Gastrocnemius and Soleus](#)
- Review of hip muscles



Coloring Anatomy

Write this list on the board and turn the projector off for now:

- Gluteus maximus
- Gluteus medius
- Gluteus minimus
- Biceps femoris
- Semimembranosus
- Semitendinosus
- Gastrocnemius
- Soleus



Palpation

Set Up by the Students

- Students form groups of 3.
- Each group sets up a table and gets 1 face cradle, 1 bolster, and 2 chairs.
- Receivers must remain clothed.
- There will be no need of sheets except for a face cradle cover.

Demo and Practice

- All of the students come to a central table to watch a brief demonstration of how to palpate one of the focus muscles:
 - List and identify the bony landmarks, especially origins and insertions.
 - List and identify the muscle bellies and tendons.
 - List and explain the actions.
 - Demo how to palpate the muscle while simultaneously offer resistance to the action, “Contract, relax. Contract, relax.”
 - The students go back to their table to practice the palpation.
 - 2 students palpate the third student collaboratively.
 - The instructor and assistant circulate to offer guidance and touch comparisons:
- This process repeats for each muscle that will be palpated.
- Once all the focus muscles have been palpated on the first student, repeat the process so that each student will palpate twice and be palpated once.

Gluteus maximus, page 315

A

All fibers:

Extend the hip (coxal joint)

Laterally rotate the hip (coxal joint)

Abduct the hip (coxal joint)

Lower fibers:

Adduct the hip (coxal joint)

O

Coccyx

Edge of sacrum

Posterior iliac crest

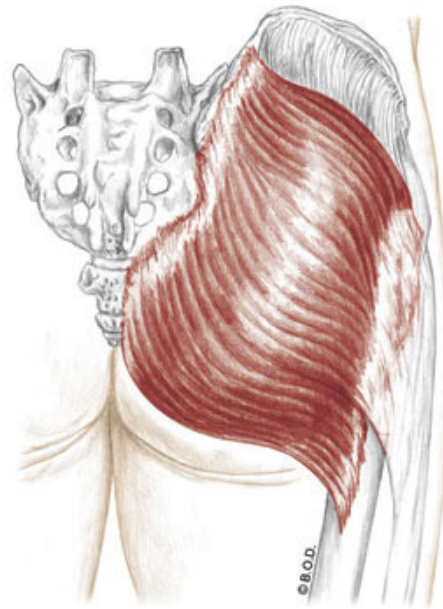
Sacrotuberous ligament

Sacroiliac ligament

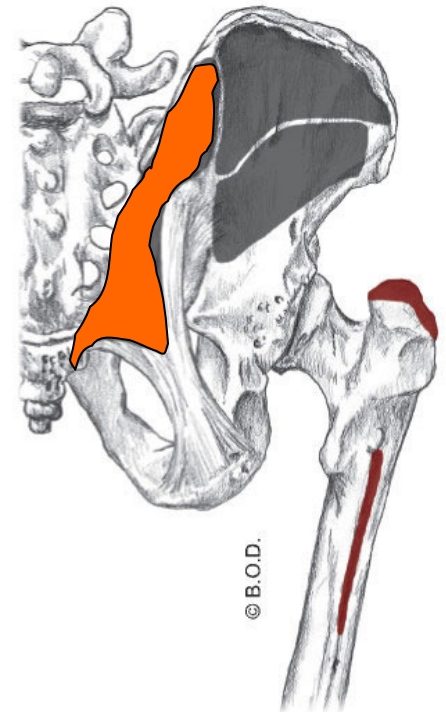
I

Iliotibial tract (upper fibers)

Gluteal tuberosity (lower fibers)



Posterior View



Gluteus maximus, page 315

A

All fibers:

Extend the hip (coxal joint)

Laterally rotate the hip (coxal joint)

Abduct the hip (coxal joint)

Lower fibers:

Adduct the hip (coxal joint)

O

Coccyx

Edge of sacrum

Posterior iliac crest

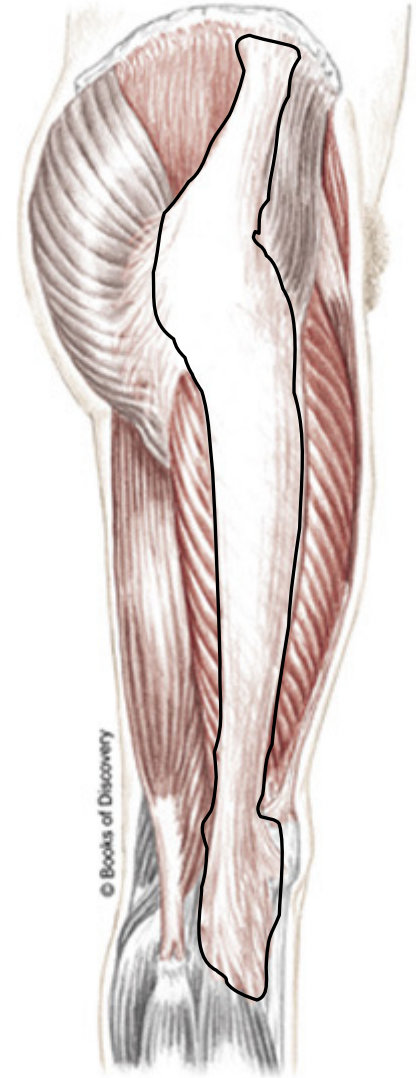
Sacrospinous ligament

Sacrospinous ligament

I

Iliotibial tract (upper fibers)

Gluteal tuberosity (lower fibers)



Posterior View

Gluteus medius, page 315

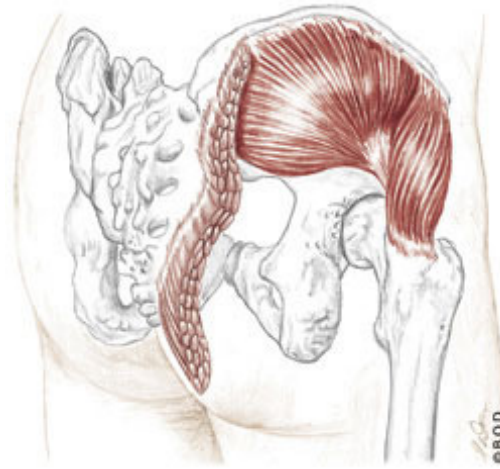
A All fibers:
Abduct the hip (coxal joint)

Anterior fibers:
Flex the hip (coxal joint)
Medially rotate the hip (coxal joint)

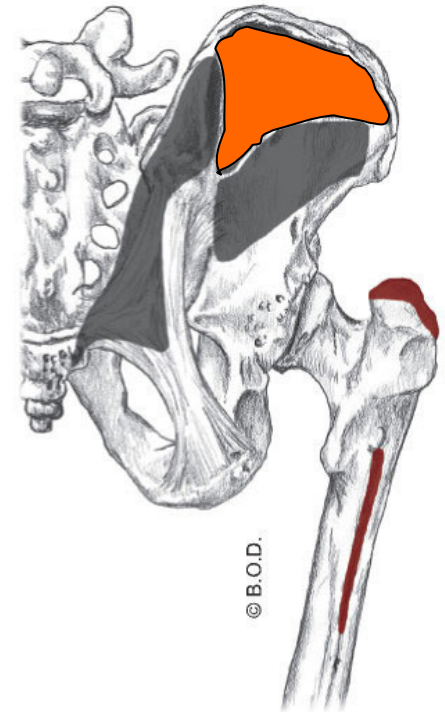
Posterior fibers:
Extend the hip (coxal joint)
Laterally rotate the hip (coxal joint)

O Gluteal surface of ilium, between posterior and anterior gluteal lines, just below the iliac crest

I Lateral aspect of greater trochanter



Posterior View

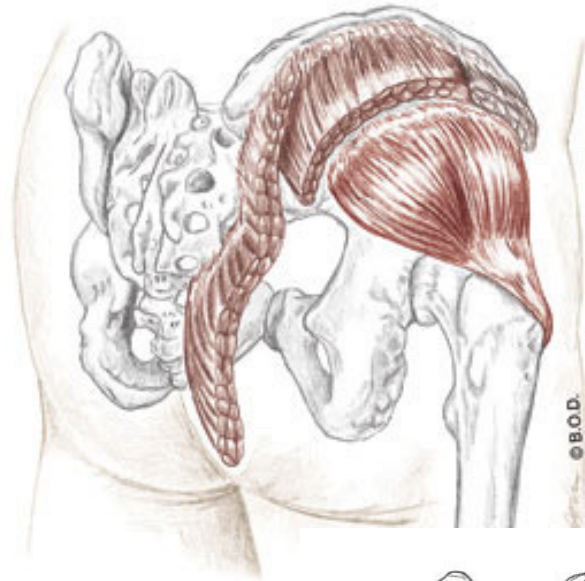


Gluteus minimus, page 316

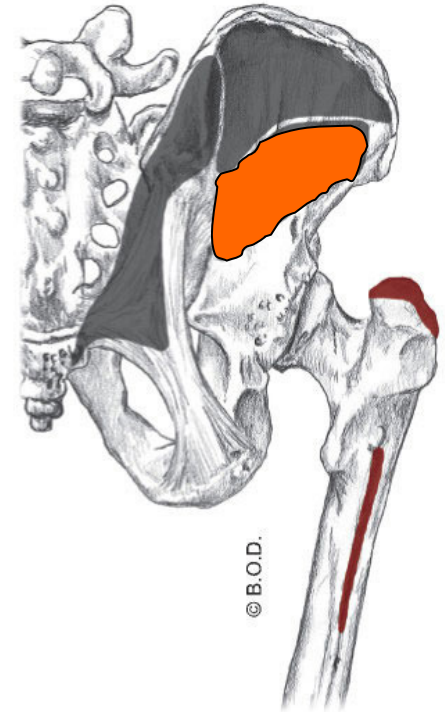
- A** **Abduct** the hip (coxal joint)
- Medially rotate** the hip (coxal joint)
- Flex** the hip (coxal joint)

O Gluteal surface of the ilium between the anterior and inferior gluteal lines

I Anterior aspect of greater trochanter



Posterior View



Biceps femoris, page 312

A **Flex** the knee (tibiofemoral joint)

Laterally rotate the flexed knee (T/F joint)

Long head:

Extend the hip (coxal joint)

Assist to **laterally rotate** the hip (coxal joint)

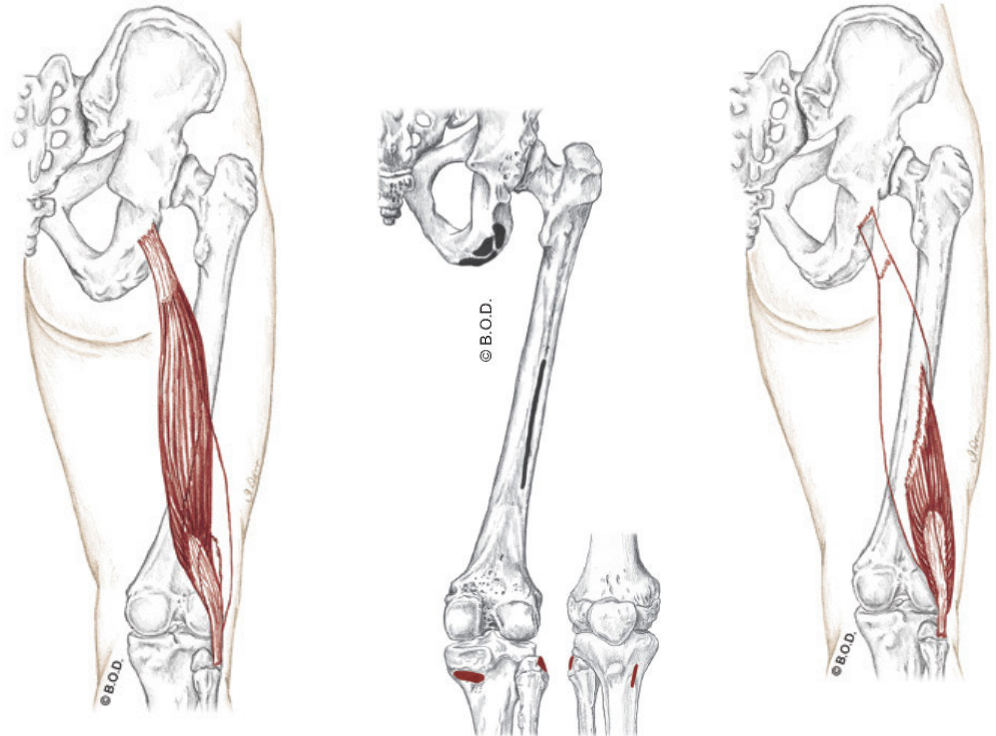
Tilt the pelvis posteriorly

O *Long head:* Ischial tuberosity

Short head: Lateral lip of linea aspera

I Head of the fibula

Posterior View

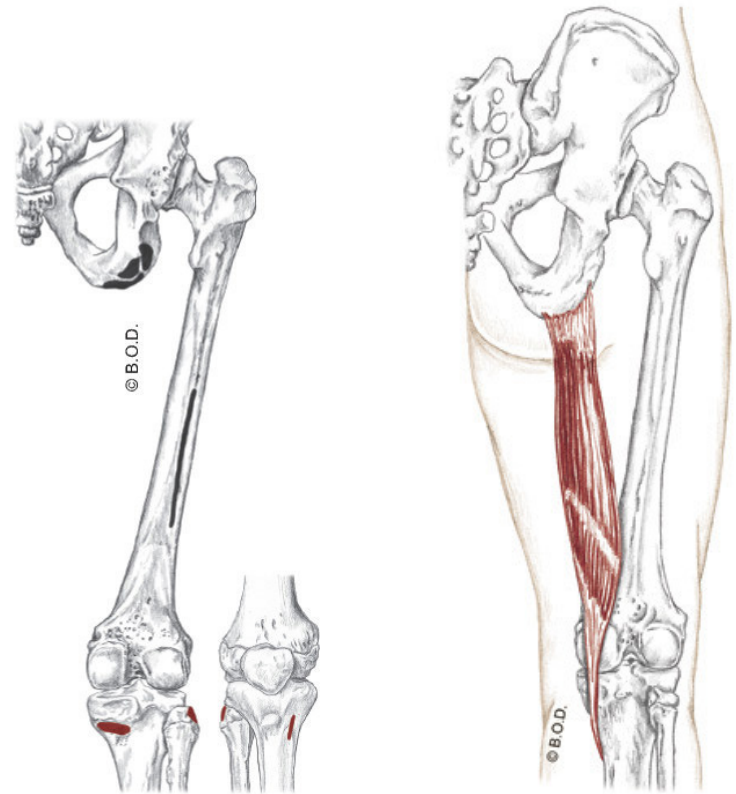


Semitendinosus, page 312

- A** **Flex** the knee (tibiofemoral joint)
- Medially rotate** the flexed knee (T/F joint)
- Extend** the hip (coxal joint)
- Assist to **medially rotate** the hip (coxal joint)
- Tilt** the pelvis posteriorly

O Ischial tuberosity

I Proximal, medial shaft of the tibia at pes anserinus tendon



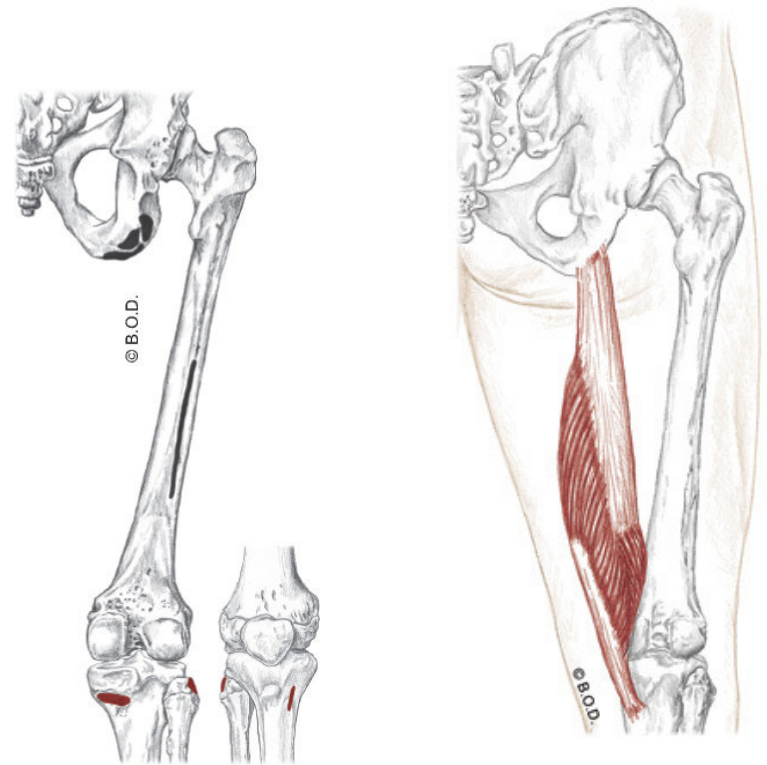
Posterior View

Semimembranosus, page 312

- A** **Flex** the knee (tibiofemoral joint)
- Medially rotate** the flexed knee (T/F joint)
- Extend** the hip (coxal joint)
- Assist to **medially rotate** the hip (coxal joint)
- Tilt** the pelvis posteriorly

O Ischial tuberosity

I Posterior aspect of medial condyle of tibia



Posterior View

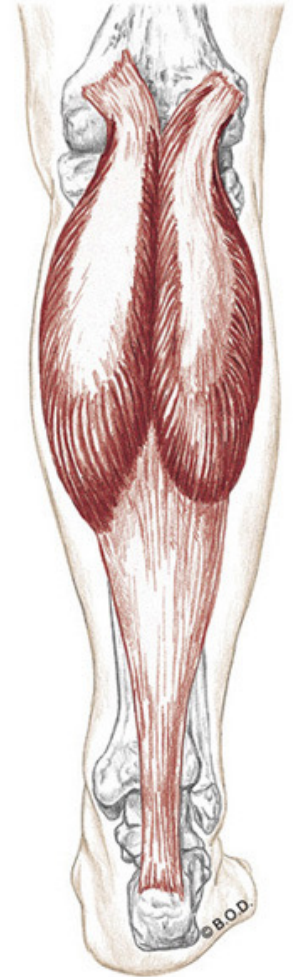
Gastrocnemius, page 371

A **Flex** the knee (tibiofemoral joint)

Plantar flex the ankle (talocrural joint)

O Condyles of the femur, posterior surfaces

I Calcaneus via calcaneal tendon



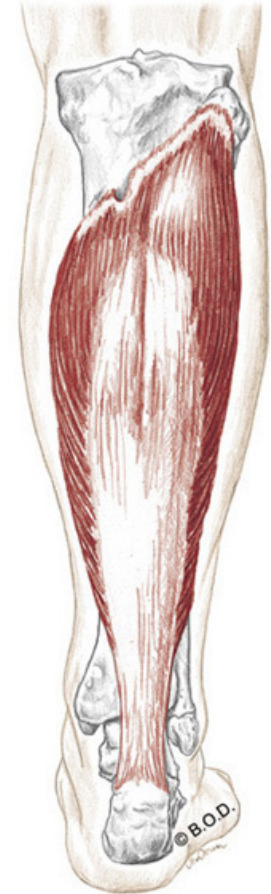Posterior View

Soleus, page 371

A **Plantar flex** the ankle (talocrural joint)

O Soleal line (proximal, posterior surface of tibia and posterior aspect of head of fibula)

I Calcaneus via calcaneal tendon



Posterior View



8b Kinesiology: AOIs - Posterior Lower Body