



# 15a A&P: Skeletal System - Bony Landmark Palpation



# 15a A&P:

## Skeletal System - Bony Landmark Palpation

### Class Outline

5 minutes	Attendance, Breath of Arrival, and Reminders
10 minutes	Lecture: AOI- SCM, Levator Scapula
25 minutes	Lecture:
15 minutes	Active study skills:
60 minutes	Total



# 15a A&P:

## Skeletal System - Bony Landmark Palpation

### Class Reminders

#### **Assignments:**

- 17a Review Questions (A: 131-140)

#### **Quizzes and Exams:**

- 17a Quiz
- 18a Kinesiology Quiz (biceps brachii, coracobrachialis, sternocleidomastoid, levator scapula, scalenes, frontalis, occipitalis, temporalis, masseter)
- 19a Quiz
- 21a Exam

#### **Preparation for upcoming classes:**

- 16a A&P: Skeletal System - Synovial Joints
  - Trail Guide: scalenes
  - Salvo: Pages 418-427
  - Packet E: 21-24
  - RQ Packet A-138
- 16b Swedish: Technique Demo and Practice - Neck, Face, and Scalp
  - Packet F: 51-54



# Classroom Rules

**Punctuality** - everybody's time is precious

- Be ready to learn at the start of class; we'll have you out of here on time
- Tardiness: arriving late, returning late after breaks, leaving during class, leaving early

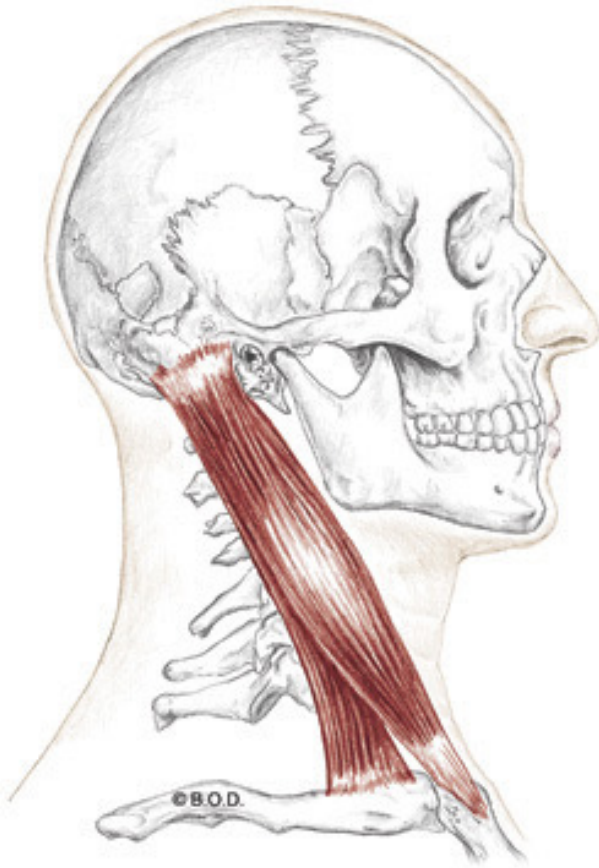
**The following are not allowed:**

- Bare feet
- Side talking
- Lying down
- Inappropriate clothing
- Food or drink except water
- Phones that are visible in the classroom, bathrooms, or internship

*You will receive one verbal warning, then you'll have to leave the room.*

# Sternocleidomastoid

Trail Guide, Page 244



Anterolateral View

## **Sternocleidomastoid**

is located on the lateral and anterior aspects of the neck.

It has a large belly with two heads:

- A flat, clavicular head
- A slender, sternal head

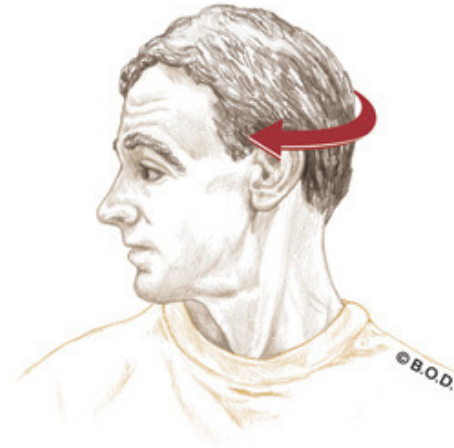
The carotid artery passes deep and medial to the SCM.

The external jugular vein lies superficial to the SCM.

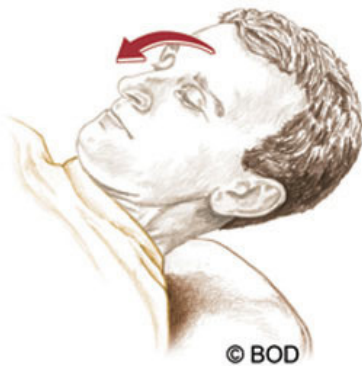
# Actions of Sternocleidomastoid



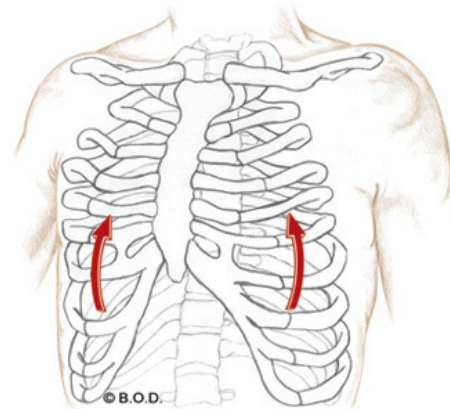
Lateral flexion of the head and neck



Rotation of the head and neck to the opposite



Flex the head and neck



Assist to elevate the ribcage during inhalation

# Sternocleidomastoid, page 244

**A** *Unilaterally:*

**Laterally flex** the head and neck to the same side

**Rotate** the head and neck to the opposite side

*Bilaterally:*

**Flex** the head and neck

Assist to **elevate** the ribcage during inhalation

**O** *Sternal head:*

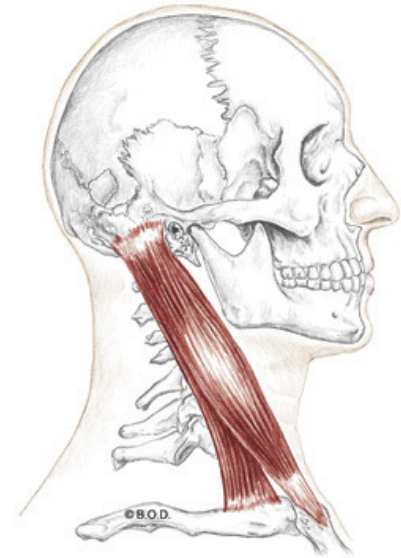
Top of manubrium

*Clavicular head:*

Medial one-third of the clavicle

**I** Mastoid process of temporal bone

Lateral portion of superior nuchal line of occiput



Lateral View



# Sternocleidomastoid, page 244

**A** *Unilaterally:*  
**Laterally flex** the head and neck to the same side

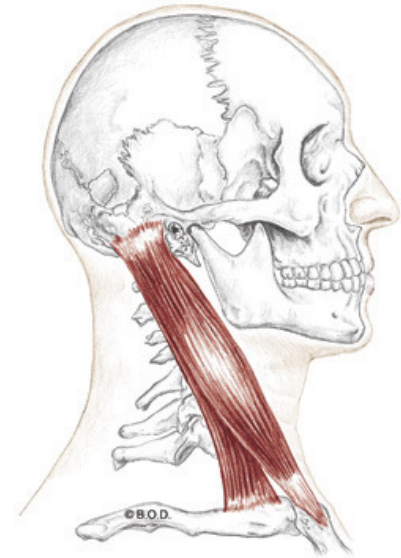
**Rotate** the head and neck to the opposite side

*Bilaterally:*  
**Flex** the head and neck  
Assist to **elevate** the ribcage during inhalation

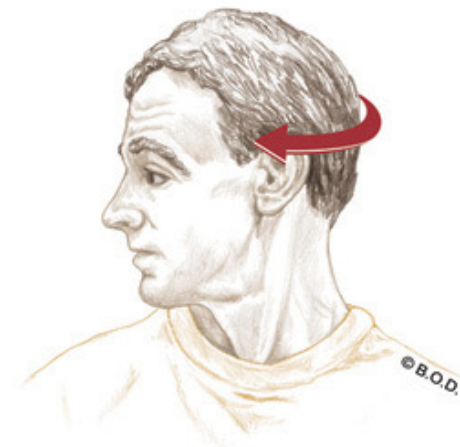**O** *Sternal head:*  
Top of manubrium

*Clavicular head:*  
Medial one-third of the clavicle

**I** Mastoid process of temporal bone  
Lateral portion of superior nuchal line of occiput



Lateral View





# Sternocleidomastoid, page 244

**A** *Unilaterally:*

**Laterally flex** the head and neck to the same side

**Rotate** the head and neck to the opposite side

*Bilaterally:*

**Flex** the head and neck

Assist to **elevate** the ribcage during inhalation

**O** *Sternal head:*

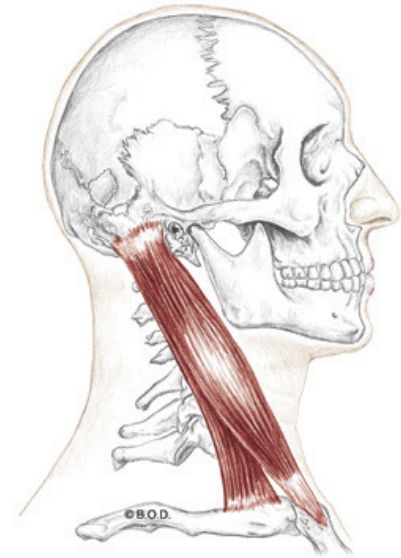
Top of manubrium

*Clavicular head:*

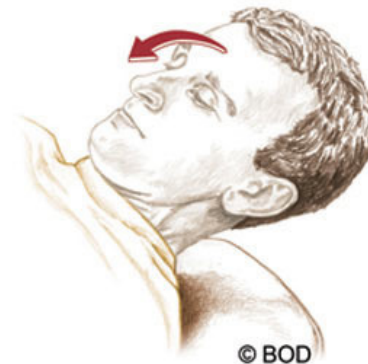Medial one-third of the clavicle

**I** Mastoid process of temporal bone

Lateral portion of superior nuchal line of occiput



Lateral View



# Sternocleidomastoid, page 244

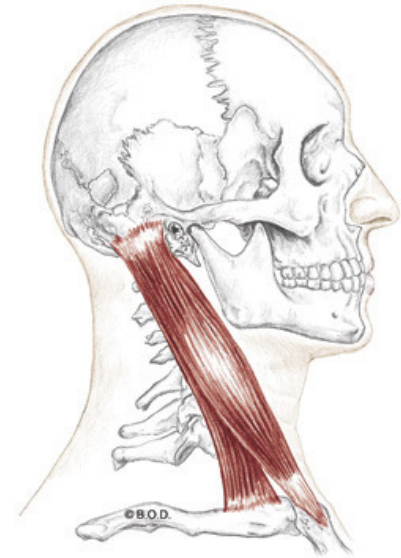
- A** *Unilaterally:*  
**Laterally flex** the head and neck to the same side  
**Rotate** the head and neck to the opposite side

*Bilaterally:*  
**Flex** the head and neck  
Assist to **elevate** the ribcage during inhalation

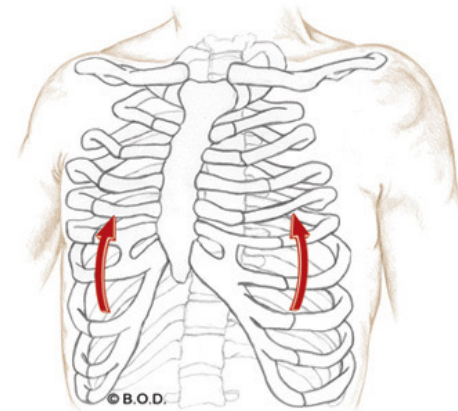
- O** *Sternal head:*  
Top of manubrium

*Clavicular head:*  
Medial one-third of the clavicle

- I** Mastoid process of temporal bone  
Lateral portion of superior nuchal line of occiput



Lateral View



# Sternocleidomastoid, page 244

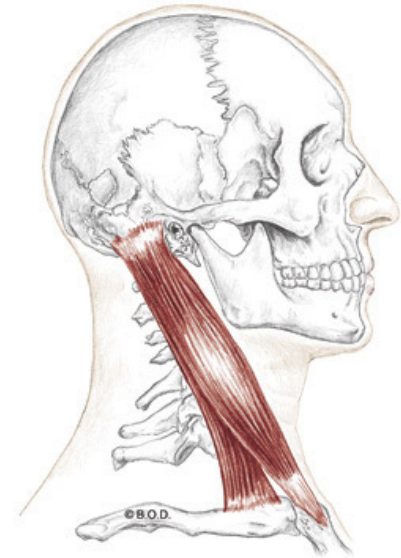
- A** *Unilaterally:*  
**Laterally flex** the head and neck to the same side  
**Rotate** the head and neck to the opposite side

*Bilaterally:*  
**Flex** the head and neck  
Assist to **elevate** the ribcage during inhalation

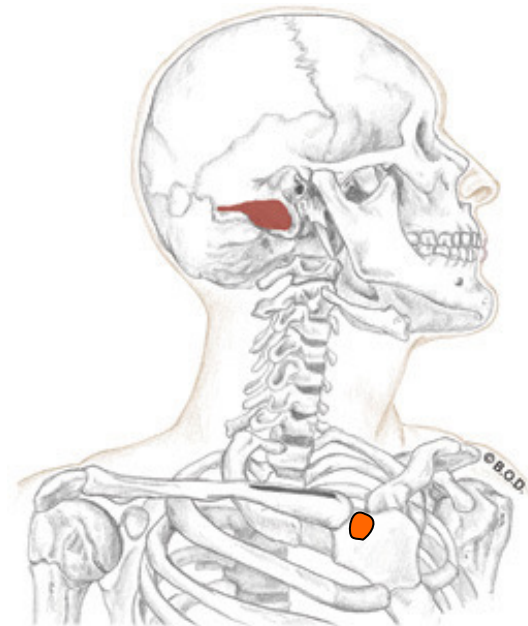
**O** *Sternal head:*  
Top of manubrium

*Clavicular head:*  
Medial one-third of the clavicle

- I** Mastoid process of temporal bone  
Lateral portion of superior nuchal line of occiput



Lateral View



# Sternocleidomastoid, page 244

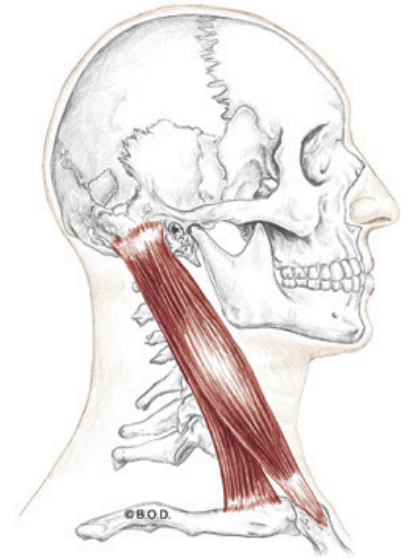
- A** *Unilaterally:*  
**Laterally flex** the head and neck to the same side  
**Rotate** the head and neck to the opposite side

*Bilaterally:*  
**Flex** the head and neck  
Assist to **elevate** the ribcage during inhalation

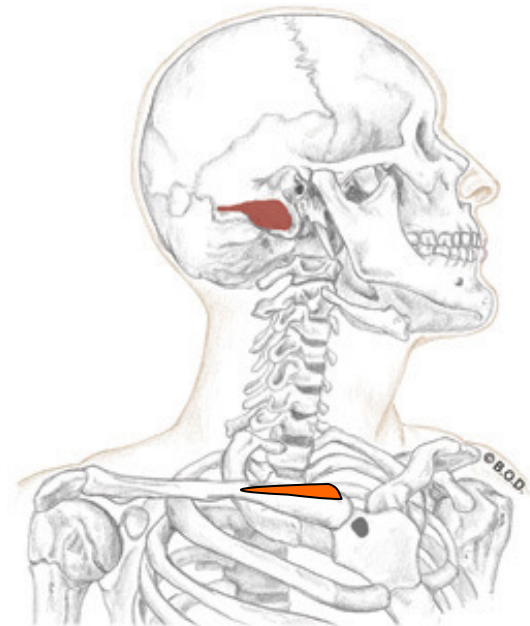
- O** *Sternal head:*  
Top of manubrium

*Clavicular head:*  
Medial one-third of the clavicle

- I** Mastoid process of temporal bone  
Lateral portion of superior nuchal line of occiput



Lateral View



# Sternocleidomastoid, page 244

**A** *Unilaterally:*

**Laterally flex** the head and neck to the same side

**Rotate** the head and neck to the opposite side

*Bilaterally:*

**Flex** the head and neck

Assist to **elevate** the ribcage during inhalation

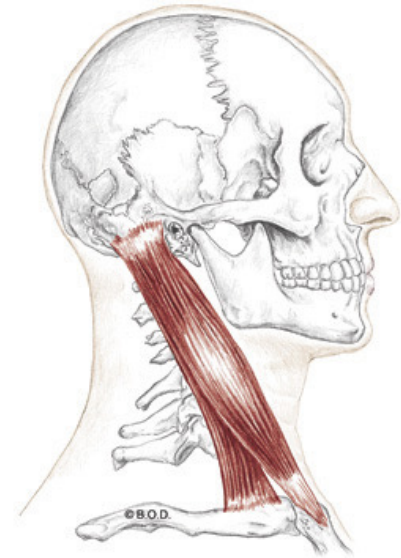
**O** *Sternal head:*

Top of manubrium

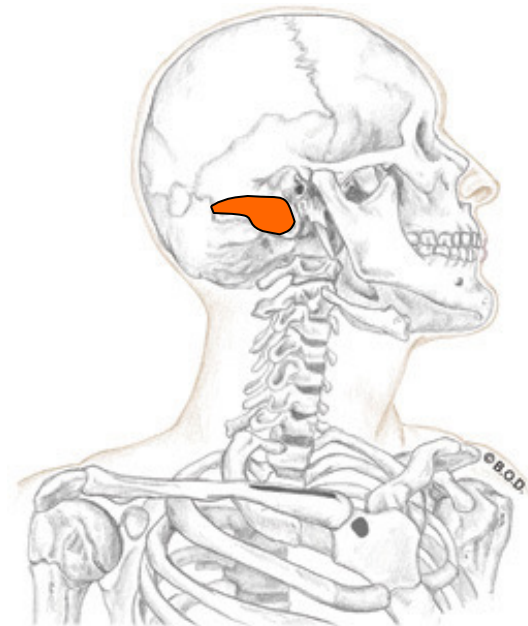
*Clavicular head:*

Medial one-third of the clavicle

**I** Mastoid process of temporal bone  
Lateral portion of superior nuchal line of occiput

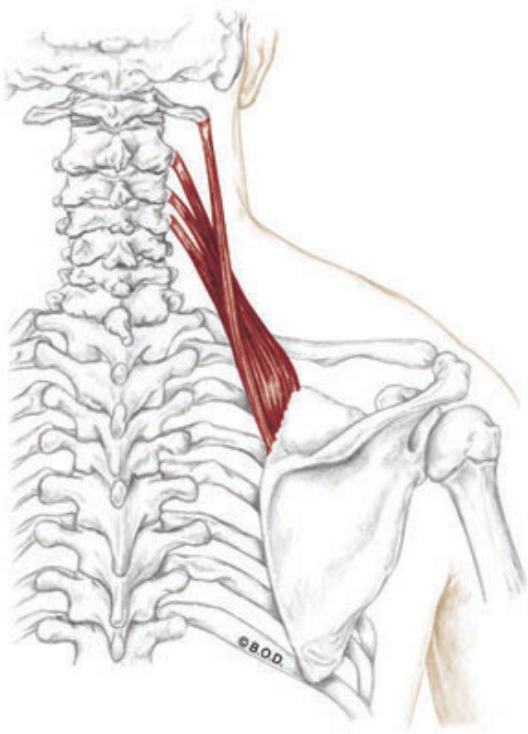


Lateral View



# Levator Scapula

## Trail Guide, Page 83



Posterior View

**Levator Scapula** is located on the lateral and posterior sides of the neck.

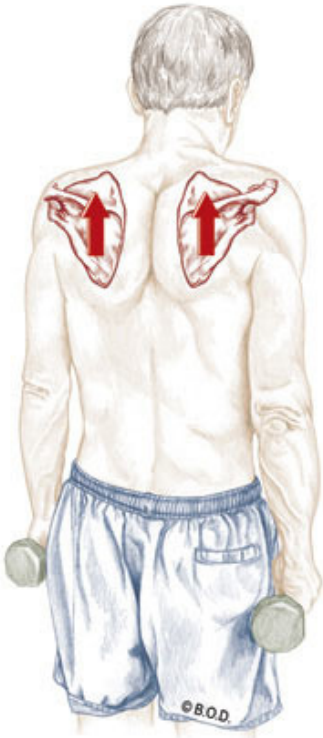
The inferior portion is deep to trapezius, but the superior portion is superficial on the lateral side of the neck.

Its belly is approximately two fingers wide with fibers that naturally twist around themselves.

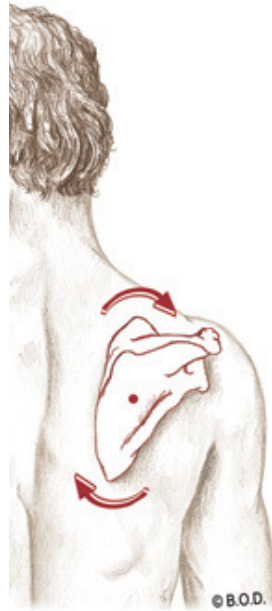What actions does the levator scapula perform?



# Actions of Levator Scapula



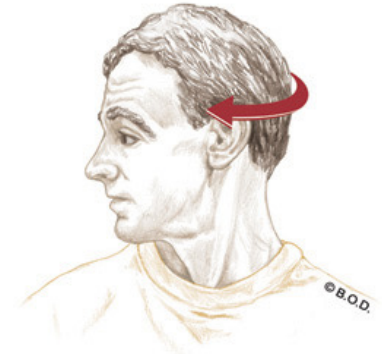
Scapulothoracic  
elevation



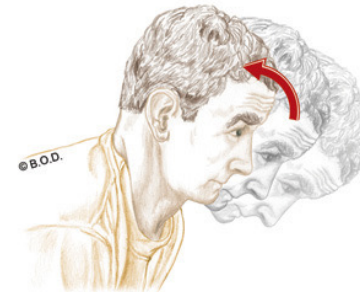
Scapulothoracic  
downward  
rotation



Lateral  
flexion of  
the head  
and neck



Rotation of the  
head and neck to  
the same side



Extension of  
the head and  
neck

# Levator Scapula, page 84

**A** *Unilaterally:*

**Elevate** the scapula, AKA: scapulothoracic joint

**Downwardly rotate** the scapula, AKA: S/T joint

**Laterally flex** the head and neck

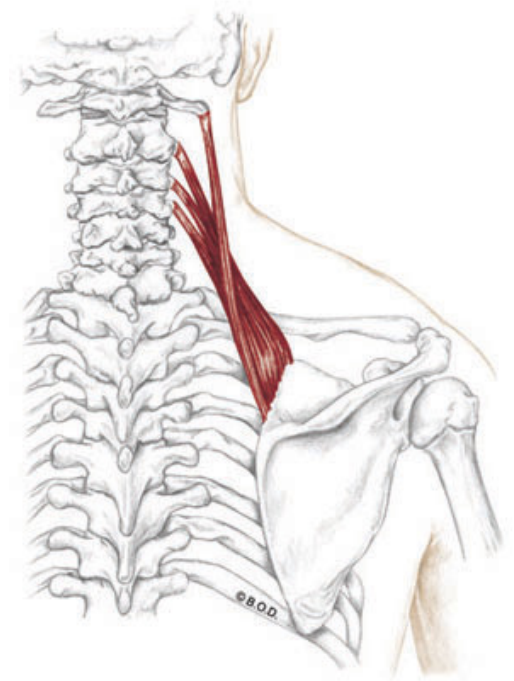
**Rotate** the head and neck to the same side

*Bilaterally:*

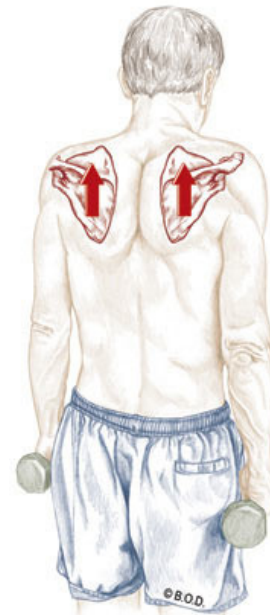
**Extend** the head and neck

**O** Transverse processes of first through fourth cervical vertebrae

**I** Medial border of scapula, between superior angle and superior portion of spine of scapula



Posterior View





# Levator Scapula, page 84

**A** *Unilaterally:*

**Elevate** the scapula, AKA: scapulothoracic joint

**Downwardly rotate** the scapula, AKA: S/T joint

**Laterally flex** the head and neck

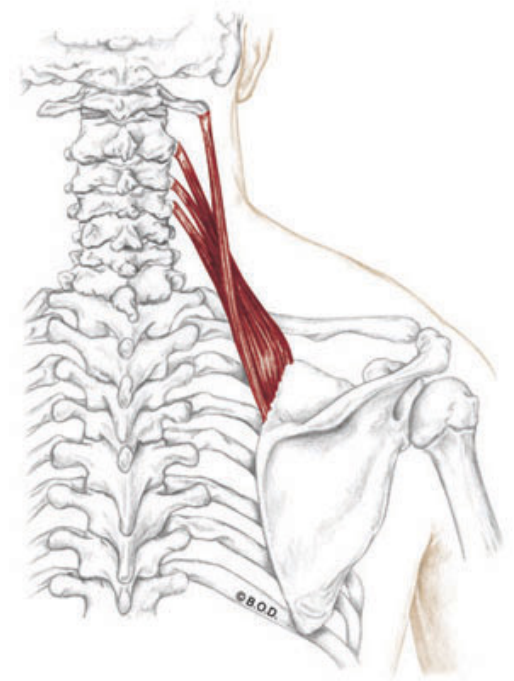
**Rotate** the head and neck to the same side

*Bilaterally:*

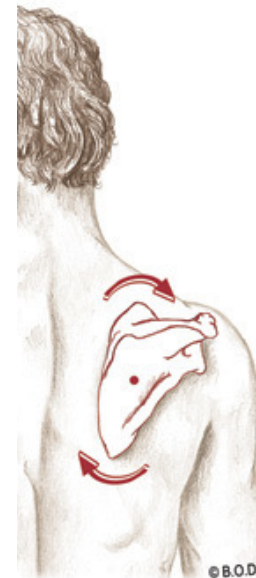**Extend** the head and neck

**O** Transverse processes of first through fourth cervical vertebrae

**I** Medial border of scapula, between superior angle and superior portion of spine of scapula



Posterior View

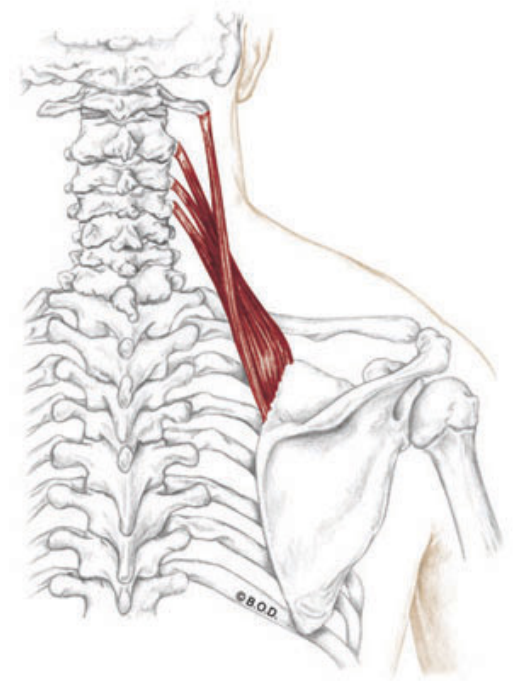


# Levator Scapula, page 84

- A** *Unilaterally:*  
**Elevate** the scapula, AKA: scapulothoracic joint  
**Downwardly rotate** the scapula, AKA: S/T joint  
**Laterally flex** the head and neck  
**Rotate** the head and neck to the same side

*Bilaterally:*  
**Extend** the head and neck

- O** Transverse processes of first through fourth cervical vertebrae
- I** Medial border of scapula, between superior angle and superior portion of spine of scapula



Posterior View



# Levator Scapula, page 84

**A** *Unilaterally:*

**Elevate** the scapula, AKA: scapulothoracic joint

**Downwardly rotate** the scapula, AKA: S/T joint

**Laterally flex** the head and neck

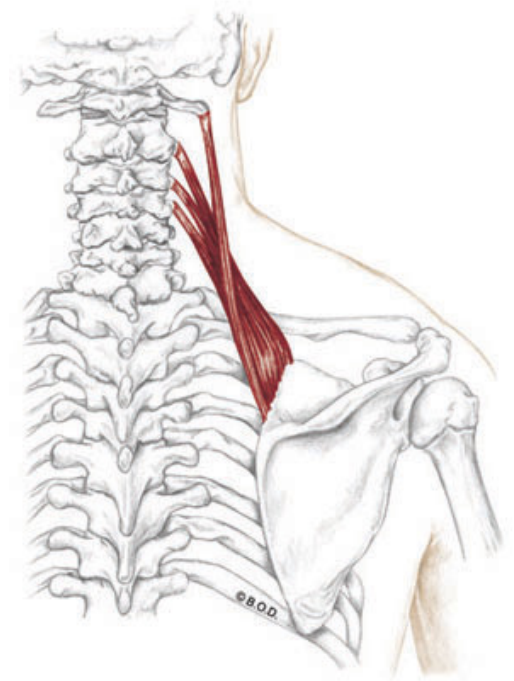
**Rotate** the head and neck to the same side

*Bilaterally:*

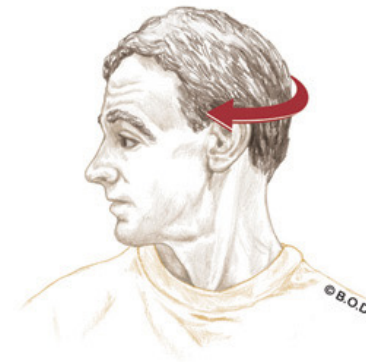
**Extend** the head and neck

**O** Transverse processes of first through fourth cervical vertebrae

**I** Medial border of scapula, between superior angle and superior portion of spine of scapula



Posterior View



# Levator Scapula, page 84

**A** *Unilaterally:*

**Elevate** the scapula, AKA: scapulothoracic joint

**Downwardly rotate** the scapula, AKA: S/T joint

**Laterally flex** the head and neck

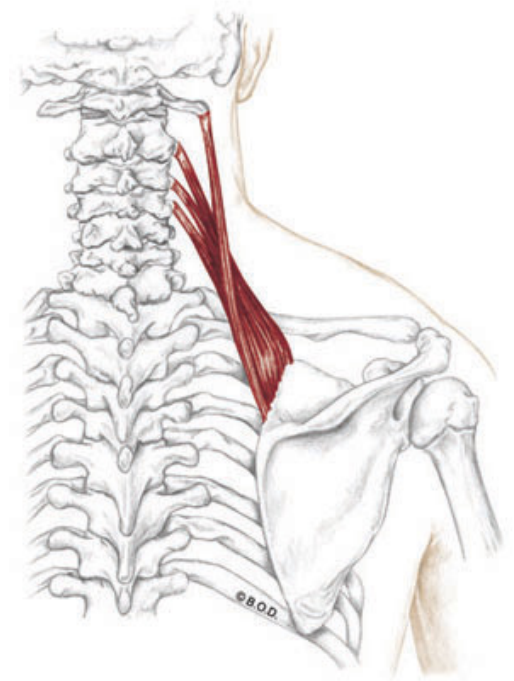
**Rotate** the head and neck to the same side

*Bilaterally:*

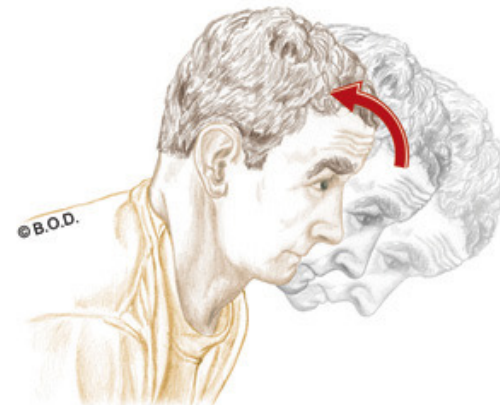
**Extend** the head and neck

**O** Transverse processes of first through fourth cervical vertebrae

**I** Medial border of scapula, between superior angle and superior portion of spine of scapula



Posterior View



# Levator Scapula, page 84

**A** *Unilaterally:*

**Elevate** the scapula, AKA: scapulothoracic joint

**Downwardly rotate** the scapula, AKA: S/T joint

**Laterally flex** the head and neck

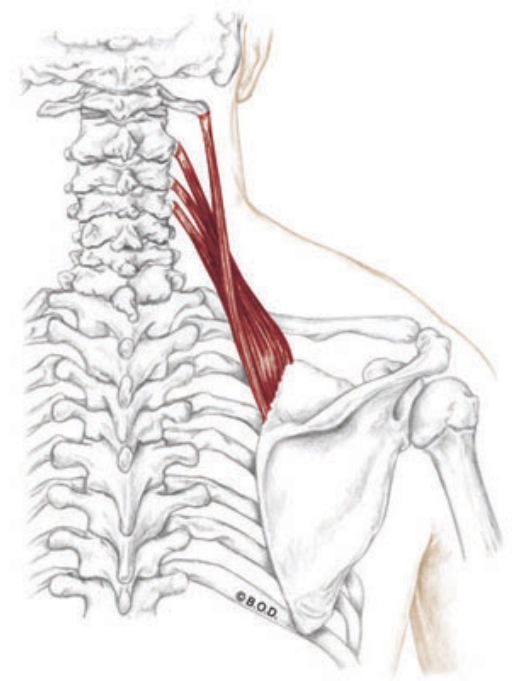
**Rotate** the head and neck to the same side

*Bilaterally:*

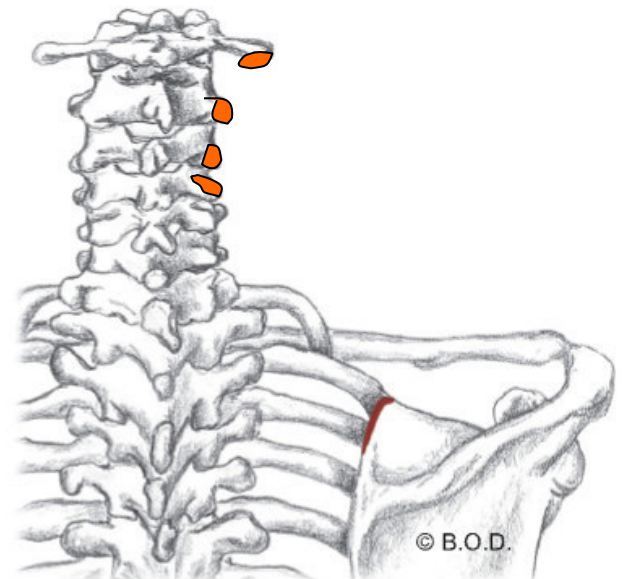
**Extend** the head and neck

**O** Transverse processes of first through fourth cervical vertebrae

**I** Medial border of scapula, between superior angle and superior portion of spine of scapula



Posterior View





# Levator Scapula, page 84

**A** *Unilaterally:*

**Elevate** the scapula, AKA: scapulothoracic joint

**Downwardly rotate** the scapula, AKA: S/T joint

**Laterally flex** the head and neck

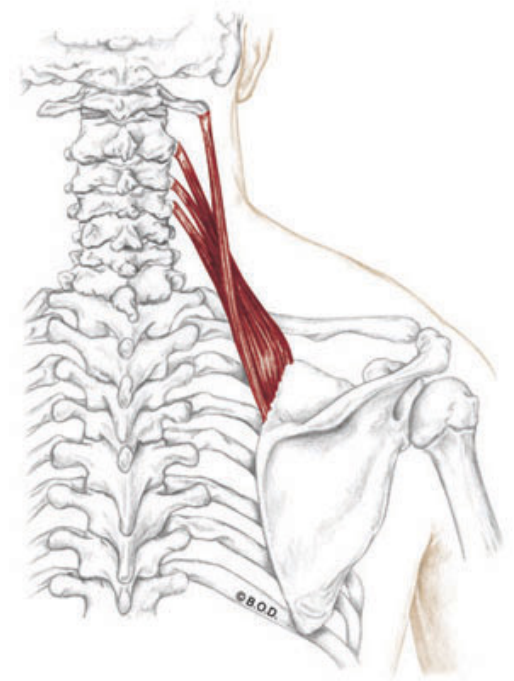
**Rotate** the head and neck to the same side

*Bilaterally:*

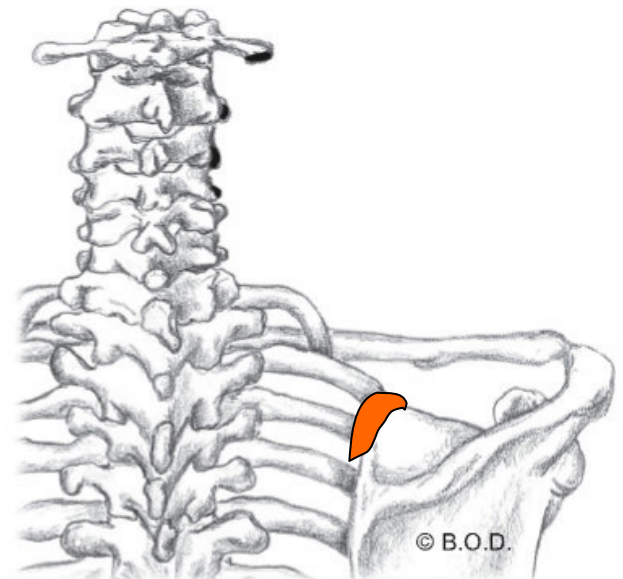
**Extend** the head and neck

**O** Transverse processes of first through fourth cervical vertebrae

**I** Medial border of scapula, between superior angle and superior portion of spine of scapula



Posterior View





# 15a A&P: Skeletal System - Bony Landmark Palpation E-19

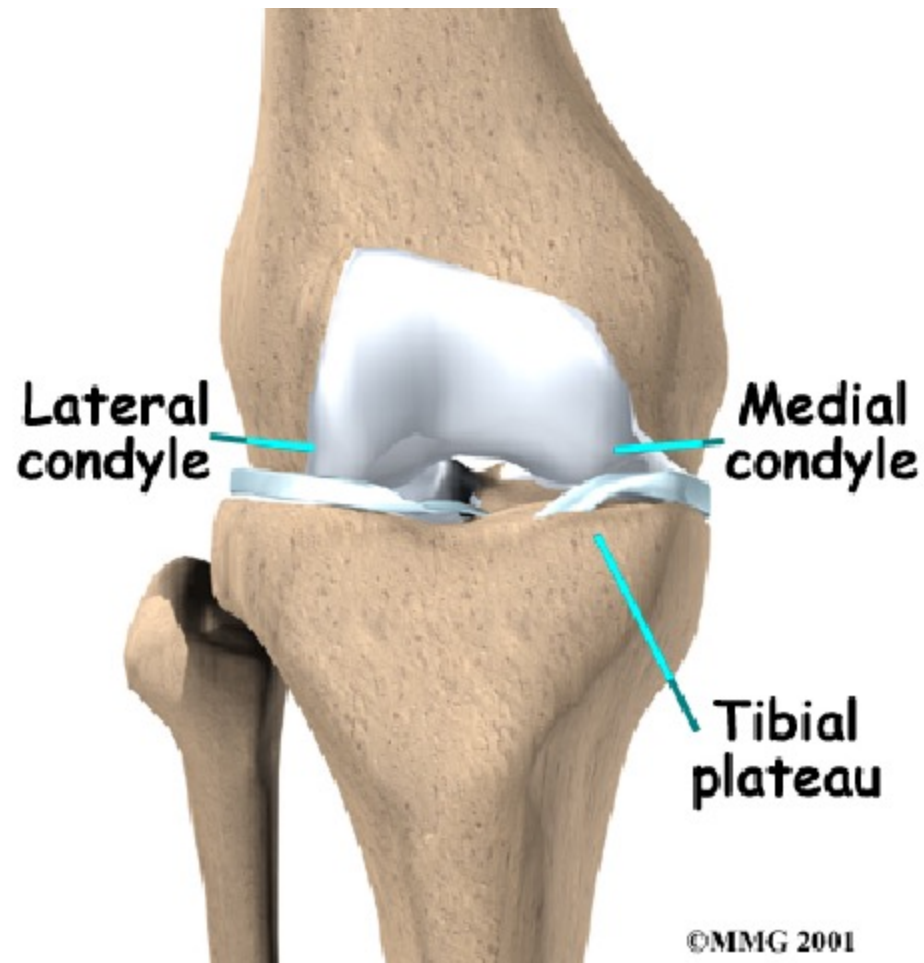


## Bony Markings



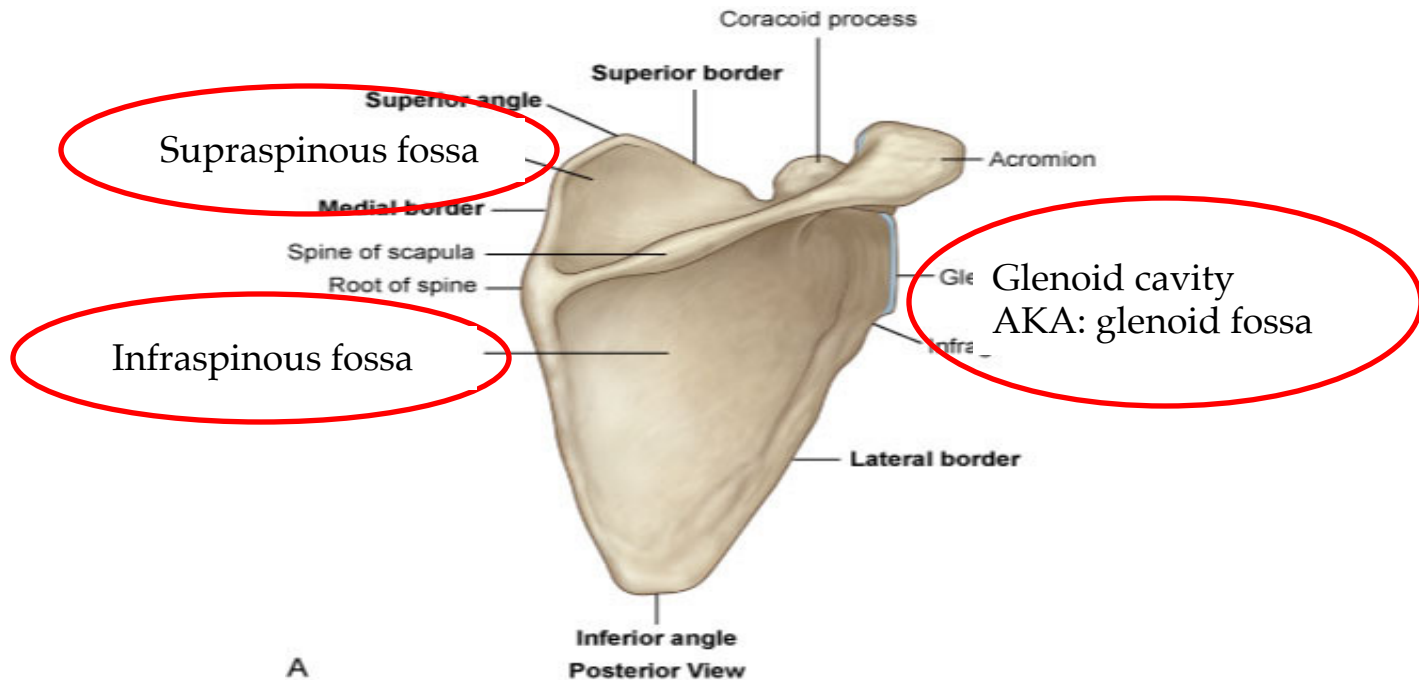
# Bony Markings

**Condyle** Rounded projection that forms a joint.



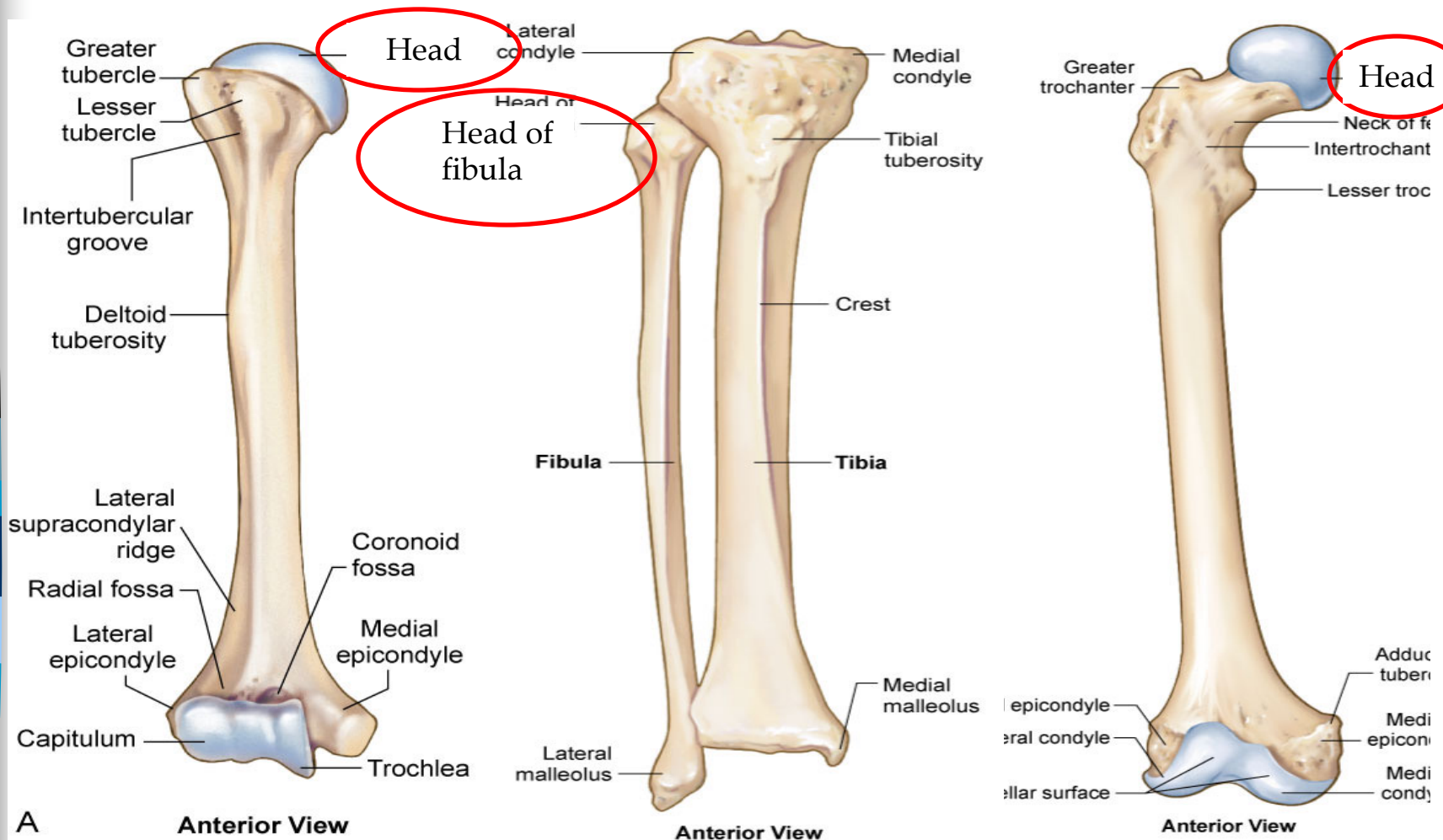
# Bony Markings

**Fossa** Shallow depression in a bone.



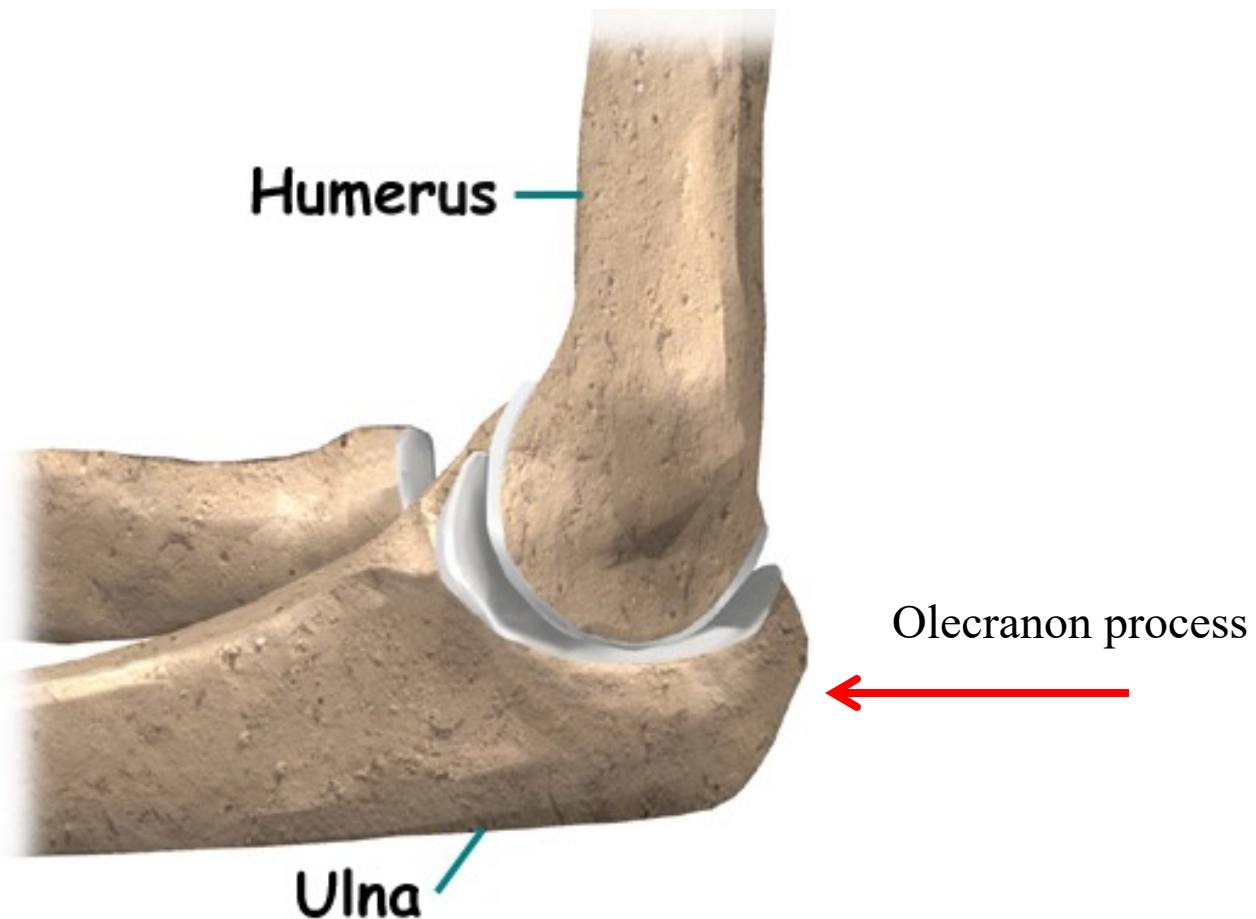
# Bony Markings

**Head** Rounded end of a bone. Example: head of the humerus.



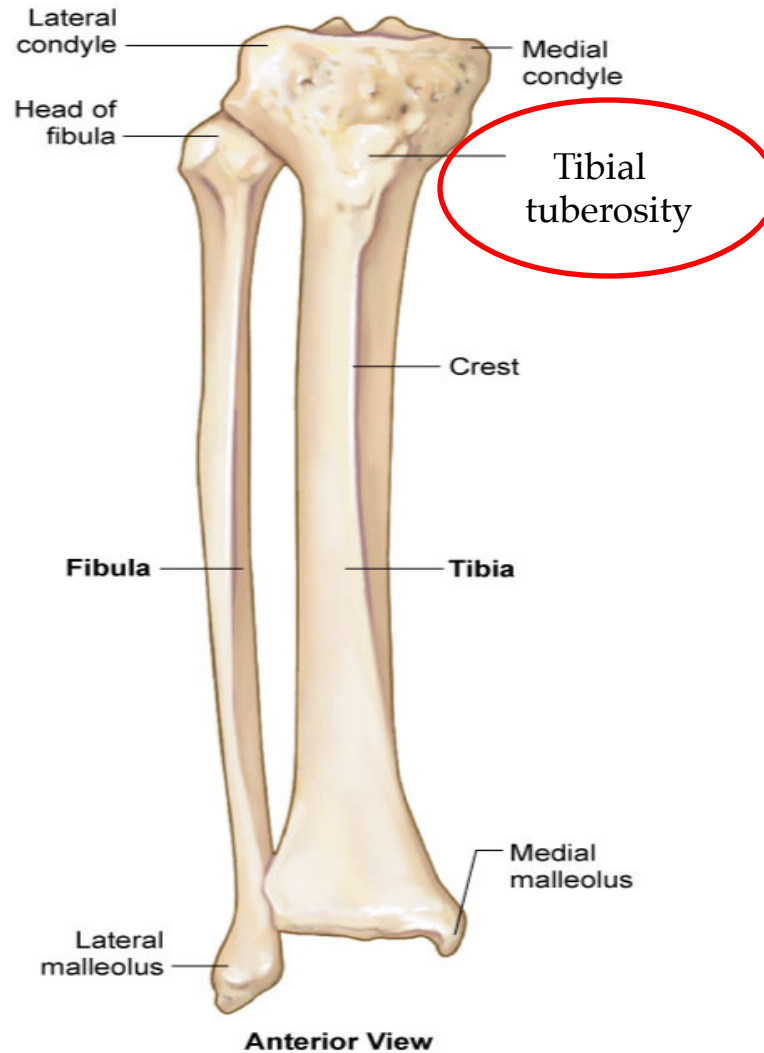
# Bony Markings

**Process** General term for any prominence or prolongation from a bone.



# Bony Markings

**Tuberosity** Large, rounded rough projection.

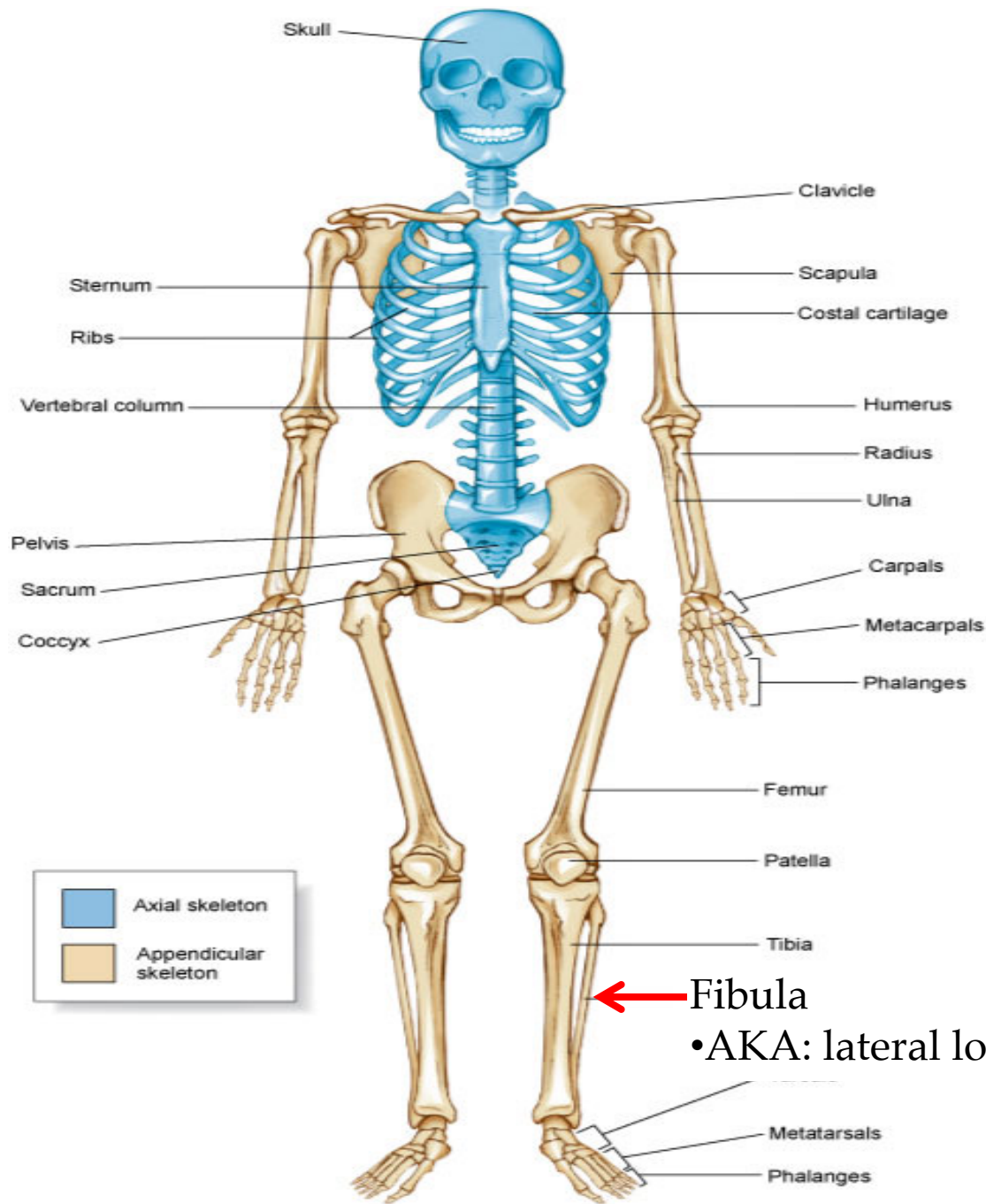




# Palpation

Setting up the room. You'll need:

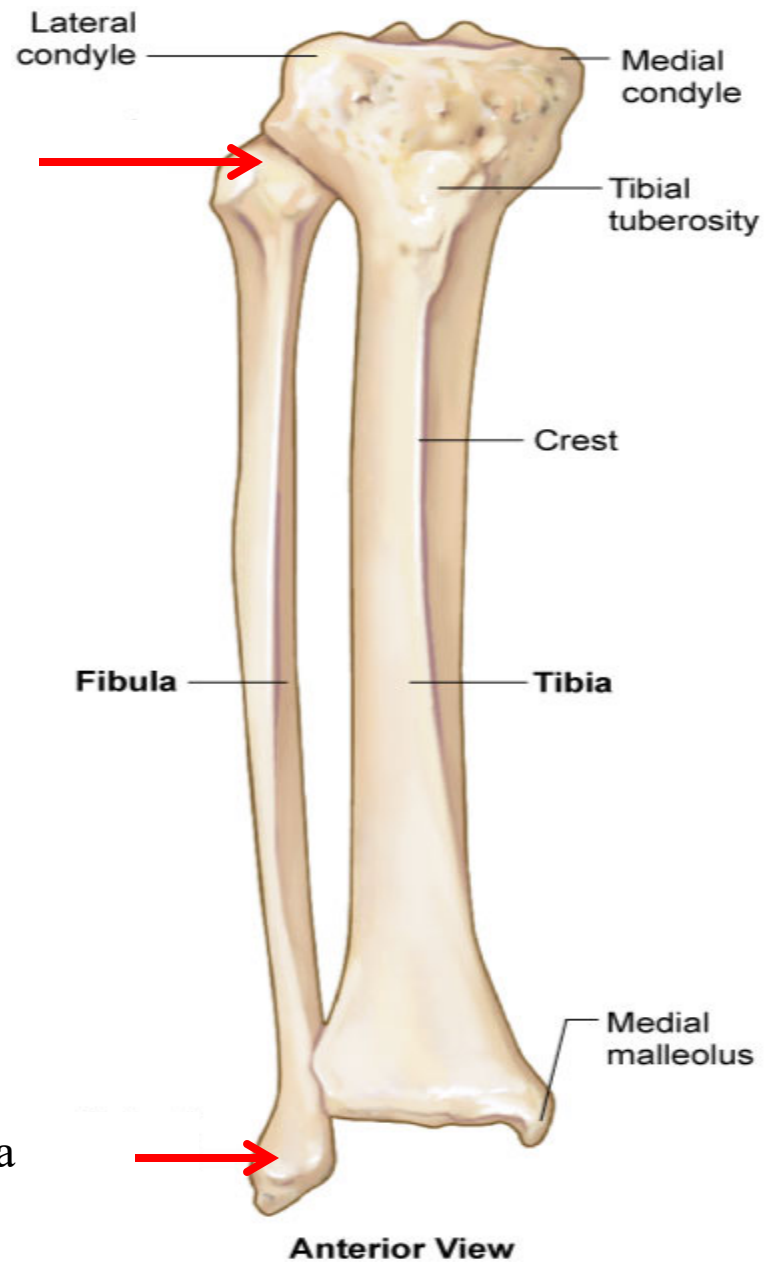
- A group of three people
- A massage table
- Face cradle with face cradle cover (set aside for now)
- Bolster



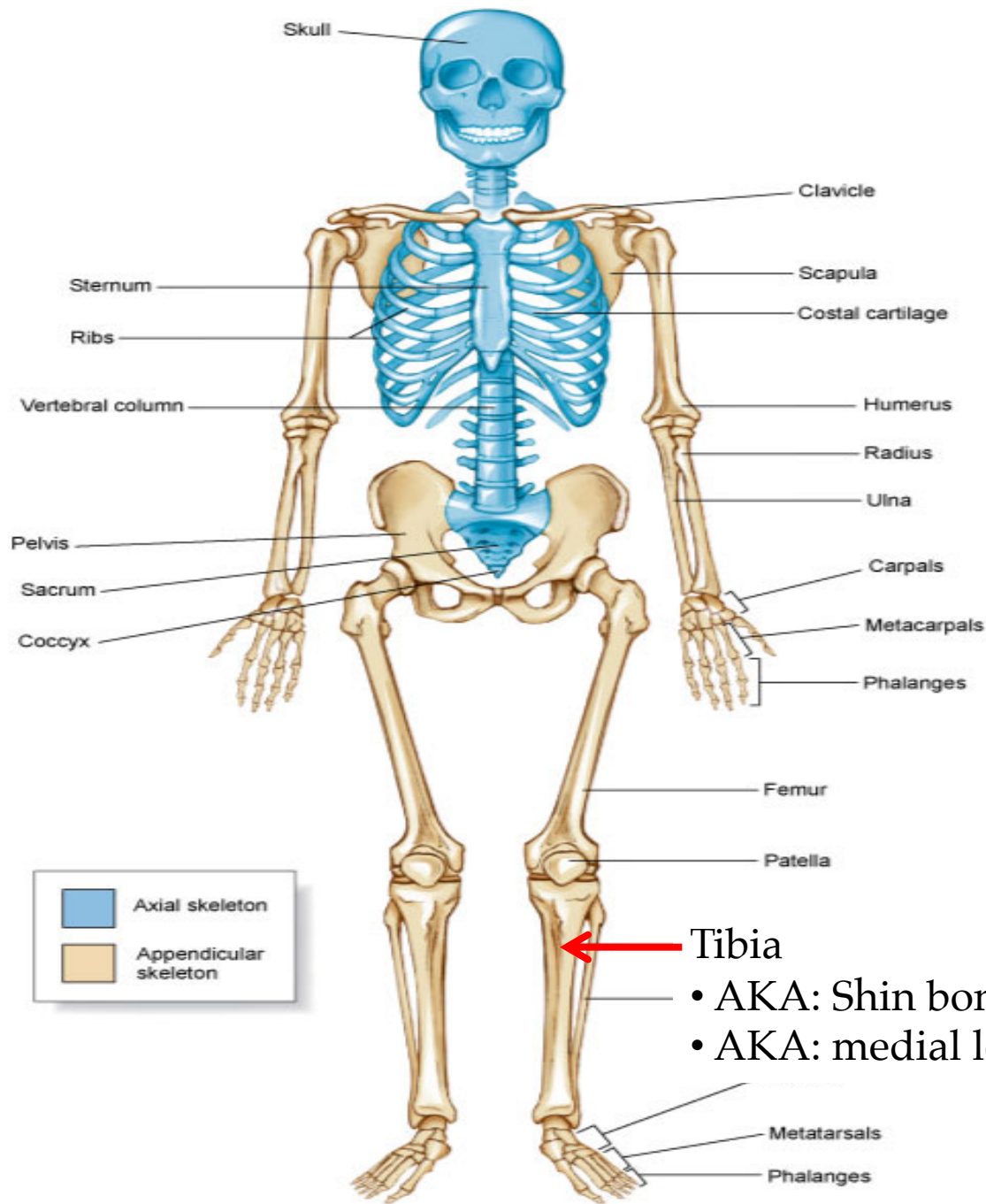
← Fibula

•AKA: lateral lower leg bone

Head of the Fibula

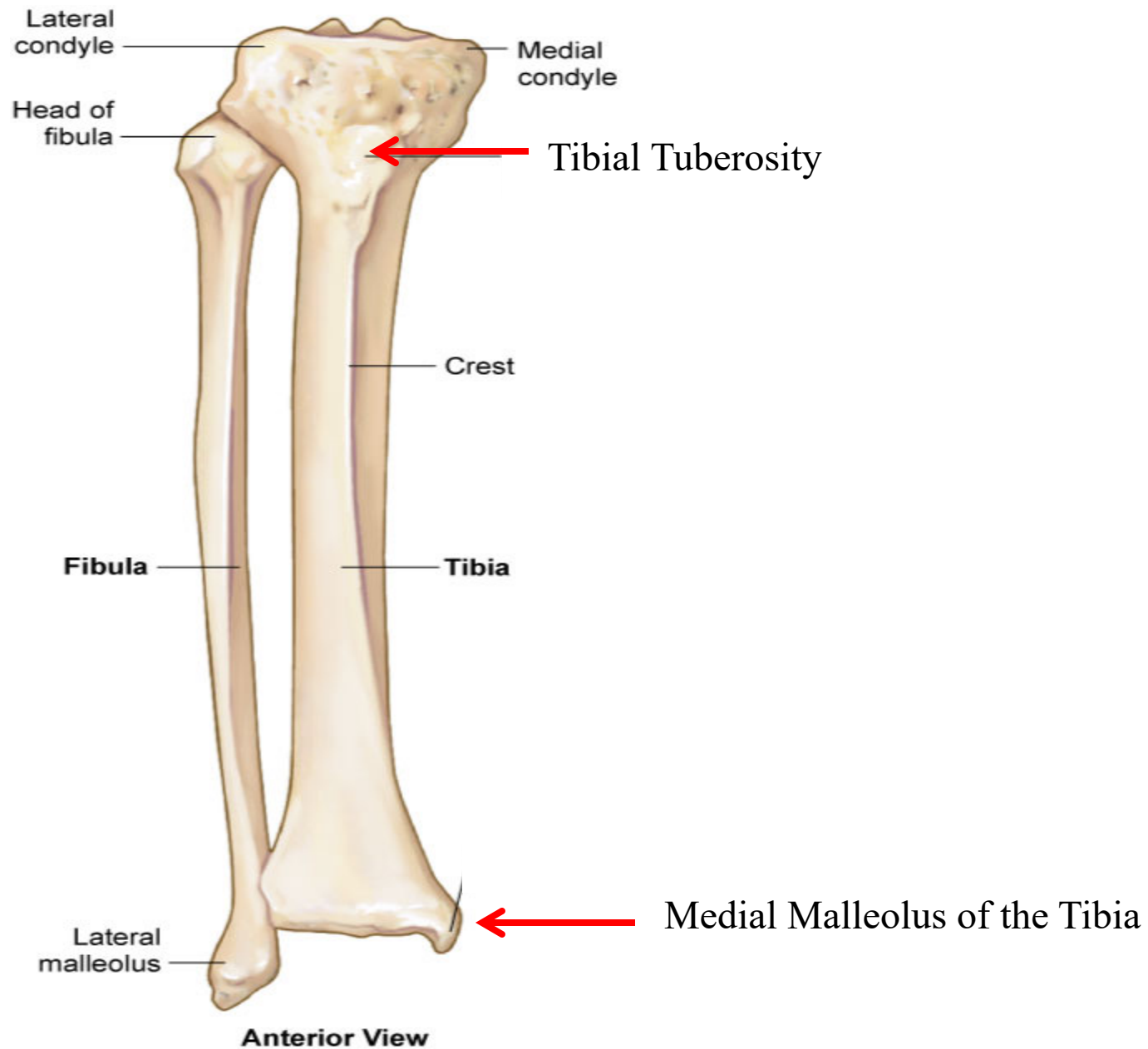


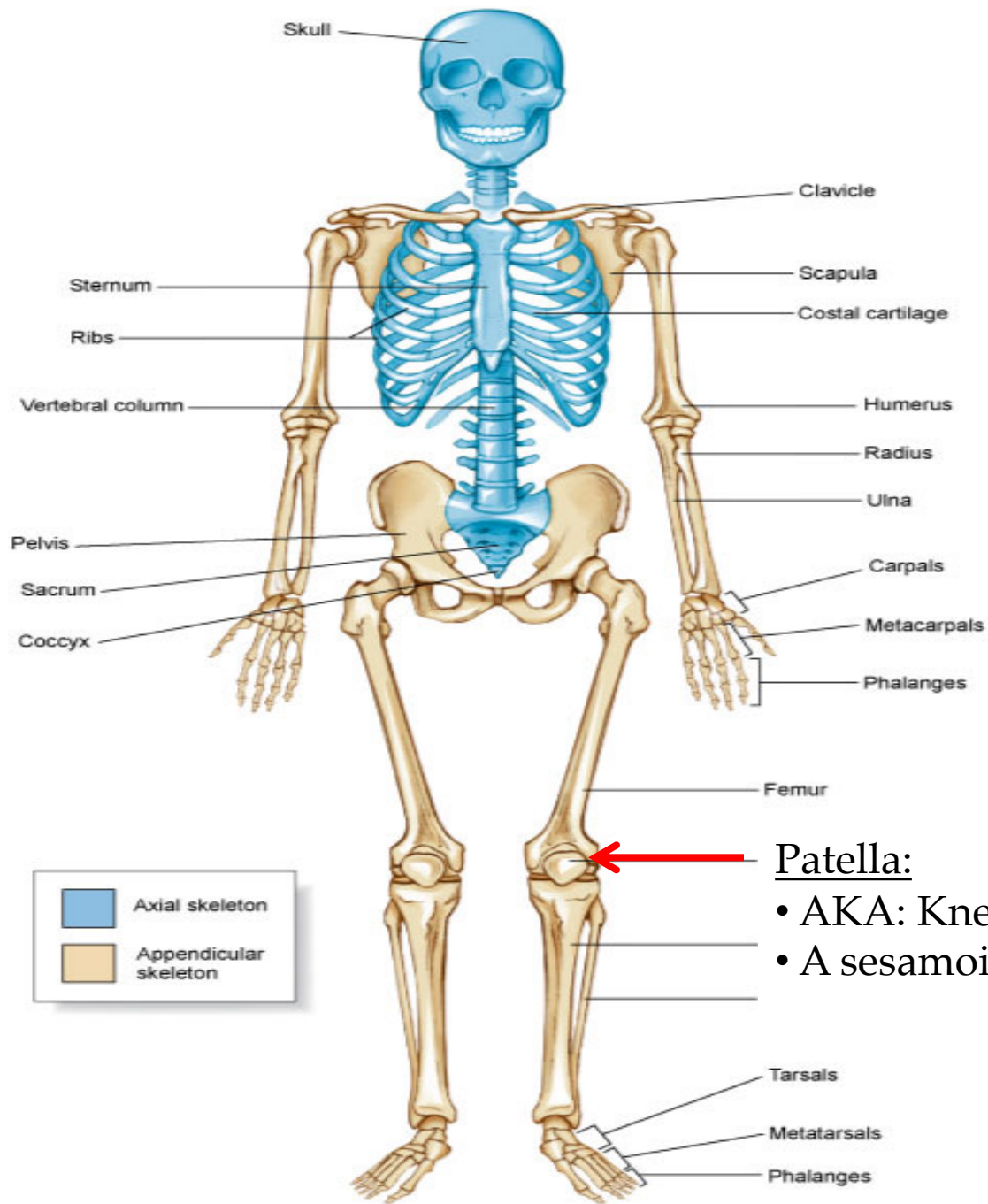




Tibia

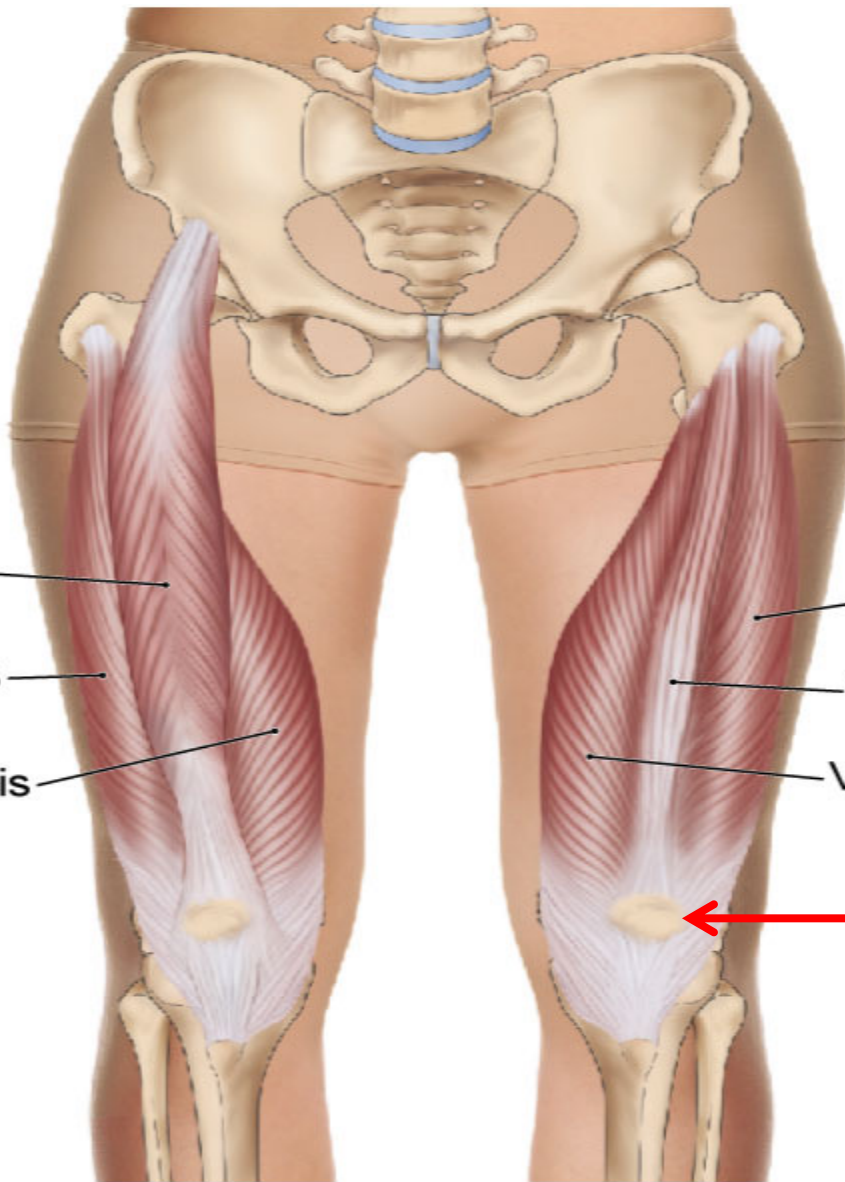
- AKA: Shin bone
- AKA: medial lower leg bone





### Patella:

- AKA: Kneecap
- A sesamoid bone



Rectus femoris

Vastus lateralis

Vastus medialis

Vastus lateralis

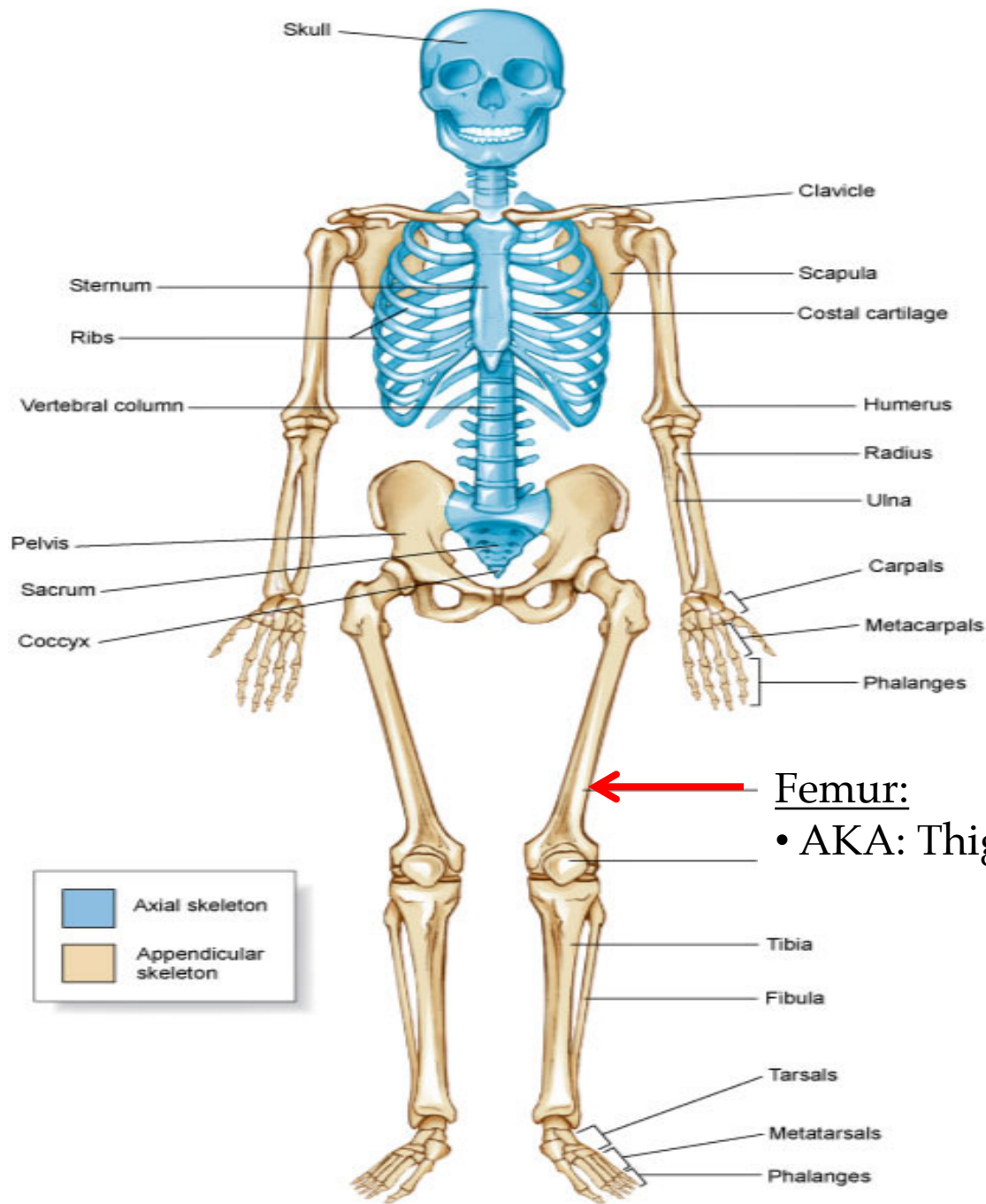
Vastus intermedius

Vastus medialis

Patella:

- AKA: Kneecap
- A sesamoid bone

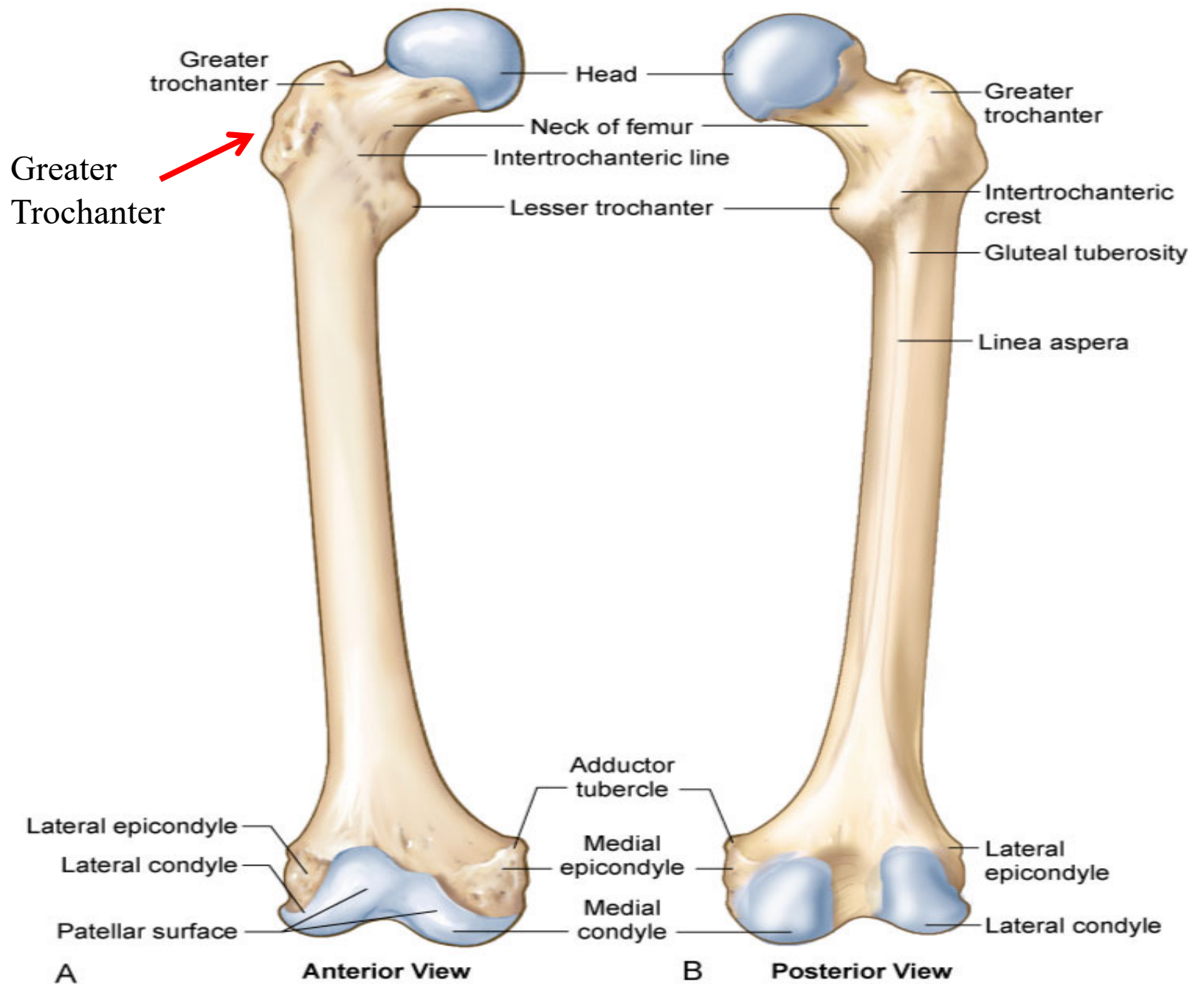
**Anterior View**



Femur:

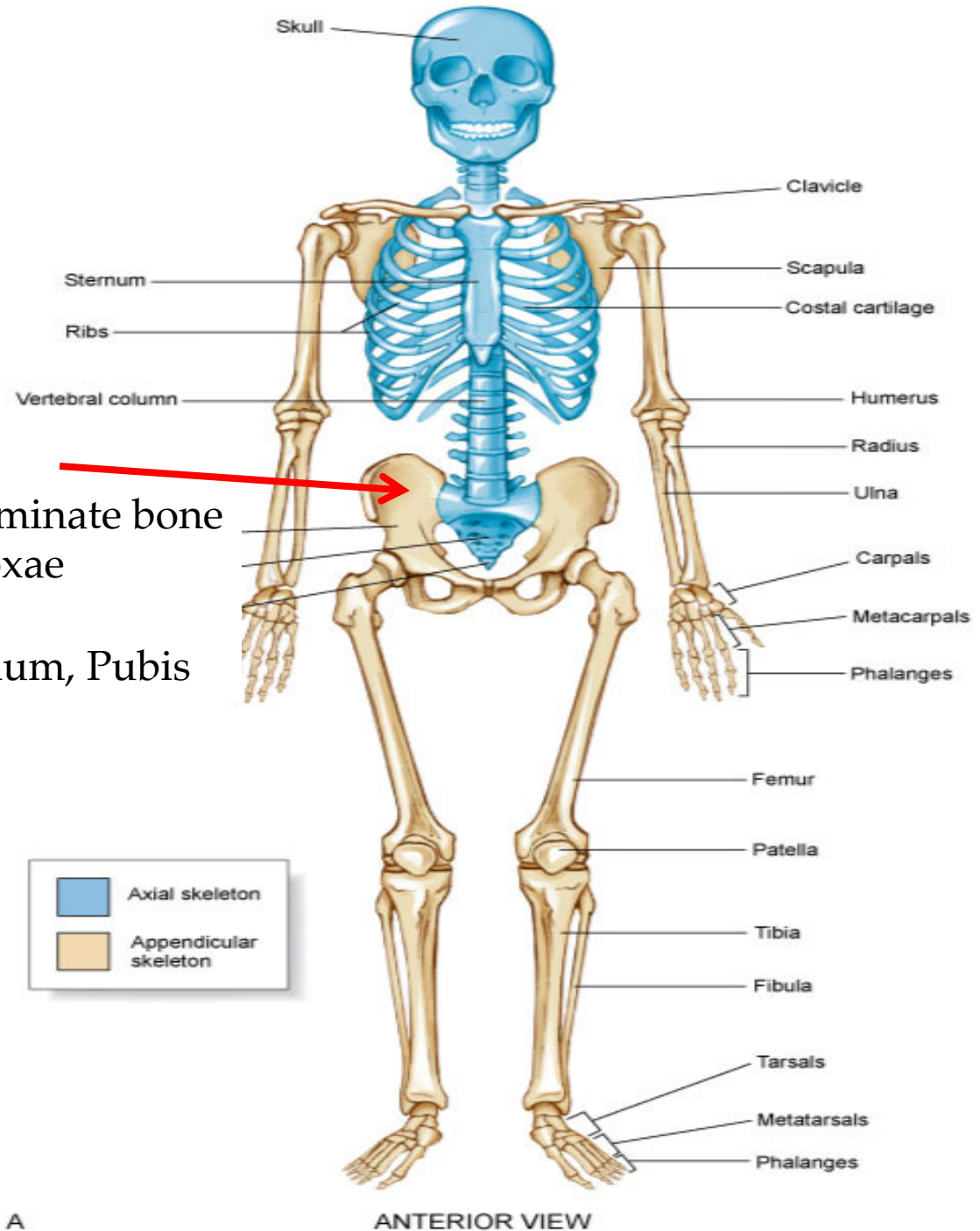
- AKA: Thigh bone





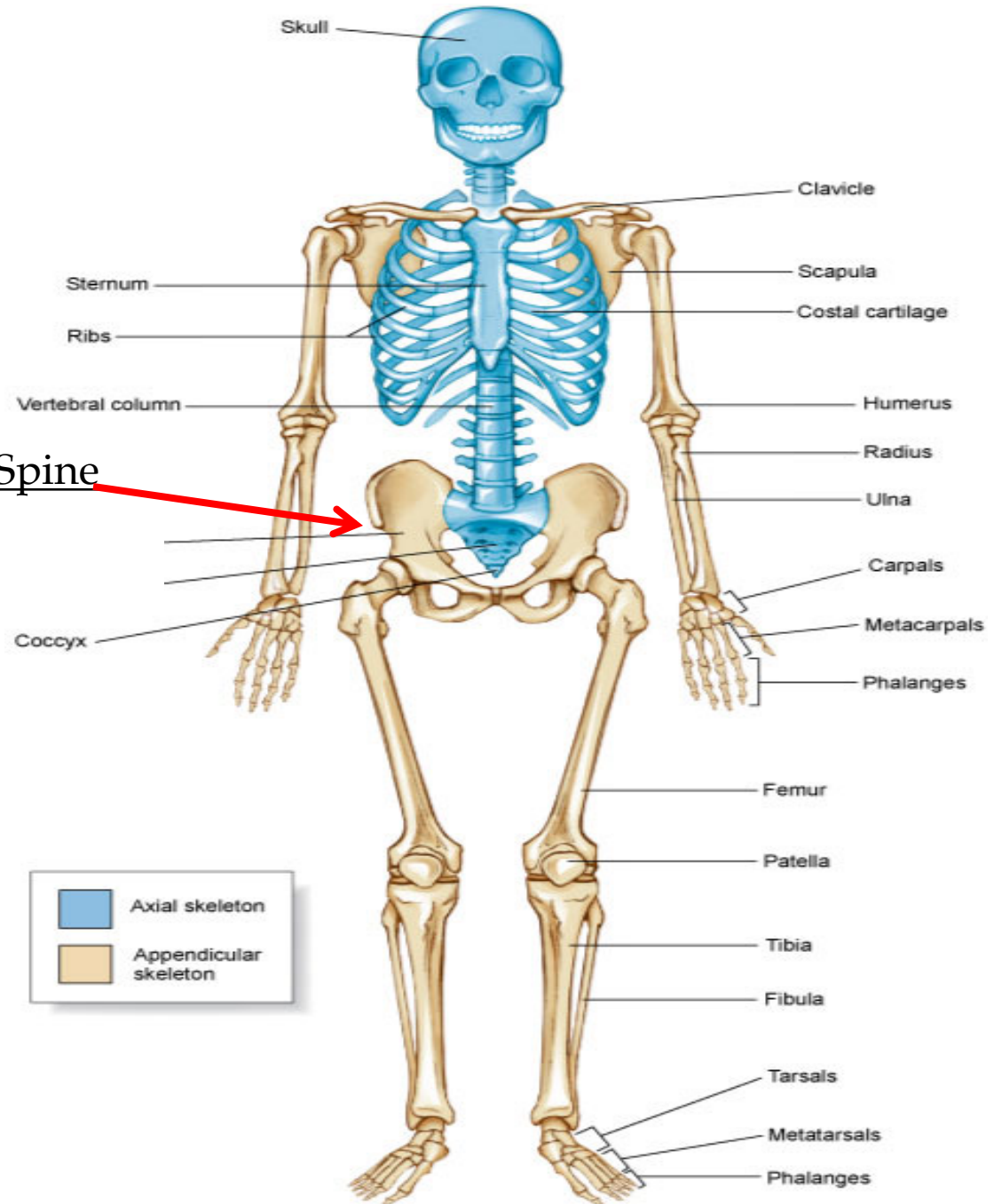
## Pelvic Bone

- AKA: innominate bone
- AKA: os coxae
- Ilium, Ischium, Pubis



## Anterior Superior Iliac Spine

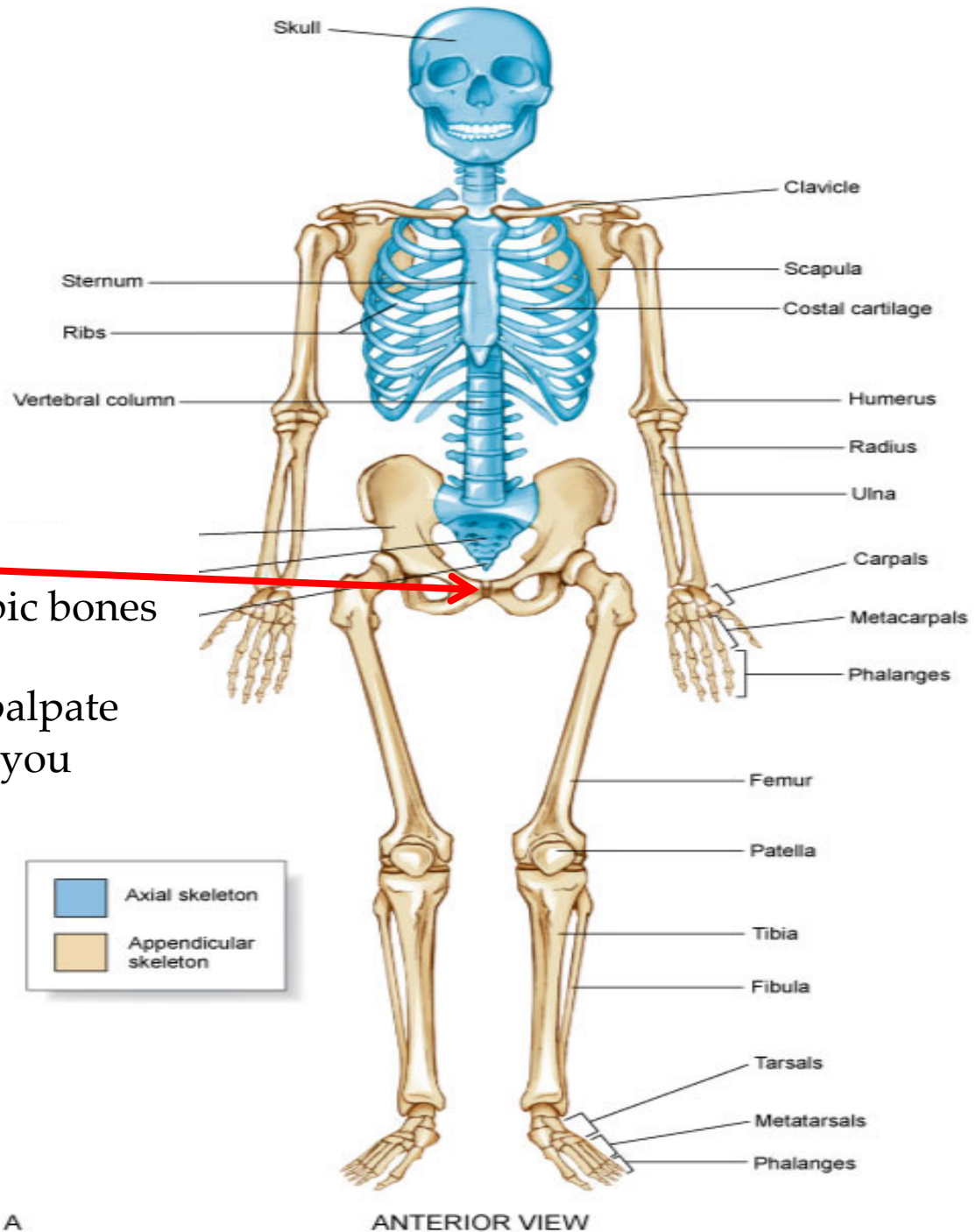
- AKA: ASIS
- AKA: Hip pointers

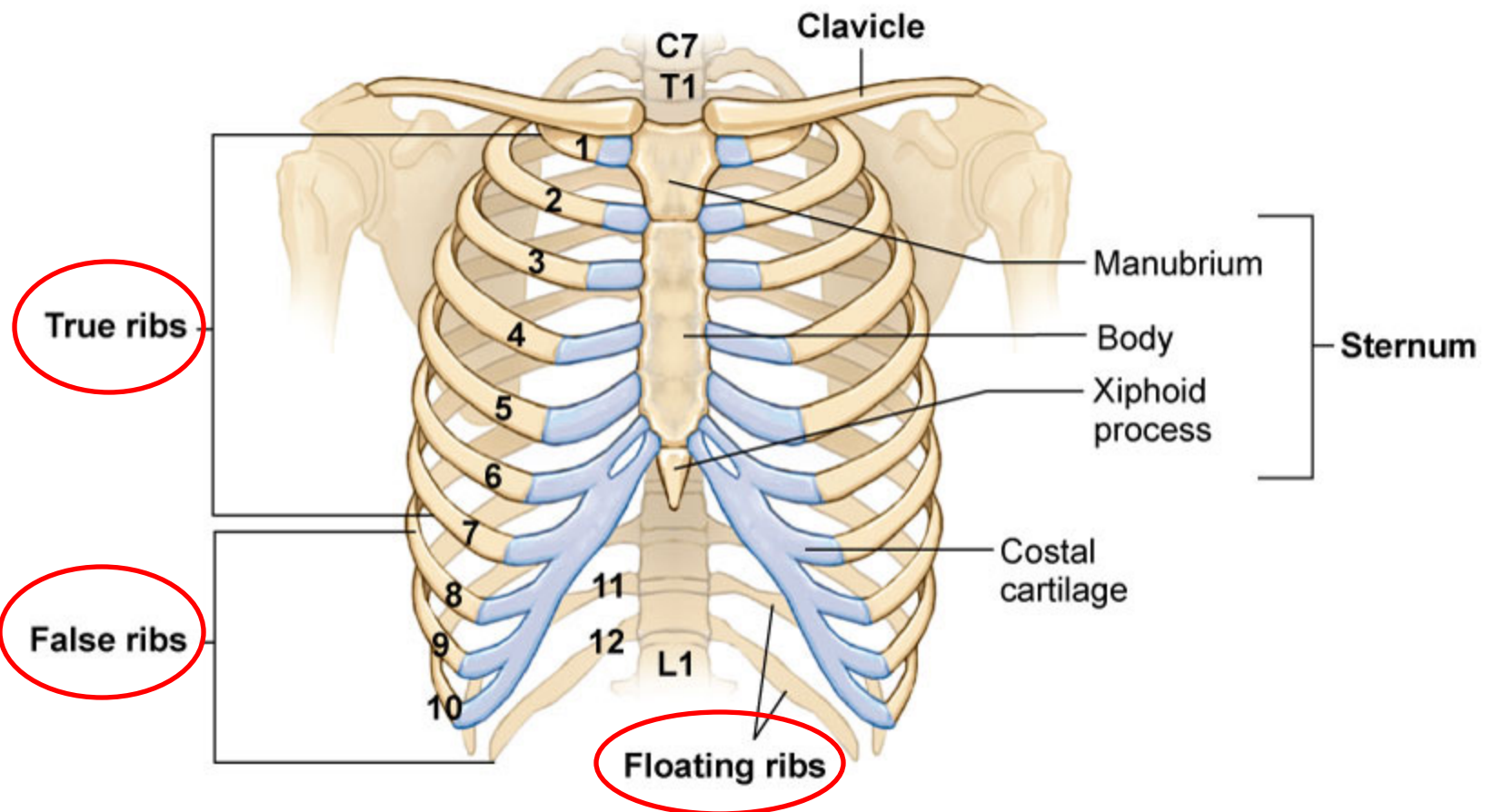




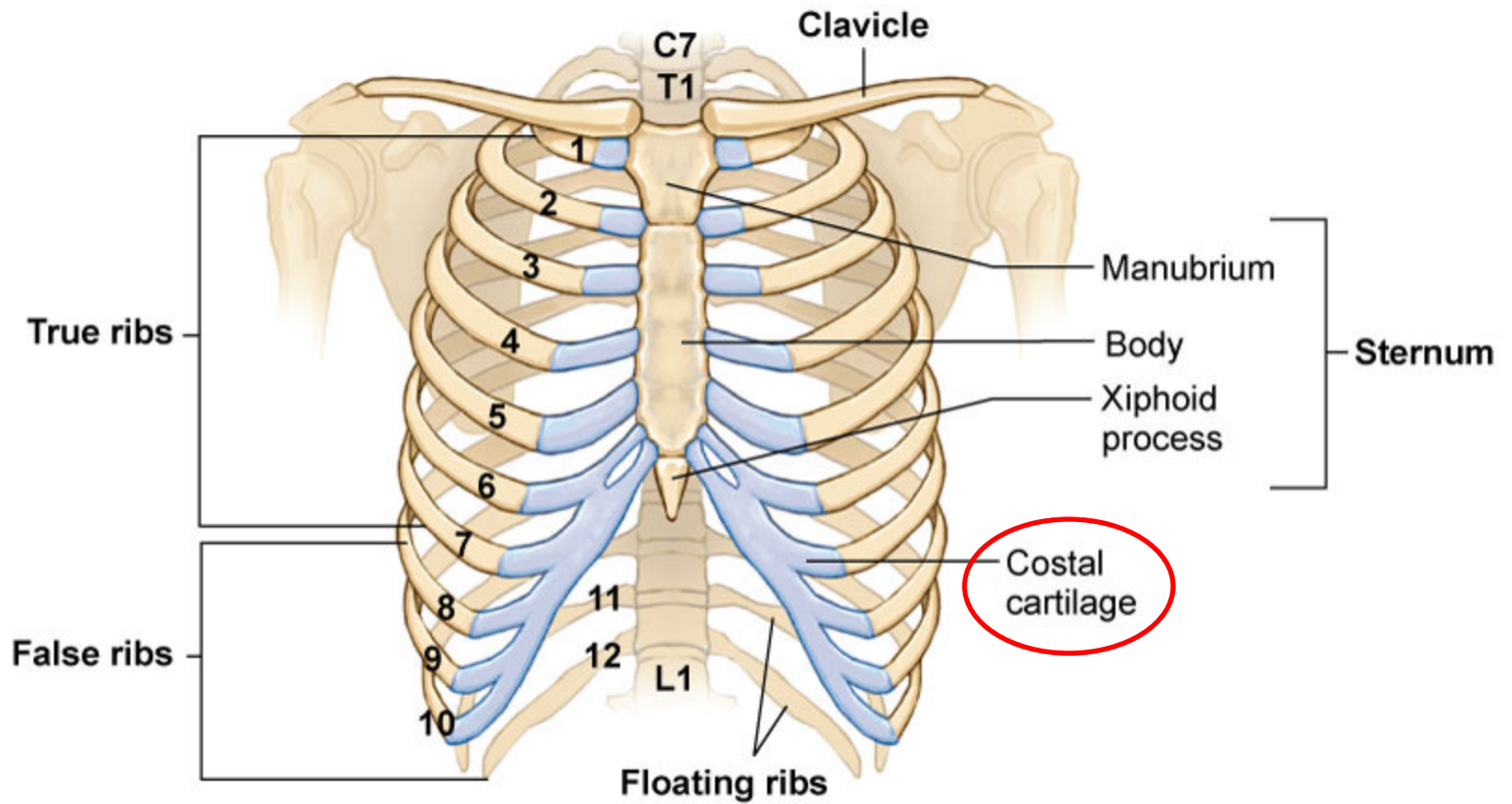
## Pubic Symphysis

- AKA: joint between pubic bones
- NOTE: let the receiver palpate this on themselves while you palpate it on yourself

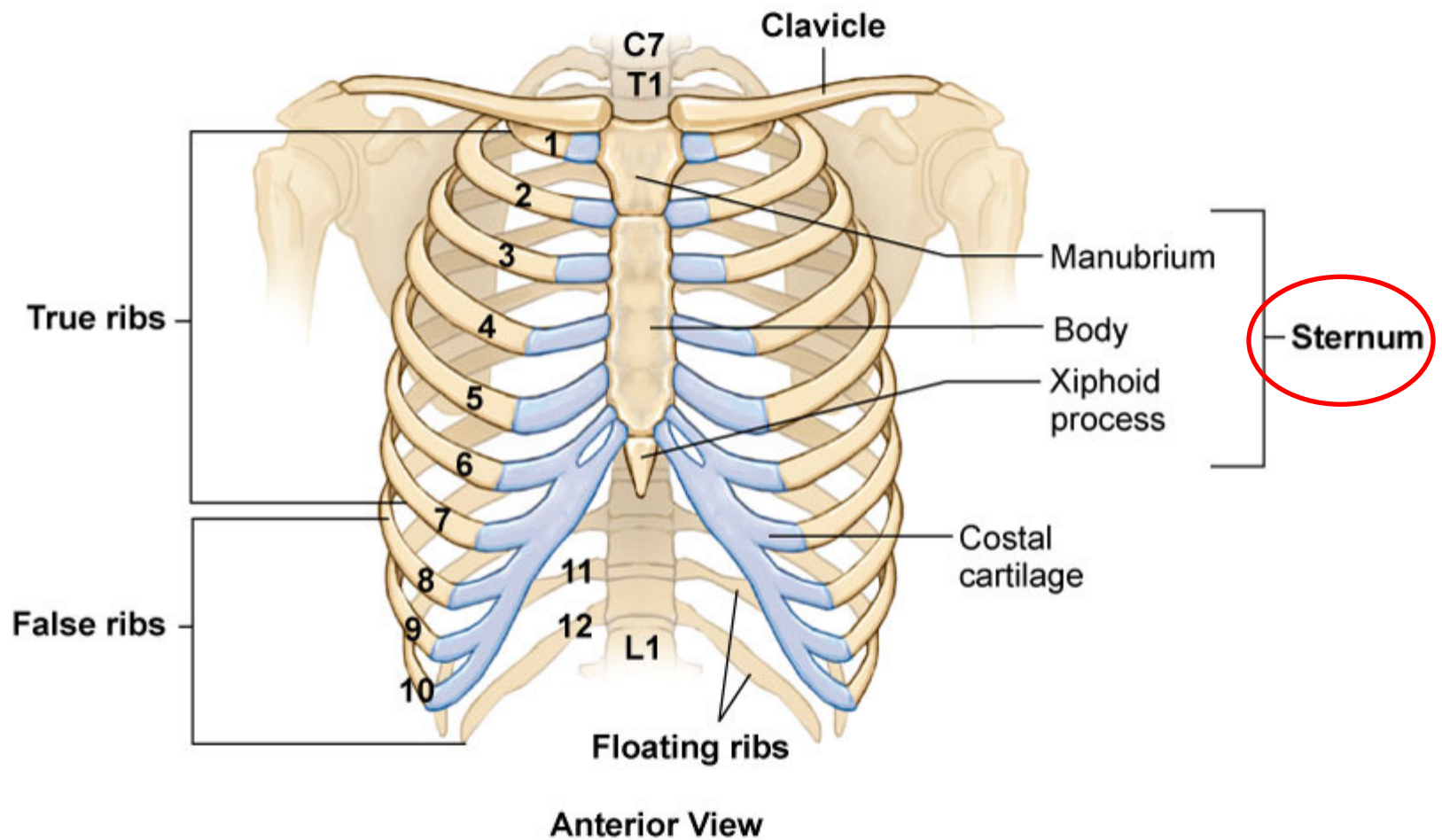




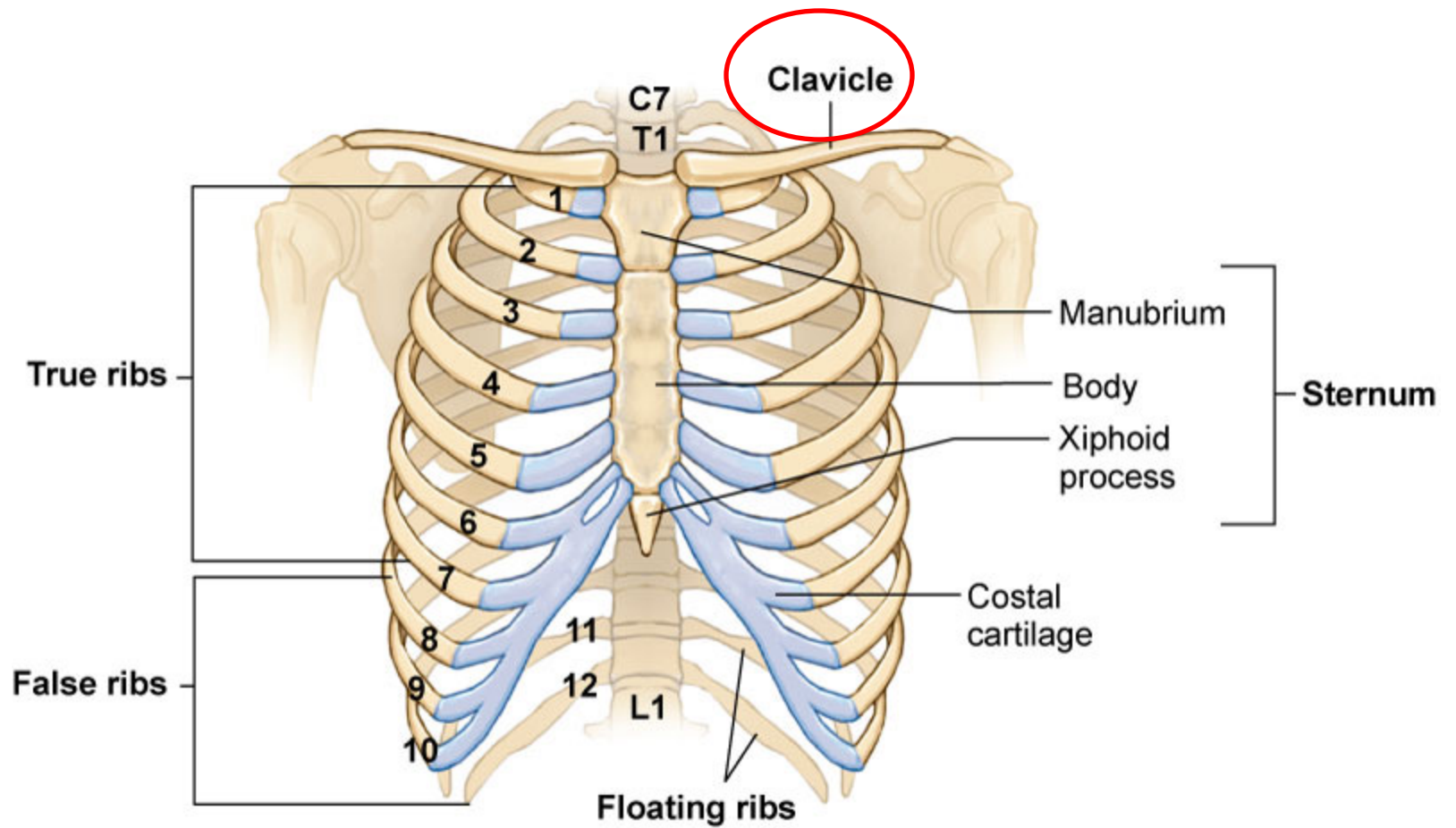
Anterior View



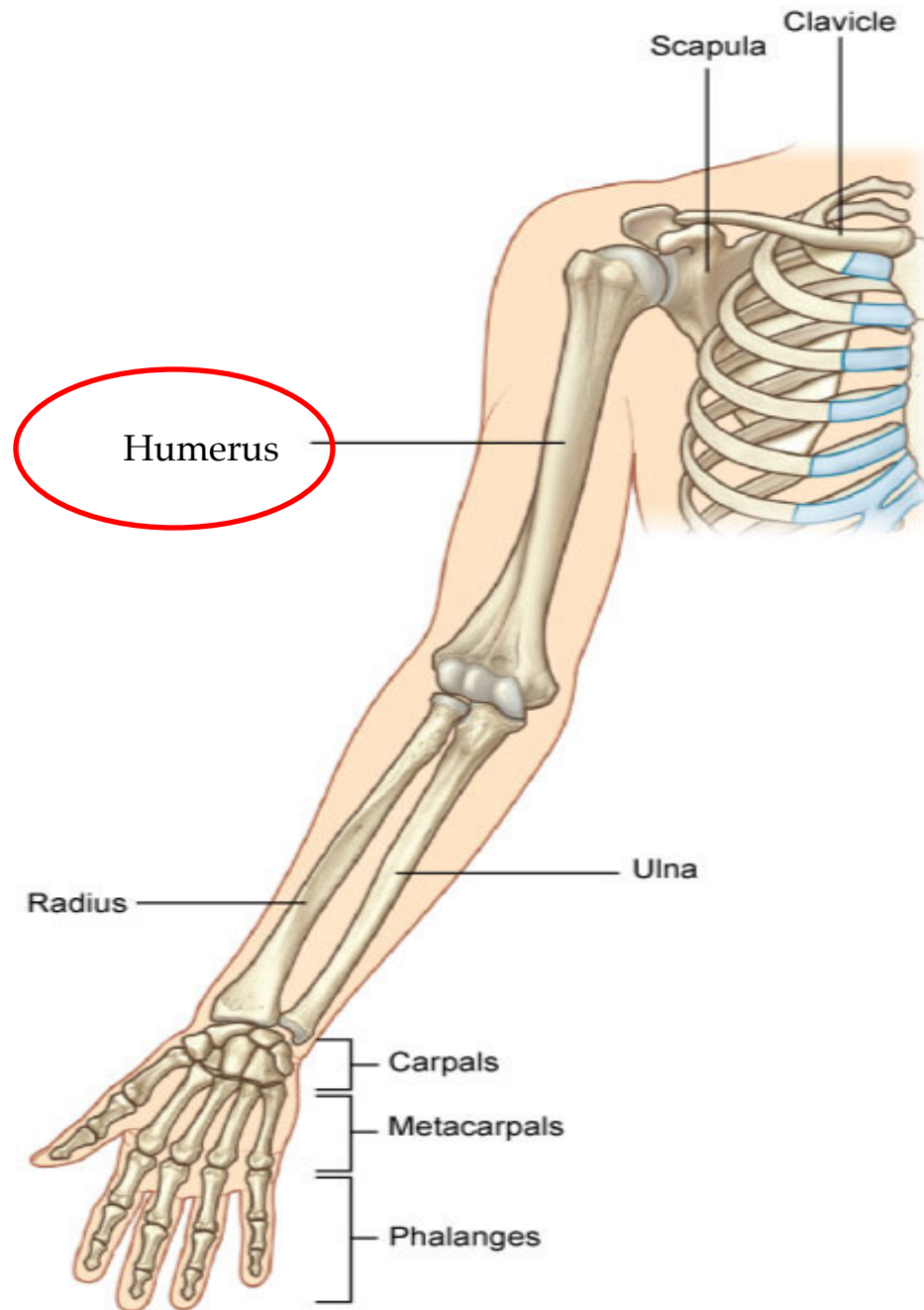
Anterior View



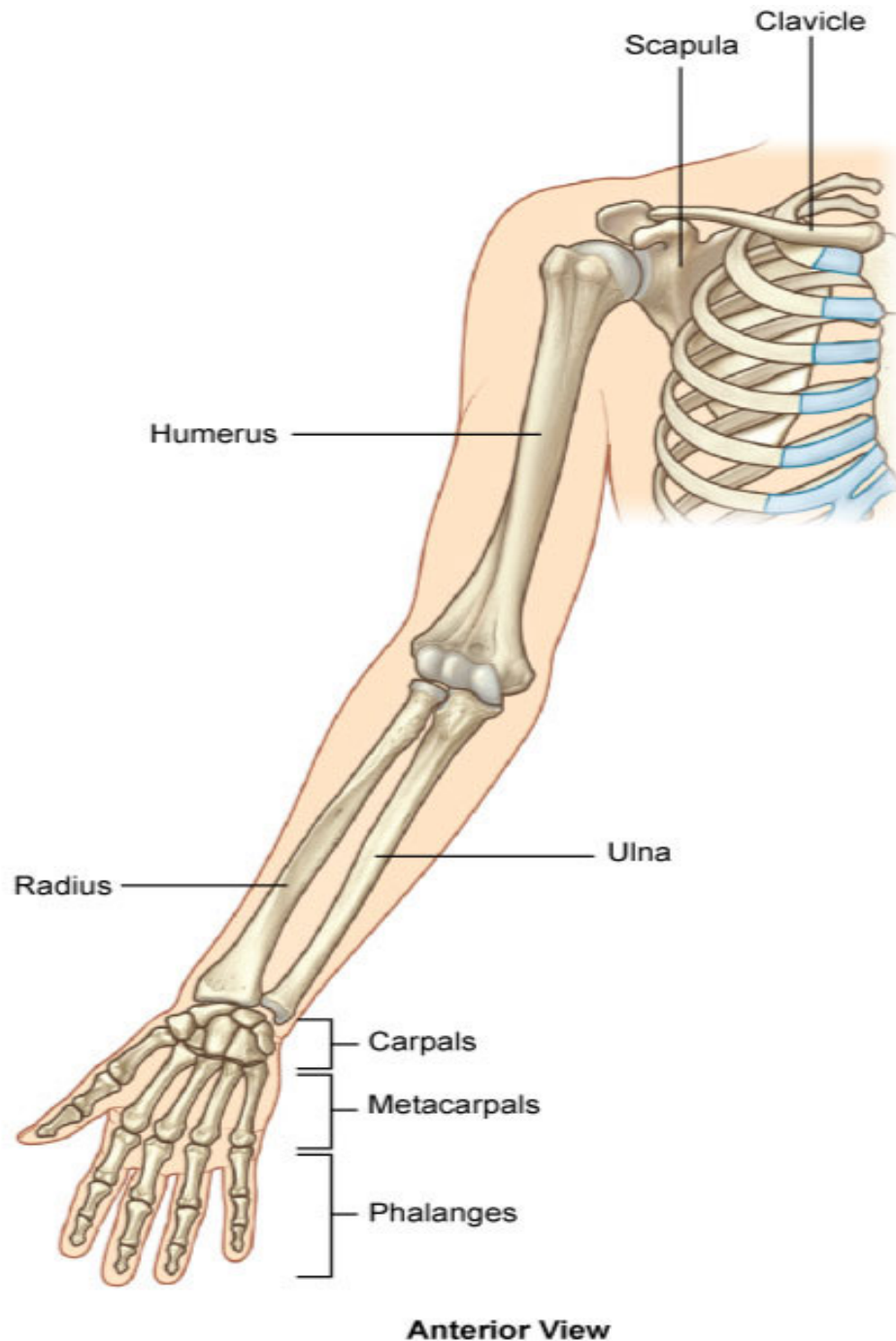
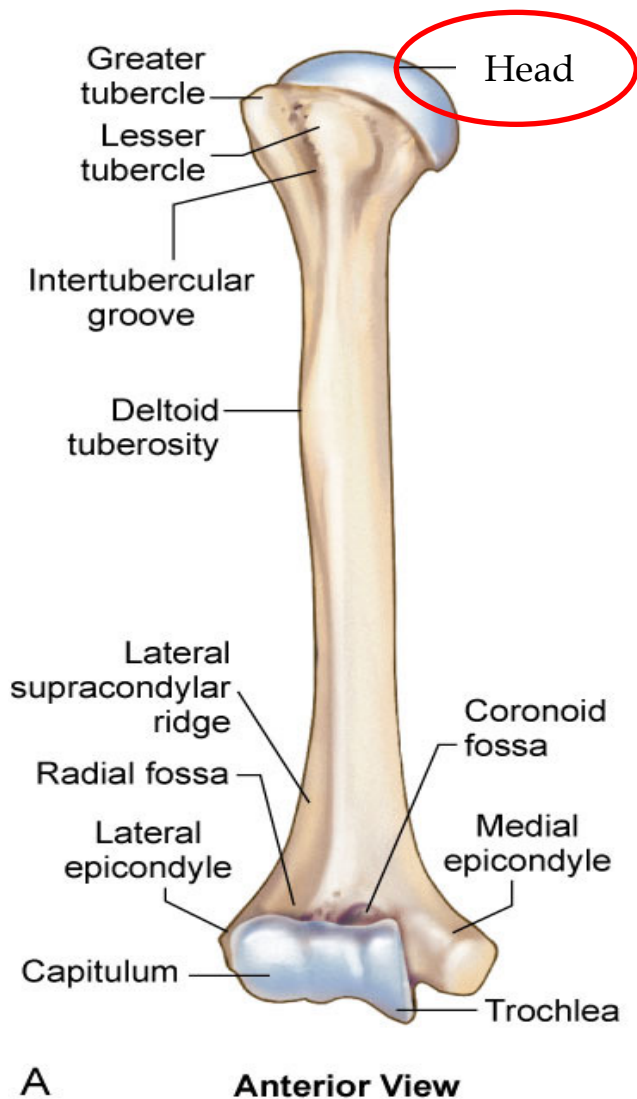




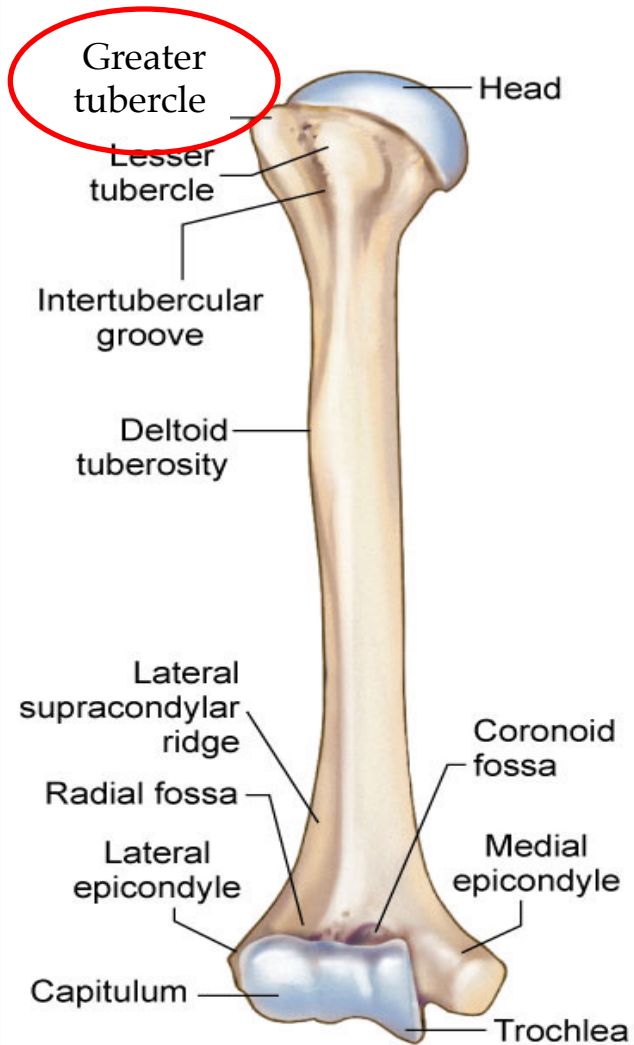
Anterior View



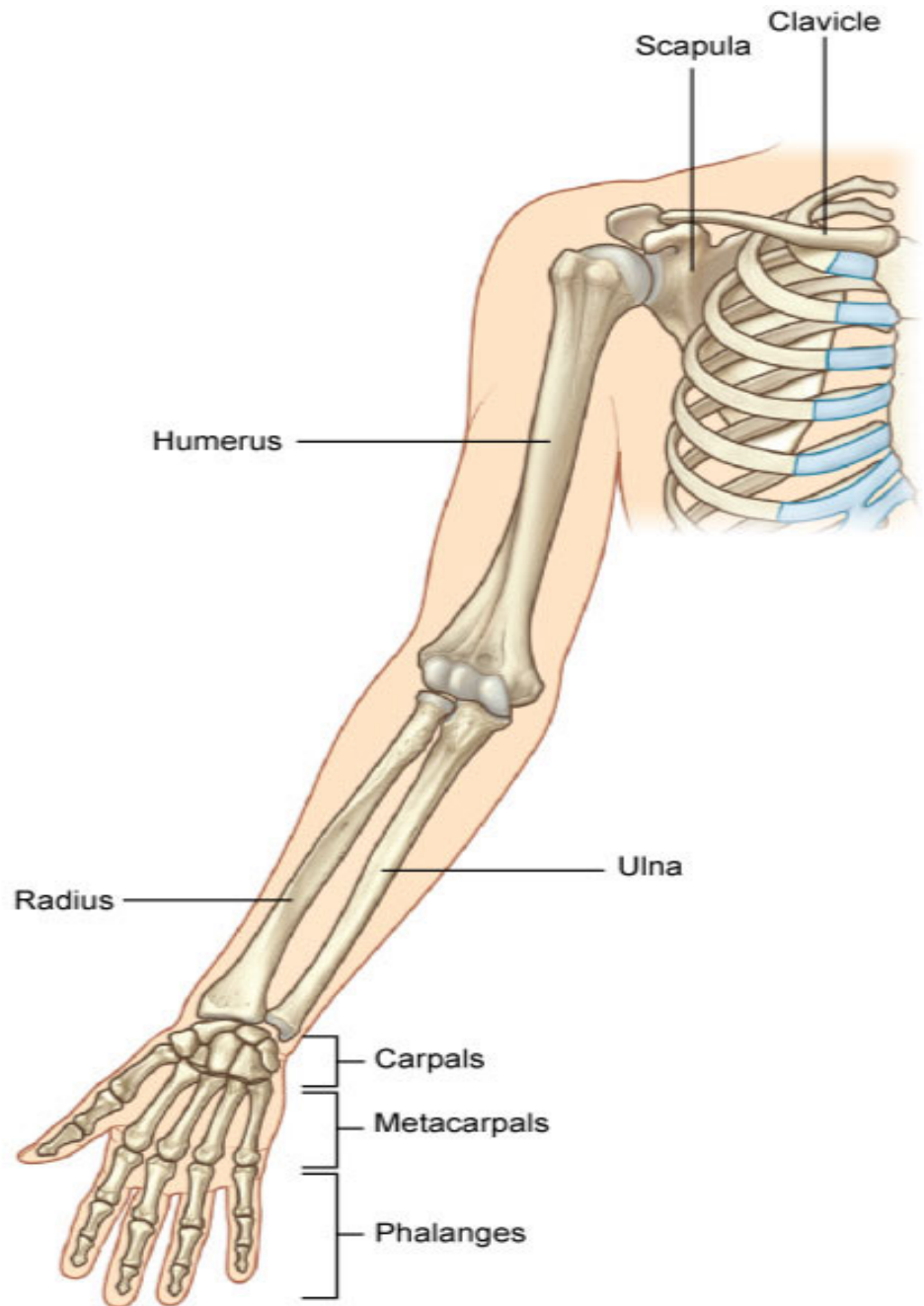
**Anterior View**



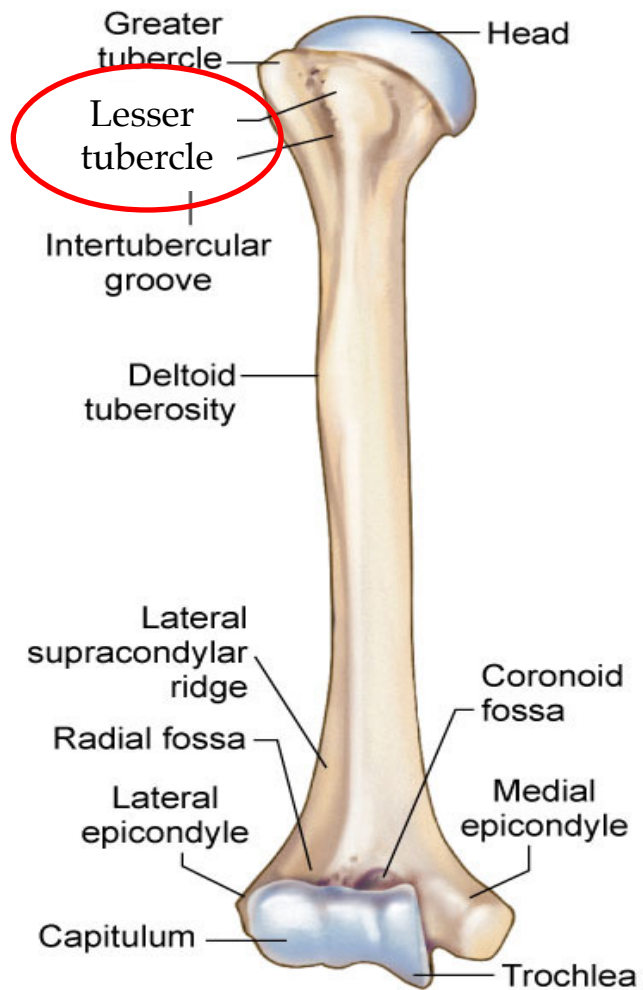




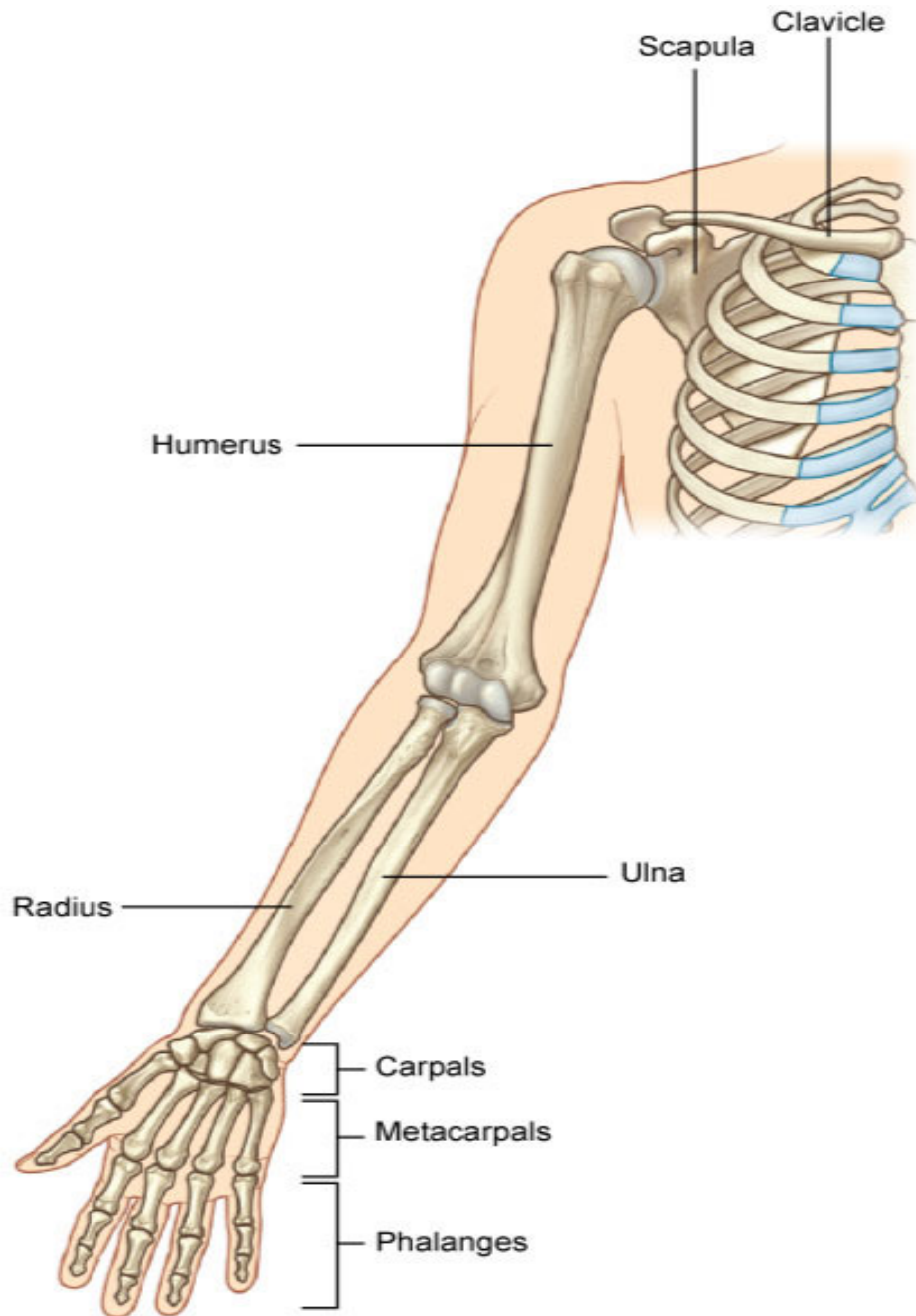
A Anterior View



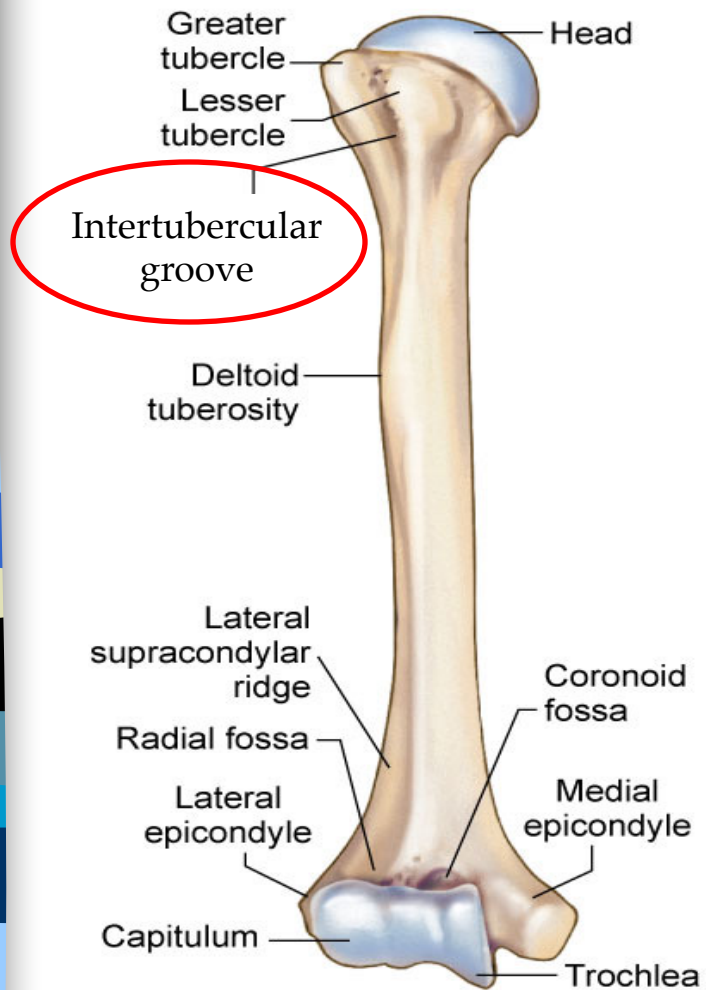
Anterior View



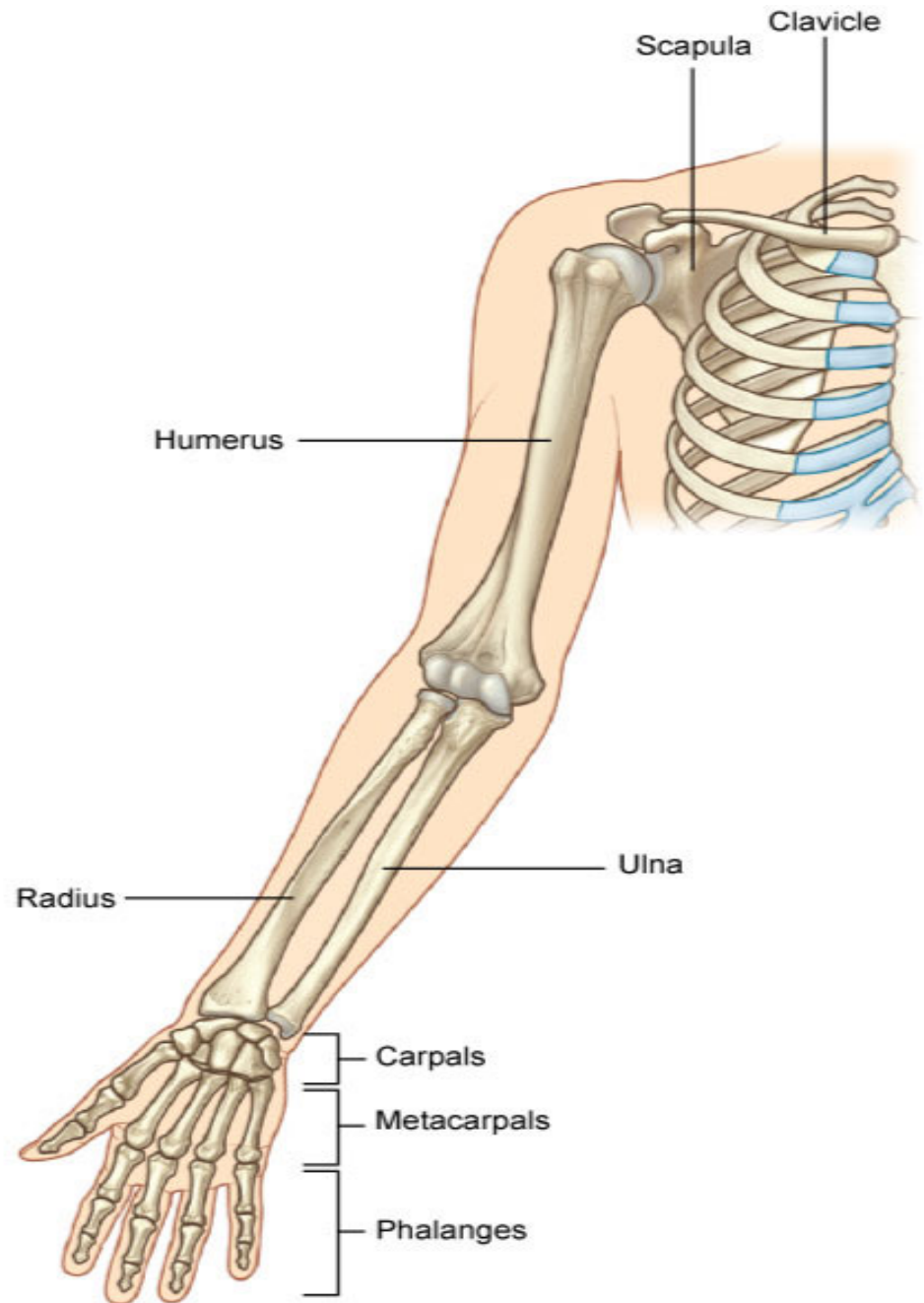
A Anterior View



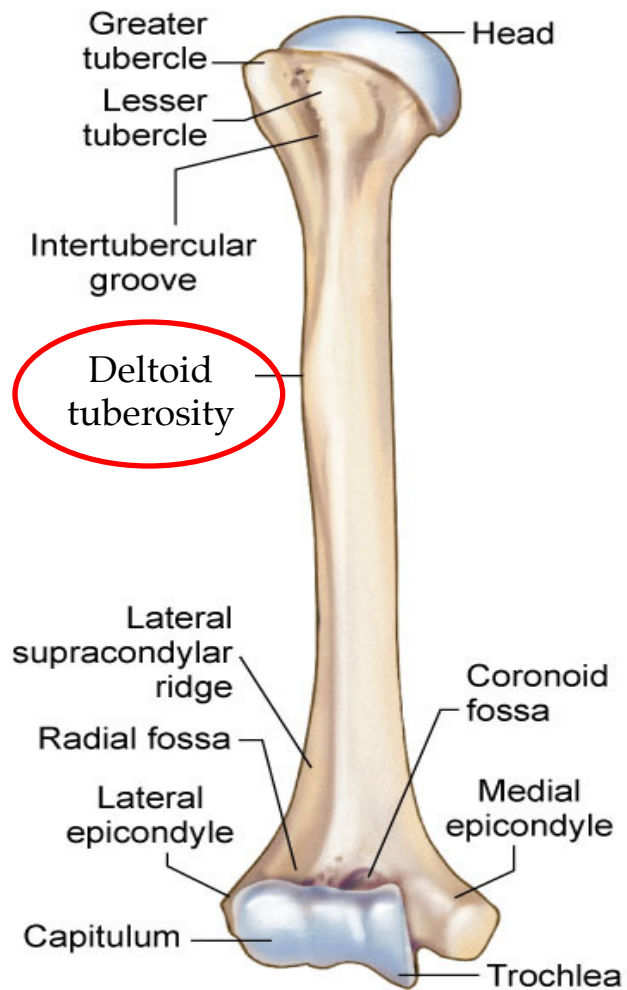
Anterior View



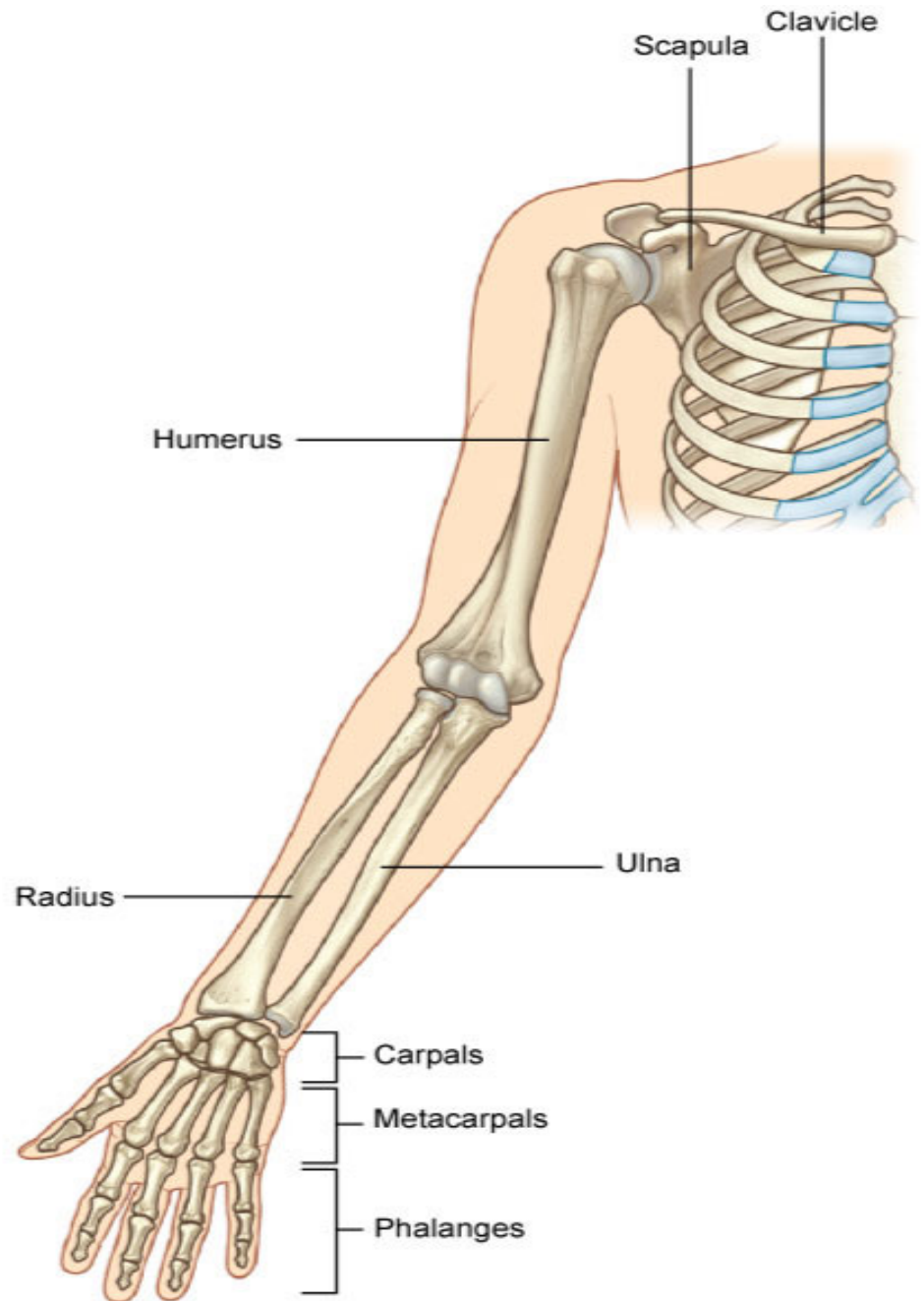
A Anterior View



Anterior View

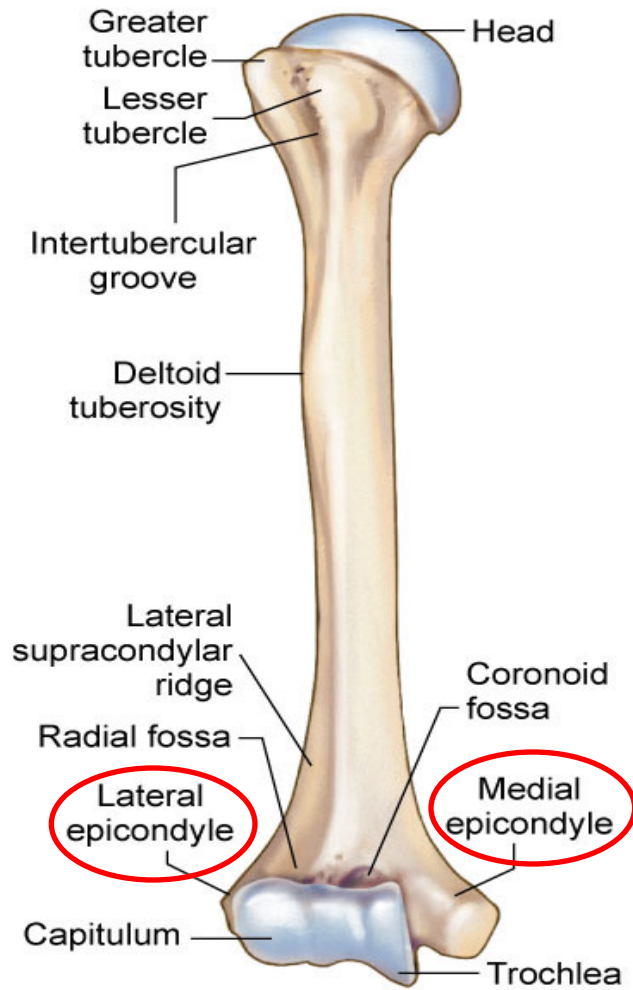


A Anterior View

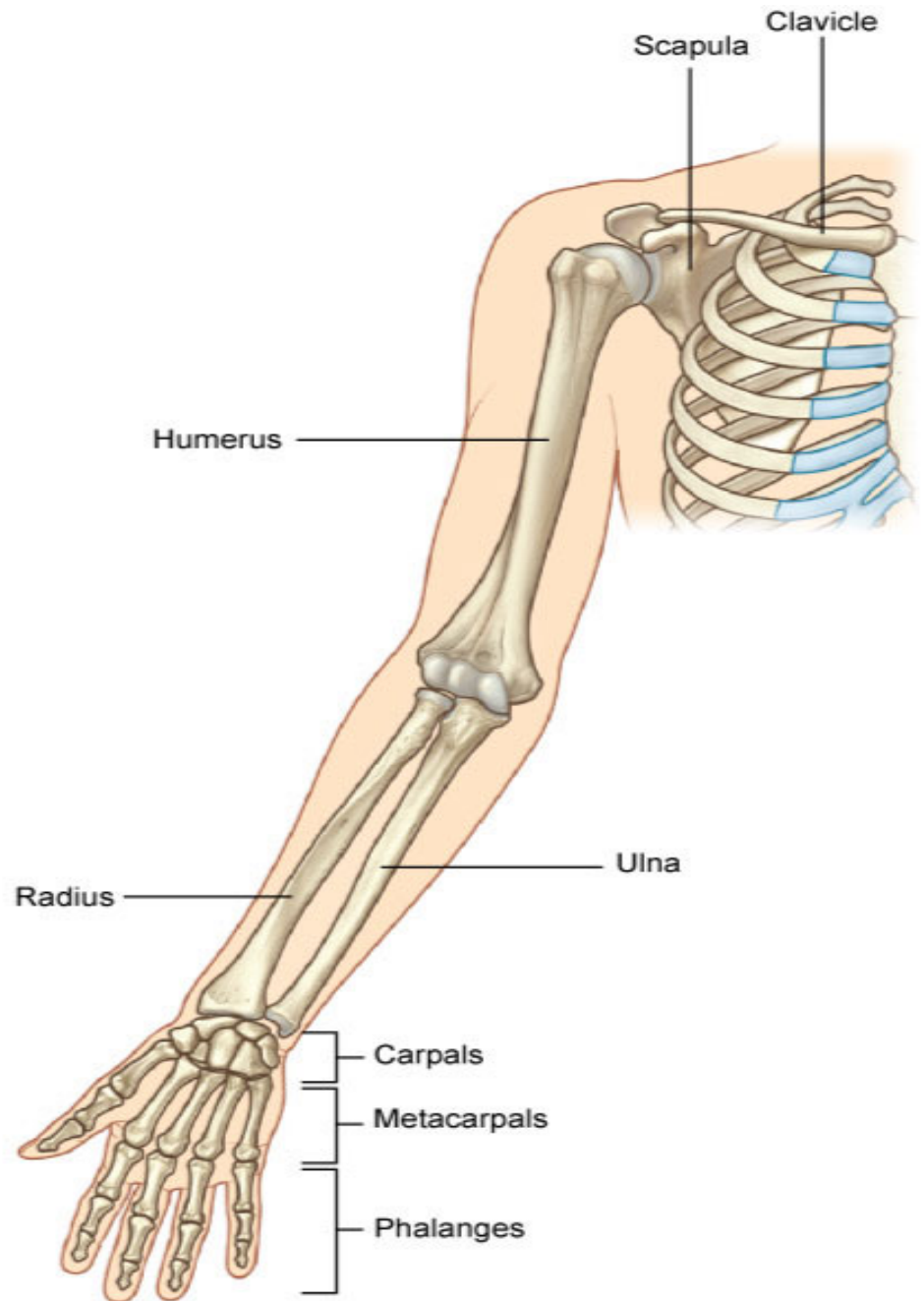


Anterior View

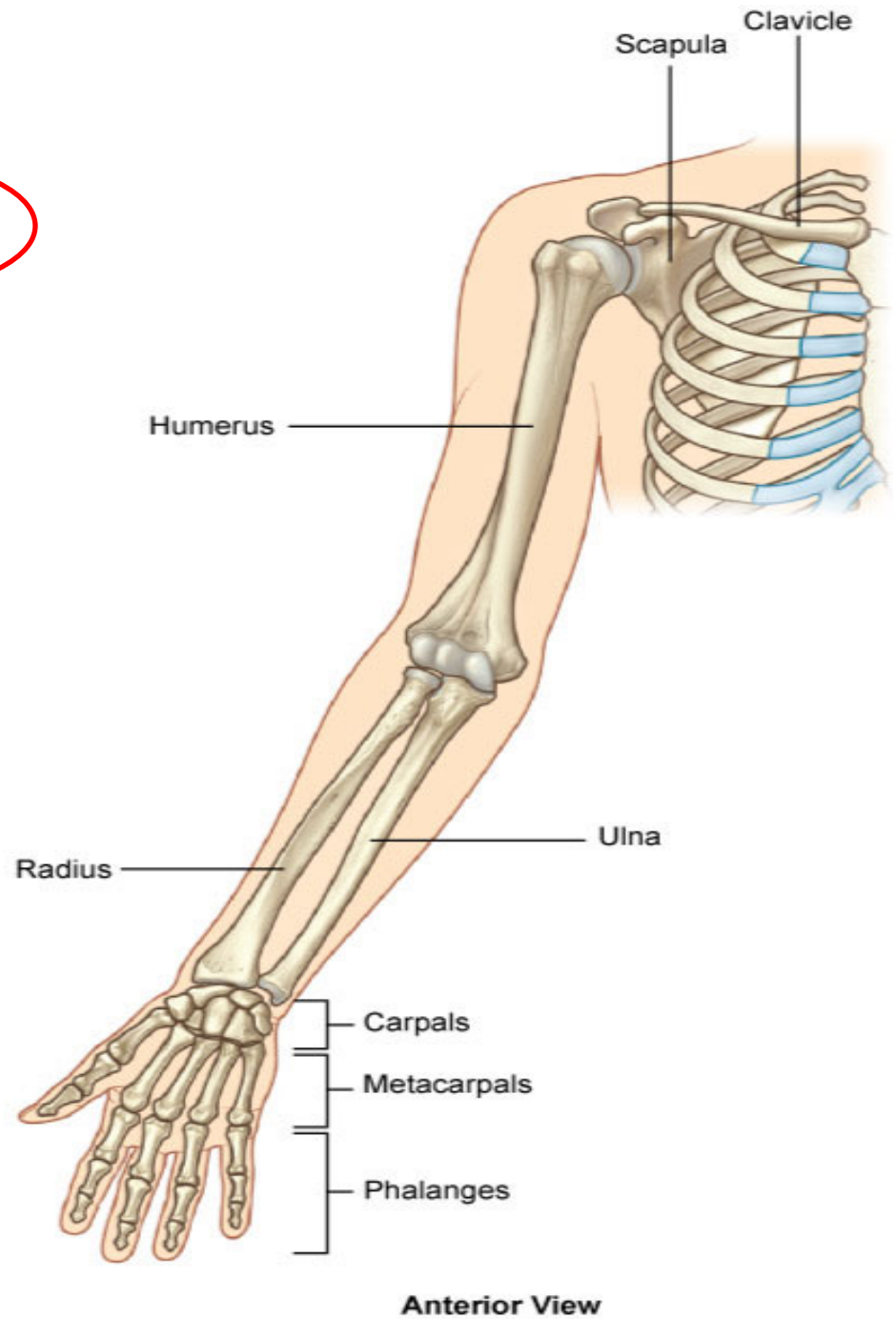
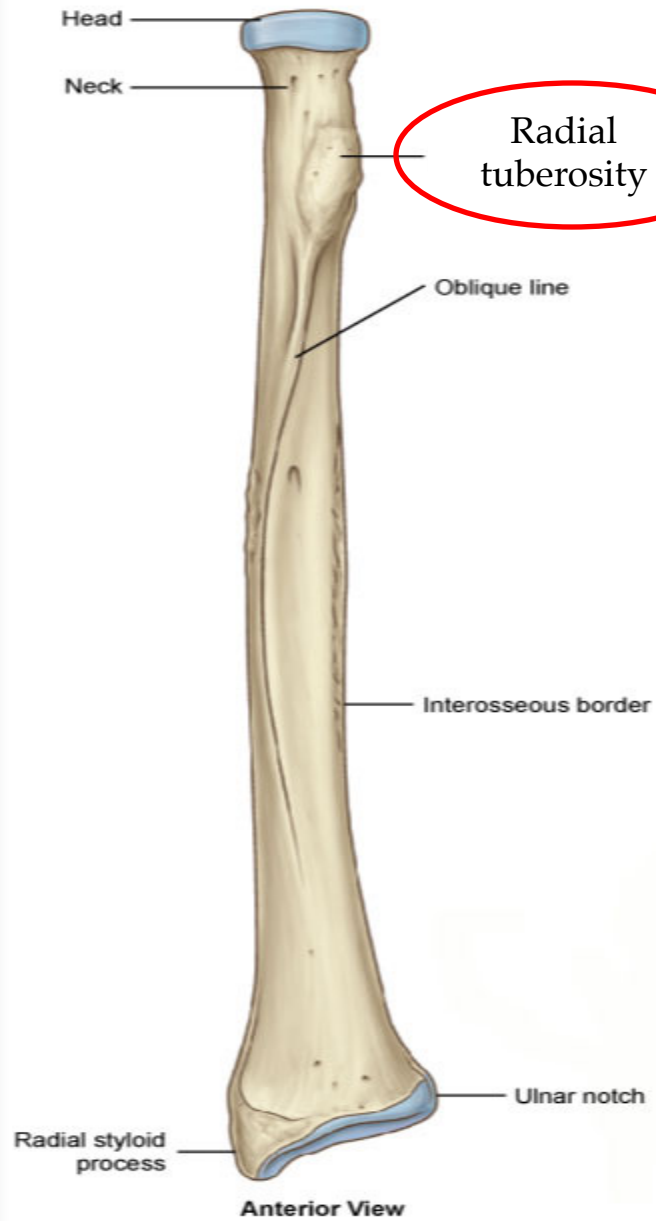


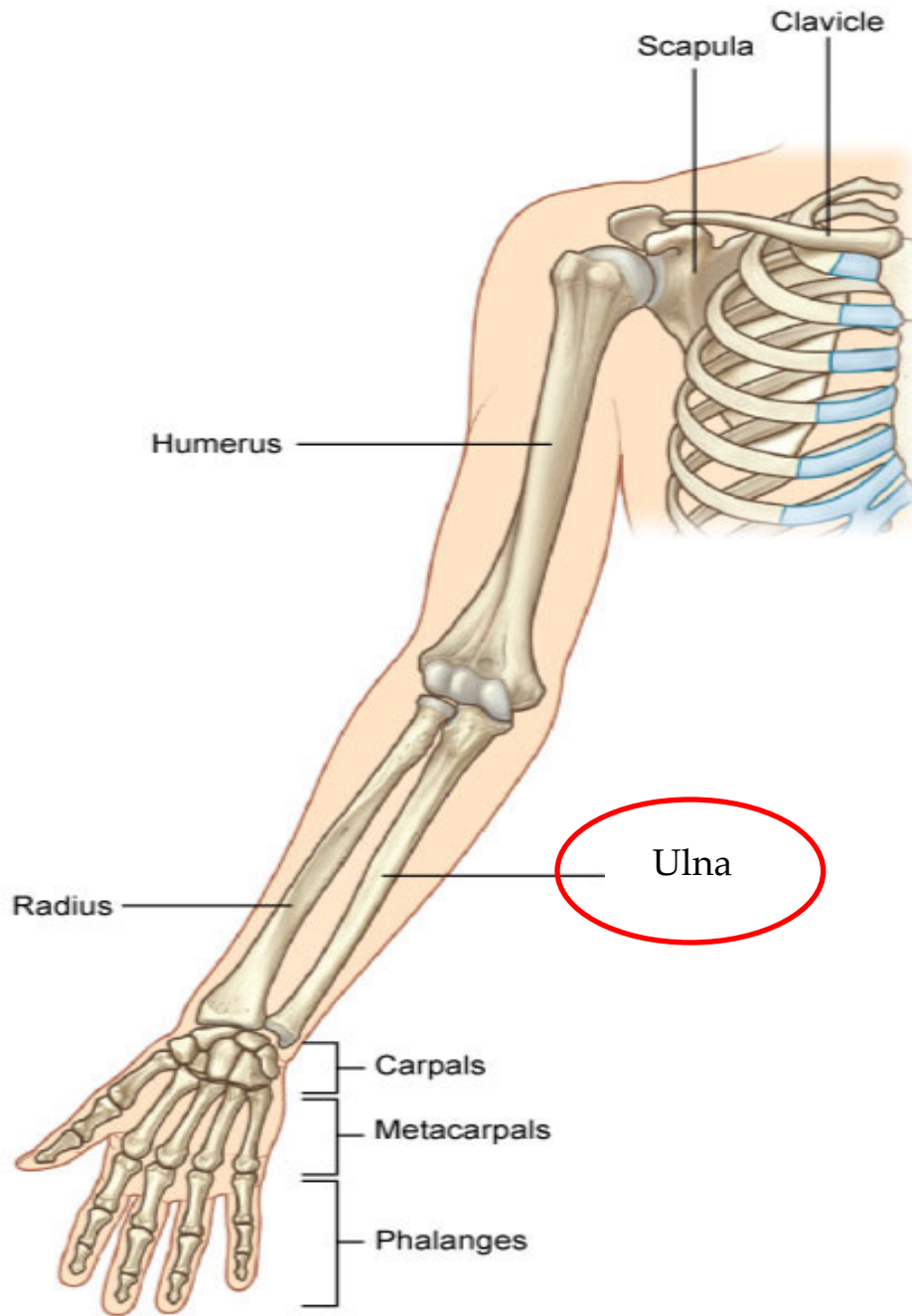


A Anterior View



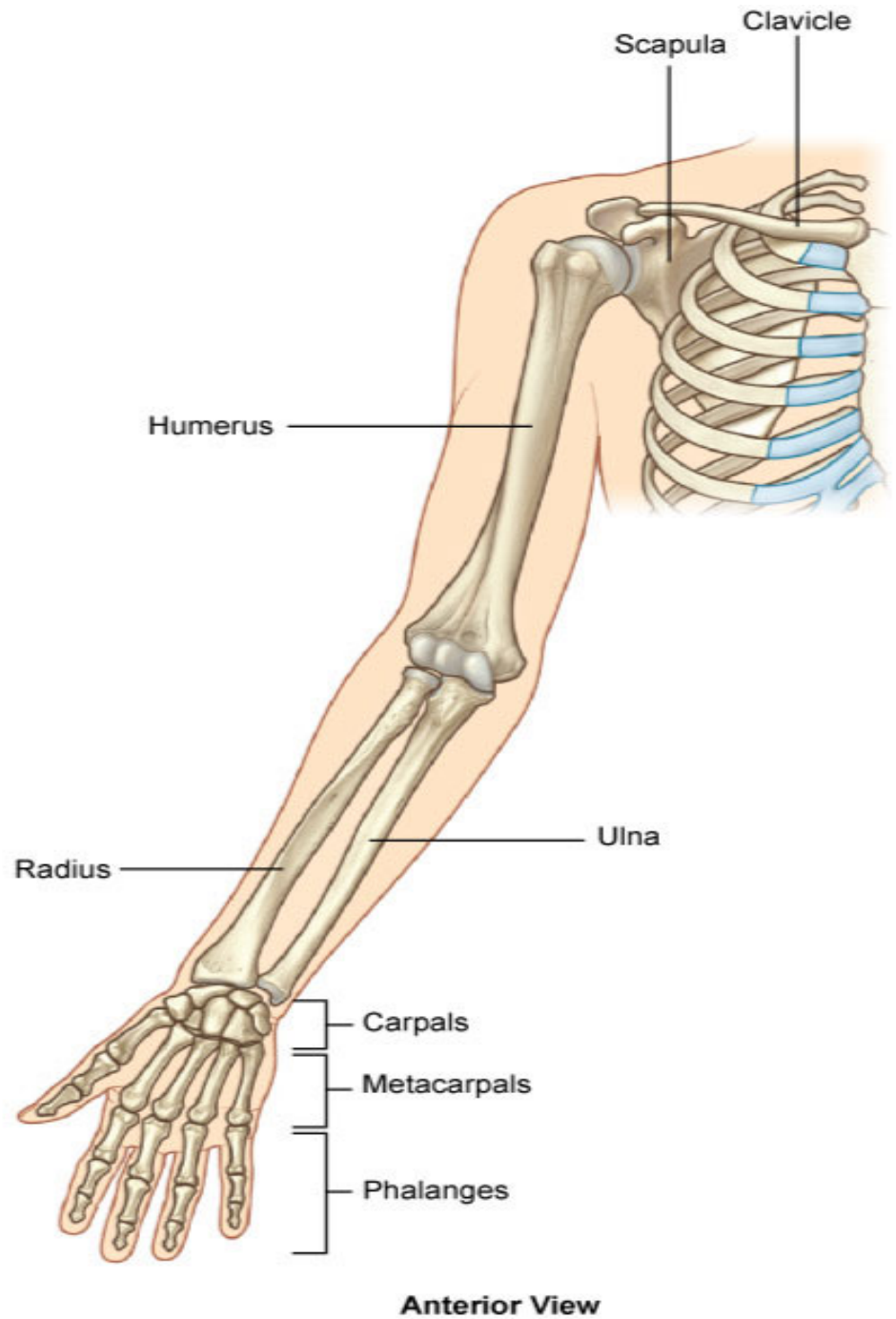
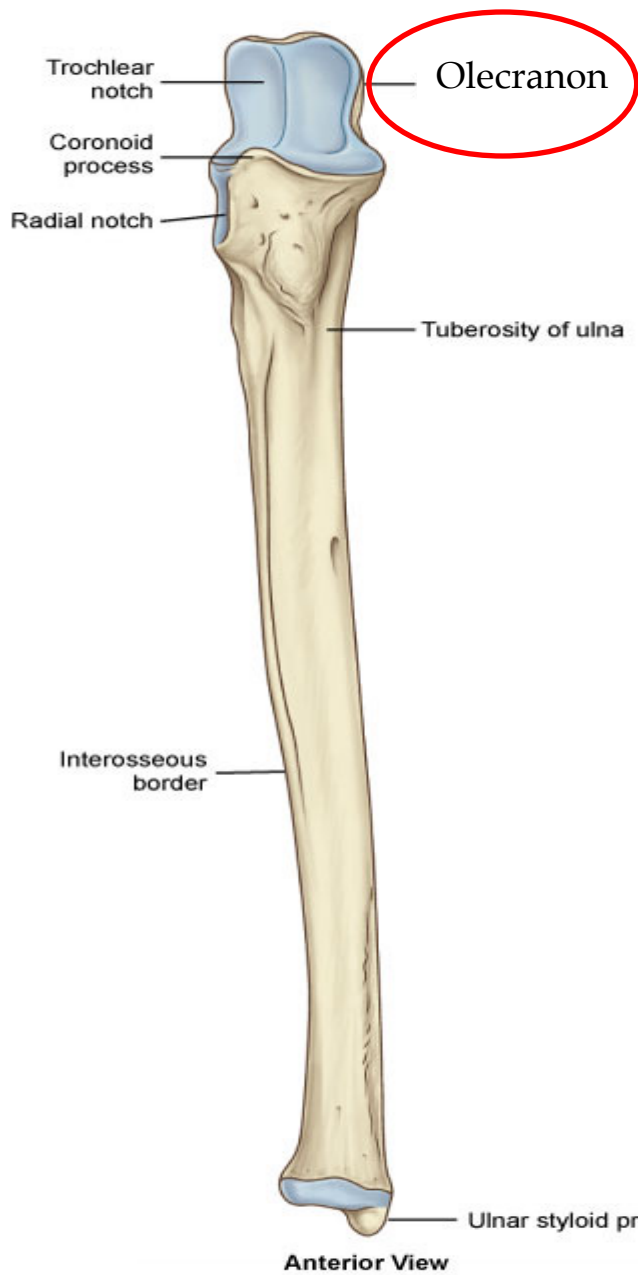
Anterior View

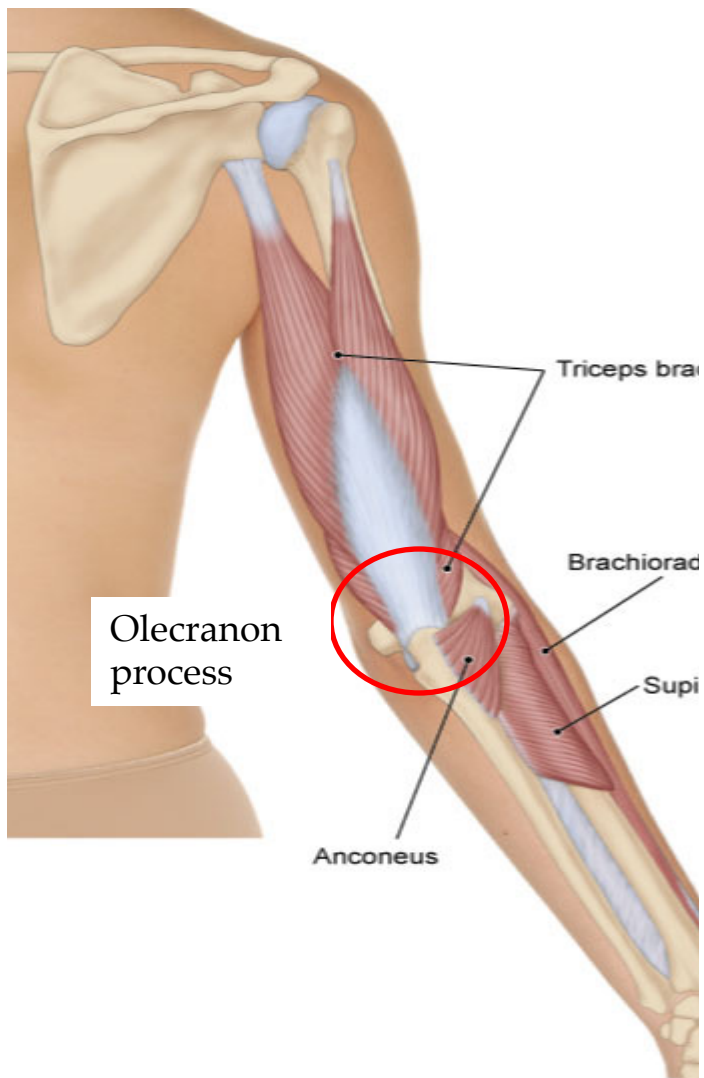



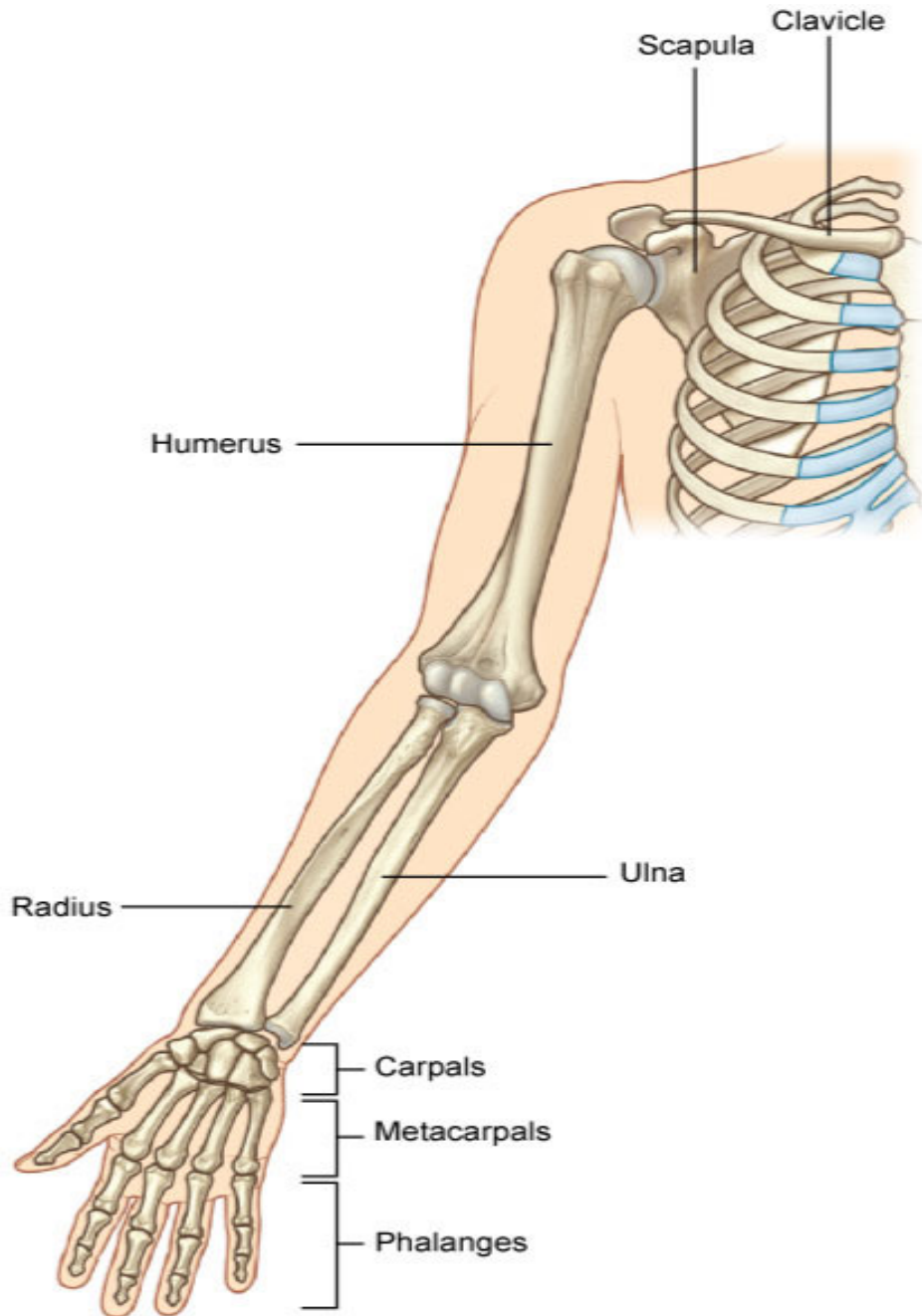
**Anterior View**



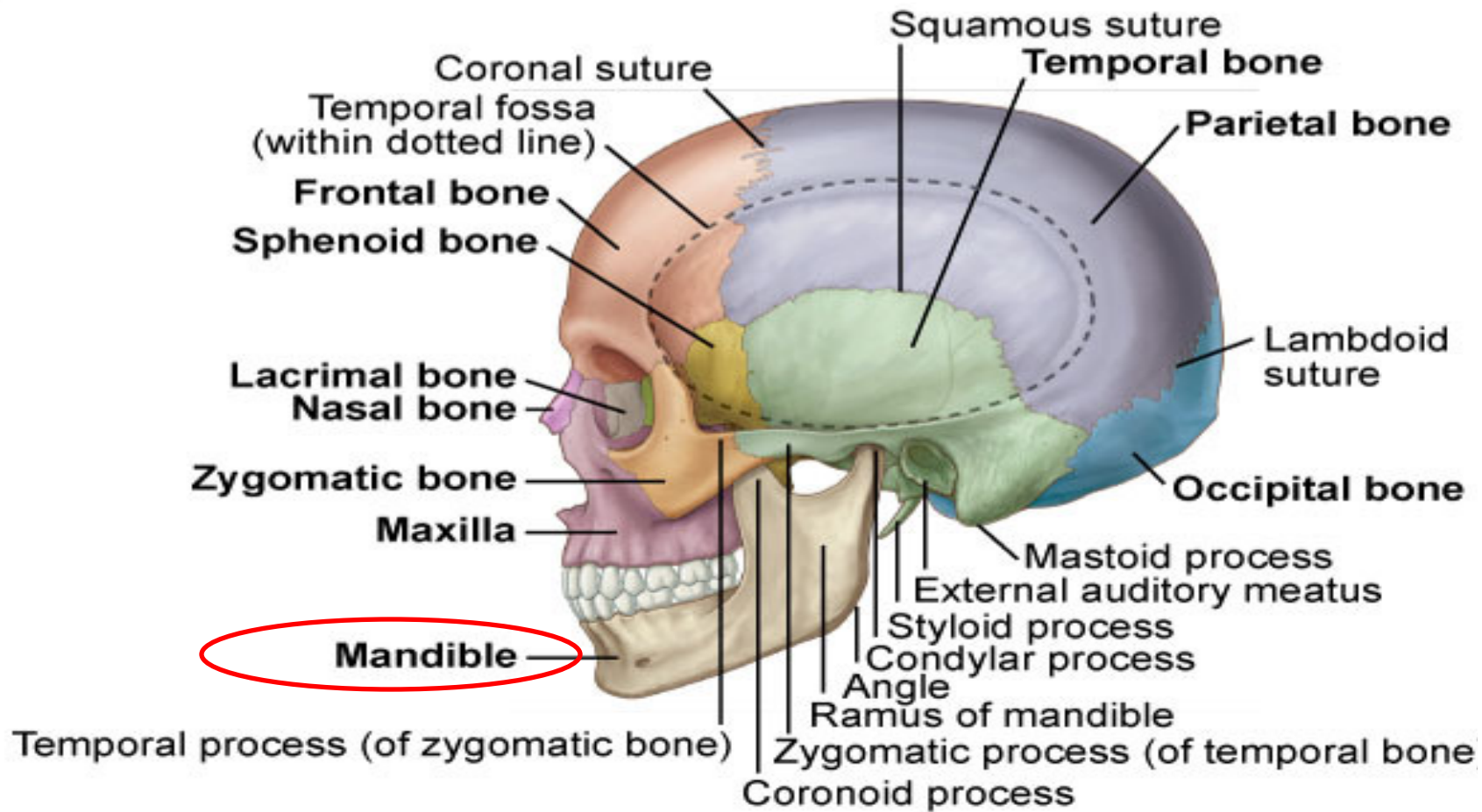




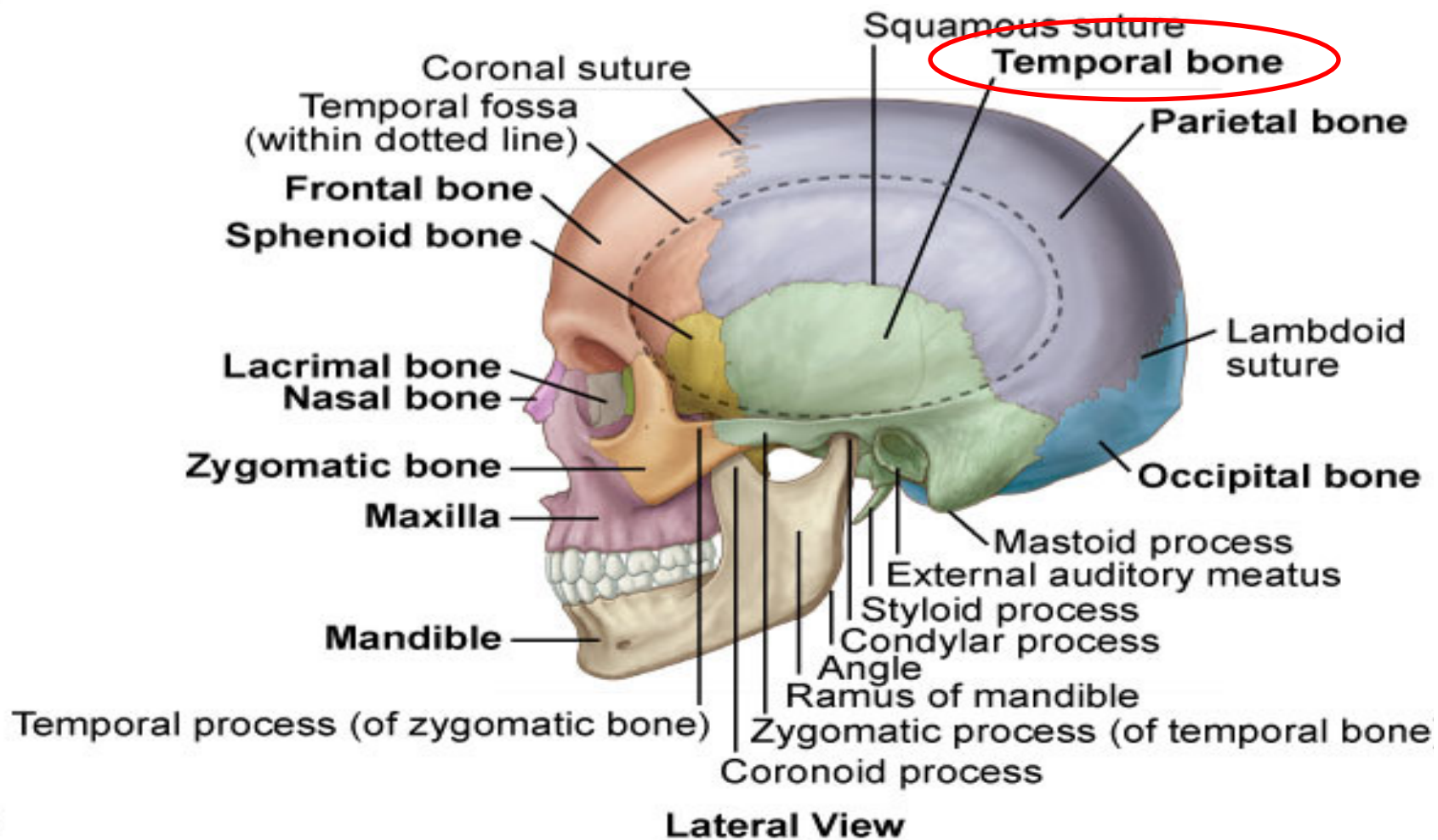
Posterior View



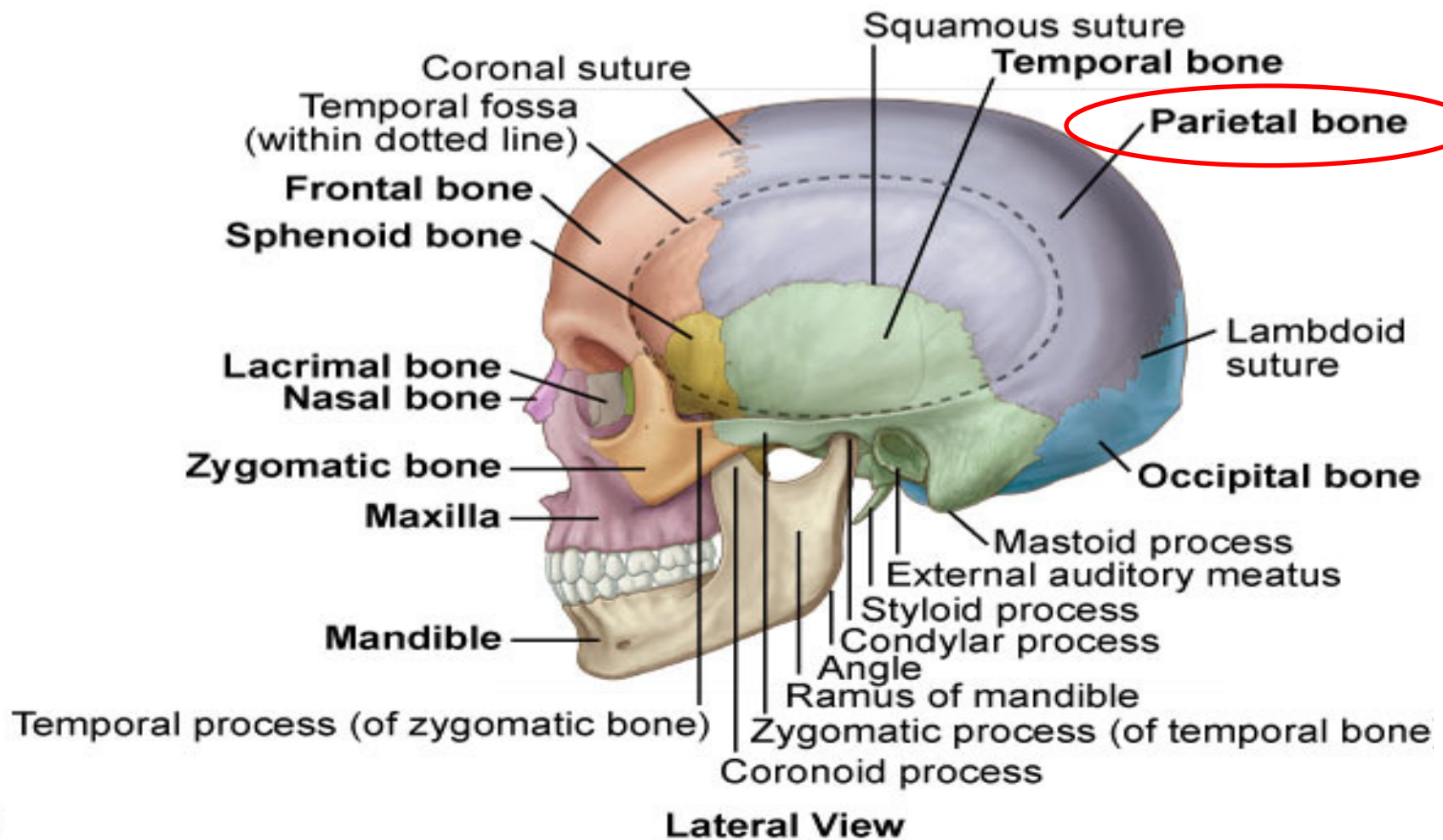
Anterior View

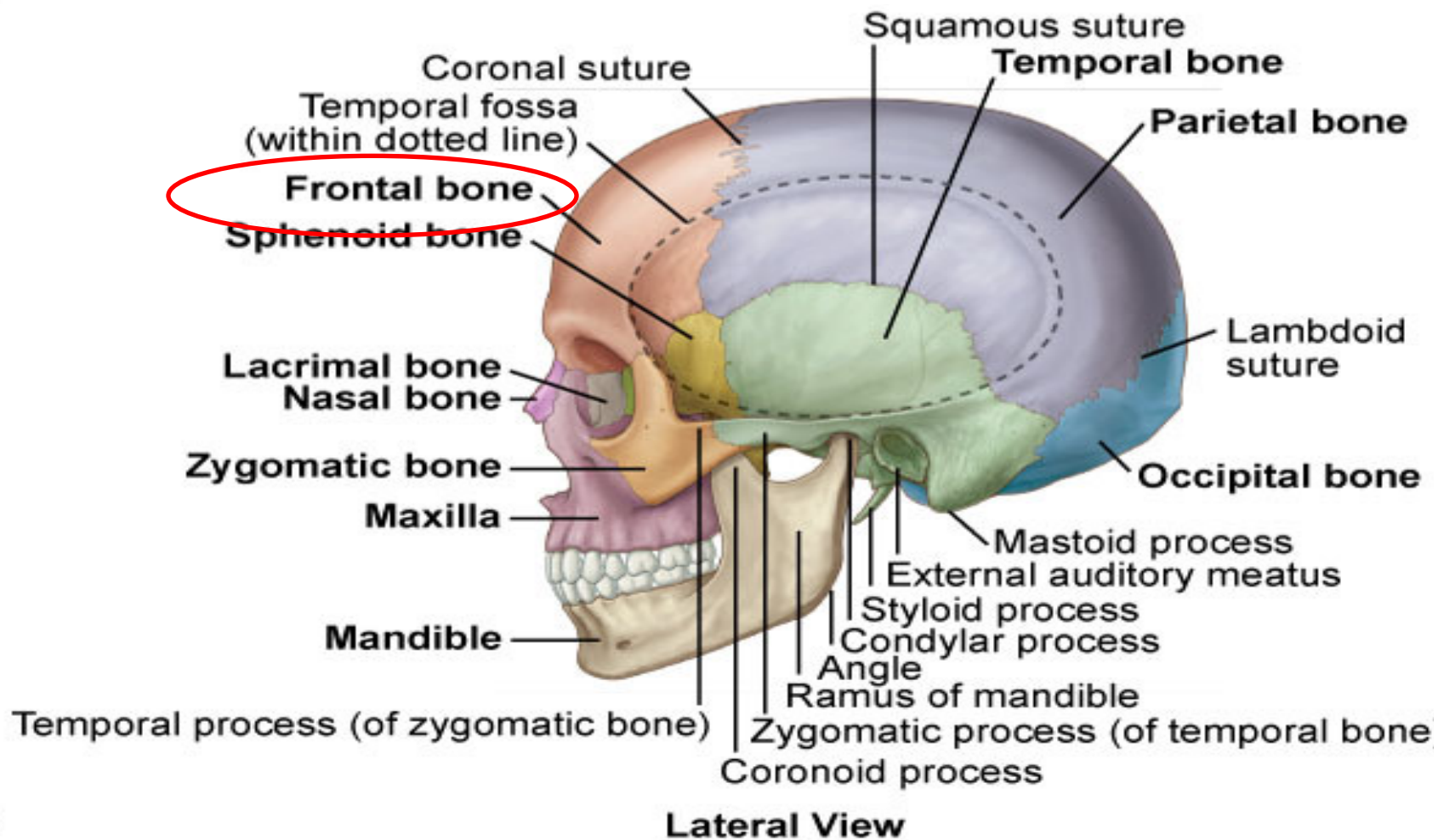


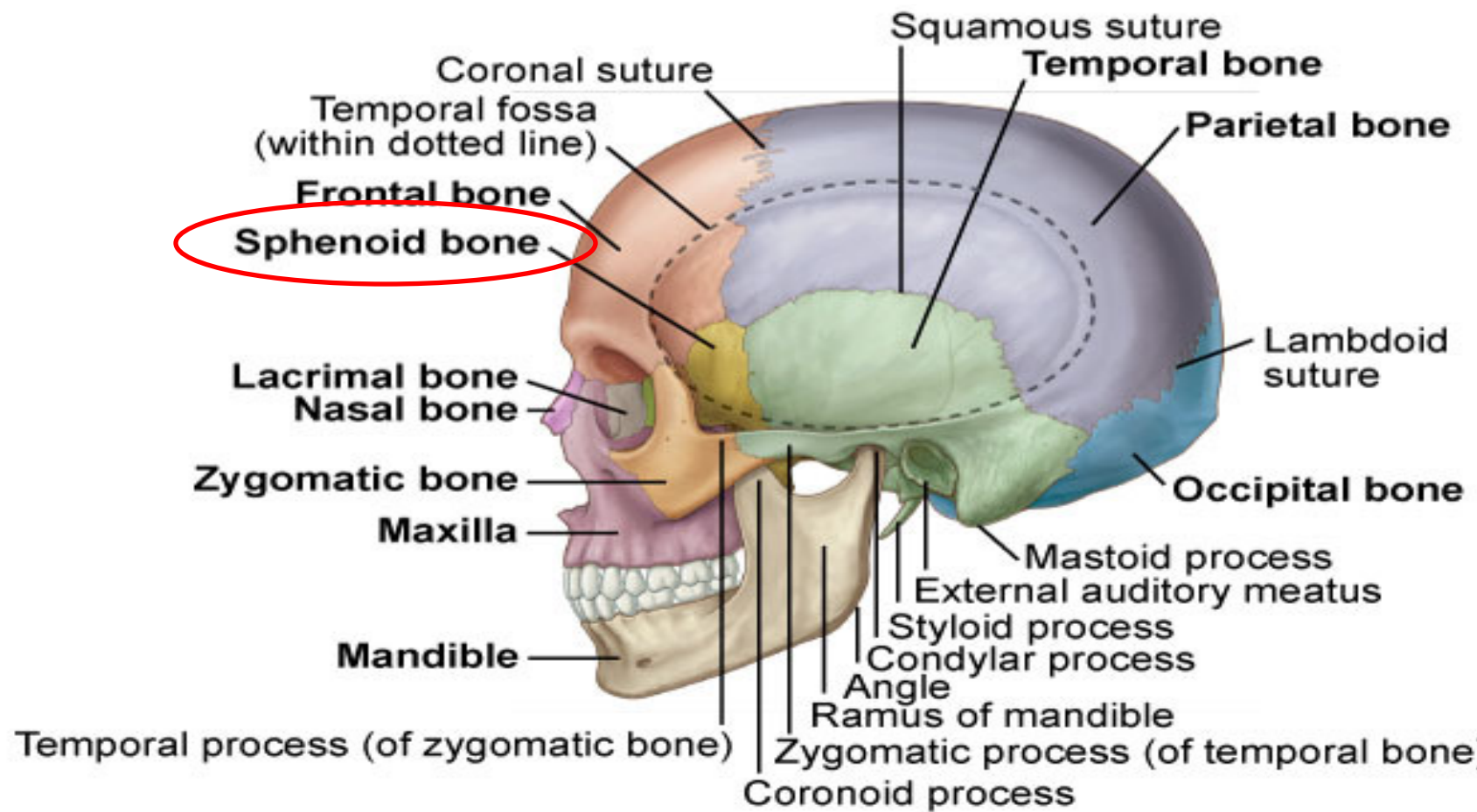
**Lateral View**





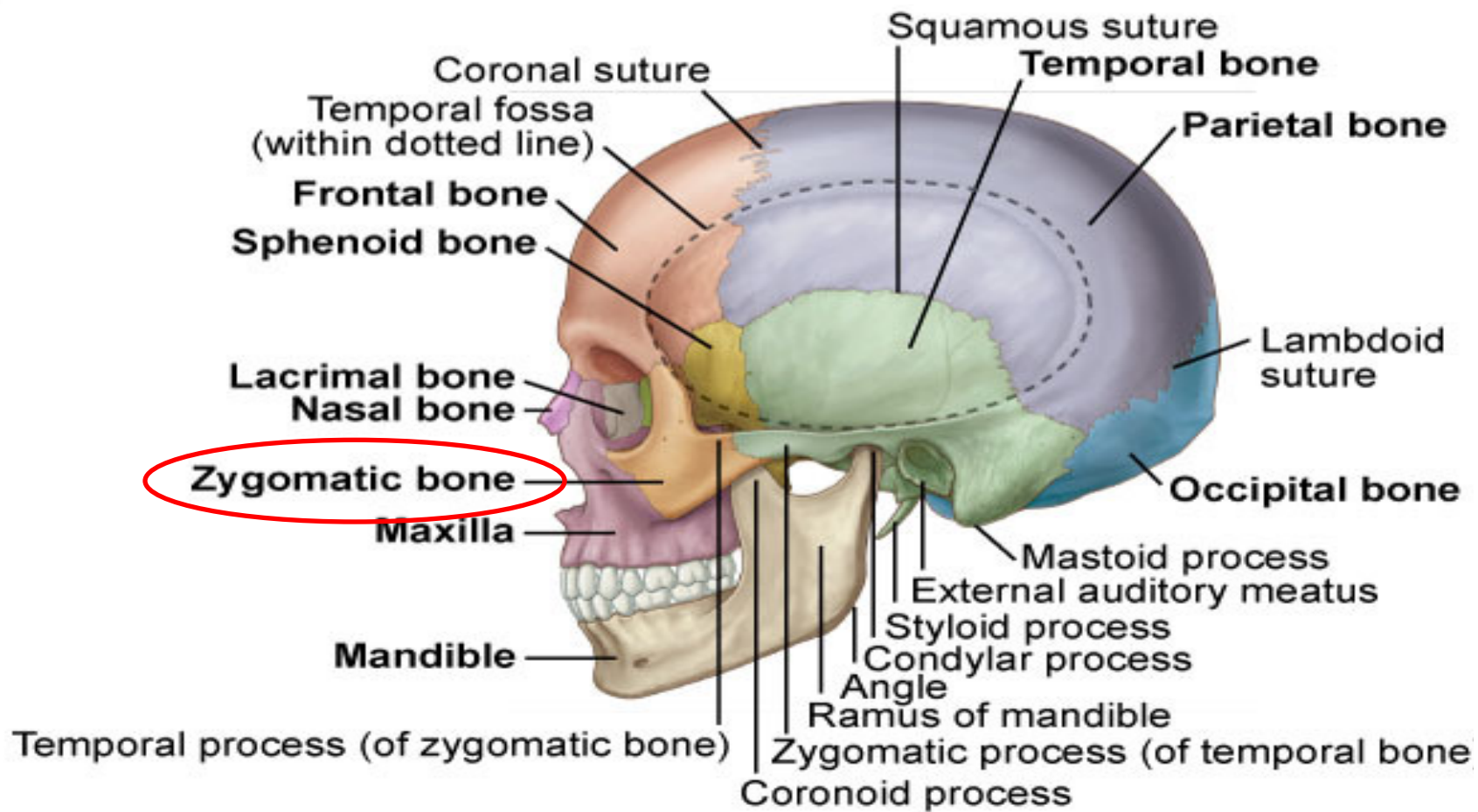







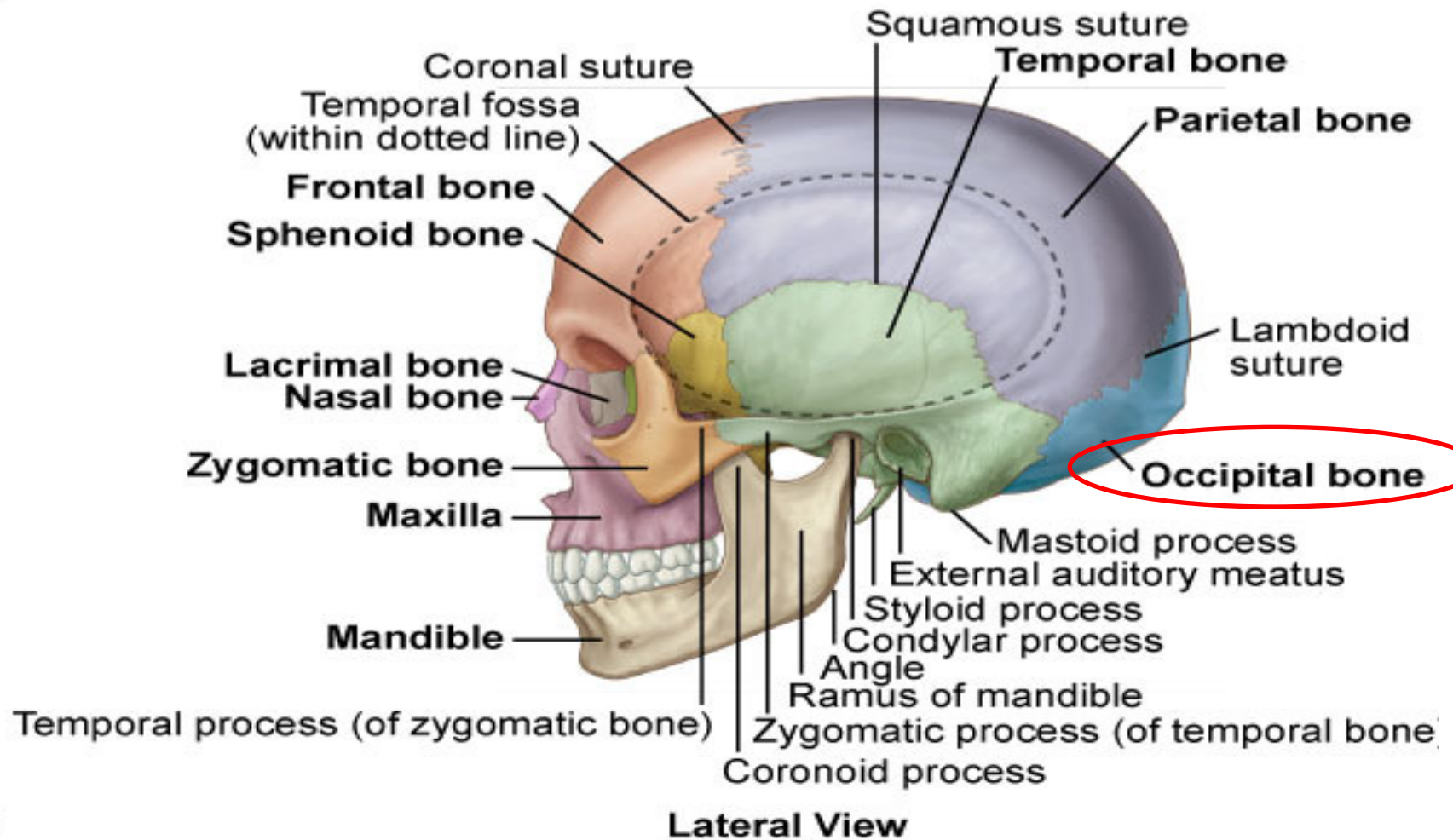
**Lateral View**

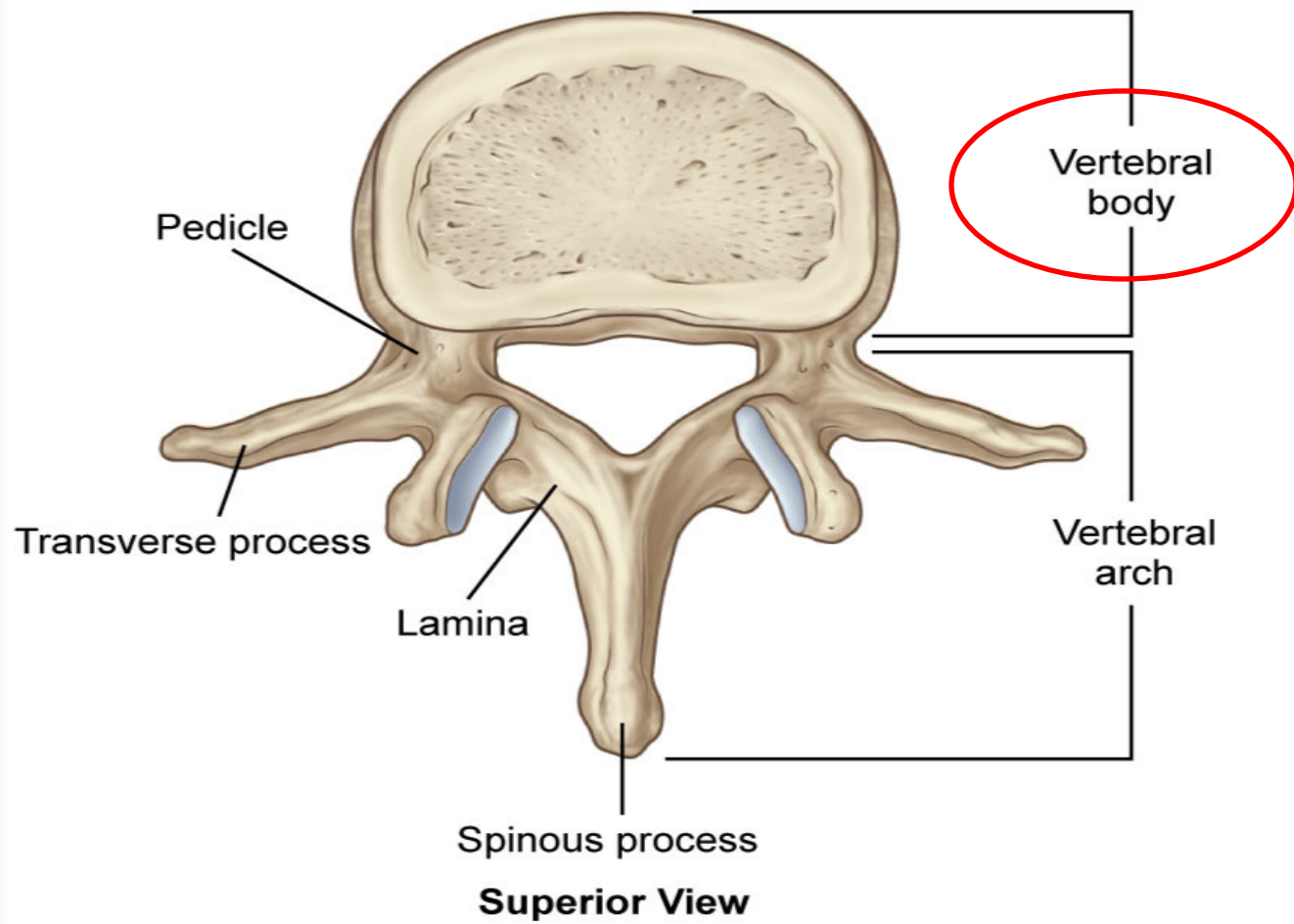


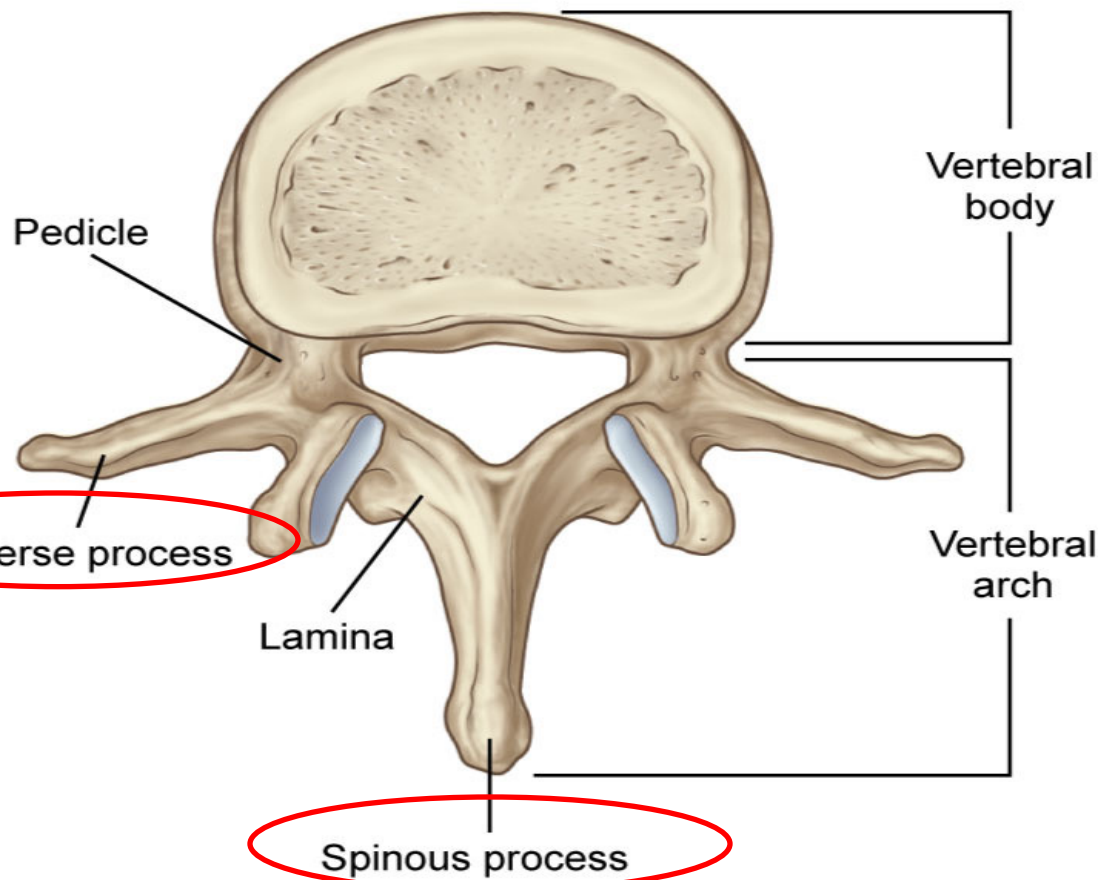


**Lateral View**

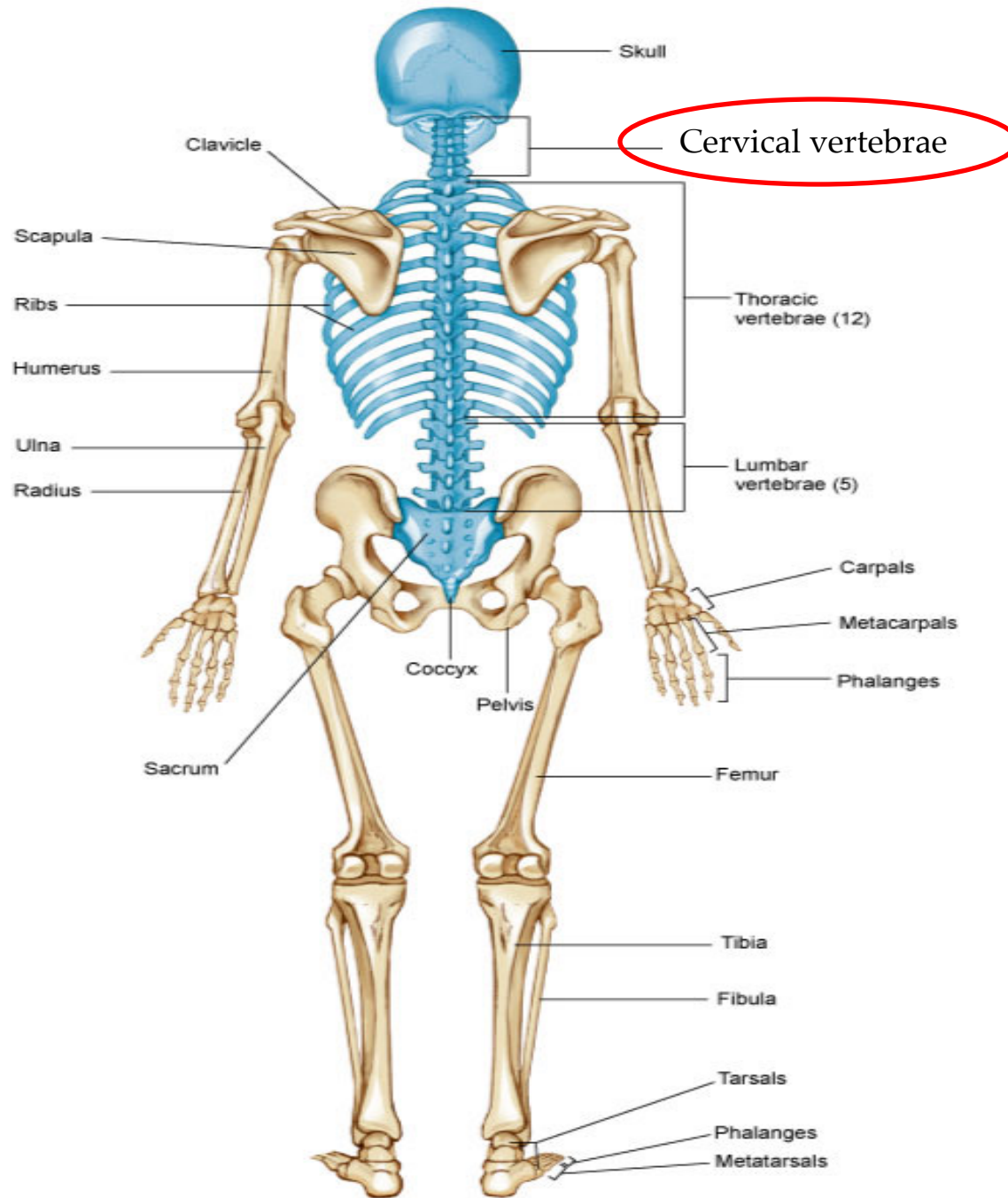
- 
- Put the face cradle in
  - Flip them over into the prone position
  - Adjust the bolster







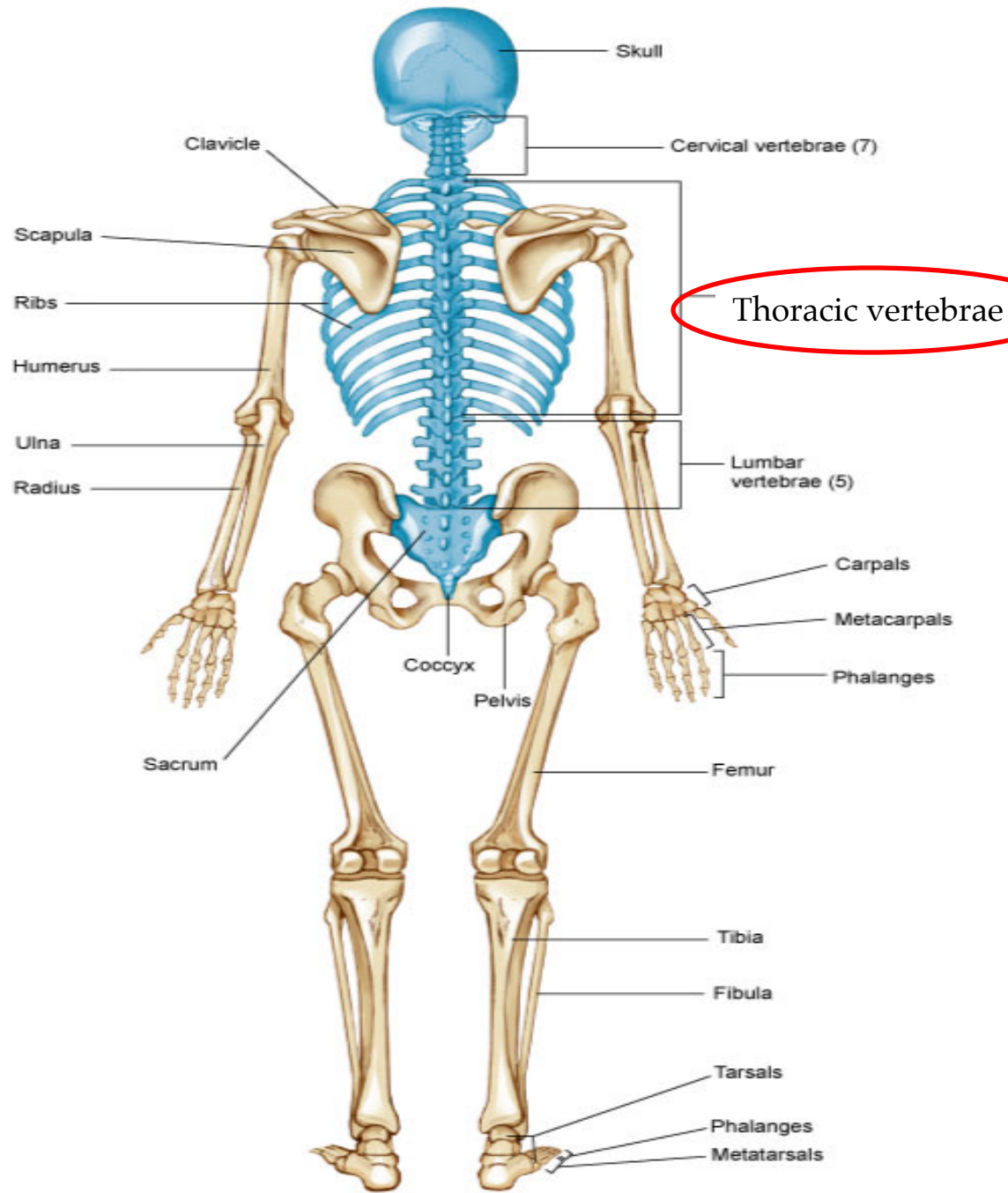
**Superior View**



B

POSTERIOR VIEW

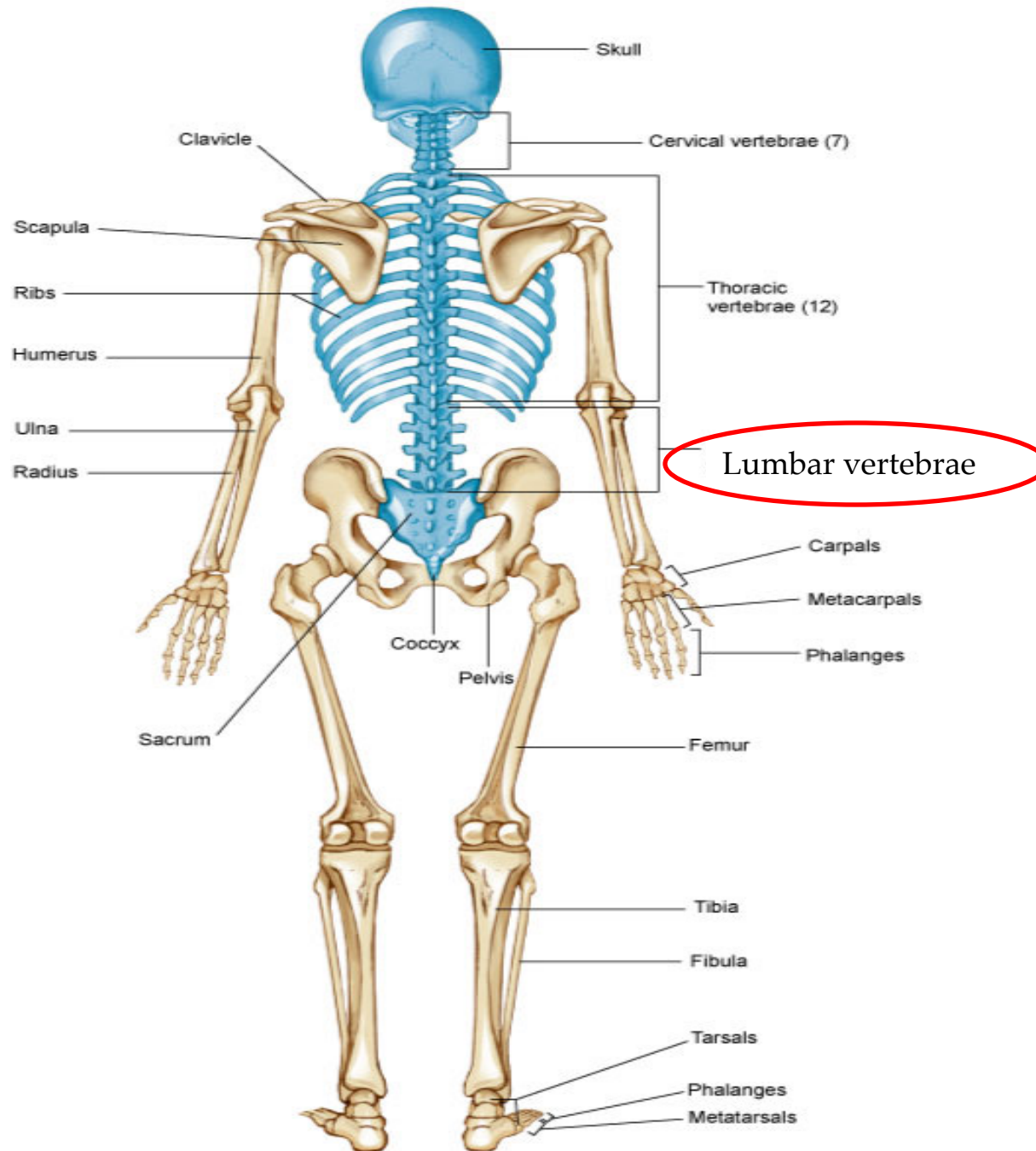




B

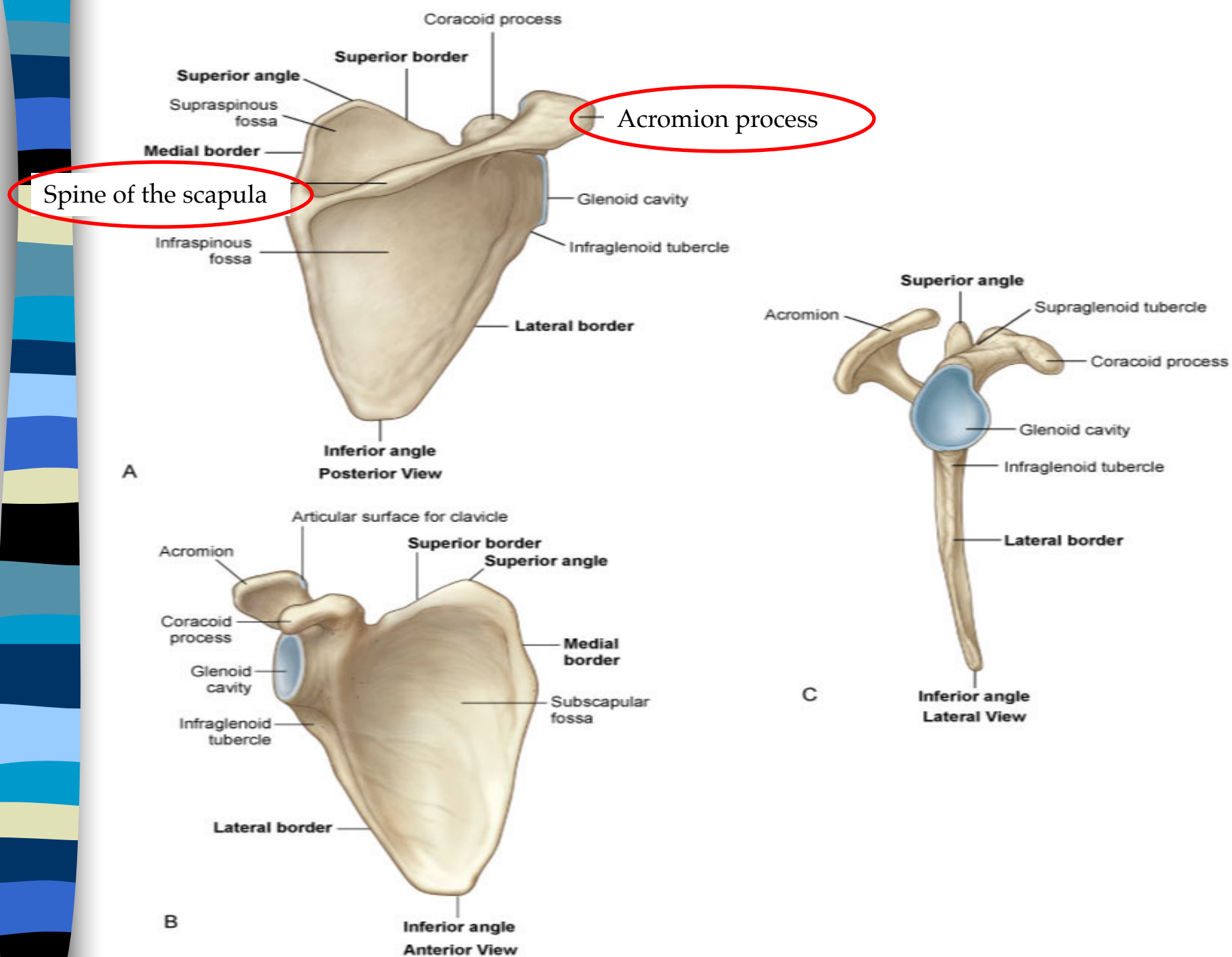
POSTERIOR VIEW



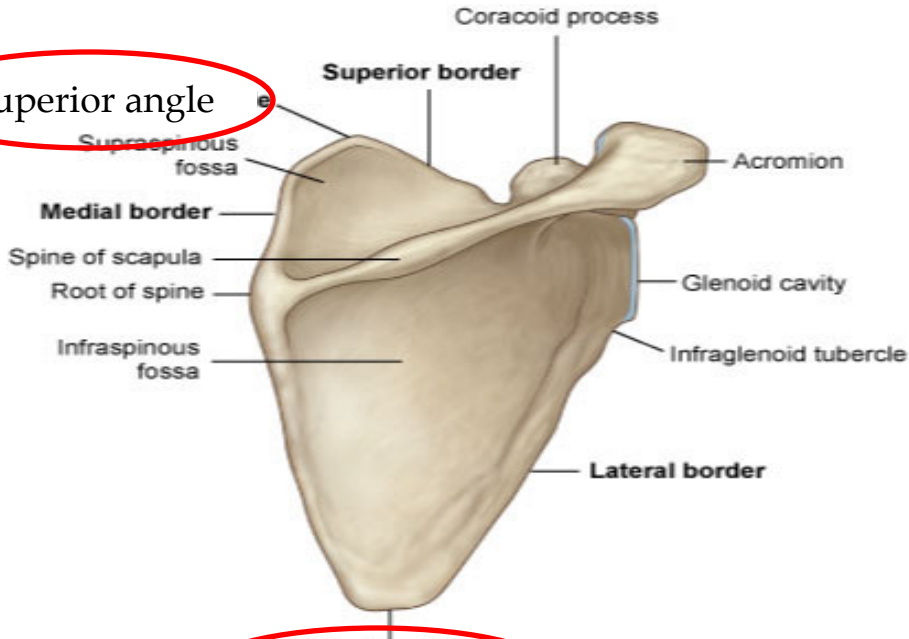


B

POSTERIOR VIEW

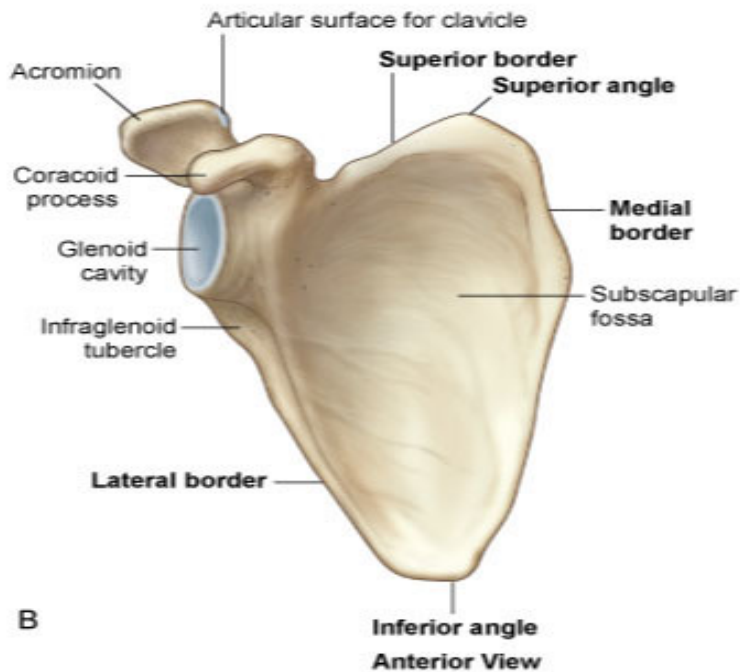


Superior angle

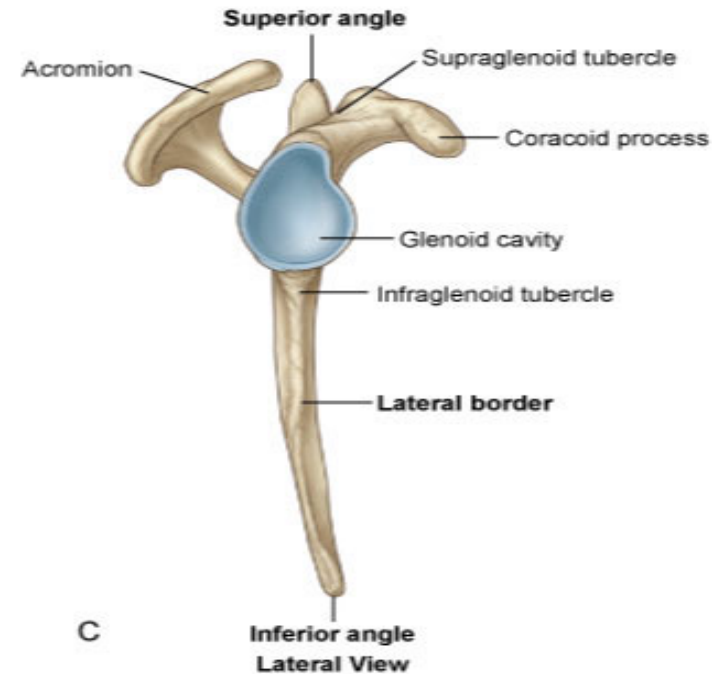


Inferior angle

A



B

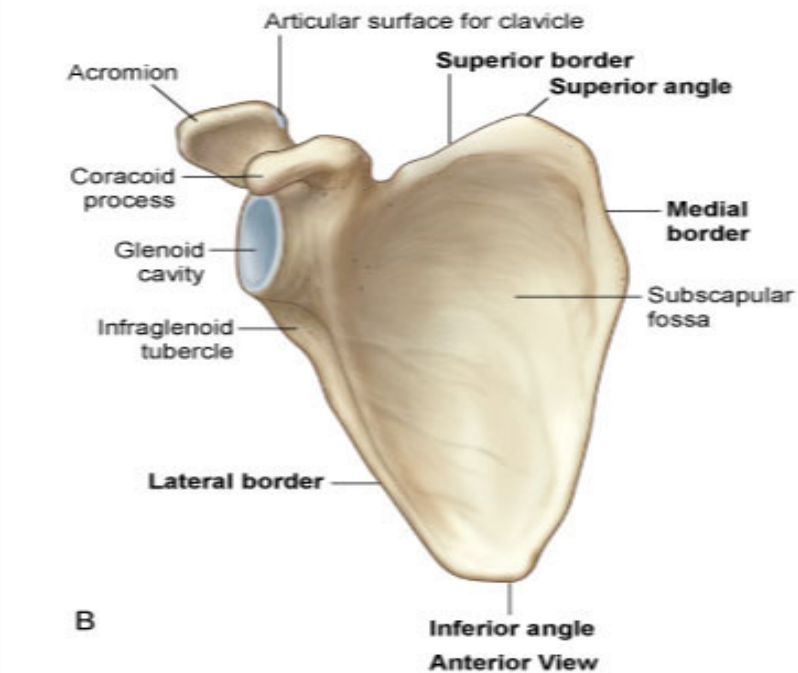


C

Medial border

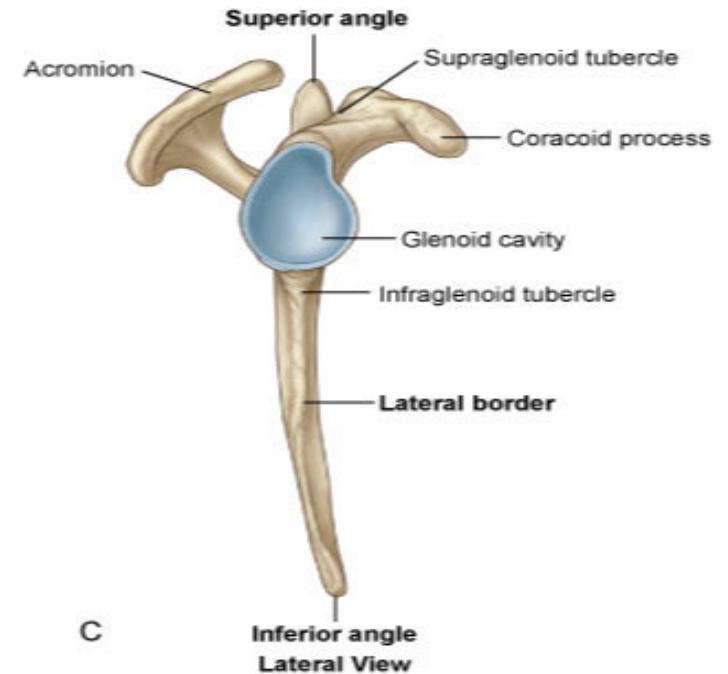
A

Inferior angle  
Posterior View

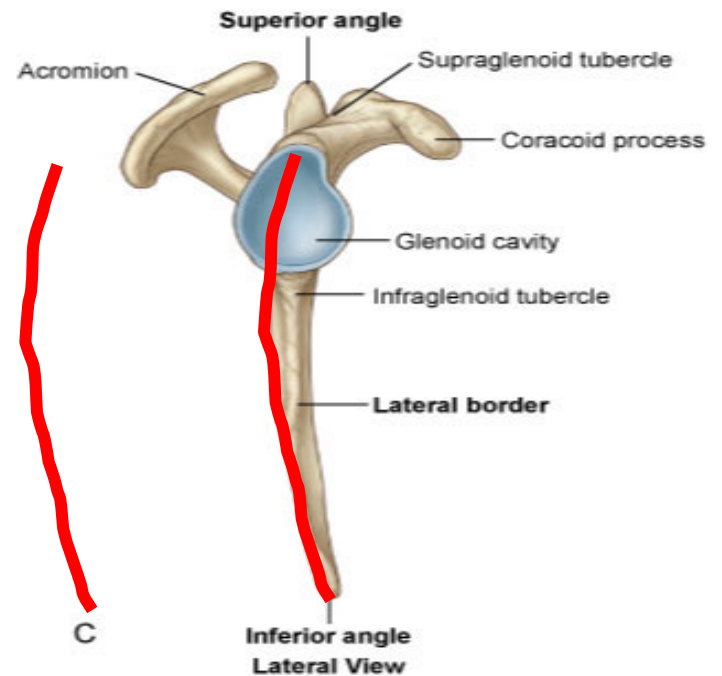
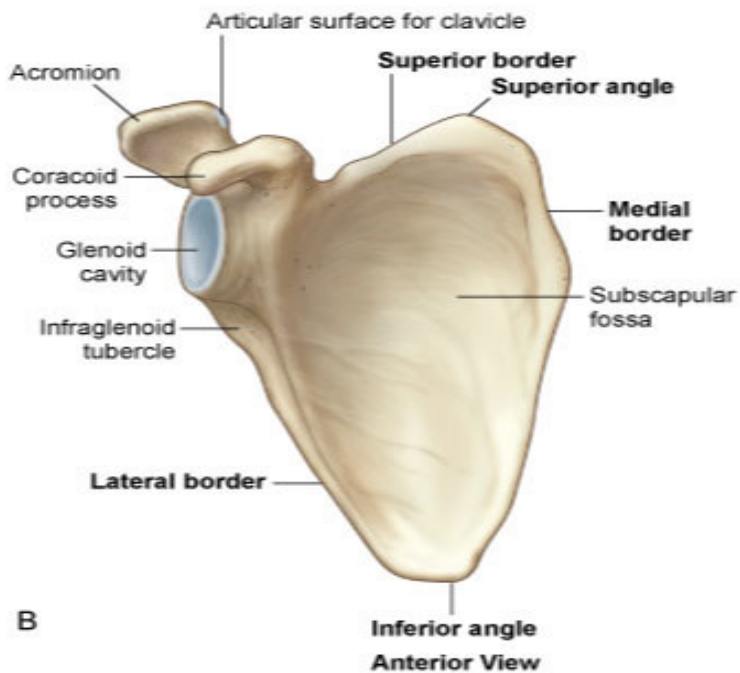
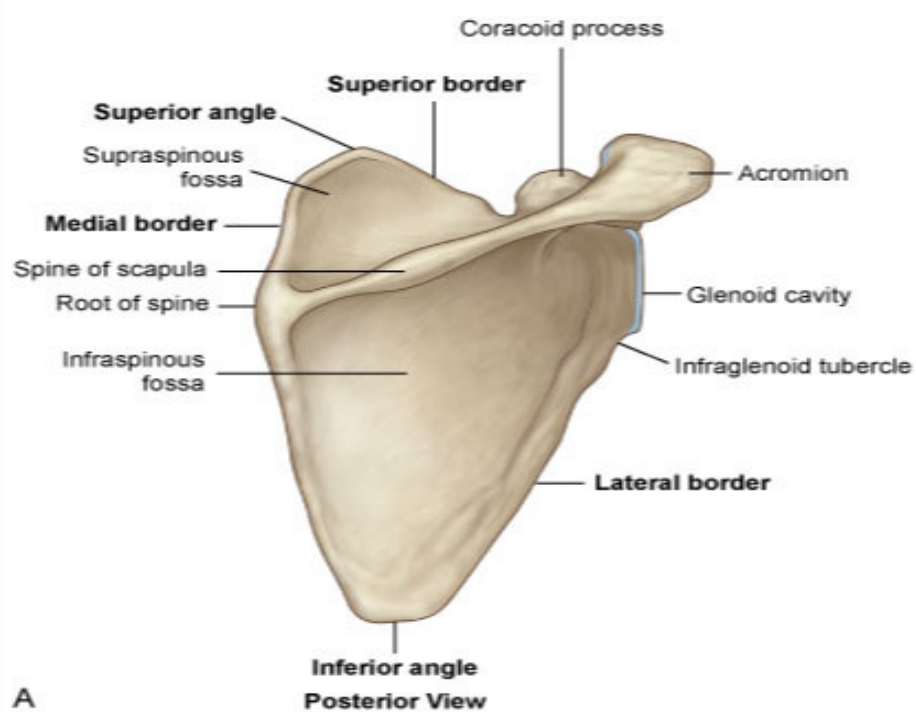


B

Inferior angle  
Anterior View



C



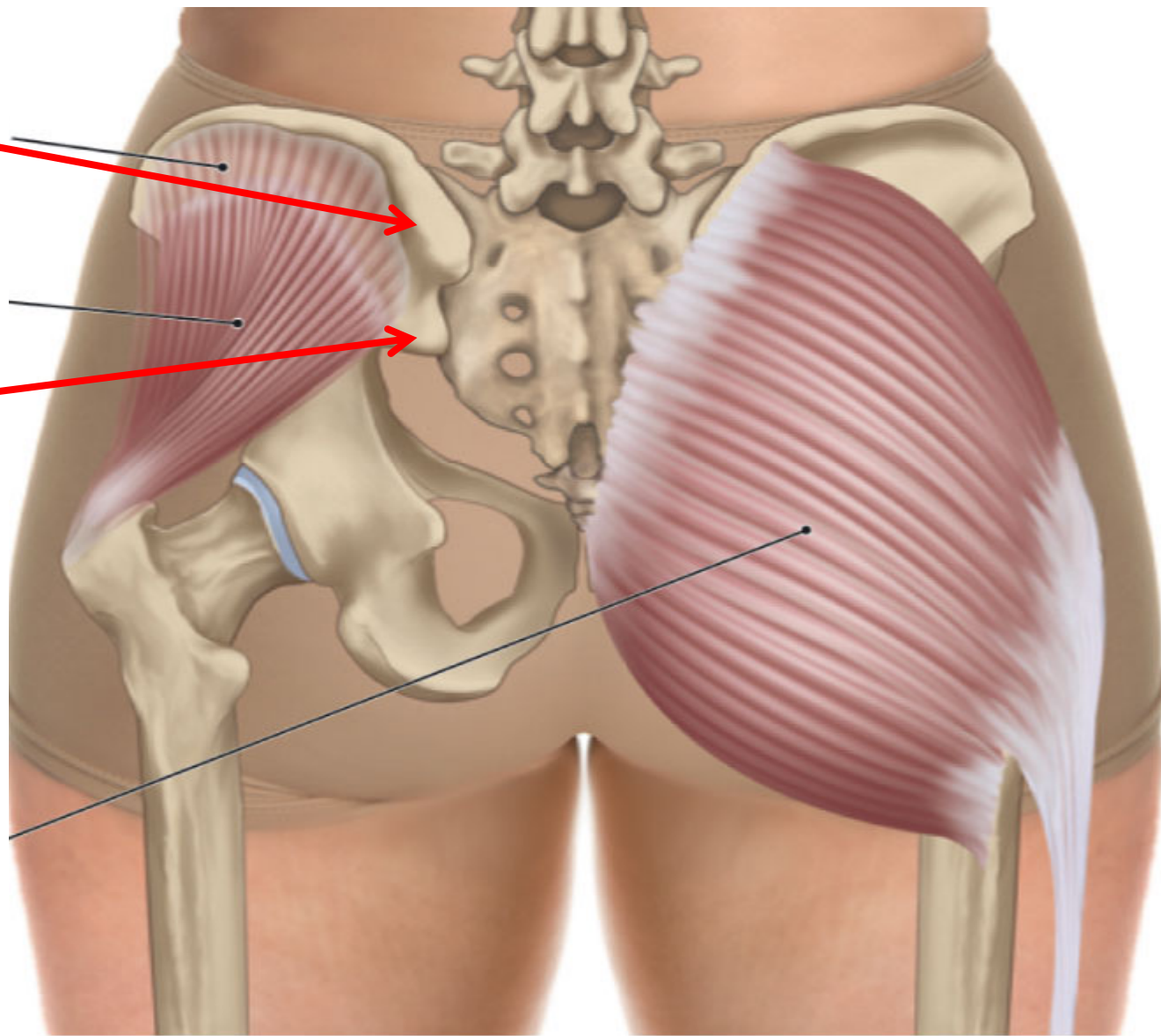


PSIS

- Posterior Superior Iliac Spine

PIIS

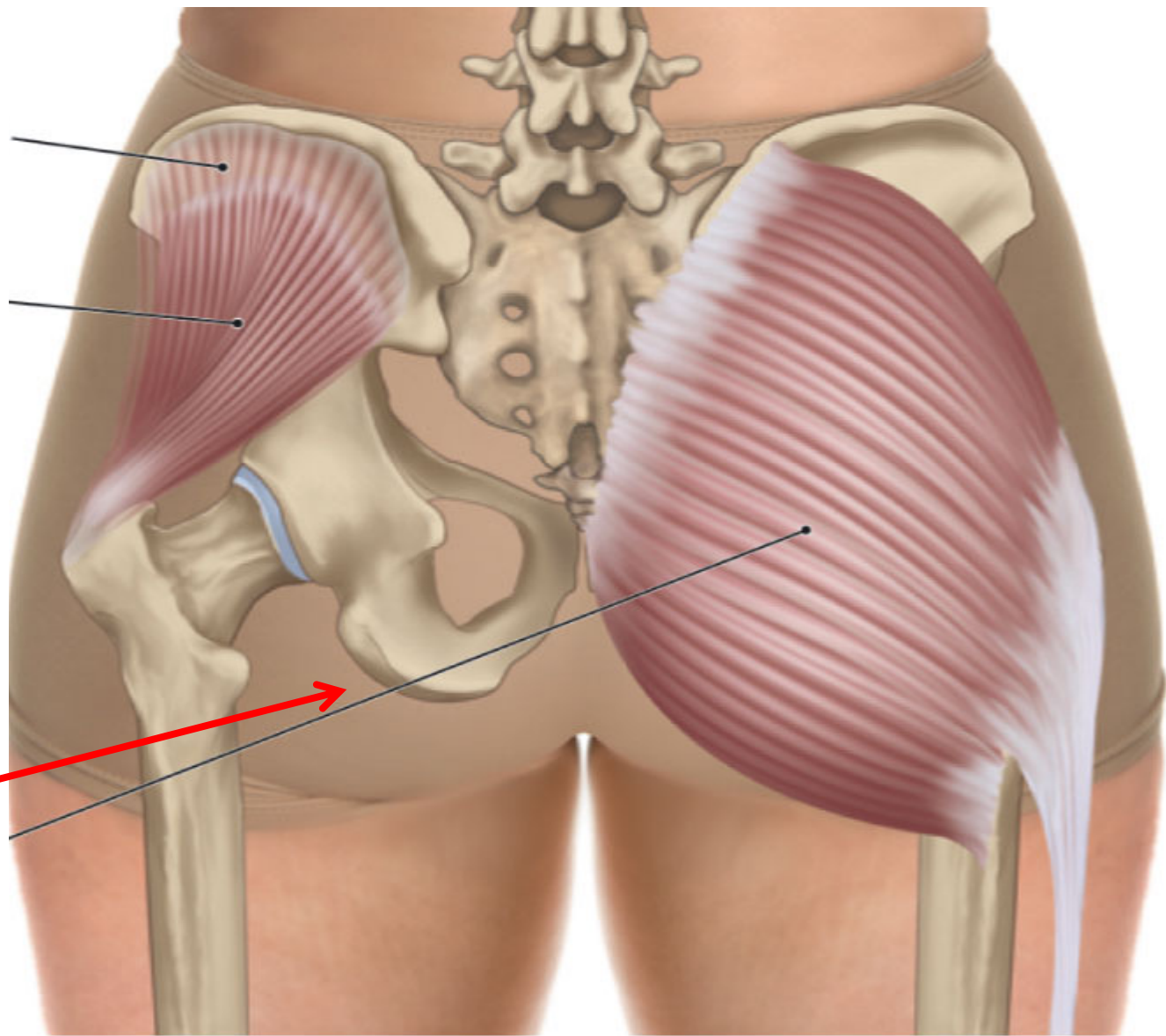
- Posterior Inferior Iliac Spine



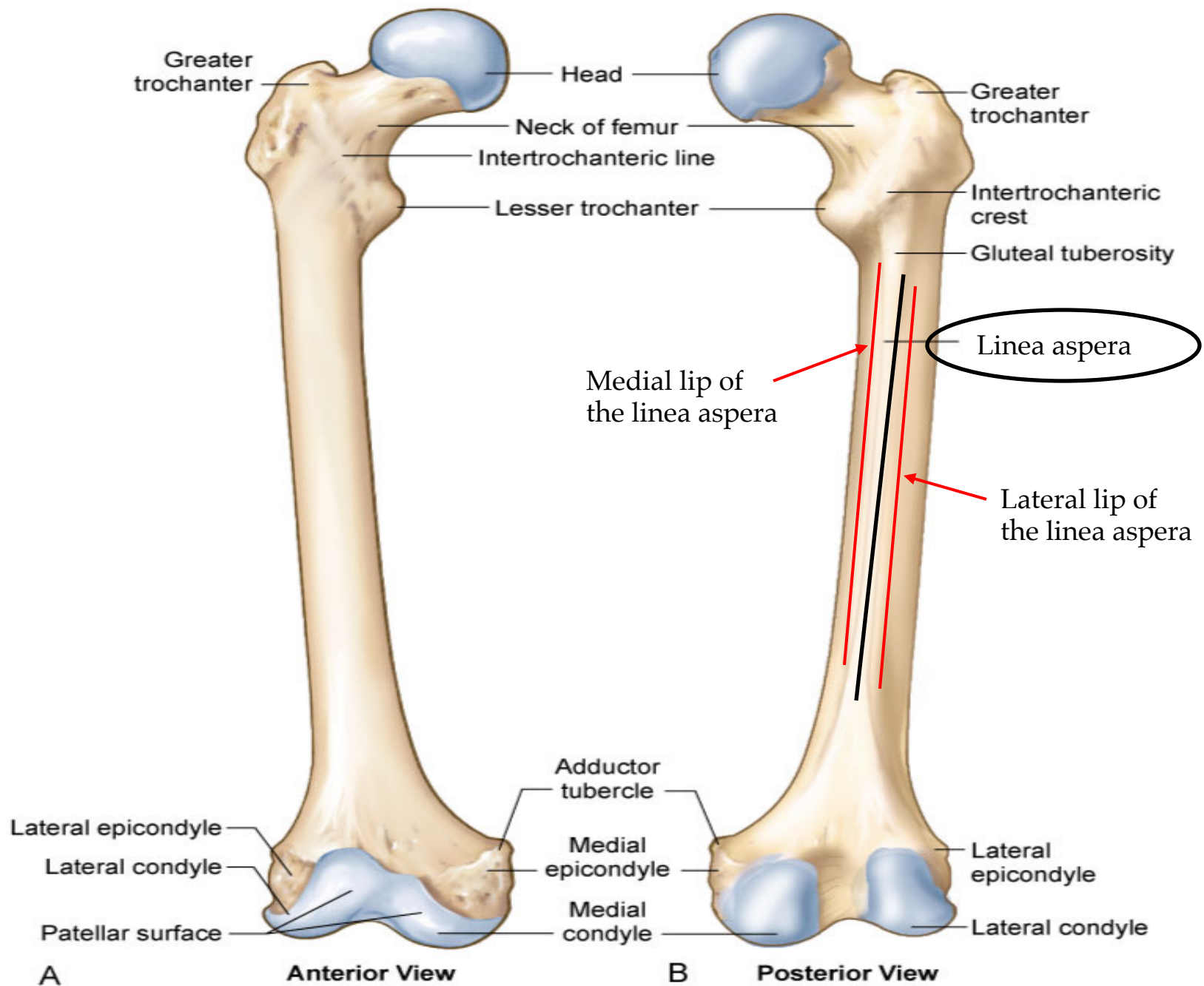
**Posterior View**

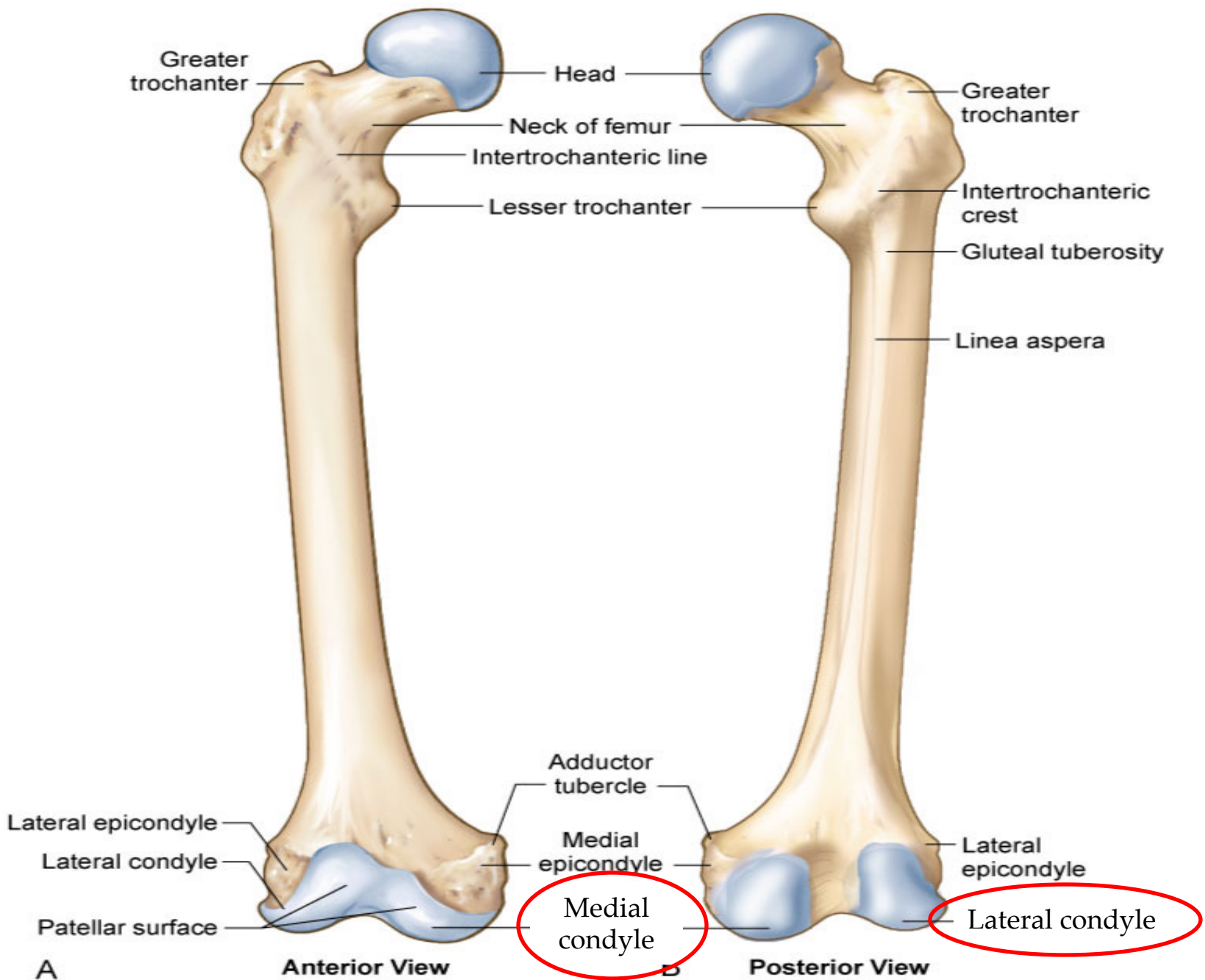


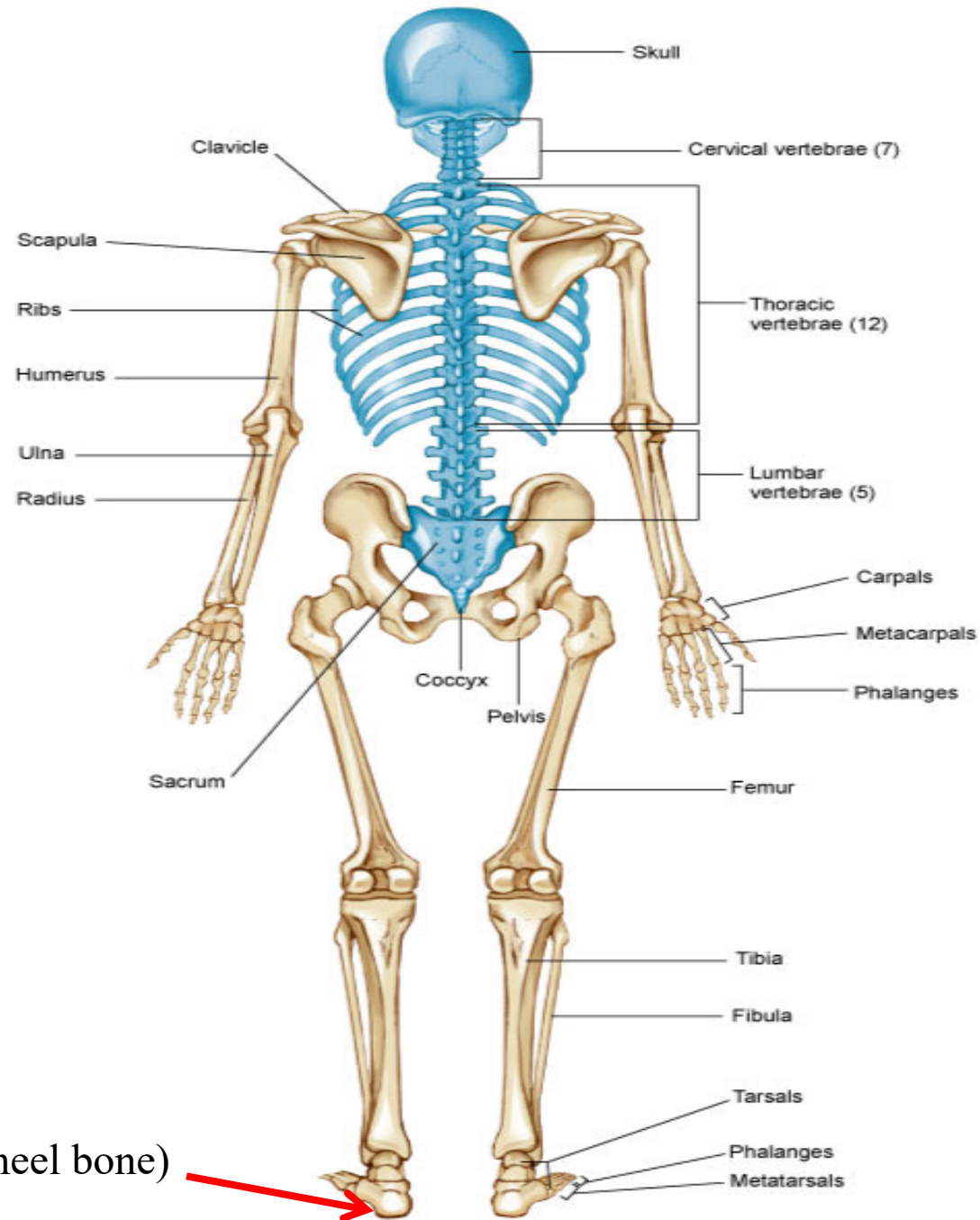
Ischial  
Tuberosity



**Posterior View**








Calcaneus (heel bone)



B

POSTERIOR VIEW

- 
- Switch and do it again!



# 15a A&P: Skeletal System - Bony Landmark Palpation