



42b Kinesiology: AOIs - Coxal and Tibiofemoral Joint Muscles



42b Kinesiology: AOIs - Coxal and Tibiofemoral Joint Muscles

10 minutes	Break Announce the return time and write it on the board.
5 minutes	Attendance Also project the “Class Reminders” slide.
20 minutes	Cadaver Video: Acland’s DVD Atlas of Human Anatomy
55 minutes	Anatomy in Clay
20 minutes	Break Announce the return time and write it on the board.
30 minutes	Active Study Skills
60 minutes	Palpation
10 minutes	<u>Break down, clean up, and circle up</u>
3h 30m	Total Class Time

42b Kinesiology – Coxal and Tibiofemoral Joint Muscles

Class Reminders

Assignments:

- 43a Swedish: Outside Massages (Packet A: 57-62)
- 45b Cover Letter and Resume assignment – due before class starts via email or hard copy to your instructor. If LMS is active, assignment must be turned in via LMS.

Quizzes and Exams:

- 43a Kinesiology Quiz
(adductor magnus, gracilis, iliopsoas, sartorius, TFL, piriformis, quadratus femoris)
- 44a Quiz (33b, 35a, 36a, 37a/b, 38a, 39a, 40a, 41a/b, 42b, and 43a)
- 46a Exam

Practical Exam:

- 44b Integration Massage: Practical Exam
(60-minute Swedish, Passive Stretches, and BMTs)
- **Bring your grading sheet for evaluation A: 83**

Preparation for upcoming classes:

- 43a Kinesiology: AOIs - Coxal and Tibiofemoral Joint Muscles
- 44a Quiz
- 47b, 48b, 49b Pregnancy Message: **These classes cannot be made up in the make-up room.** To schedule a sit-in, please contact the Student Administrator.



Cadaver Video

- [Deep Lateral Rotators](#)
- [Adductors](#)
- [IT Tract, TFL, and Iliopsoas](#)
- [Sartorius](#)



Anatomy in Clay

- Coxal and tibiofemoral joint muscles that we've studied so far:
 - Gluteus maximus
 - Gluteus medius
 - Gluteus minimus
 - Biceps femoris
 - Semitendinosus
 - Semimembranosus
 - Rectus femoris
 - Vastus lateralis
 - Vastus medialis
 - Vastus intermedius
 - Gastrocnemius
 - Adductor magnus *
 - Gracilis *
 - Psoas major *
 - Iliacus *
 - Sartorius *
 - Tensor fasciae latae *
 - Piriformis *
 - Quadratus femoris *



Palpation

Set Up by the Students

- Students form groups of 3.
- Each group sets up a table and gets 1 face cradle, 1 bolster, and 2 chairs.
- Receivers must remain clothed.
- There will be no need of sheets except for a face cradle cover.

Demo and Practice

- All of the students come to a central table to watch a brief demonstration of how to palpate one of the focus muscles:
 - List and identify the bony landmarks, especially origins and insertions.
 - List and identify the muscle bellies and tendons.
 - List and explain the actions.
 - Demo how to palpate the muscle while simultaneously offer resistance to the action, “Contract, relax. Contract, relax.”
 - The students go back to their table to practice the palpation.
 - 2 students palpate the third student collaboratively.
 - The instructor and assistant circulate to offer guidance and touch comparisons:
- This process repeats for each muscle that will be palpated.
- Once all the focus muscles have been palpated on the first student, repeat the process so that each student will palpate twice and be palpated once.

Adductor Magnus, page 320

- A** All fibers:
Adduct the hip (coxal joint)
Medially rotate the hip (coxal joint)
Assist to **flex** the hip (coxal joint)

Posterior fibers:
Extend the hip (coxal joint)

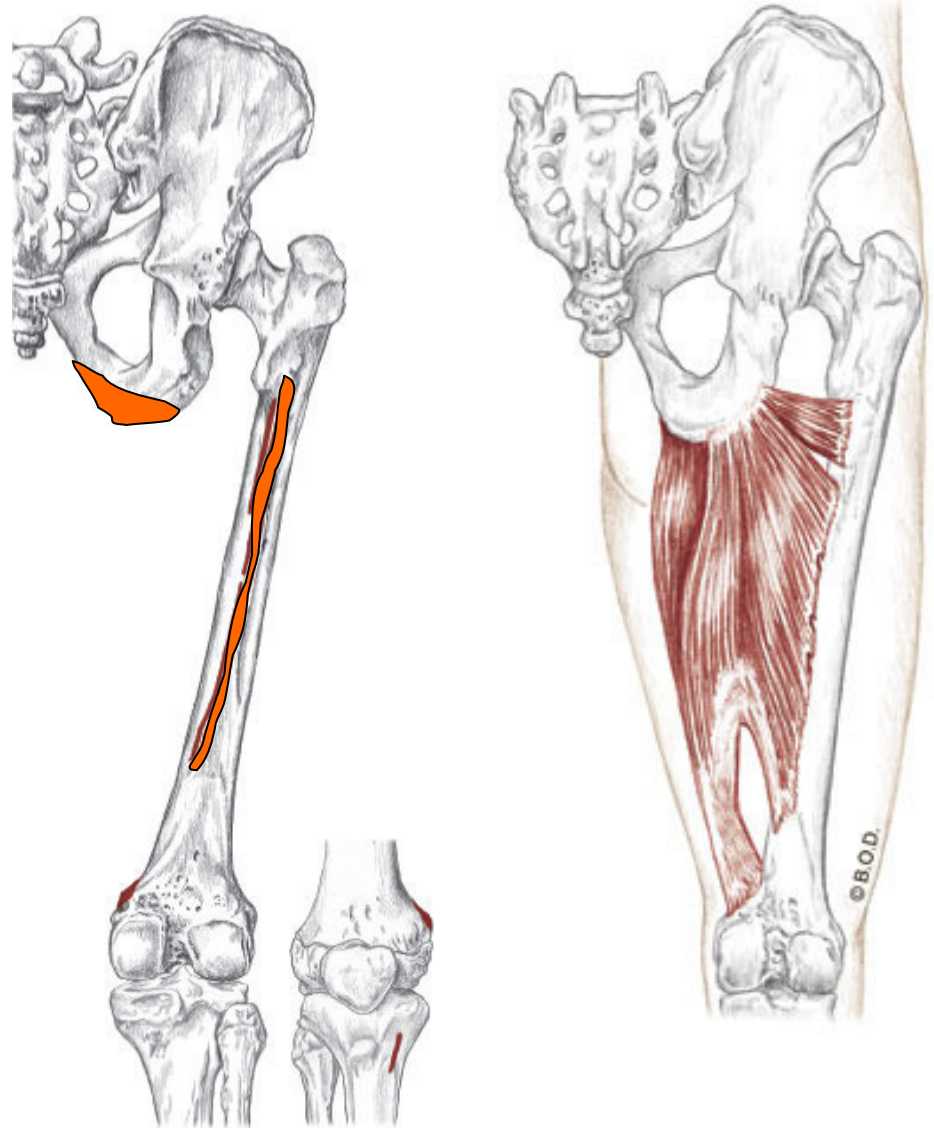
- O** Inferior ramus of the pubis

Ramus of the ischium

Ischial tuberosity

- I** Medial lip of linea aspera

Adductor tubercle



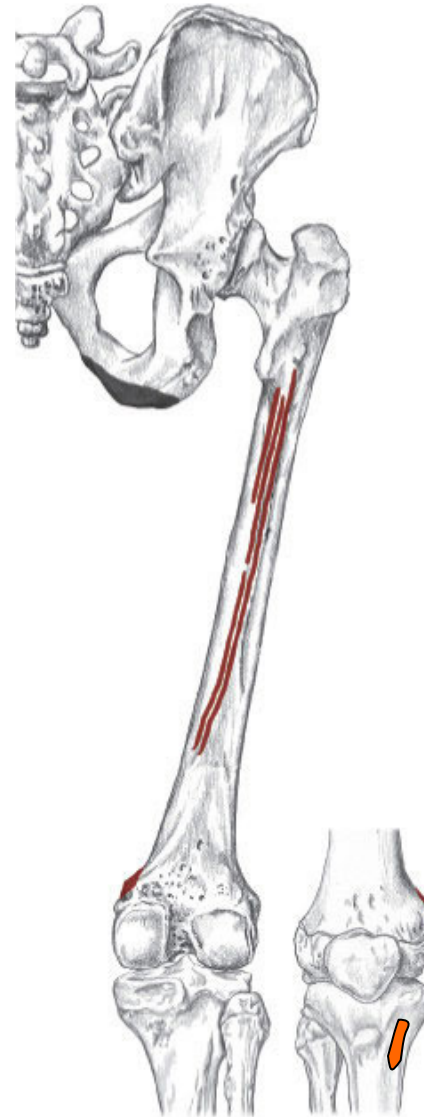Posterior View

Gracilis, page 321

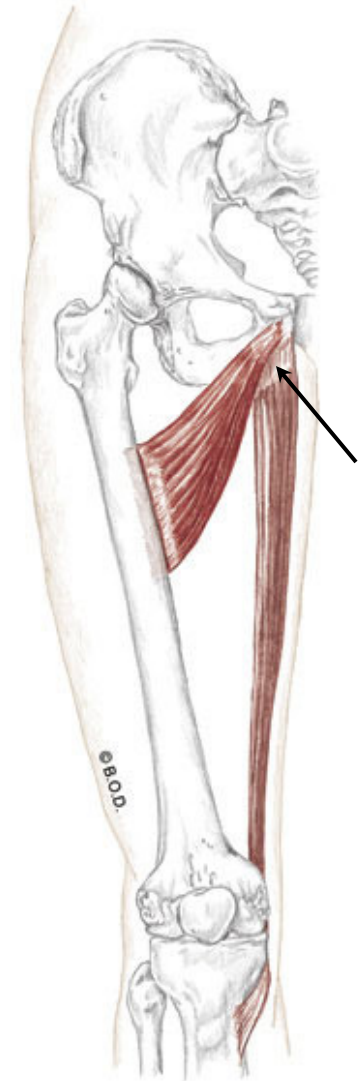
- A** All fibers:
- Adduct** the hip (coxal joint)
 - Medially rotate** the hip (coxal joint)
 - Flex** the knee (tibiofemoral joint)
 - Medially rotate** the knee (tibiofemoral joint)

O Inferior ramus of the pubis

I Proximal, medial shaft of tibia
at pes anserinus tendon



Posterior View



Anterior View

Psoas Major, page 332

A

With the origin fixed:

Flex the hip (coxal joint)

May **laterally rotate** the hip (coxal joint)

With the insertion fixed:

Flex the trunk toward the thigh

Tilt the pelvis anteriorly

Unilaterally:

Assist to **laterally flex** the lumbar spine

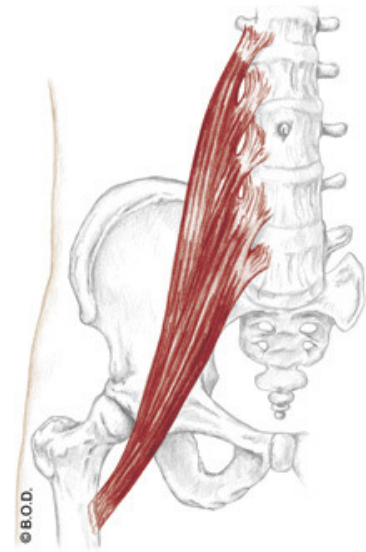
O

Bodies of lumbar vertebrae

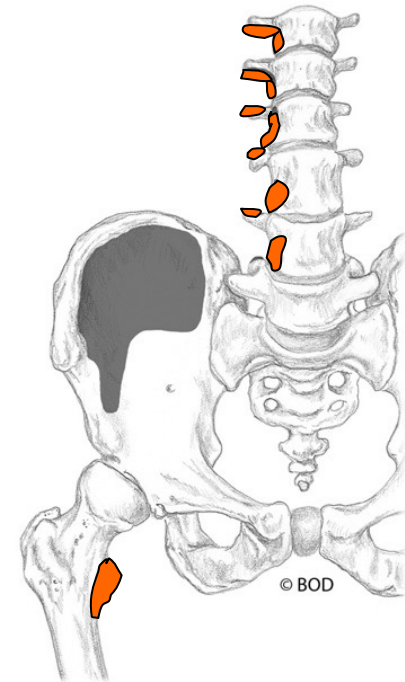
Transverse processes of lumbar vertebrae

I

Lesser trochanter



Anterior View



Iliacus, page 332

A *With the origin fixed:*
Flex the hip (coxal joint)

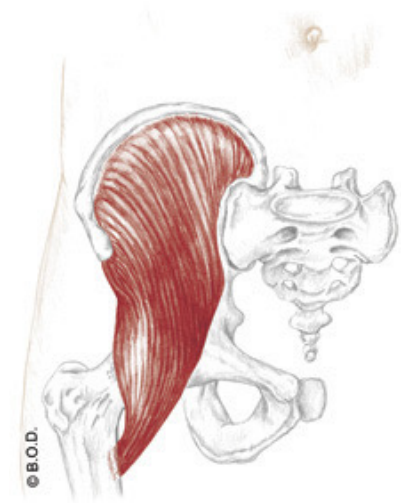
May **laterally rotate** the hip (coxal joint)

With the insertion fixed:
Flex the trunk toward the thigh

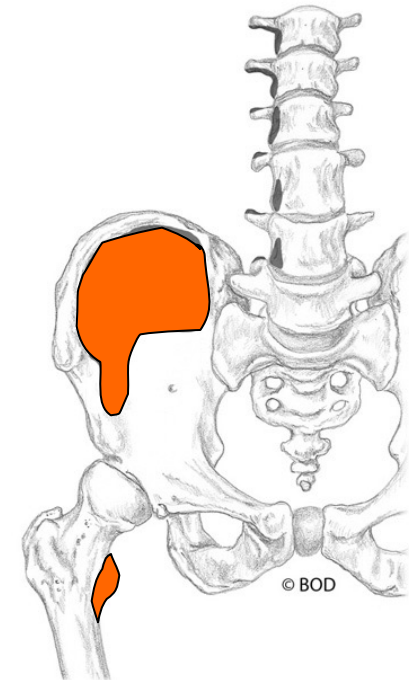
Tilt the pelvis anteriorly

O Iliac fossa

I Lesser trochanter



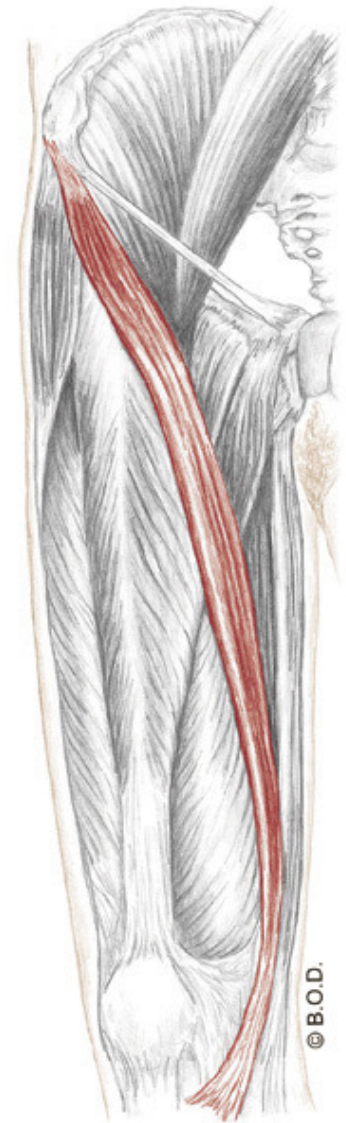
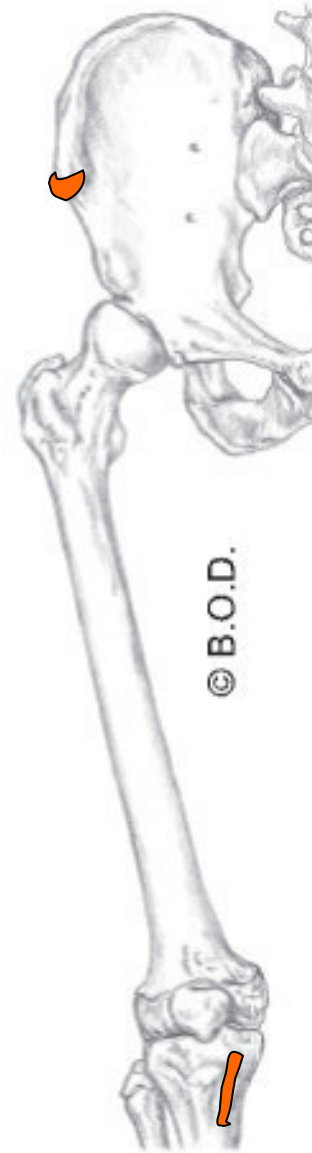
Anterior View



- A** Flex the hip (coxal joint)
- Laterally rotate the hip (coxal joint)
- Abduct the hip (coxal joint)
- Flex the knee (tibiofemoral joint)
- Medially rotate the knee (tibiofemoral joint)

O Anterior superior iliac spine (ASIS)

I Proximal, medial shaft of the tibia
at pes anserinus tendon



Anteromedial View

Tensor Fasciae Latae, page 324

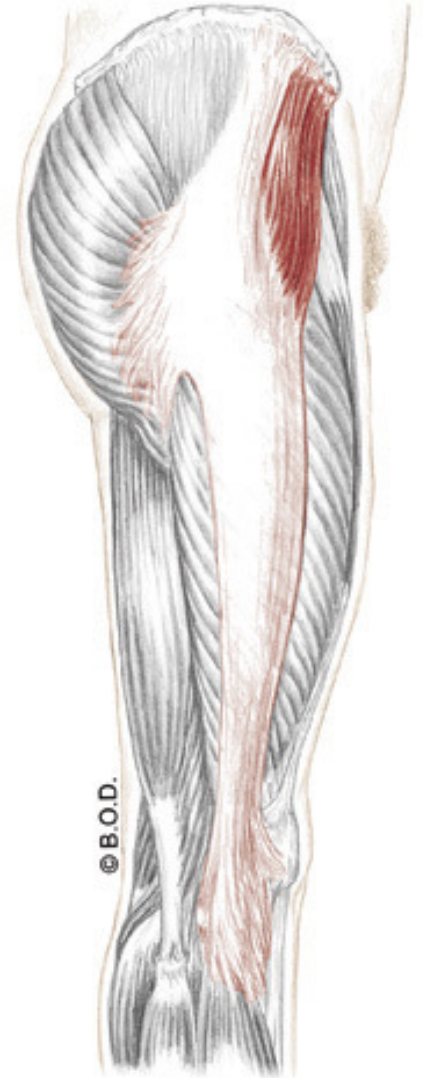
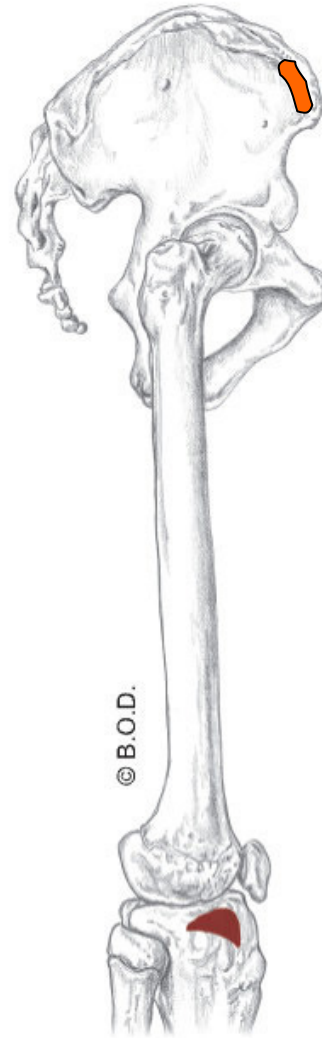
A Flex the hip (coxal joint)

Medially rotate the hip (coxal joint)

Abduct the hip (coxal joint)

O Iliac crest, posterior to the ASIS

I Iliotibial tract



Lateral View

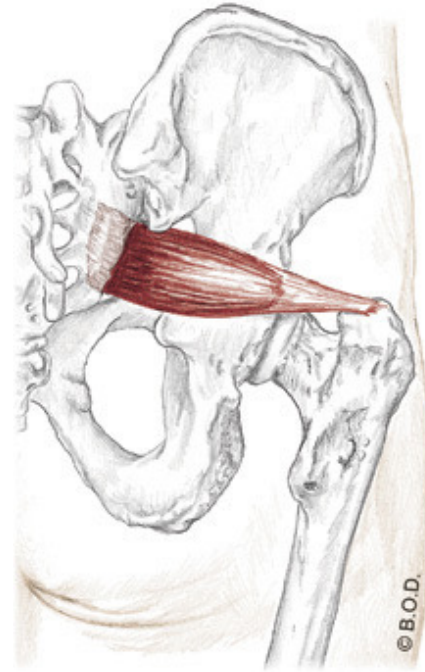
Piriformis, page 328

A Laterally rotate the hip (coxal joint)

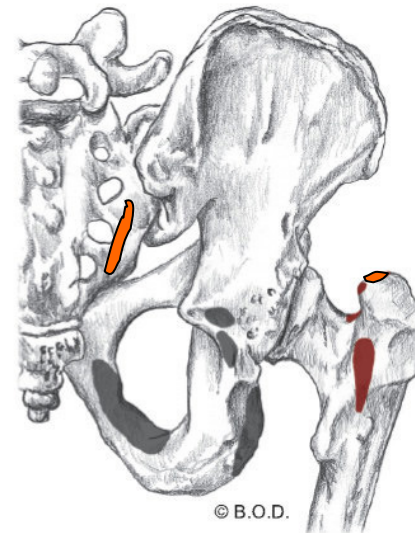
Abduct the hip (coxal joint) when it is flexed

O Anterior surface of sacrum

I Superior aspect of greater trochanter



Posterior View

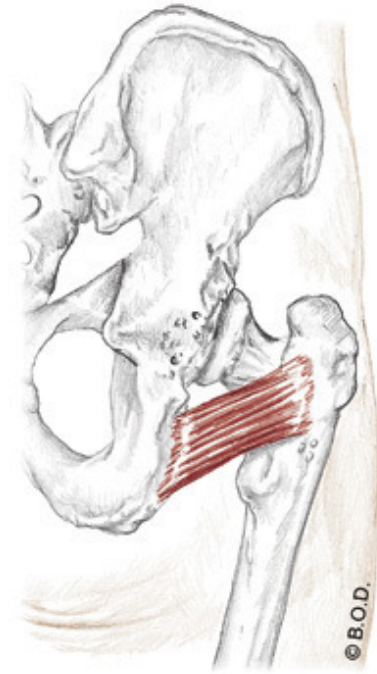


Quadratus Femoris, page 328

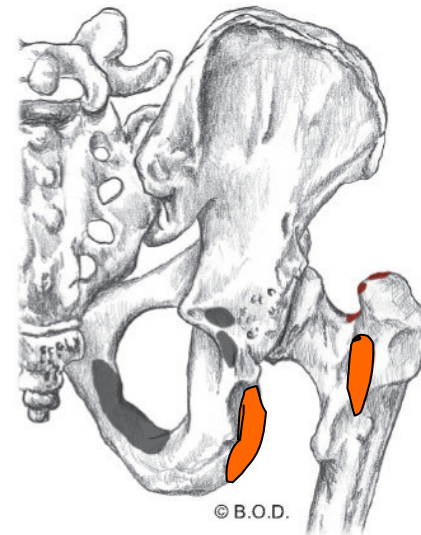
A Laterally rotate the hip (coxal joint)

Lateral border of ischial tuberosity

I Intertrochanteric crest, between the greater and lesser trochanters



Posterior View



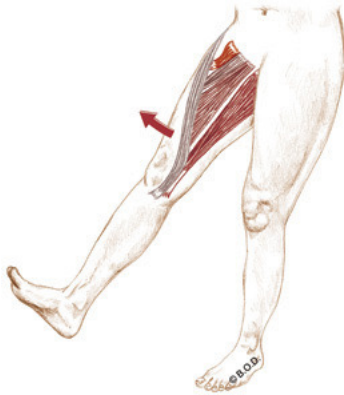Thinking ahead

Which muscles are synergists in doing the following actions on the coxal joint? ...

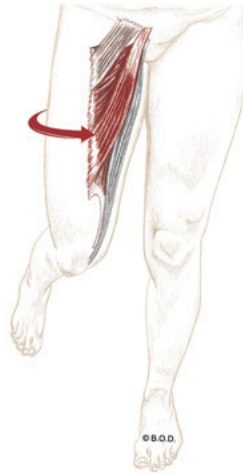
Coxal Joint

Trail Guide, page 302-304

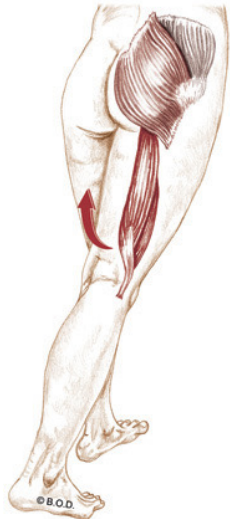
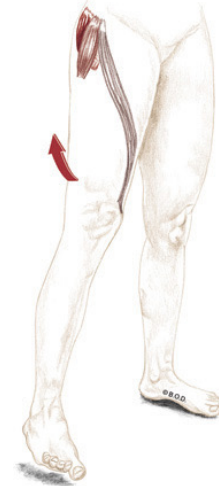Flexion



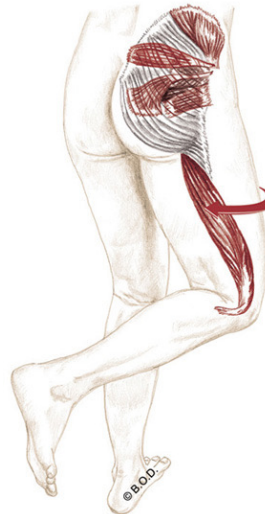
Medial Rotation



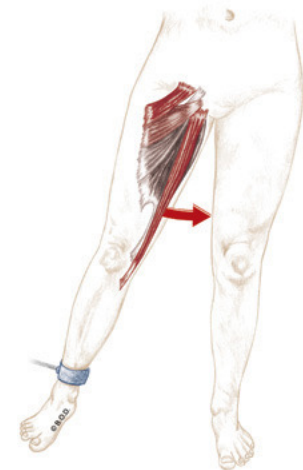
Abduction



Extension



Lateral rotation

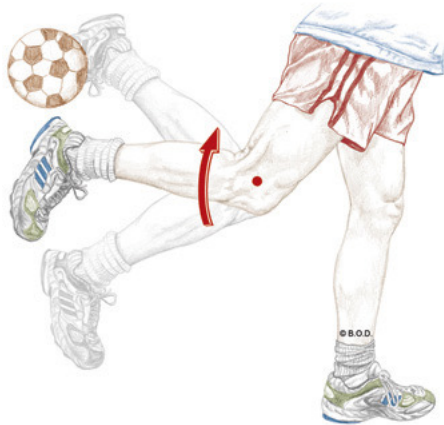

Adduction

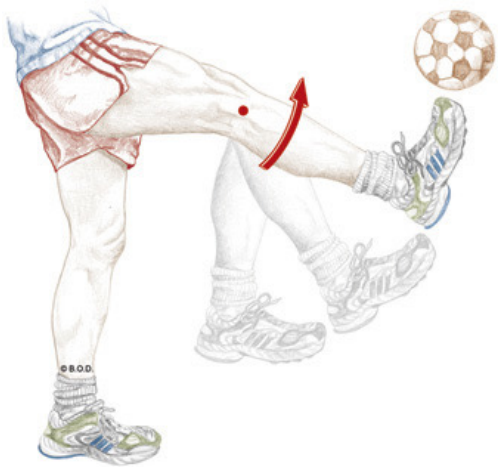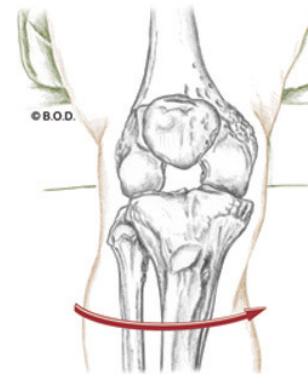
Which muscles are synergists in doing the following actions on the tibiofemoral joint? ...

Tibiofemoral Joint

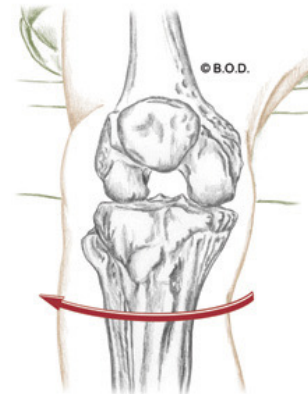
Flexion



Medial Rotation of Flexed Knee



Extension



Lateral Rotation of Flexed Knee

42b Kinesiology: AOIs - Coxal and Tibiofemoral Joint Muscles