




29b Kinesiology: AOIs - Glenohumeral and Scapulothoracic Joint Muscles



29b Kinesiology: AOIs - Glenohumeral and Scapulothoracic Joint Muscles

10 minutes	Break Announce the return time and write it on the board.
5 minutes	Attendance Also project the “Class Reminders” slide.
50 minutes	Cadaver Video: Acland’s DVD Atlas of Human Anatomy
55 minutes	Anatomy in Clay
20 minutes	Break Announce the return time and write it on the board.
60 minutes	Palpation
5 minutes	<u>Break down, clean up, and circle up</u>
3h 30m	Total Class Time



29b Kinesiology: AOIs - Glenohumeral and Scapulothoracic Joint Muscles

Class Reminders

Quizzes:

- 30a Kinesiology Quiz
- 31a Quiz (study all material from classes 18a, 20a/b, 21b, 23a, 24a/b, 25a, 26a, 27a, 28a, 29a/b, 30a/b)

Assignments:

- 30a Review Questions
 - Packet A: 149-163

Exams:

- 34a Exam
(0b, 2a, 2b, 3a, 3b, 4a, 5a, 6a, 7a, 8b, 9a, 9b, 11a, 12a, 13a, 13b, 15a, 16a, 17a, 17b, 18a, 20a, 20b, 21b, 22a, 23a, 24a, 24b, 25a, 26a, 27a, 28a, 29a, 29b, 30a, 30b, and 31b)

Preparation for upcoming classes:

- 30a Kinesiology: Synergists - Glenohumeral and Scapulothoracic Joints
 - Trail Guide: Pages 63-66
 - RQ Packet A: 155-156
- 30b Passive Stretches: Technique Demo and Practice - Upper Body
 - Packet F: 65-70
 - RQ Packet A-157
- 33b Chair Massage: This class cannot be made up in the make-up room. To schedule a sit-in, please contact the Student Administrator.



Classmarker

Grading your Quiz/Exam

- Classmarker will automatically grade your assignment and email you a copy of your completed test.
- Retakes. If you did not pass a test you may reserve space in the make-up room. If you are not making up hours, your time there will be at no cost. Retakes may be done at anytime before a student graduates. You may retake it for a grade up to a 70. These are done on paper copies.
- Please refer to your assignment grid on pages A: 29-32.



Cadaver Video

- [Rotator Cuff](#)
- [Serratus Anterior](#)
- [Pectoralis Minor](#)



Anatomy in Clay

- Glenohumeral muscles that we've studied so far:

- Deltoid
- Latissimus dorsi
- Teres major
- Triceps brachii
- Pectoralis major
- Biceps brachii
- Coracobrachialis
- Supraspinatus *
- Infraspinatus *
- Teres minor *
- Subscapularis *

- Scapulothoracic muscles that we've studied so far:

- Trapezius
- Rhomboids major and minor
- Levator scapula
- Pectoralis minor *
- Serratus anterior *



Palpation

Set Up by the Students

- Students form groups of 3.
- Each group sets up a table and gets 1 face cradle, 1 bolster, and 2 chairs.
- Receivers must remain clothed.
- There will be no need of sheets except for a face cradle cover.

Demo and Practice

- All of the students come to a central table to watch a brief demonstration of how to palpate one of the focus muscles:
 - List and identify the bony landmarks, especially origins and insertions.
 - List and identify the muscle bellies and tendons.
 - List and explain the actions.
 - Demo how to palpate the muscle while simultaneously offer resistance to the action, “Contract, relax. Contract, relax.”
 - The students go back to their table to practice the palpation.
 - 2 students palpate the third student collaboratively.
 - The instructor and assistant circulate to offer guidance and touch comparisons:
- This process repeats for each muscle that will be palpated.
- Once all the focus muscles have been palpated on the first student, repeat the process so that each student will palpate twice and be palpated once.

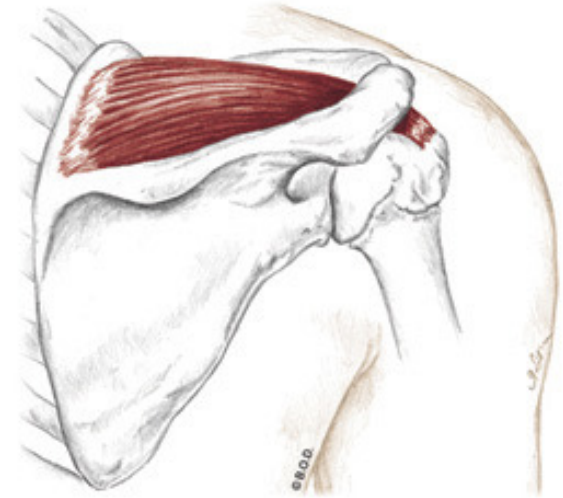
Supraspinatus, page 75

A **Abduct** the shoulder joint (glenohumeral joint)

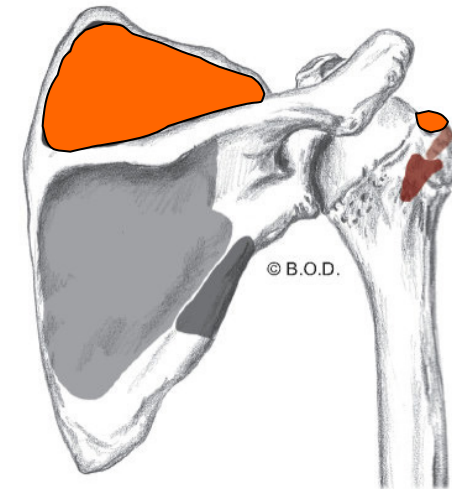
Stabilize the head of the humerus in glenoid cavity

O Supraspinous fossa of the scapula

I Greater tubercle of the humerus



Posterior View



Infraspinatus, page 75

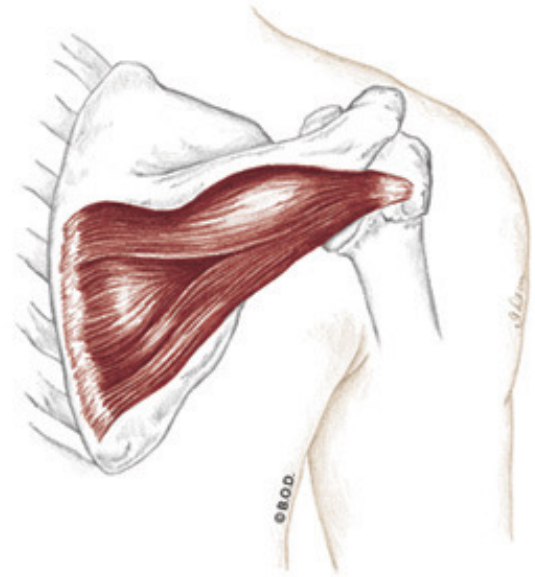
A Laterally rotate the shoulder joint (glenohumeral joint)

Adduct the shoulder joint (glenohumeral joint)

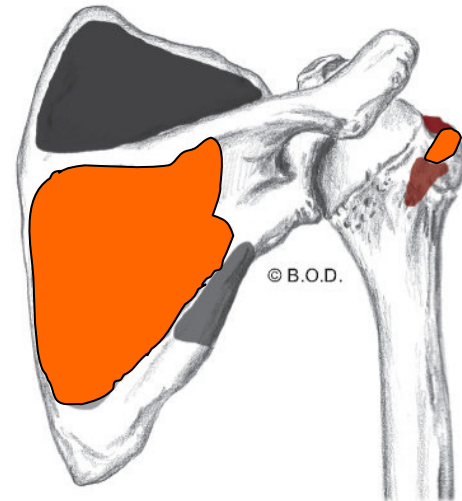
Stabilize the head of the humerus in glenoid cavity

O Infraspinous fossa of the scapula

I Greater tubercle of the humerus



Posterior View



Teres Minor, page 75

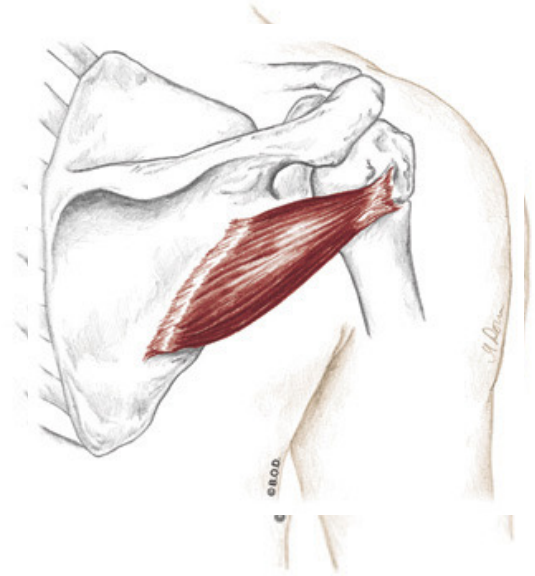
A Laterally rotate the shoulder joint (glenohumeral joint)

Adduct the shoulder joint (glenohumeral joint)

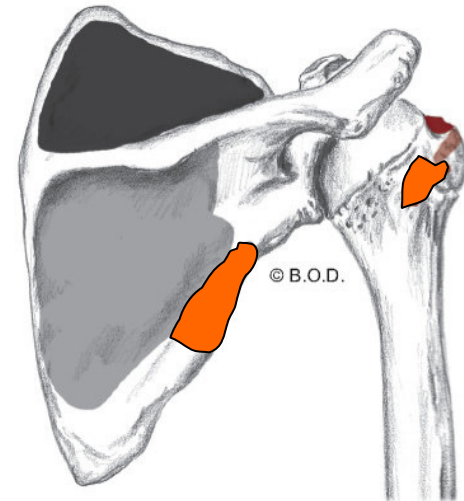
Stabilize the head of the humerus in glenoid cavity

O Upper two-thirds of lateral border of the scapula

I Greater tubercle of the humerus



Posterior View



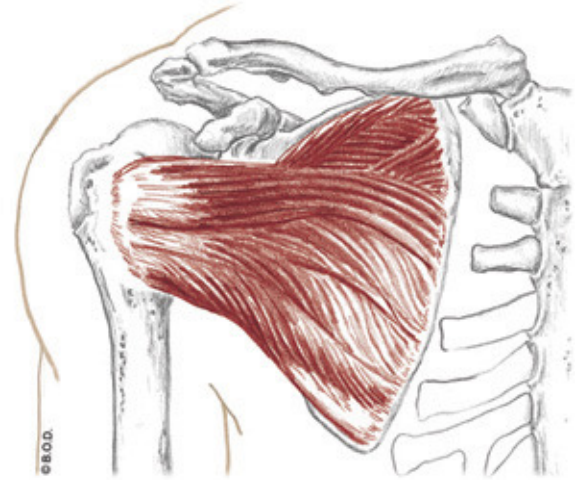
Subscapularis, page 75

A **Medially rotate** the shoulder joint (glenohumeral joint)

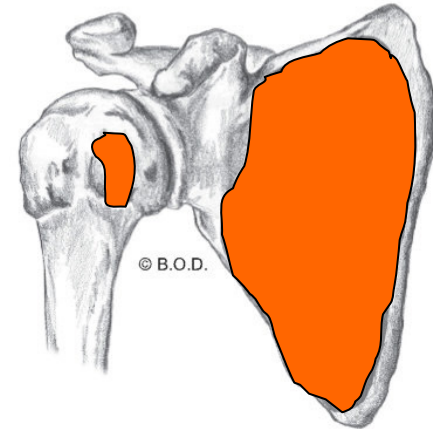
Stabilize the head of the humerus in glenoid cavity

O Subscapular fossa of the scapula

I Lesser tubercle of the humerus



Anterior View



Pectoralis Minor, page 92

A Depress the scapula (scapulothoracic joint)

Abduct the scapula (S/T joint)

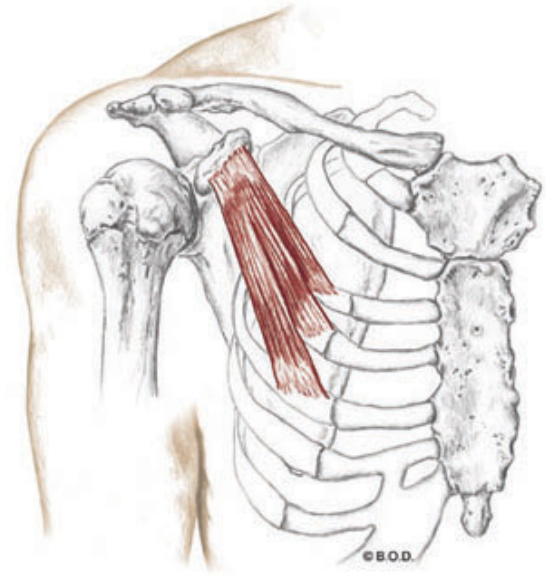
Downwardly rotate the scapula (S/T joint)

With the scapula fixed:

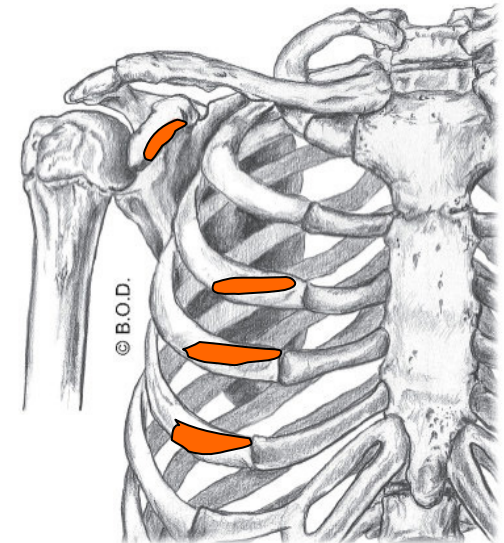
Assist to **elevate** the thorax during forced inhalation

O Third, fourth, and fifth ribs

I Medial surface of coracoid process of the scapula



Anterior View



Serratus Anterior, page 86

A **Abduct** the scapula (scapulothoracic joint)

Upwardly rotate the scapula (S/T joint)

Depress the scapula (S/T joint)

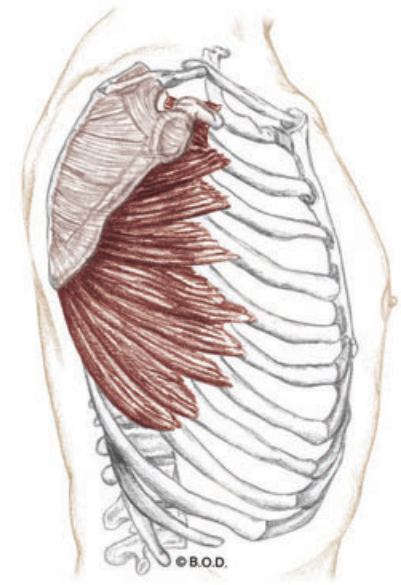
Hold the medial border of the scapula against the rib cage

With the scapula fixed:

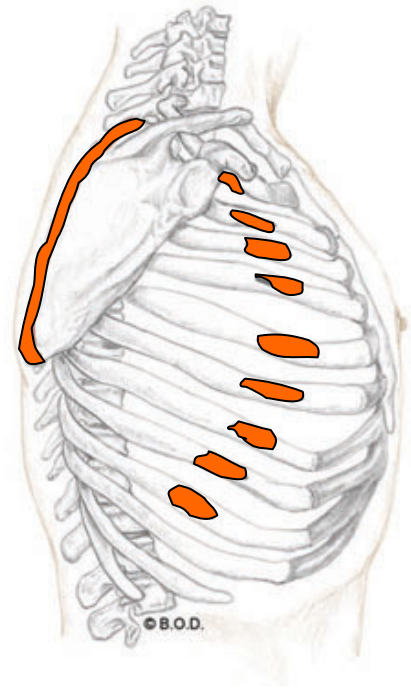
May act to **elevate** the thorax during forced inhalation

O External surfaces of upper eight or nine ribs

I Anterior surface of medial border of the scapula



Lateral View





29b Kinesiology: AOIs - Glenohumeral and Scapulothoracic Joint Muscles