

# 5b Kinesiology:

## AOIs - Posterior Upper Body





## 5b Kinesiology: AOIs - Posterior Upper Body

### Activity Timing

10 minutes	<b>Break</b> Announce the return time and write it on the board.
5 minutes	<b>Attendance</b> Also project the “Class Reminders” slide.
25 minutes	<b>Cadaver Video:</b> Acland’s Atlas of Human Anatomy
60 minutes	<b>Active study:</b> Coloring, self study, breakout rooms
20 minutes	<b>Break</b> Announce the return time and write it on the board.
35 minutes	<b>Active study:</b> Skeletons and clay, self study
30 minutes	<b>Palpation Video:</b> Trail Guide palpation videos with palpation
10 minutes	<b><u>Break down, clean up, and circle up</u></b>
3h 15m	<b>Total Class Time plus 15 flex minutes</b>



# 5b Kinesiology:

## AOIs - Posterior Upper Body

### Class Reminders

#### **Assignments:**

- 7a Review Questions (A: 119-130)

#### **Quizzes and Exams:**

- 6a Kinesiology Quiz (A: 73, and 75-80)
  - AOIs of deltoid, traps, lats, teres major, triceps, rhomboids, and erectors
  - Also definitions on A-51: anterior, posterior, lateral, medial, belly, tendon, action, origin, and insertion

#### **Preparation for upcoming classes:**

- 6a A&P: Introduction to the Human Body - Tissues
  - Trail Guide: gluteals
  - Salvo: pages 391-398
  - Packet E: 7-10
  - RQ Packet A-129
- 6b Swedish: Technique Review and Practice - Posterior Upper Body
  - Packet F: 29-30



# Classroom Rules

**Punctuality** - everybody's time is precious

- Be ready to learn at the start of class; we'll have you out of here on time
- Tardiness: arriving late, returning late after breaks, leaving during class, leaving early

**The following are not allowed:**

- Bare feet
- Side talking
- Lying down
- Inappropriate clothing
- Food or drink except water
- Phones that are visible in the classroom, bathrooms, or internship

*You will receive one verbal warning, then you'll have to leave the room.*

# Classroom Rules

## **Cell Phones – Turn it off!**



And put it away!



# Cadaver Video

- Triceps Brachii
- Teres Major
- Rhomboids, Levator, and Trapezius
- Latissimus Dorsi and Deltoid
- Erector Spinae



# Coloring Anatomy

Write this list on the board and turn the projector off for now:

- Deltoid
- Trapezius
- Latissimus dorsi
- Teres major
- Triceps brachii
- Rhomboid major
- Rhomboid minor
- Spinalis
- Longissimus
- Iliocostalis



# Palpation

## Set Up by the Students

- Students form groups of 3.
- Each group sets up a table and gets 1 face cradle, 1 bolster, and 2 chairs.
- Receivers must remain clothed.
- There will be no need of sheets except for a face cradle cover.

## Demo and Practice

- All of the students come to a central table to watch a brief demonstration of how to palpate one of the focus muscles:
  - List and identify the bony landmarks, especially origins and insertions.
  - List and identify the muscle bellies and tendons.
  - List and explain the actions.
  - Demo how to palpate the muscle while simultaneously offer resistance to the action, “Contract, relax. Contract, relax.”
  - The students go back to their table to practice the palpation.
  - 2 students palpate the third student collaboratively.
  - The instructor and assistant circulate to offer guidance and touch comparisons:
- This process repeats for each muscle that will be palpated.
- Once all the focus muscles have been palpated on the first student, repeat the process so that each student will palpate twice and be palpated once.

Prone

# Trapezius

- A** *Upper fibers:*  
Bilaterally  
**Extend** the head and neck  
Unilaterally  
**Laterally flex** the head and neck to the same side  
**Rotate** the head and neck to the opposite side  
**Elevate** the scapula (scapulothoracic joint)  
**Upwardly rotate** the scapula (S/T joint)

## *Middle fibers:*

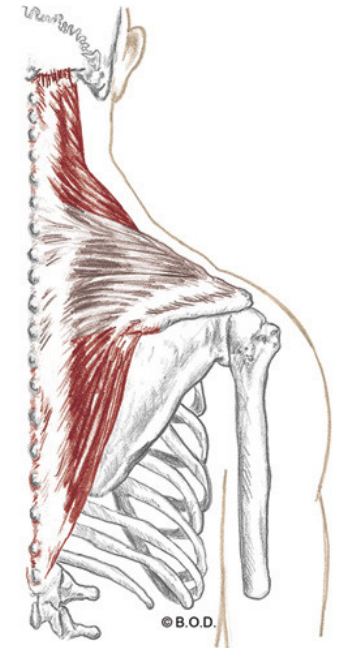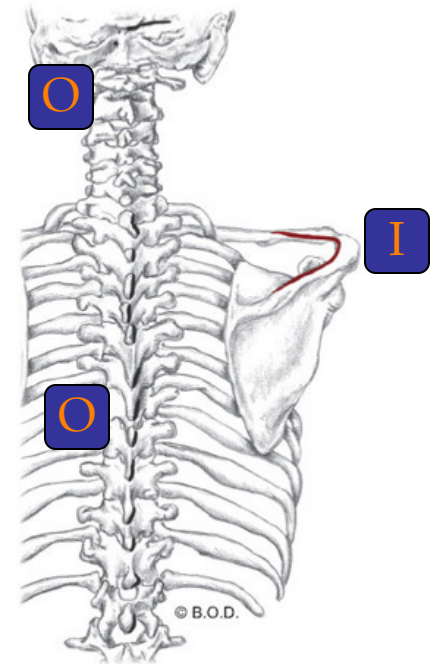
- Adduct** the scapula (S/T joint)  
**Stabilize** the scapula (S/T joint)

## *Lower fibers:*

- Depress** the scapula (S/T joint)  
**Upwardly rotate** the scapula (S/T joint)

- O** External occipital protuberance  
Medial portion of superior nuchal line  
Ligamentum nuchae  
Spinous processes of C-7 through T-12

- I** Lateral one-third of clavicle  
Acromion  
Spine of scapula



# Rhomboid Major and Minor

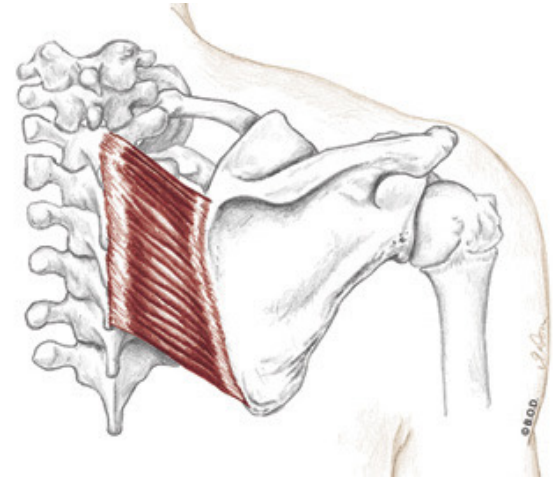
- A** **Adduct** the scapula (scapulothoracic joint)  
**Elevate** the scapula (S/T joint)  
**Downwardly rotate** the scapula (S/T joint)

- O** *Major:*  
Spinous process of T2 to T5

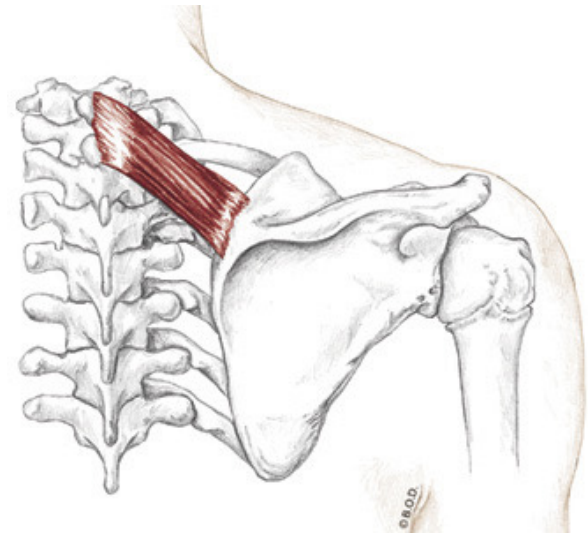
*Minor:*  
Spinous process of C7 and T1

- I** *Major:*  
Medial border of the scapula between the spine of the scapula and inferior angle

*Minor:*  
Upper portion of medial border of the scapula, across from the spine of the scapula



Posterior View



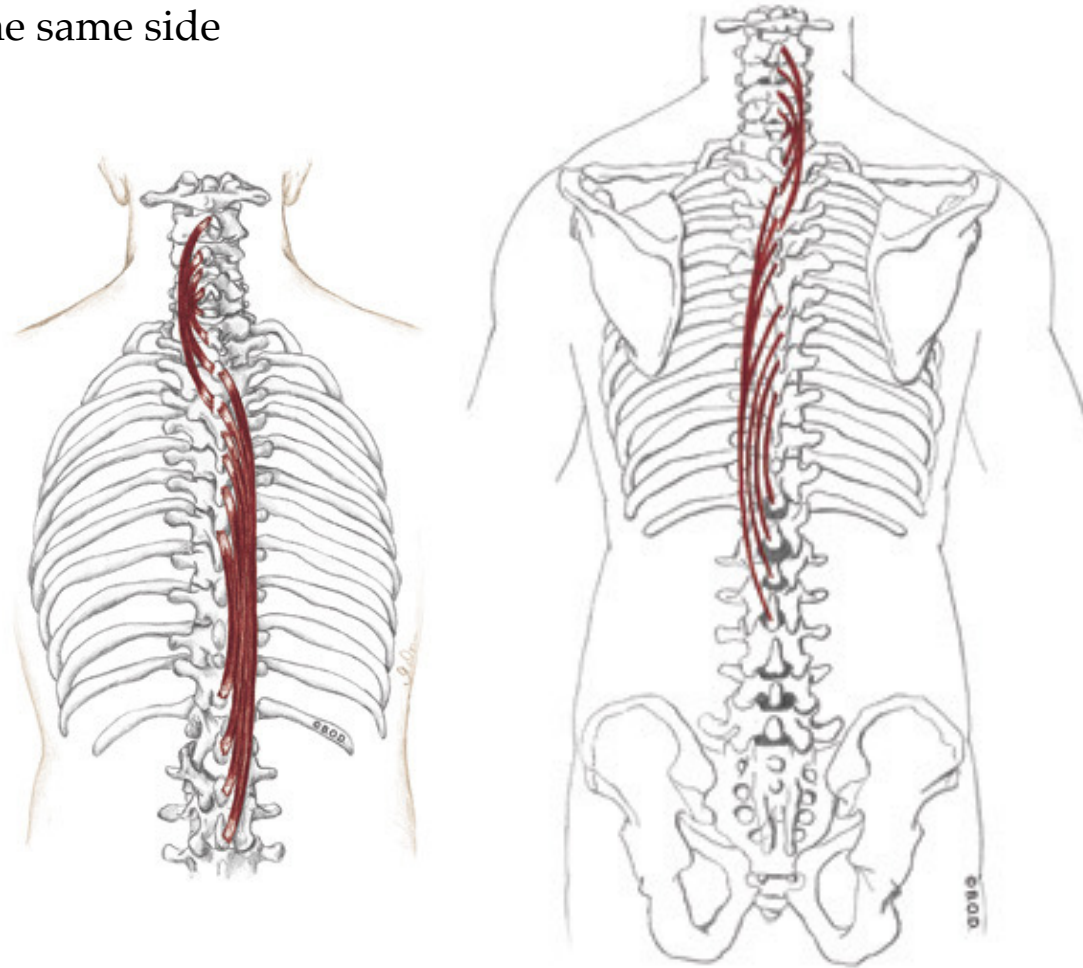
# Spinalis, page 197

**A** *Unilaterally:*  
**Laterally flex** vertebral column to the same side

*Bilaterally:*  
**Extend** the vertebral column

**O** Spinous processes of:  
C7 vertebrae  
Upper lumbar vertebrae  
Lower thoracic vertebrae  
Ligamentum nuchae

**I** Spinous processes of:  
Upper thoracic vertebrae  
Cervical vertebrae



Posterior View

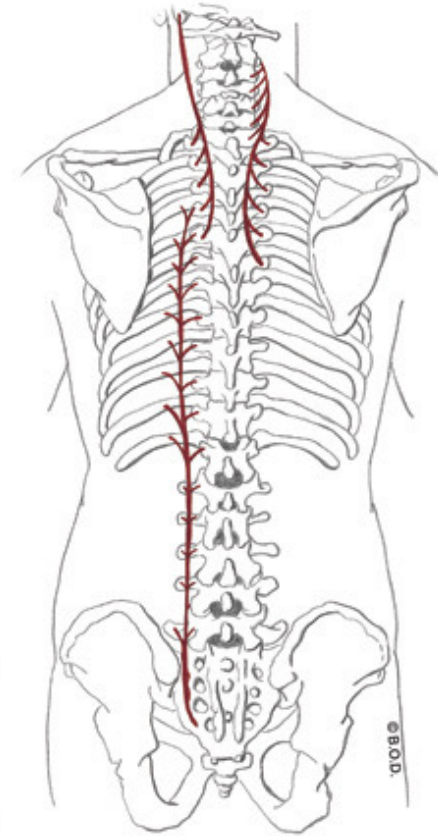
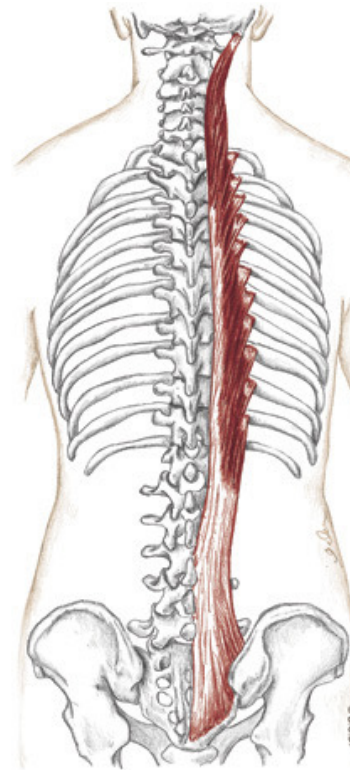
# Longissimus, page 198

**A** *Unilaterally:*  
**Laterally flex** vertebral column to the same side

*Bilaterally:*  
**Extend** the vertebral column

**O** Common tendon (thoracis)  
Transverse processes of upper five thoracic  
vertebrae (cervicis and capitis)

**I** Lower nine thoracic ribs (thoracis)  
Lower nine thoracic transverse processes (thoracis)  
Cervical transverse processes (cervicis)  
Mastoid process of temporal bone (capitis)



Posterior View

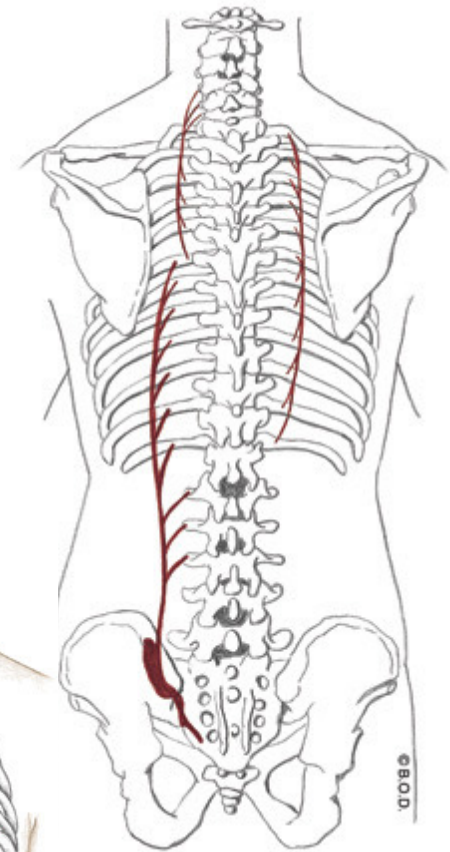
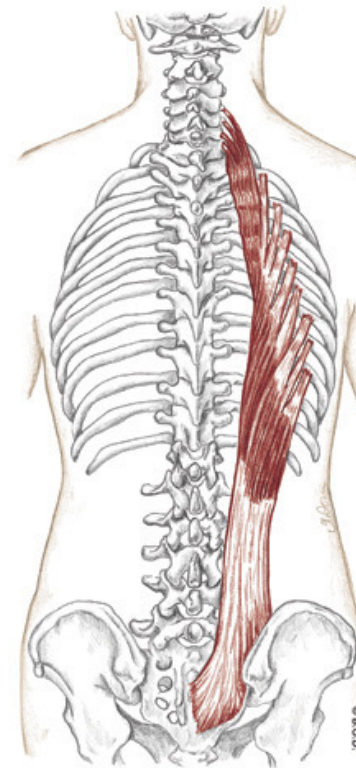
# Iliocostalis, page 198

**A** *Unilaterally:*  
**Laterally flex** vertebral column to the same side

*Bilaterally:*  
**Extend** the vertebral column

**O** Common tendon (thoracis)  
Posterior surface of ribs 1-12 (thoracis and cervicis)

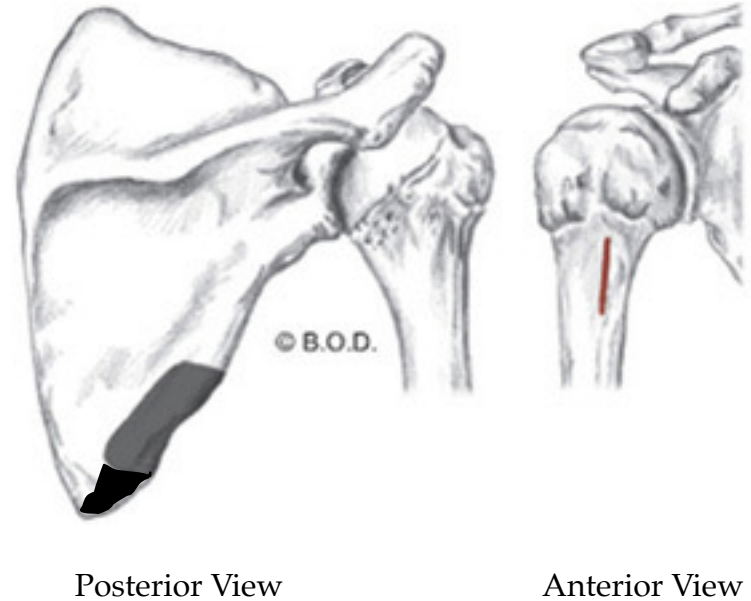
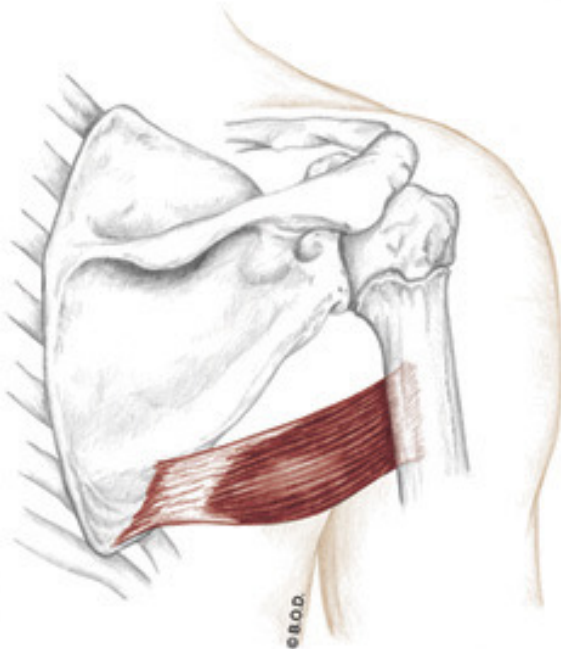
**I** Transverse processes of lumbar vertebrae 1-3  
(thoracis)  
Posterior surface of ribs 6-12 (lumborum)  
Posterior surface of ribs 1-6 (thoracis)  
Transverse processes of lower cervicals (cervicis)



Posterior View

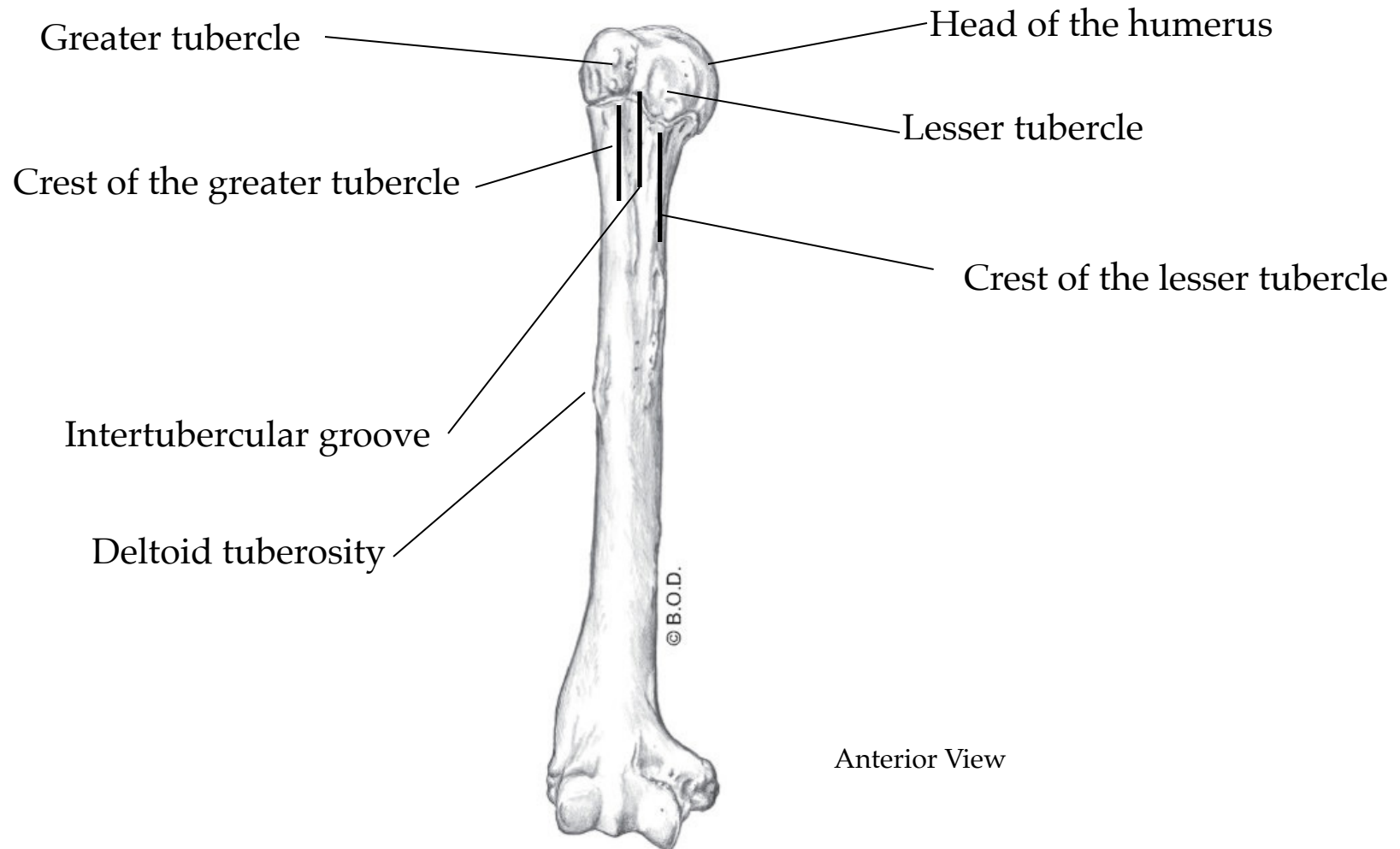
# Teres major

- A** **Extend** the shoulder (glenohumeral joint)  
**Adduct** the shoulder (G/H joint)  
**Medially rotate** the shoulder (G/H joint)
- O** Inferior angle of scapula  
Lower one-third of lateral border of the scapula
- I** Crest of the lesser tubercle of the humerus



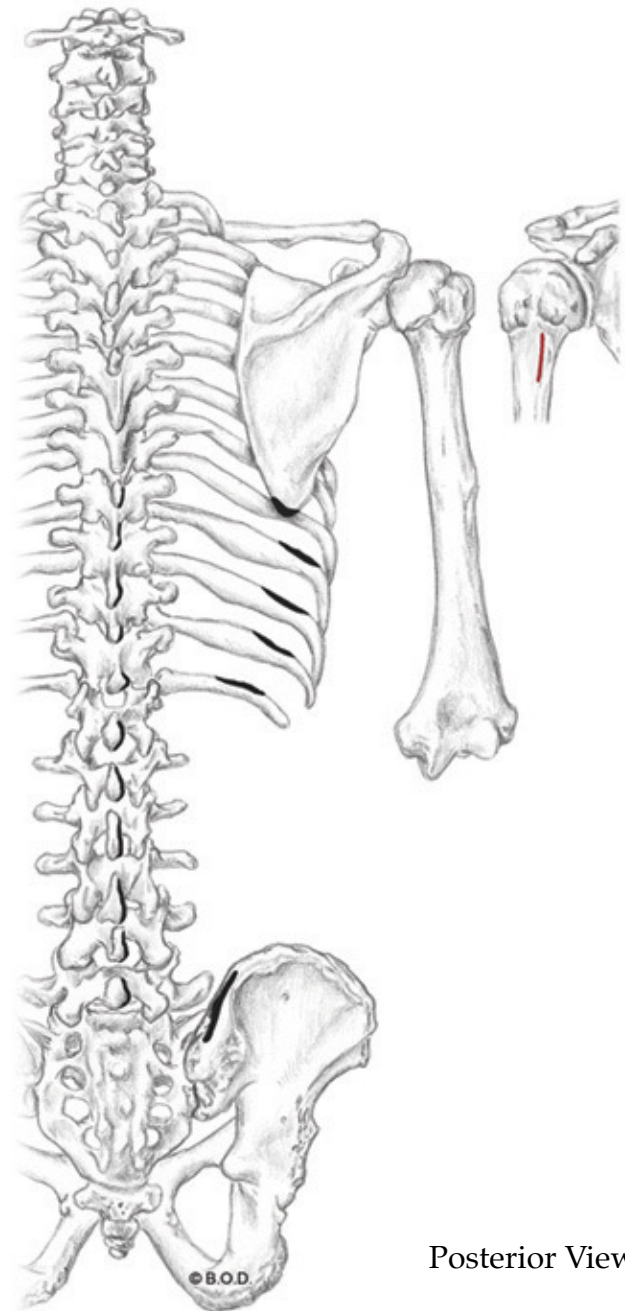
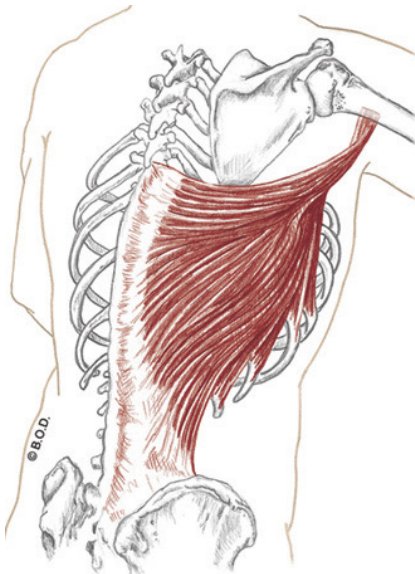
# Bony Landmarks of the Humerus

Trail Guide, page 50



# Latissimus dorsi

- A** **Extend** the shoulder (glenohumeral joint)  
**Adduct** the shoulder (G/H joint)  
**Medially rotate** the shoulder (G/H joint)
- O** Inferior angle of scapula  
Spinous processes of last six thoracic vertebrae  
Last three or four ribs  
Thoracolumbar aponeurosis  
Posterior iliac crest
- I** Intertubercular groove of the humerus



Posterior View

# Triceps brachii

**A** All heads:  
**Extend** the elbow (humeroulnar joint)

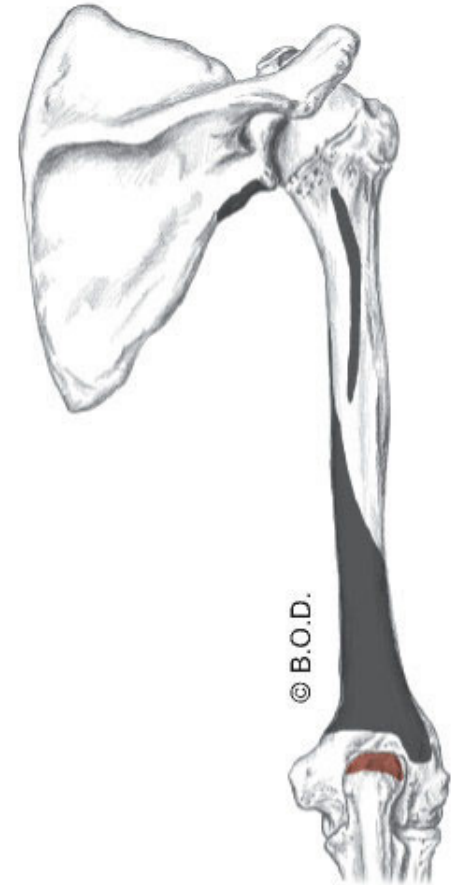
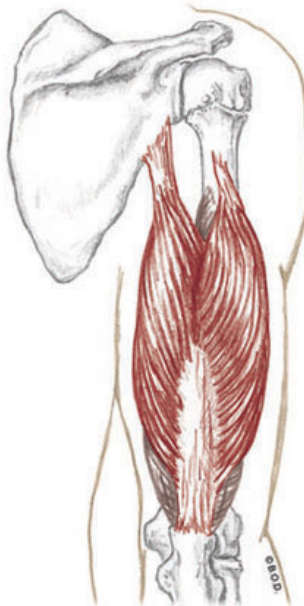
Long head:  
**Extend** the shoulder (glenohumeral joint)  
**Adduct** the shoulder (G/H joint)

**O** Long head:  
Infraglenoid tubercle of the scapula

Lateral head:  
Posterior surface of proximal half  
of the humerus

Medial head:  
Posterior surface of distal half  
of the humerus

**I** Olecranon process of the ulna



Posterior View

Supine

# Deltoid

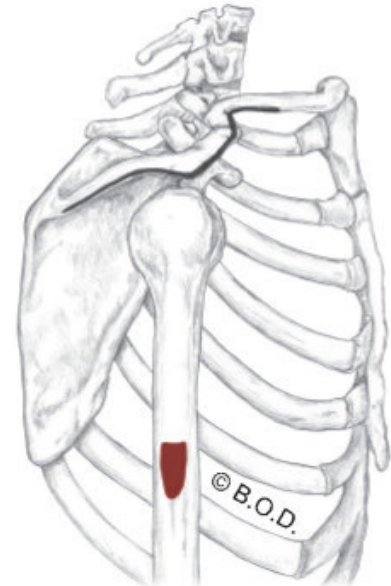
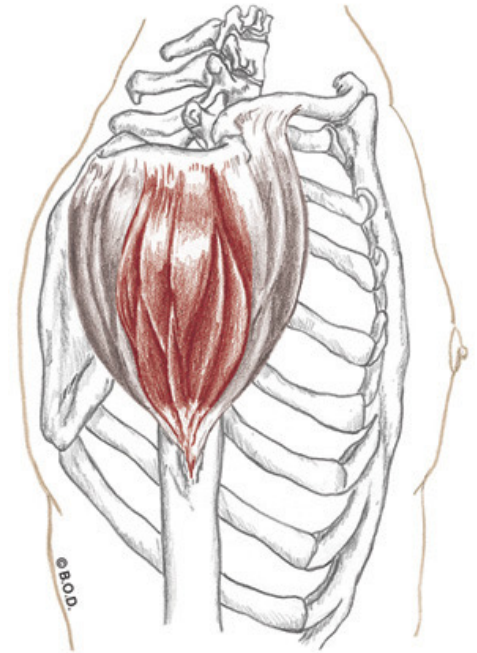
**A** All fibers:  
**Abduct** the shoulder (G/H joint)

Anterior fibers:  
**Flex** the shoulder (G/H joint)  
**Medially rotate** the shoulder (G/H joint)  
**Horizontally adduct** the shoulder (G/H joint)

Posterior fibers:  
**Extend** the shoulder (G/H joint)  
**Laterally rotate** the shoulder (G/H joint)  
**Horizontally abduct** the shoulder (G/H joint)

**O** Lateral one-third of clavicle  
Acromion  
Spine of scapula

**I** Deltoid tuberosity





# Active Study

Instructor will give you directions for today's active study. Options may include:

- Self Study
- Group Study
- Group quizzing
- Coloring pages
- Additional videos
- Skeletons and clay
- Stretches and self care
- Etc.

# 5b Kinesiology:

## AOIs - Posterior Upper Body

