



## 61a A&P: Respiratory System



# 61a A&P: Respiratory System

## Class Outline

5 minutes	Attendance, Breath of Arrival, and Reminders
10 minutes	Lecture:
25 minutes	Lecture:
15 minutes	Active study skills:
60 minutes	Total

# 61a A&P: Respiratory System

## Class Reminders

### **ABMP Exam Coach**

- “Access your ABMP account” using instructions on page A-74
- Familiarize yourself with ABMP Exam Coach, especially the “Study Subjects” section
- Preview the preparation assignments for MBLEx Prep classes (74a, 75a, 80a, 81a, 84a, 86a, 87a)

### **Assignments:**

- 62a Deep Tissue: Outside Massages (due before class starts)
- 64b Executive Summary (due before the end of class)  
Packet pages 21-22; Sections 1-4 to be done *in* class.  
completed Executive Summary to be handed in at end of class.
- 66a Review Questions (due before class starts)

### **Quizzes and Exams:**

- 62b Deep Tissue: Touch Assessment **Bring your grading sheet for evaluation A: 83**
- 66a Quiz (59a, 61a, 62a, 63a, 64a, /b, 65a/b)
- 68a Kinesiology Quiz

### **Preparation for upcoming classes:**

- 62a Pathology: Respiratory System  
Packet E: 151-152.; RQ – Packet A-198.



# Classroom Rules

**Punctuality** - everybody's time is precious

- Be ready to learn at the start of class; we'll have you out of here on time
- Tardiness: arriving late, returning late after breaks, leaving during class, leaving early

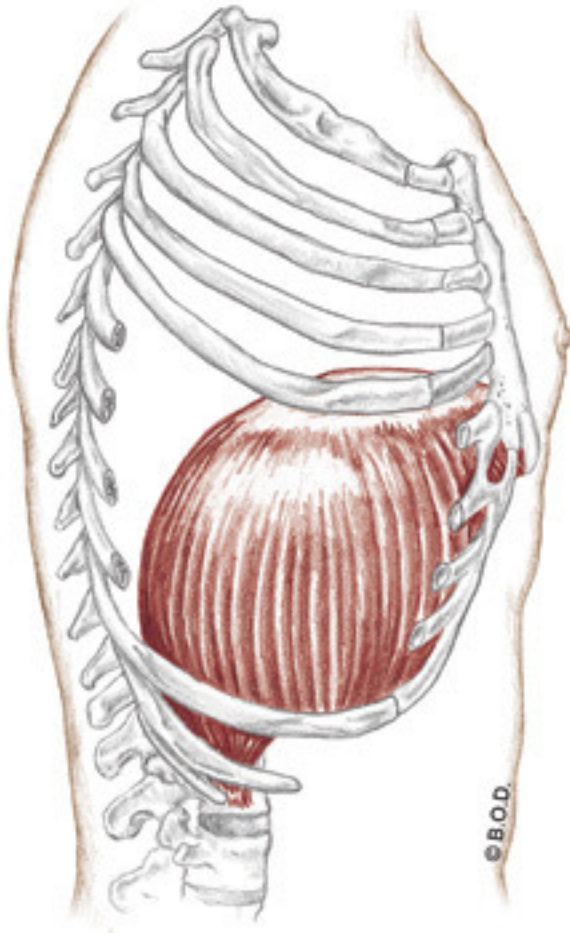
**The following are not allowed:**

- Bare feet
- Side talking
- Lying down
- Inappropriate clothing
- Food or drink except water
- Phones that are visible in the classroom, bathrooms, or internship

*You will receive one verbal warning, then you'll have to leave the room.*

# Diaphragm

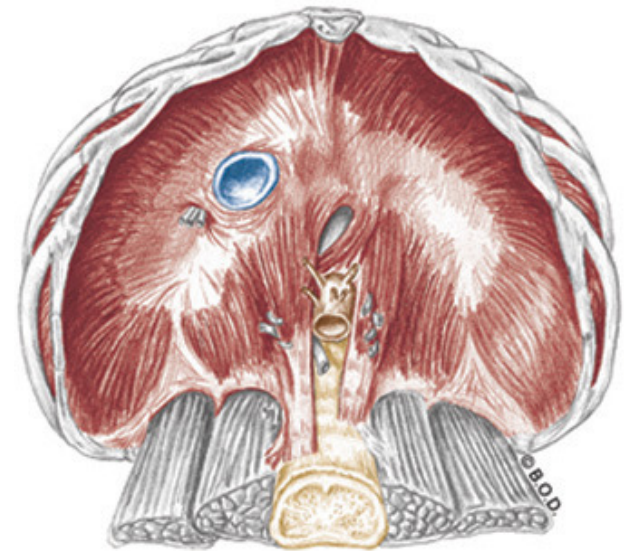
## Trail Guide, Page 213



Lateral View

The **diaphragm** is the primary muscle of respiration.

It has a broad, umbrella-like shape that separates the thoracic cavity from the abdominal cavity.



Inferior View

# Diaphragm, page 213

**A** Draw down the central tendon of the diaphragm

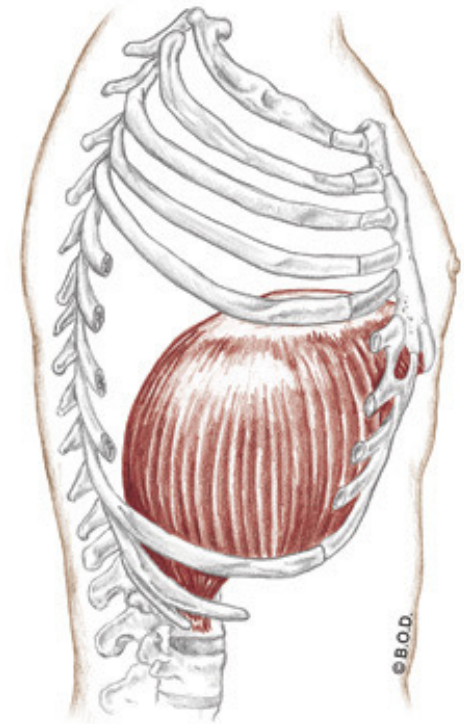
Increase the volume of the thoracic cavity during inhalation

**O** Costal attachment: Inner surface of the lower 6 ribs

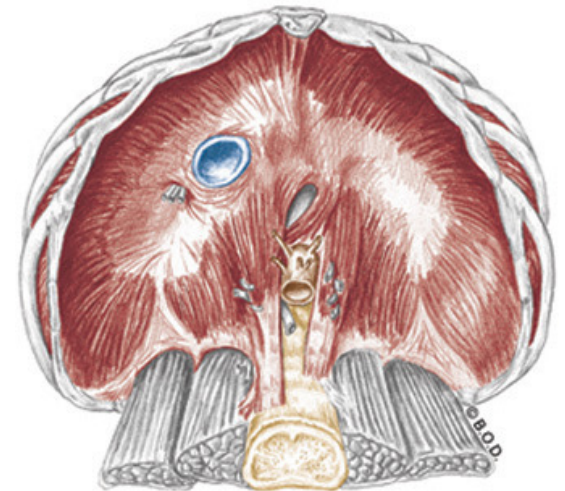
Lumbar attachment: Upper 2 or 3 lumbar vertebrae

Sternal attachment: Inner part of the xiphoid process

**I** Central tendon



Lateral View



Inferior View

# Diaphragm, page 213

**A** Draw down the central tendon of the diaphragm

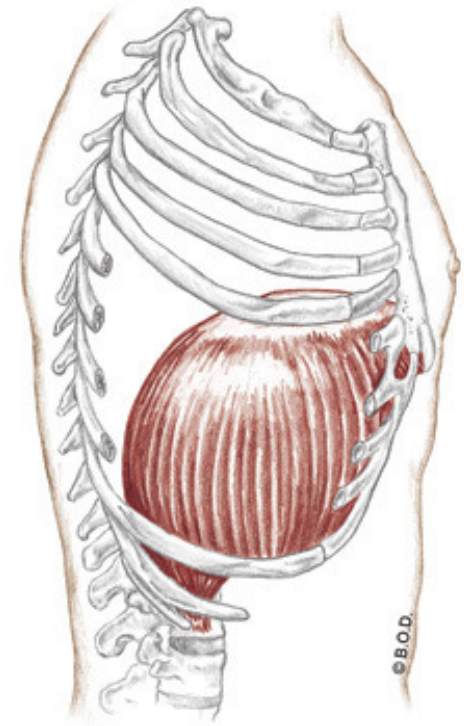
Increase the volume of the thoracic cavity during inhalation

**O** Costal attachment: Inner surface of the lower 6 ribs

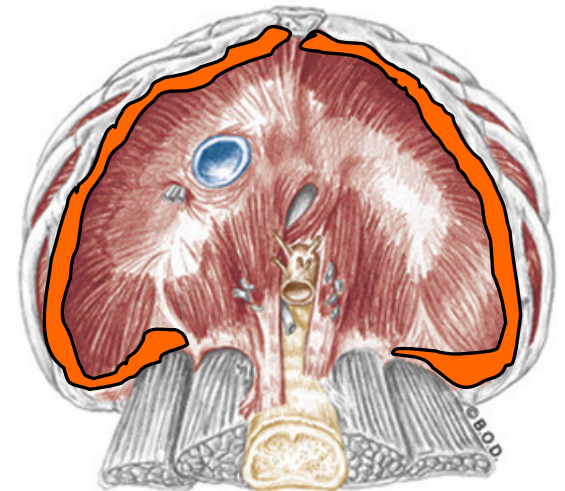
Lumbar attachment: Upper 2 or 3 lumbar vertebrae

Sternal attachment: Inner part of the xiphoid process

**I** Central tendon



Lateral View



Inferior View



# Diaphragm, page 213

**A** Draw down the central tendon of the diaphragm

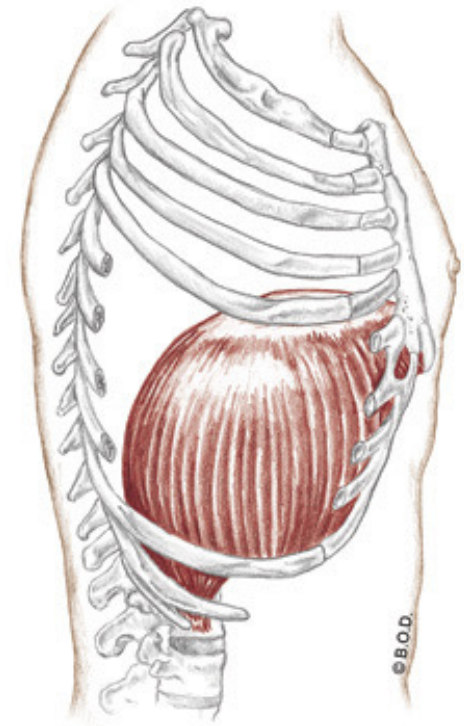
Increase the volume of the thoracic cavity during inhalation

**O** Costal attachment: Inner surface of the lower 6 ribs

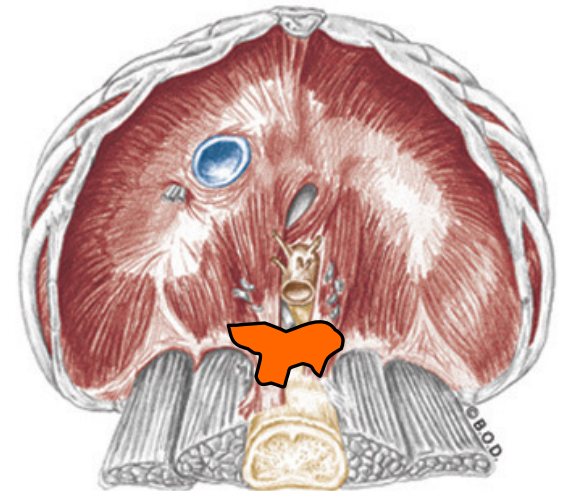
Lumbar attachment: Upper 2 or 3 lumbar vertebrae

Sternal attachment: Inner part of the xiphoid process

**I** Central tendon



Lateral View



Inferior View



# Diaphragm, page 213

**A** Draw down the central tendon of the diaphragm

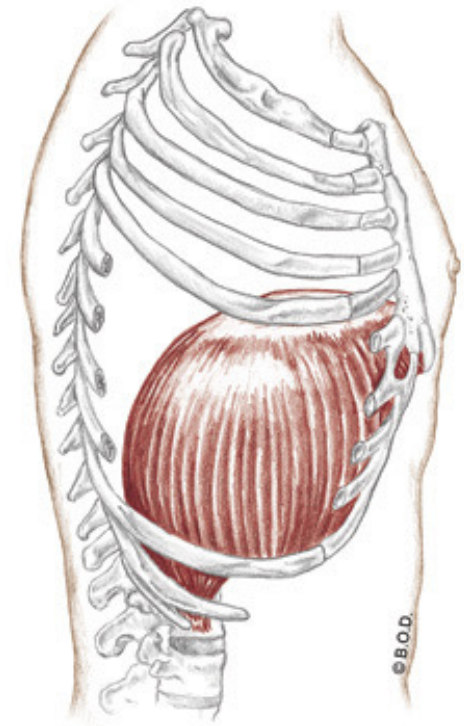
Increase the volume of the thoracic cavity during inhalation

**O** Costal attachment: Inner surface of the lower 6 ribs

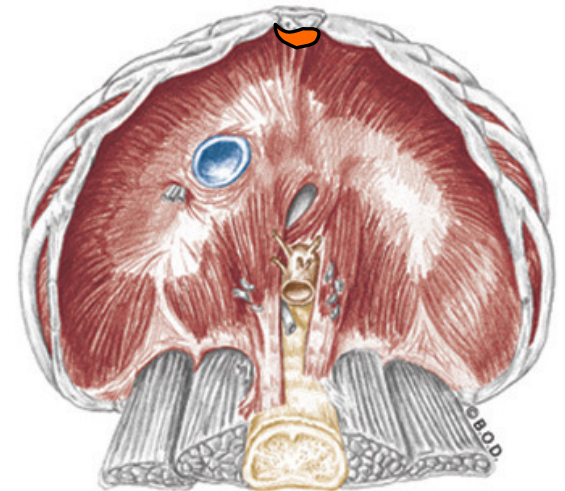
Lumbar attachment: Upper 2 or 3 lumbar vertebrae

Sternal attachment: Inner part of the xiphoid process

**I** Central tendon



Lateral View



Inferior View

# Diaphragm, page 213

**A** Draw down the central tendon of the diaphragm

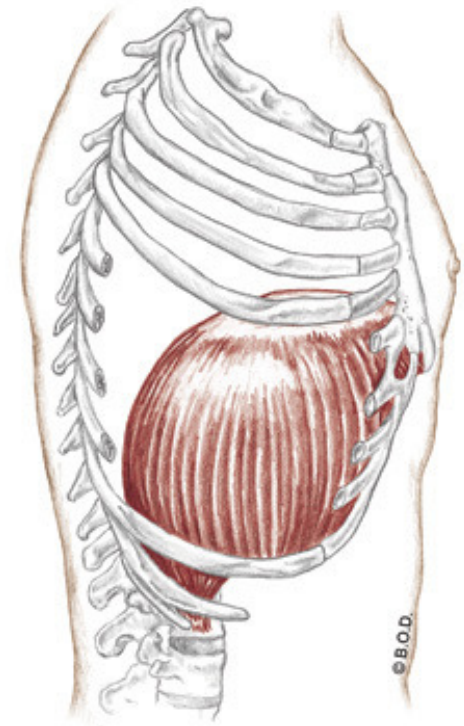
Increase the volume of the thoracic cavity during inhalation

**O** Costal attachment: Inner surface of the lower 6 ribs

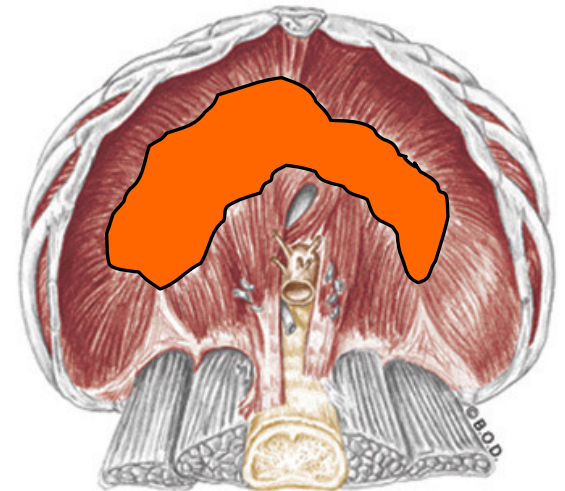
Lumbar attachment: Upper 2 or 3 lumbar vertebrae

Sternal attachment: Inner part of the xiphoid process

**I** Central tendon



Lateral View



Inferior View



# 61a A&P: Respiratory System

Packet E - 145



# Introduction

**Respiration** Movement of air in and out of the lungs, and the exchange of oxygen and carbon dioxide between the blood and body tissues.

The respiratory and cardiovascular systems work together to provide oxygen to the tissues and remove metabolic wastes including carbon dioxide.

Failure of either system results in disruption of homeostasis and rapid cell death from oxygen deprivation.



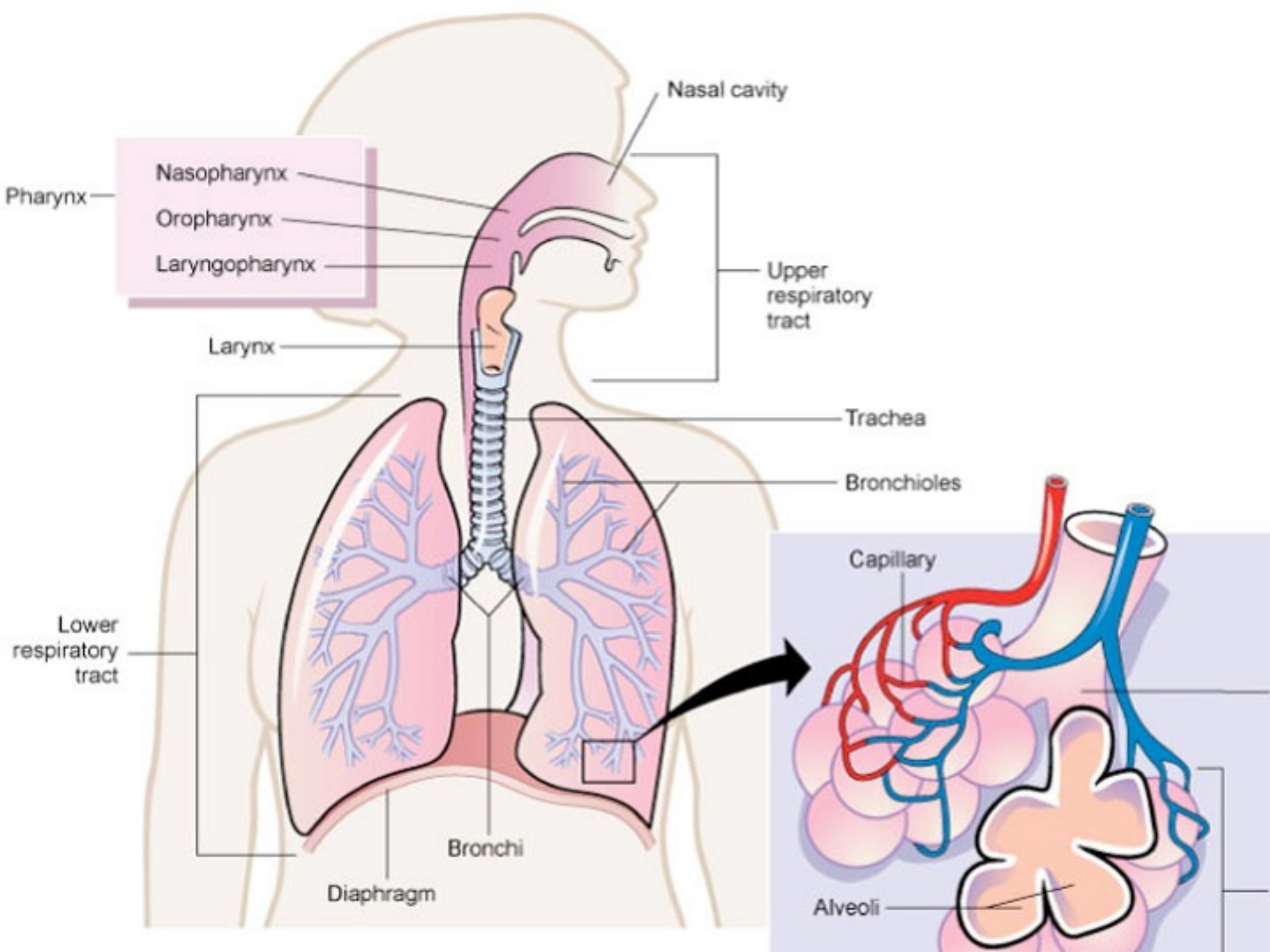
# Anatomy

## Upper respiratory tract

- Nose and nasal cavity
- Pharynx
- Larynx
- Sinuses

## Lower Respiratory tract

- Trachea
- Bronchi and Bronchioles
- Alveolar ducts and alveoli
- Lungs
- Diaphragm



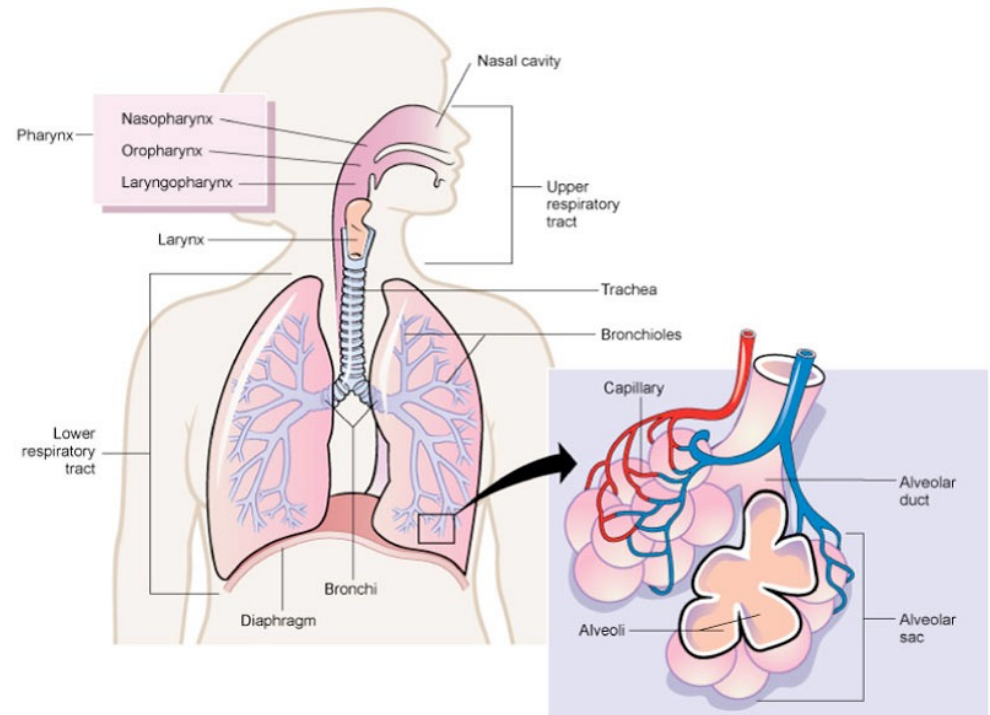
# Physiology

Exchange gases

Olfaction

Sound production

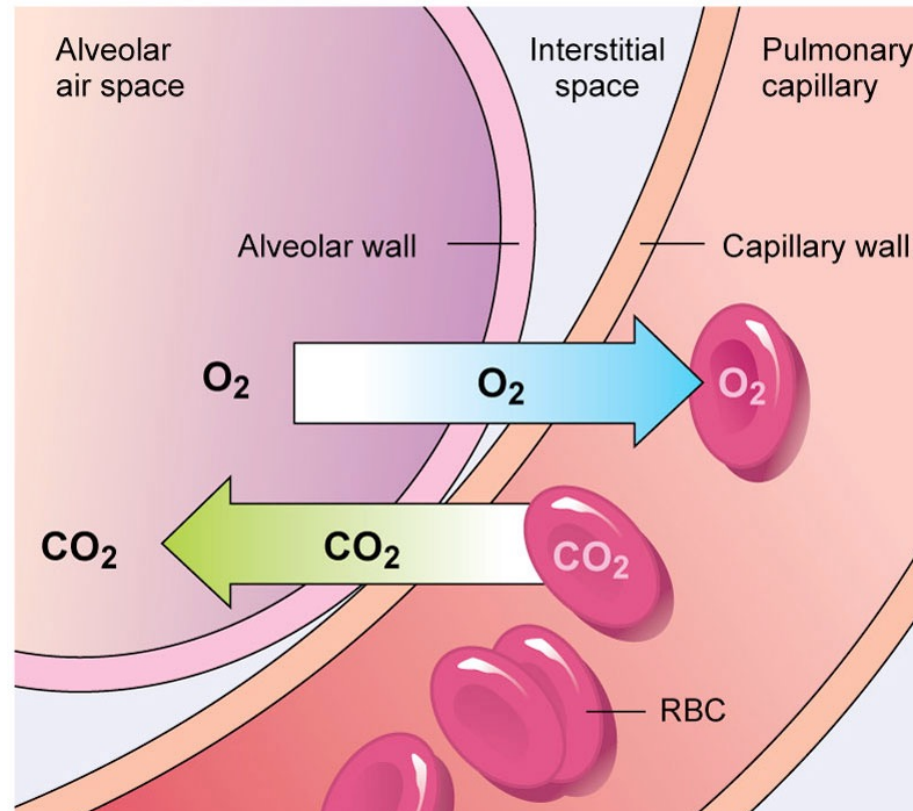
Maintenance of homeostasis





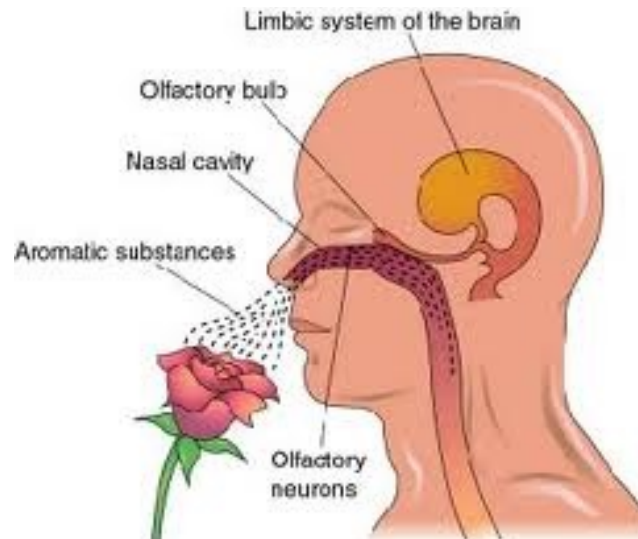
# Physiology

**Exchange gases** Oxygen and CO<sub>2</sub> exchange occurs through the capillary walls in the lungs and in the systemic circulation.



# Physiology

**Olfaction** The sense of smell. During inhalation, scent molecules are forced against ends of the olfactory nerves which connect to the olfactory bulb. The nerve impulse is then carried to the cortex for interpretation.



# Physiology

**Sound production** Air moving over the vocal cords combined with movements of the lips, facial muscles, and tongue forms words and produces speech.





# Physiology

**Maintenance of homeostasis** Maintains oxygen levels in the blood.

Eliminates wastes such as carbon dioxide and heat. Also regulates blood pH.



# Response Moment

The 4 physiologies of the Respiratory System:

- 1.
- 2.
- 3.
- 4.



# Response Moment

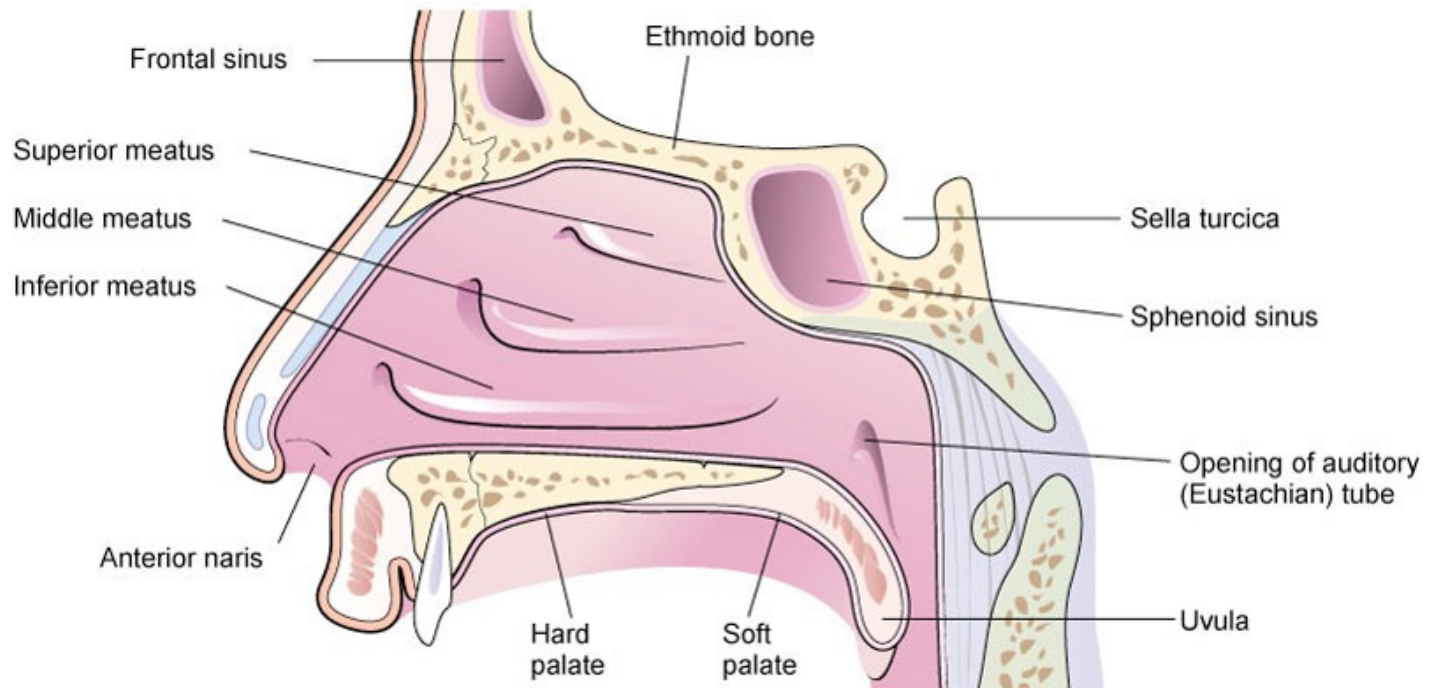
The 4 physiologies of the Respiratory System:

1. Exchange of gases
2. Olfaction
3. Sound production
4. Maintenance of homeostasis

# Upper Respiratory Tract

**Nose** Port of entry for air and the beginning of the air conduction pathway.

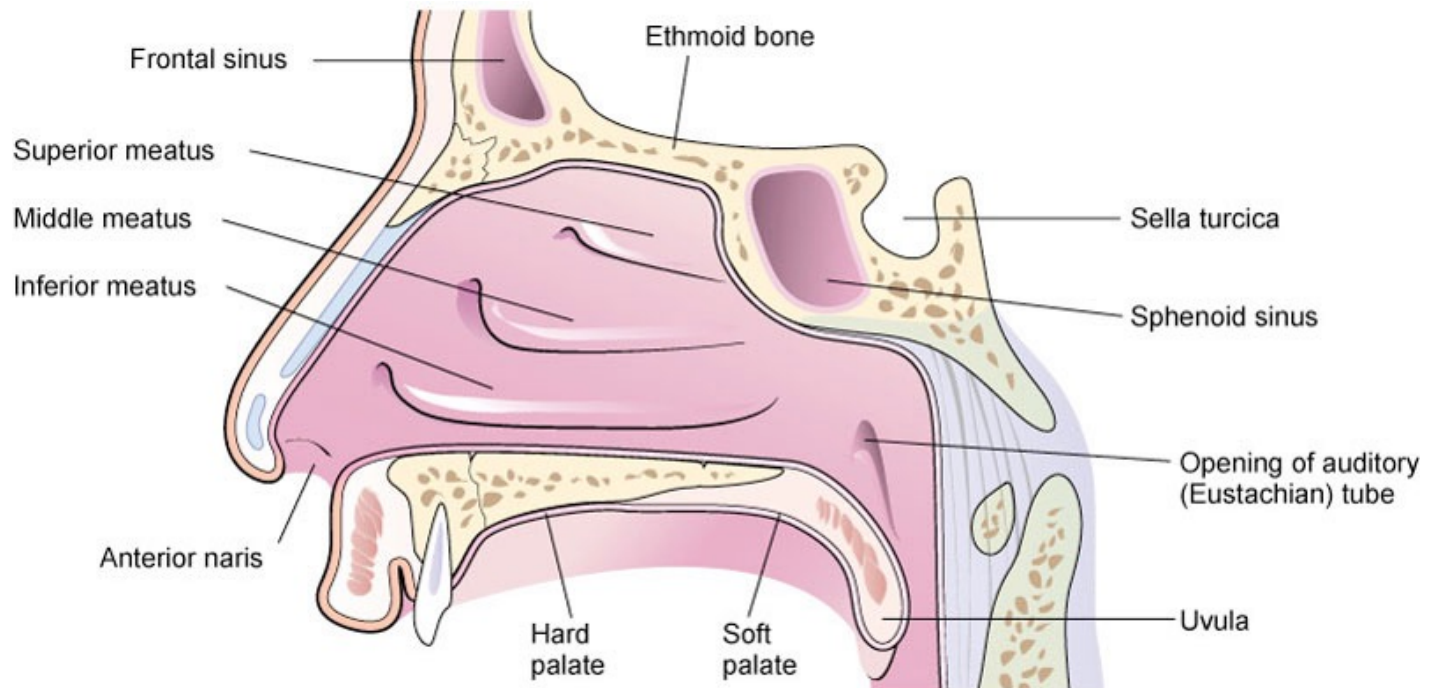
**Nasal hair** Traps particles and foreign matter as air flows through the nose.





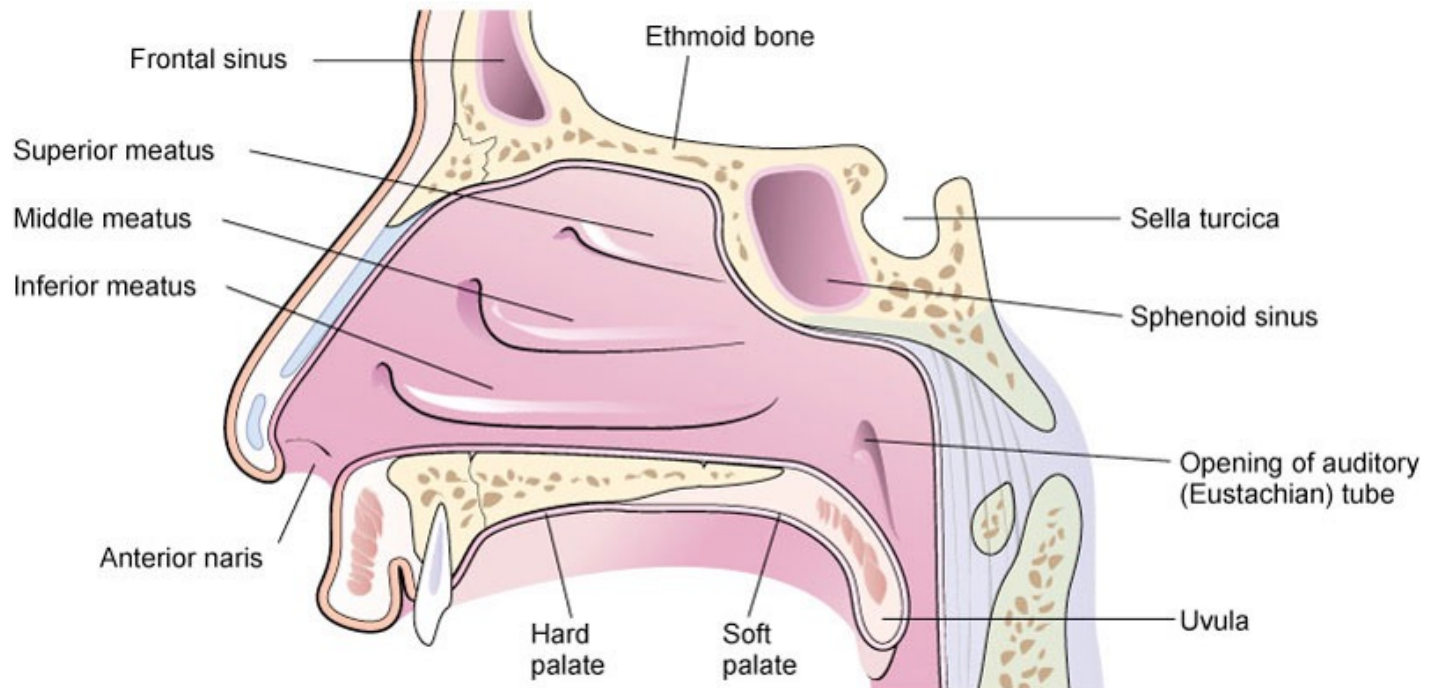
# Upper Respiratory Tract

**Nasal cavity** Cavity just behind the nose where air is warmed by superficial blood vessels and moistened by mucosal secretions.



# Upper Respiratory Tract

**Cilia** Tiny hair-like projections of the mucosae that trap foreign particles and transport them down the throat where they are either swallowed or coughed out through the mouth.





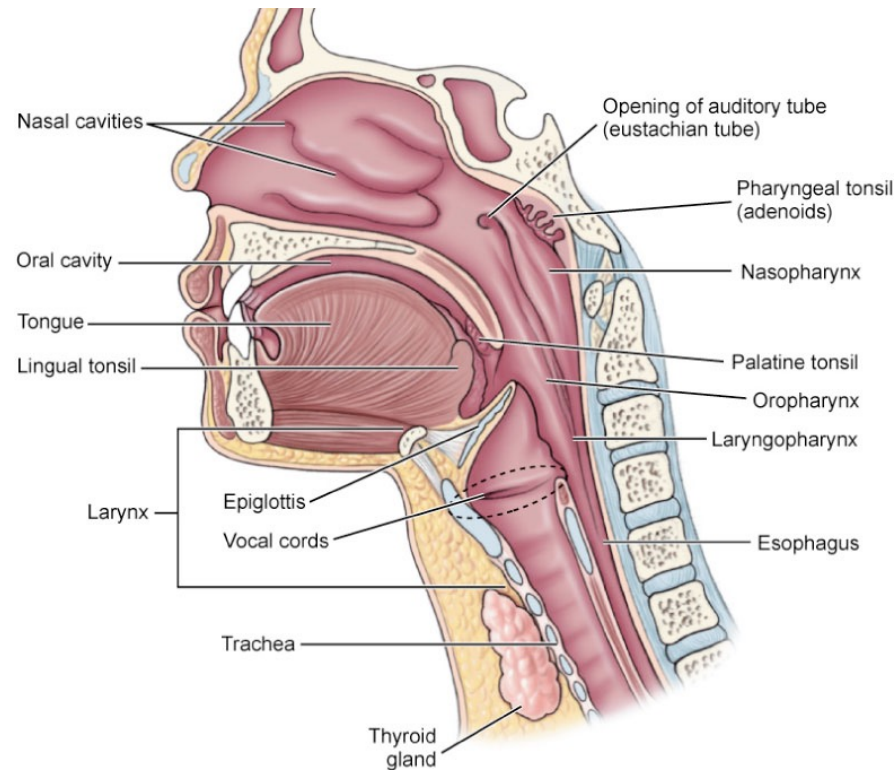
# Upper Respiratory Tract

**Pharynx (AKA: throat)** Muscular tube shared by the respiratory and digestive systems. Contains tonsils and openings to the Eustachian tubes.

**Larynx (AKA: voice box)** Connects the pharynx to the trachea.  
Houses the vocal cords where sound is produced when air passes over them.

# Upper Respiratory Tract

**Epiglottis** Elastic cartilage in the larynx that closes the trachea during swallowing to prevent food and water from entering the lower respiratory tract.





# Response Moment

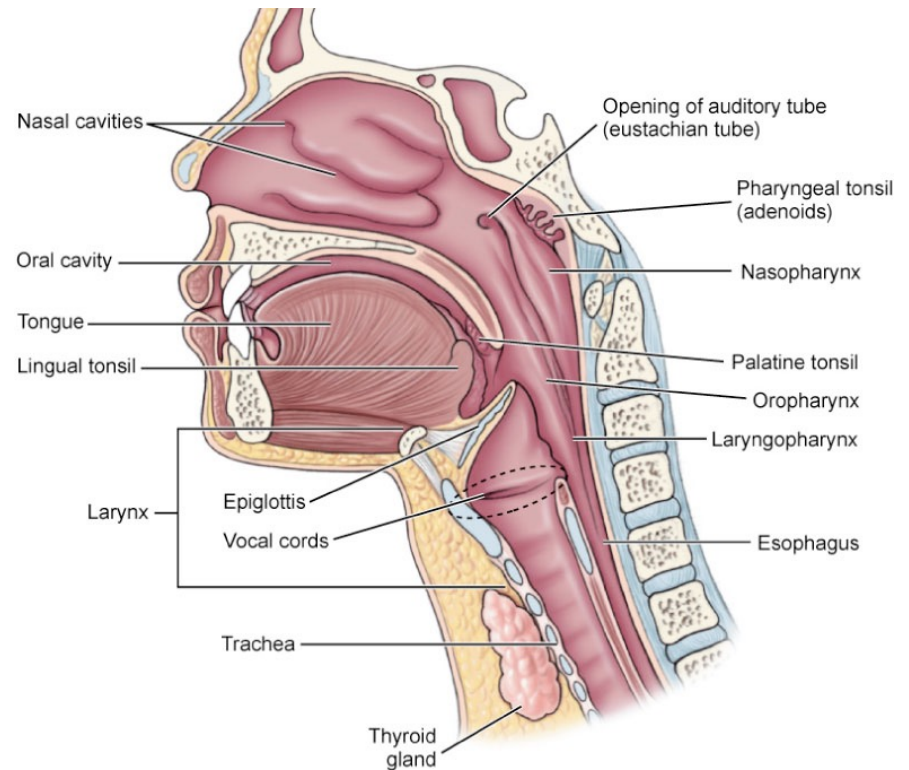
7 anatomical features of the upper respiratory tract:

- 1.
- 2.
- 3.
- 4.
- 5.
- 6.
- 7.

# Response Moment

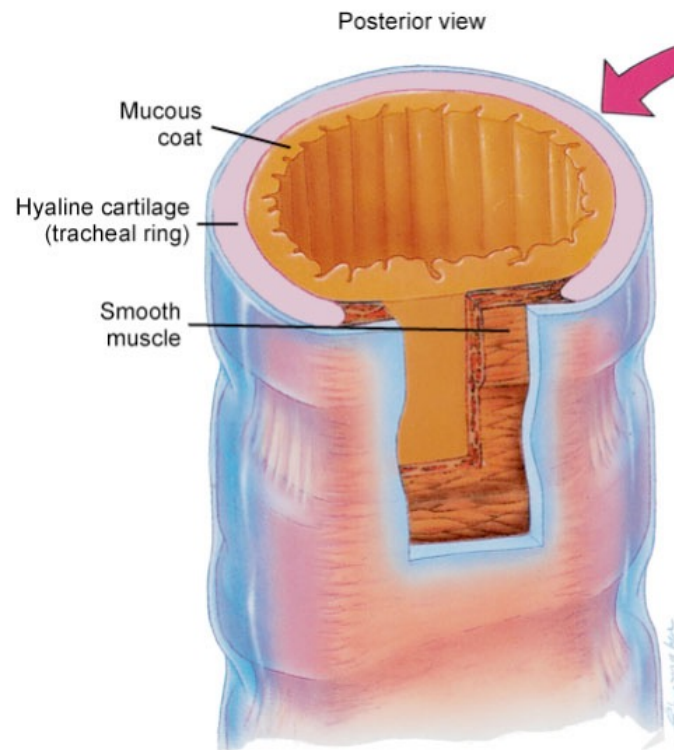
7 anatomical features of the upper respiratory tract:

1. Nose
2. Nasal hairs
3. Nasal cavity
4. Cilia
5. Pharynx
6. Larynx
7. Epiglottis



# Lower Respiratory Tract

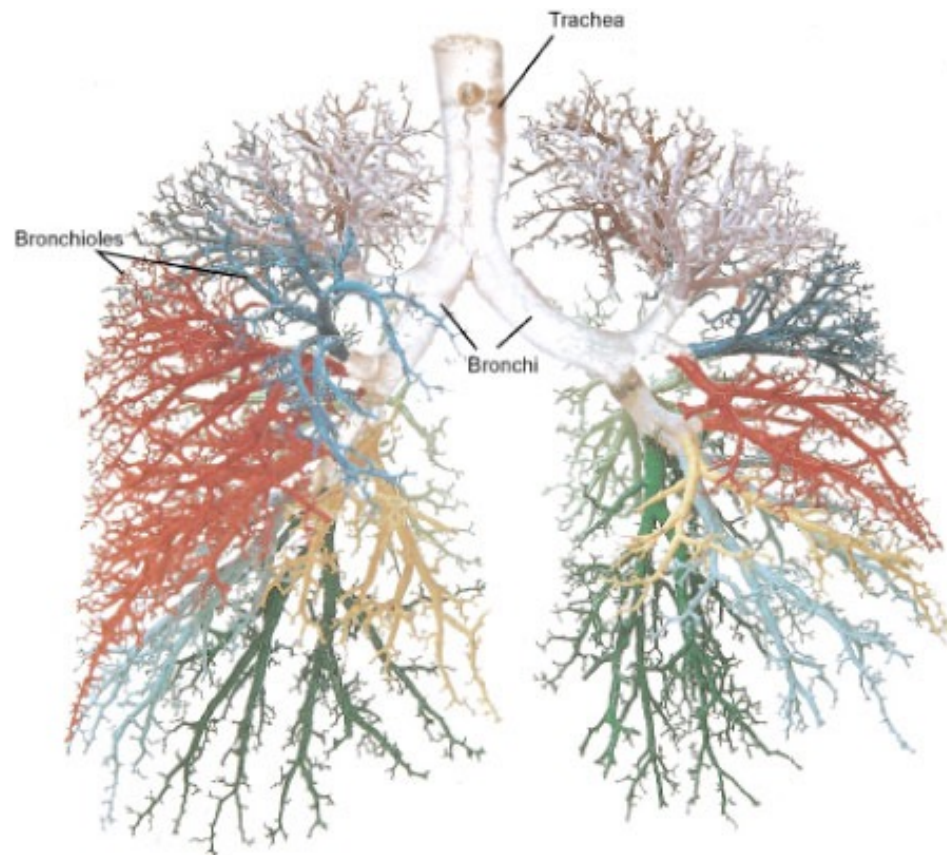
**Trachea (AKA: windpipe)** Tube that connects the larynx to the lungs.





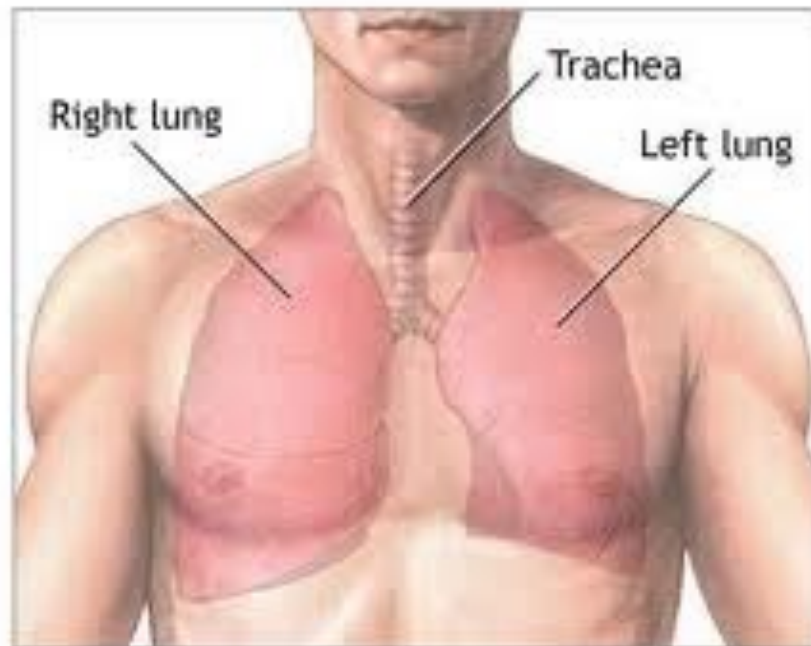
# Lower Respiratory Tract

**Primary bronchi** Air conduction passageways from the trachea to each lung.



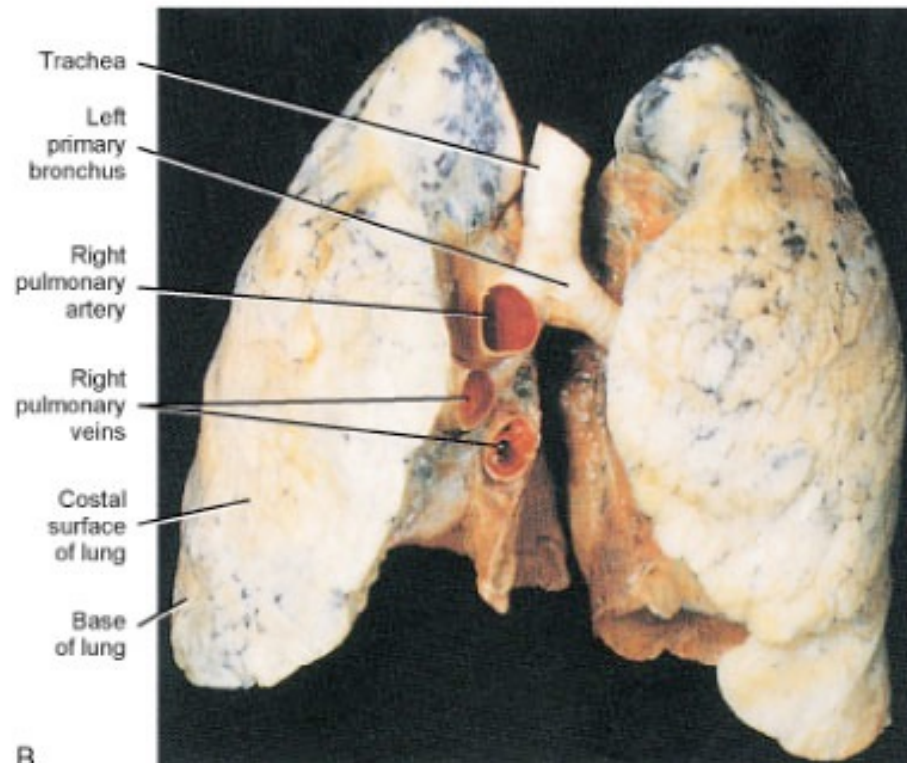
# Lower Respiratory Tract

**Lungs** Primary organs of respiration. Extend from the diaphragm to just above the clavicles. Right lung has 3 lobes. Left lung has 2 lobes.



# Lower Respiratory Tract

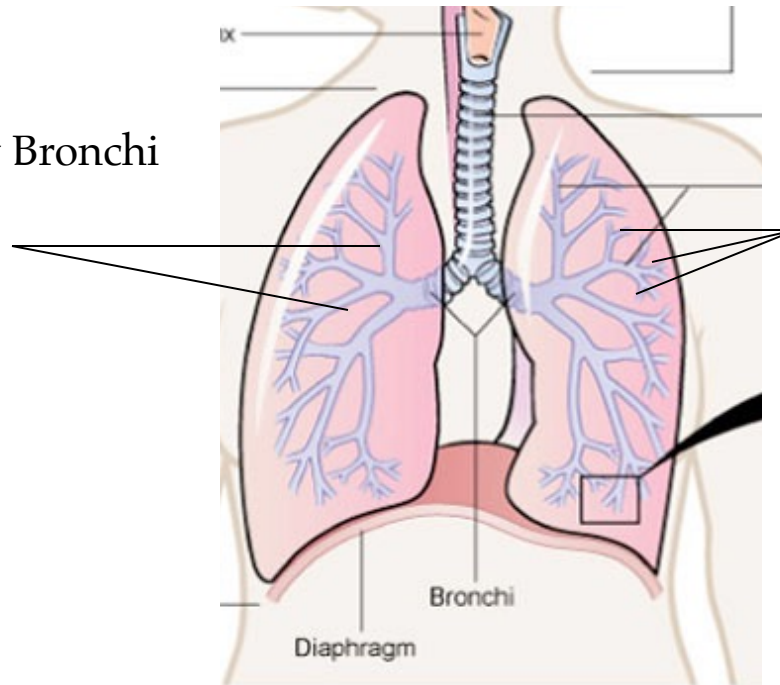
**Lungs** Primary organs of respiration. Extend from the diaphragm to just above the clavicles. Right lung has 3 lobes. Left lung has 2 lobes.



# Lower Respiratory Tract

**Secondary and tertiary bronchi** (not detailed in Salvo) Branches from the primary bronchi, similar to them but decreasing in size.

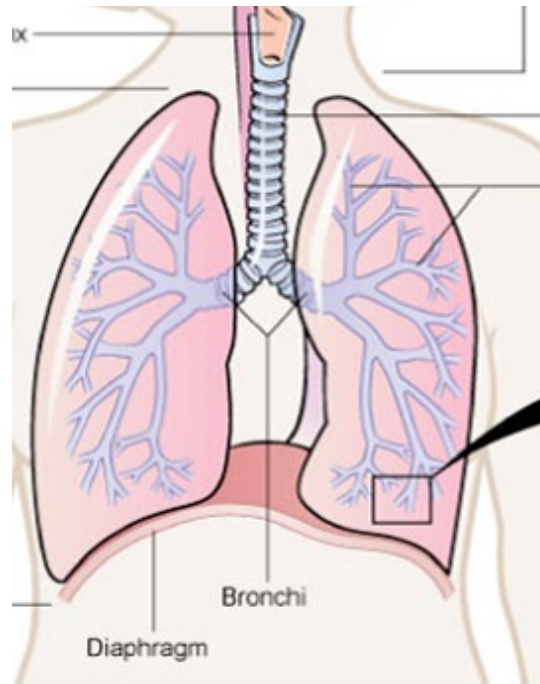
Secondary Bronchi



Tertiary Bronchi

# Lower Respiratory Tract

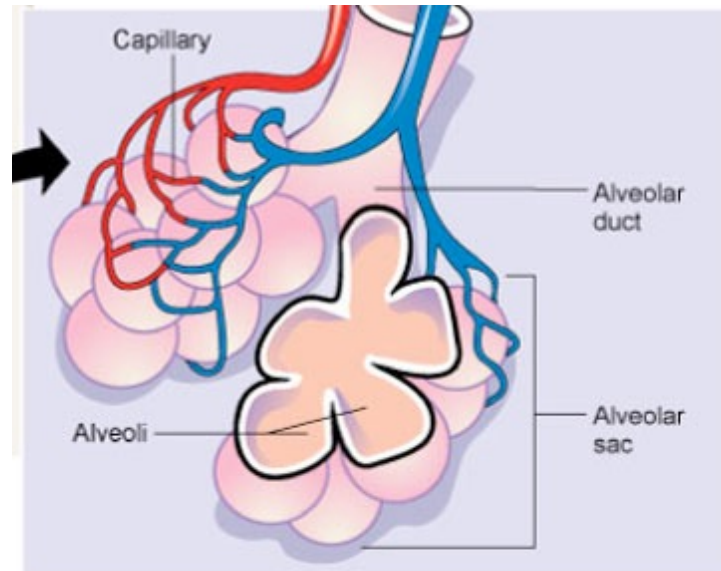
**Bronchioles** Smaller branches off the tertiary bronchi, having no cartilage, and surrounded by smooth muscle.



# Lower Respiratory Tract

**Alveolar ducts** Connect bronchioles to alveoli.

**Alveoli** Tiny sacs attached in clusters resembling grapes to alveolar ducts. Made of single-layer epithelial tissue and surrounded by capillaries which together make gas exchange possible.





# Response Moment

7 anatomical features of the lower respiratory tract:

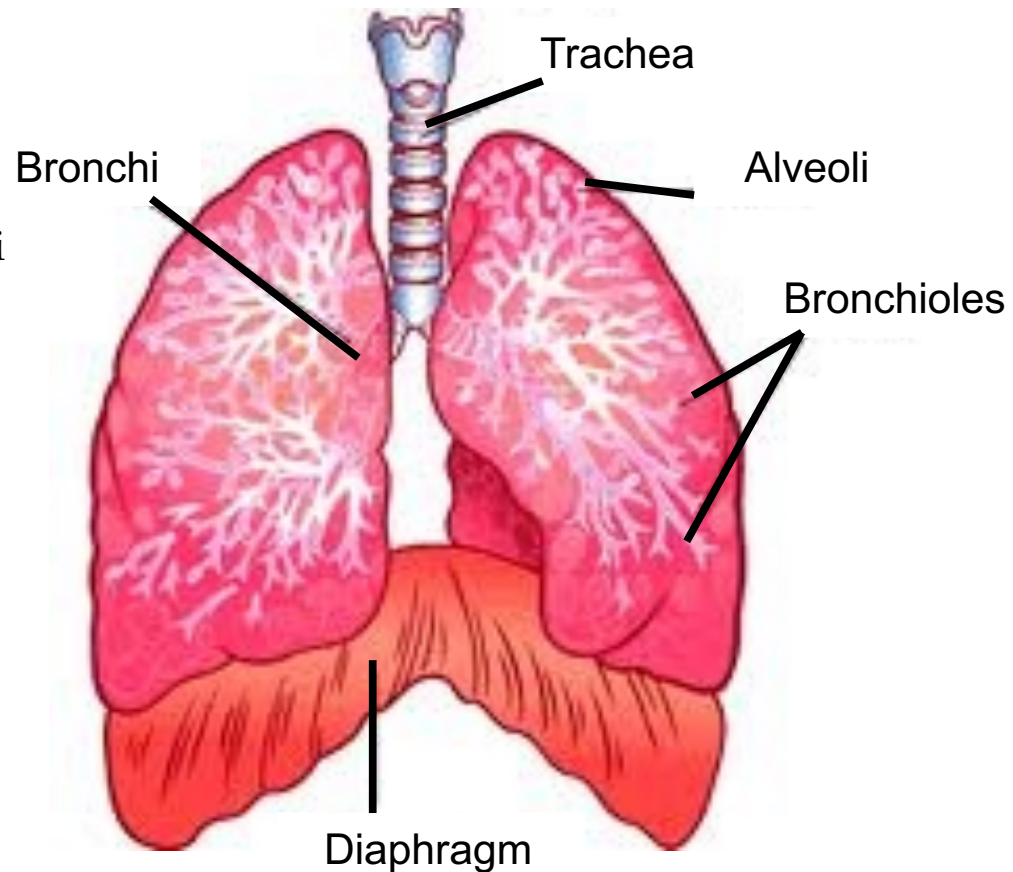
- 1.
- 2.
- 3.
- 4.
- 5.
- 6.
- 7.



# Response Moment

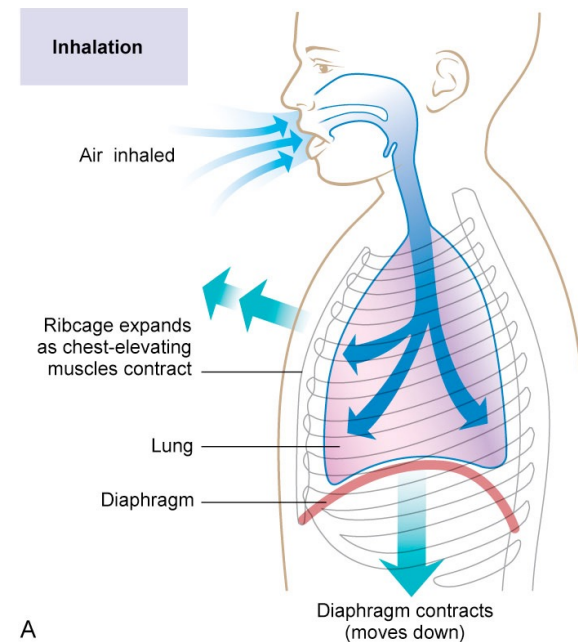
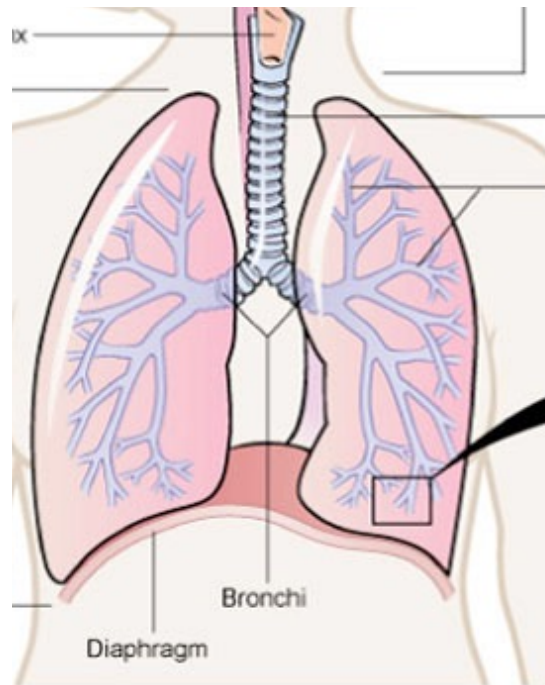
7 anatomical features of the lower respiratory tract:

1. Trachea
2. Primary bronchi
3. Lungs
4. Secondary and tertiary bronchi
5. Bronchioles
6. Alveolar ducts
7. Alveoli



# Diaphragm

**Diaphragm** Main muscle of respiration and structure separating the thoracic cavity from the abdominal cavity.





# Response Moment

Main organ of respiration?

Main muscle of respiration?

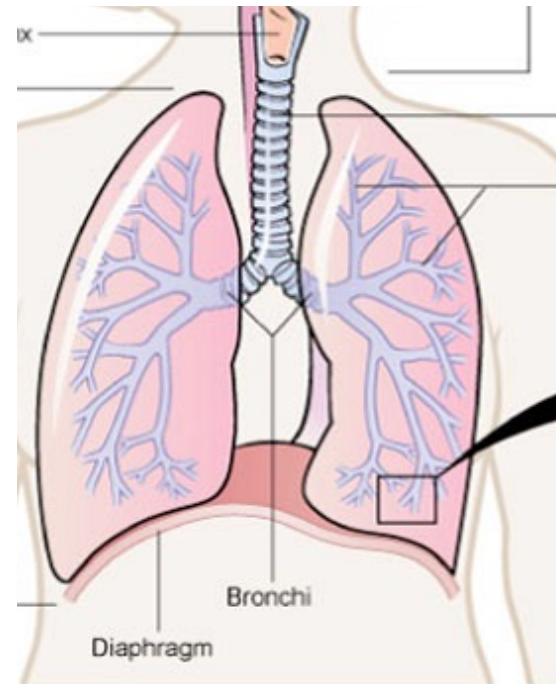
# Response Moment

**Main organ of respiration?**

- Lungs

**Main muscle of respiration?**

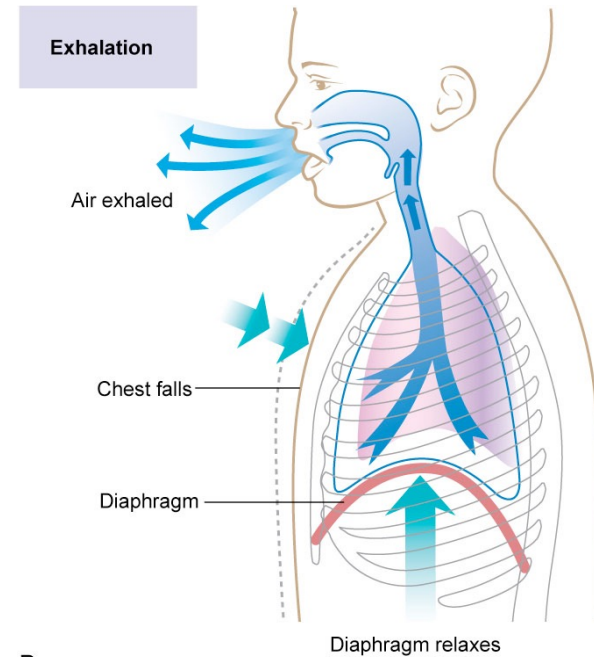
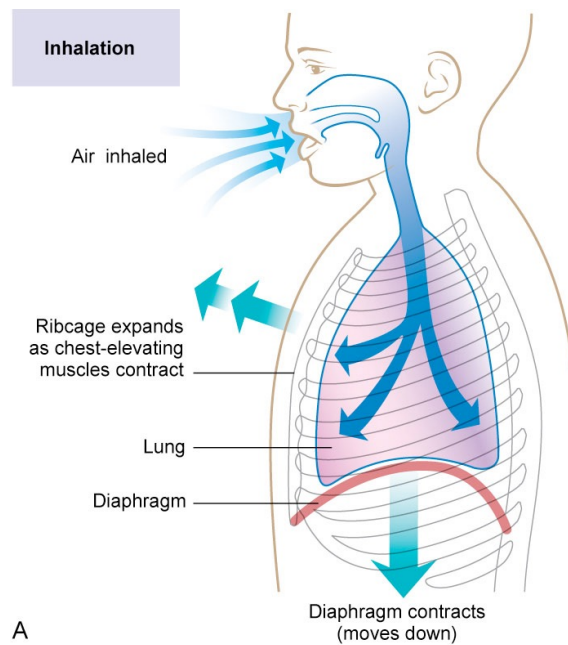
- Diaphragm



# Breathing

**Breathing** A mechanical action consisting of two phases:

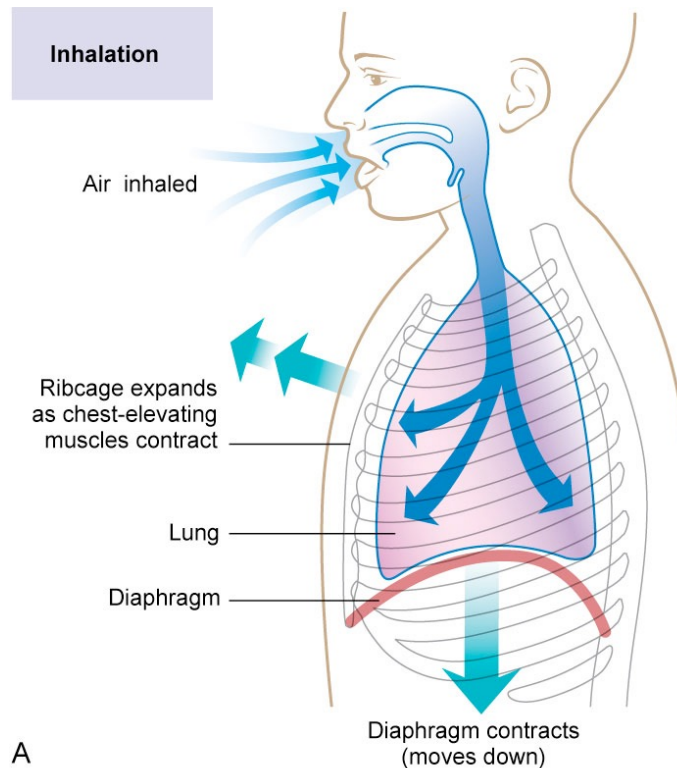
inhalation (inspiration) and exhalation (expiration). These phases are the result of nerve stimulation, muscle contraction, and differences between the pressure in the lungs and the atmospheric pressure outside the lungs. Adults breathe 12-16 times per minute.



# Breathing

**Inhalation (AKA: inspiration)** Process of drawing air into the lungs.

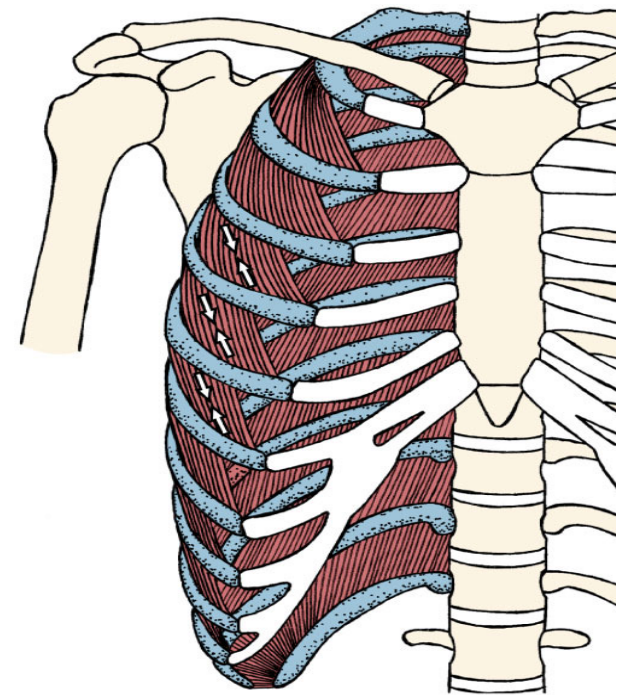
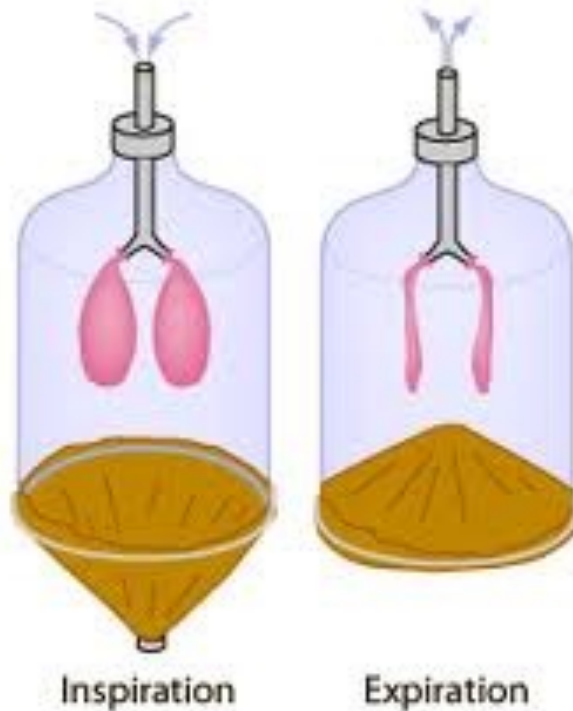1. Diaphragm contracts and moves down.
2. External intercostals contract to lift the ribcage up and out.
3. Pressure in the lungs is now lower compared to atmospheric pressure.
4. Air moves from higher pressure (atmosphere) to lower pressure (lungs).



# Breathing

**Inhalation (AKA: inspiration)** Process of drawing air into the lungs.

1. Diaphragm contracts and moves down.
2. External intercostals contract to lift the ribcage up and out.
3. Pressure in the lungs is now lower compared to atmospheric pressure.
4. Air moves from higher pressure (atmosphere) to lower pressure (lungs).

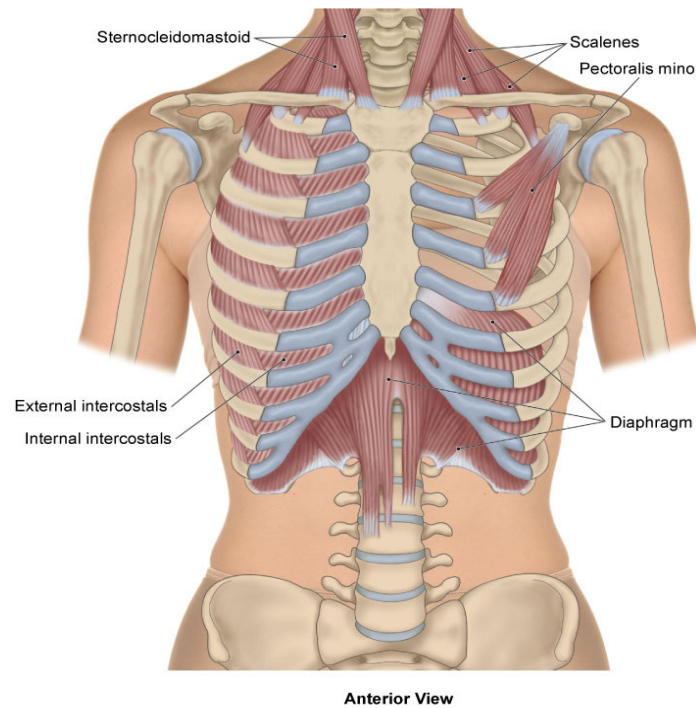


Anterior View



# Breathing

**Forced inhalation** Intensified and voluntary inhalation that requires contraction of \_\_\_\_\_ accessory \_\_\_\_\_ muscles of inhalation (sternocleidomastoid, scalenes, and pectoralis minor).

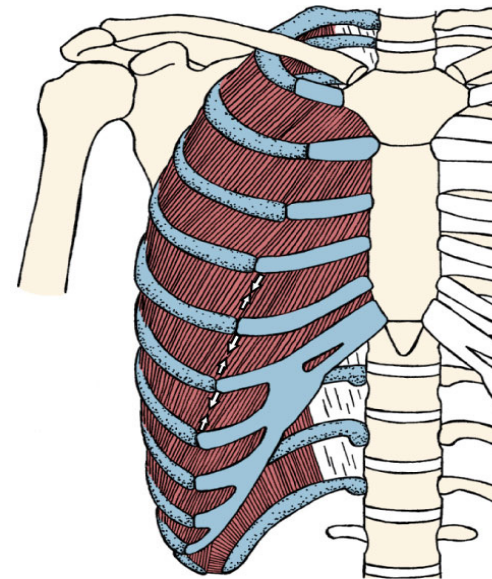
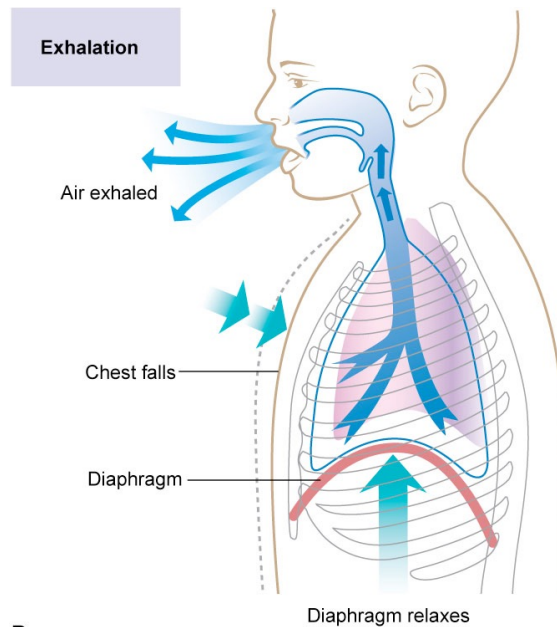




# Breathing

**Exhalation (AKA: expiration)** Process of expelling air from the lungs.

1. Diaphragm relaxes; elastic recoil of stretched tissues causes it to rise up.
2. External intercostals relax; elastic recoil of the stretched tissues causes the ribcage to move down and in.
3. Thoracic cavity and lungs are reduced in size as a result.
4. Pressure in the lungs is now higher compared to atmospheric pressure.
5. Air moves from higher pressure (lungs) to lower pressure (atmosphere).

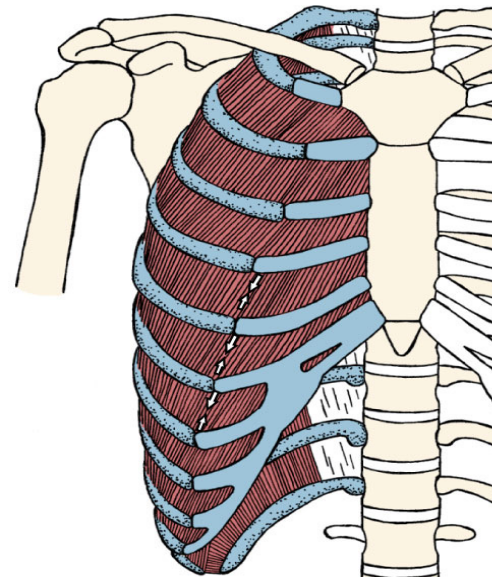
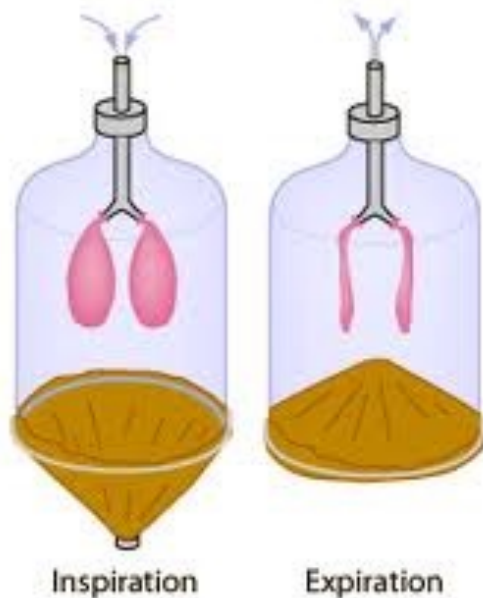

Anterior View

# Breathing

**Exhalation (AKA: expiration)** Process of expelling air from the lungs.

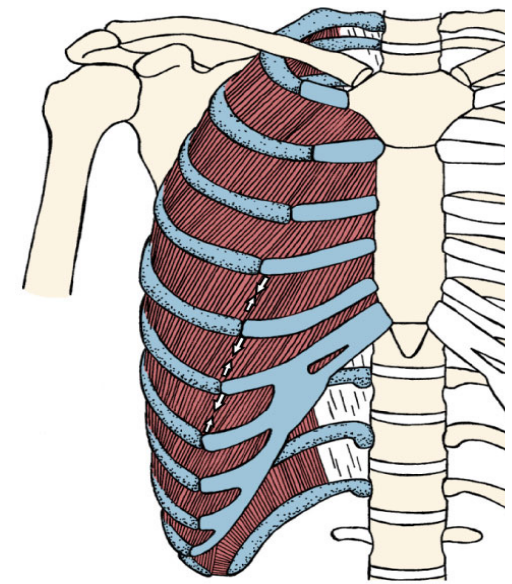
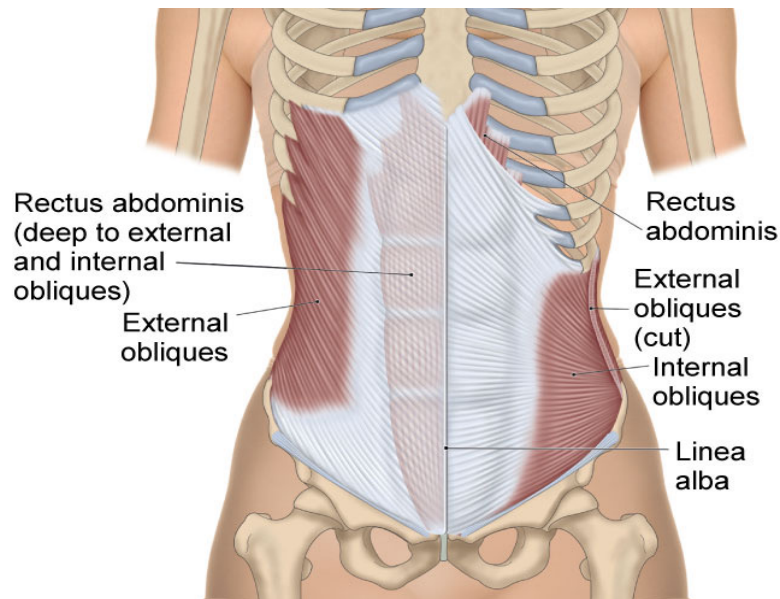
1. Diaphragm relaxes; elastic recoil of stretched tissues causes it to rise up.
2. External intercostals relax; elastic recoil of the stretched tissues causes the ribcage to move down and in.
3. Thoracic cavity and lungs are reduced in size as a result.
4. Pressure in the lungs is now higher compared to atmospheric pressure.
5. Air moves from higher pressure (lungs) to lower pressure (atmosphere).



Anterior View

# Breathing

**Forced exhalation** Intensified and voluntary exhalation that requires contraction of accessory muscles of exhalation (internal intercostals and abdominals).



Anterior View

# Breathing

**Volitional/voluntary breathing** Allows you to hold your breath while swimming under water and to take deep breaths to project your voice during public speaking.





# Response Moment

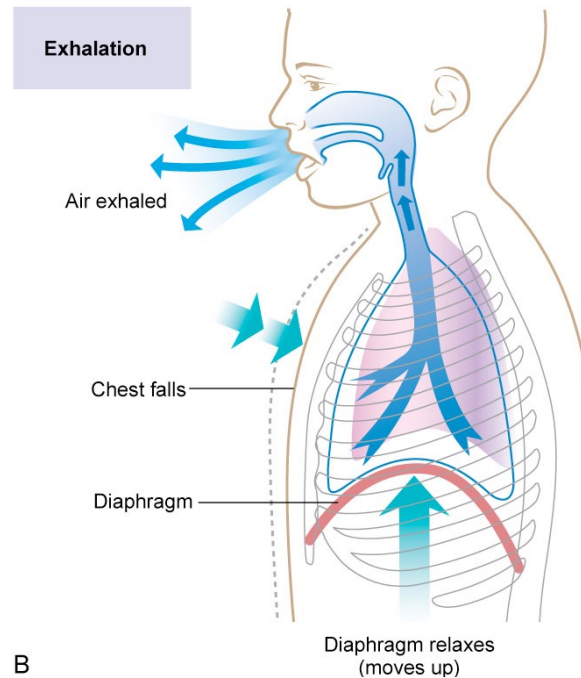
4 steps of inhalation?

- 1.
- 2.
- 3.
- 4.

# Response Moment

4 steps of inhalation?

1. Diaphragm contract and moves down
2. External intercostals contract to lift the ribcage up and out
3. Pressure in the lungs is now lower compared to atmospheric pressure
4. Air moves from higher pressure (atmosphere) to lower pressure (lungs)





# Response Moment

5 steps of exhalation?

1.

2.

3.

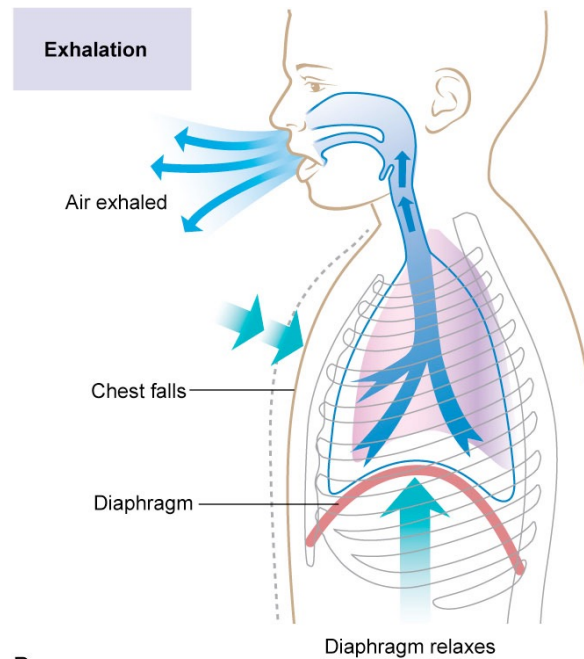
4.

5.

# Response Moment

5 steps of exhalation?

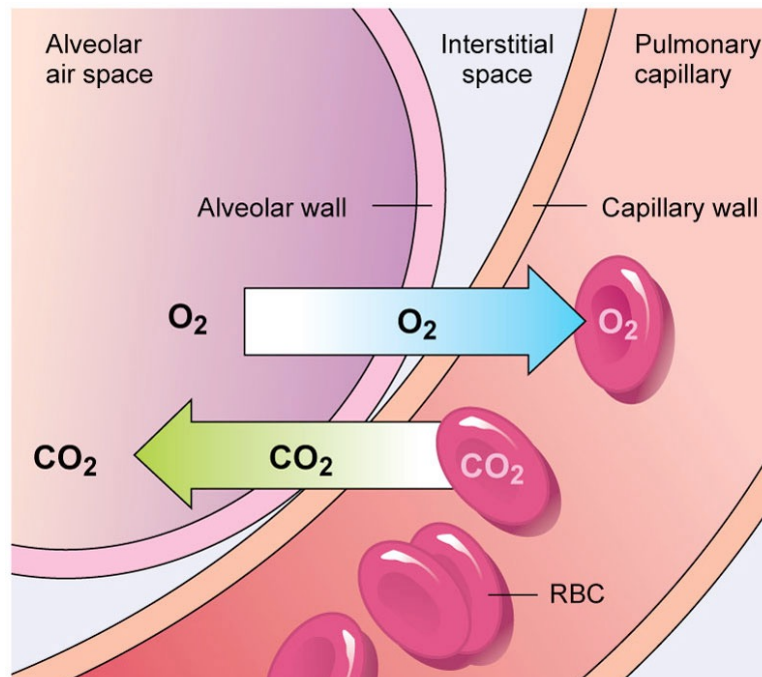
1. Diaphragm relaxes; elastic recoil of stretched tissues causes it to rise up
2. External intercostals relax; elastic recoil of the stretched tissues causes the ribcage to move down and in
3. Thoracic cavity and lungs are now reduced in size as a result
4. Pressure in the lungs is now higher compared to atmospheric pressure
5. Air moves from higher pressure (lungs) to lower pressure (atmosphere)





# External and Internal Respiration

**External respiration (AKA: pulmonary respiration)** Gas exchange in the lungs. Occurs by diffusion between blood in capillaries and air in the alveoli.





# External and Internal Respiration

**Internal respiration (AKA: tissue respiration)** Gas exchange between blood and the body tissues.



Response Moment

**Definition of respiration?**

**Site of external respiration?**

**Site of internal respiration?**



# Response Moment

## **Definition of respiration?**

- Gas exchange

## **Site of external respiration?**

- Lungs

## **Site of internal respiration?**

- Tissues



## 61a A&P: Respiratory System