




35a Cardiovascular System: Blood Cells, Tissues, and the Heart




Do you know what you must do to be ready to go into clinic after class 56?

Are you making up your absences?

Are you taking makeup tests and turning in missed assignments so you are passing in all subjects?

Not sure? – Check your student portal or email Tila about to verify your status!


tilat@tlcschool.com



35a Cardiovascular System: Blood Cells, Tissues, and the Heart

Class Outline

5 minutes	Attendance, Breath of Arrival, and Reminders
10 minutes	Lecture:
25 minutes	Lecture:
15 minutes	Active study skills:
60 minutes	Total



35a Cardiovascular System: Blood Cells, Tissues, and the Heart

Class Reminders

In Class 35b:

- Full SOAP notes with date and first and last names. Signatures and date on intake form

Assignments:

- 36a State Law Review Questions (Packet A: 167-172)
- 41a Review Questions (Packet A: 173-185)
- 43a Swedish: Outside Massages (Packet A: 57-62)

Quizzes:

- 43a Kinesiology Quiz
 - (adductor magnus, gracilis, iliopsoas, sartorius, TFL, piriformis, quadratus femoris)
- 44a Quiz (33b, 35a, 36a, 37a/b, 38a, 39a, 40a, 41a/b, 42b, and 43a)

Preparation for upcoming classes:

- 36a A&P: Cardiovascular System - Blood Vessels and Paths of Circulation
 - Trail Guide: iliopsoas
 - Packet E: 69-72
 - RQ Packet A-168
- 36b Business: Professional Ethics



Classroom Rules

Punctuality - everybody's time is precious

- Be ready to learn at the start of class; we'll have you out of here on time
- Tardiness: arriving late, returning late after breaks, leaving during class, leaving early

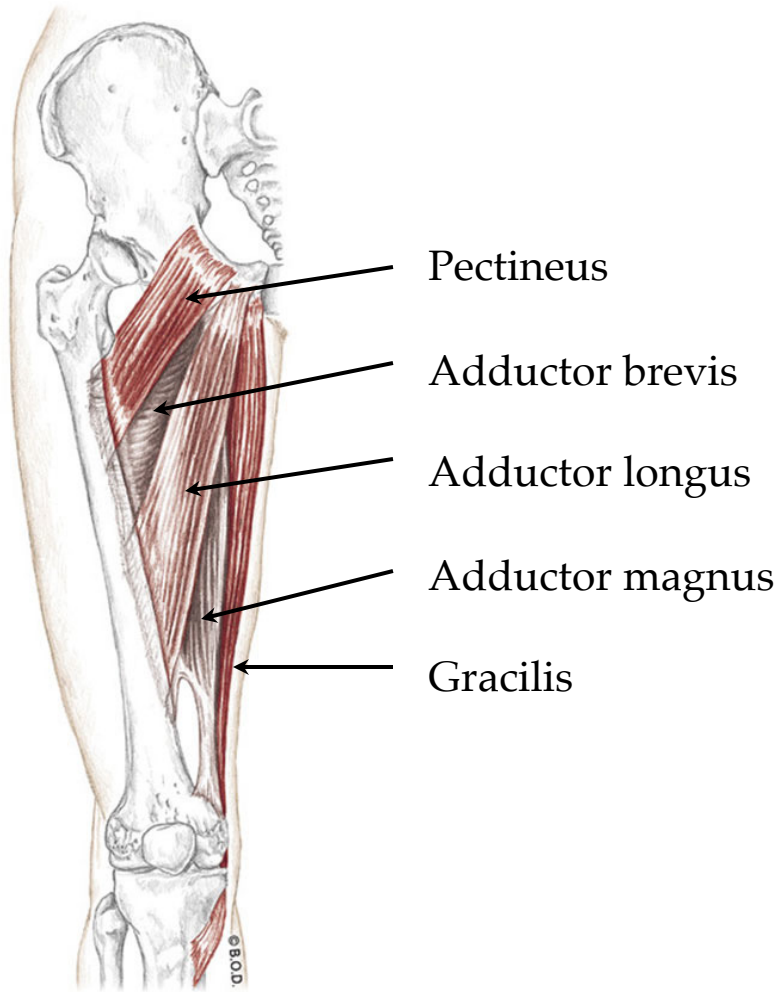
The following are not allowed:

- Bare feet
- Side talking
- Lying down
- Inappropriate clothing
- Food or drink except water
- Phones that are visible in the classroom, bathrooms, or internship

You will receive one verbal warning, then you'll have to leave the room.

Adductor Group

Trail Guide, Page 319

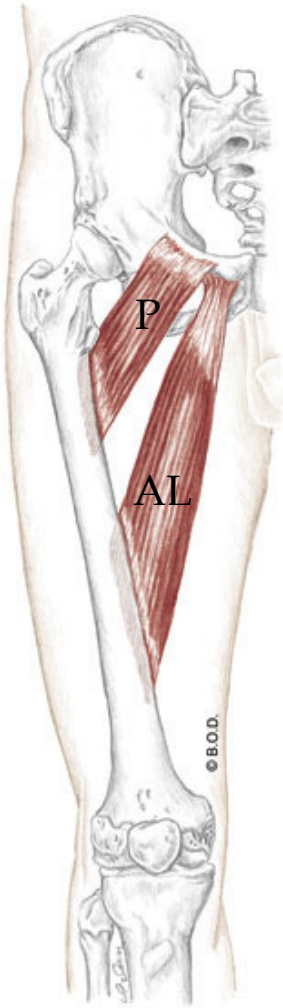


The five adductors are located along the medial thigh between the hamstrings and quadriceps.

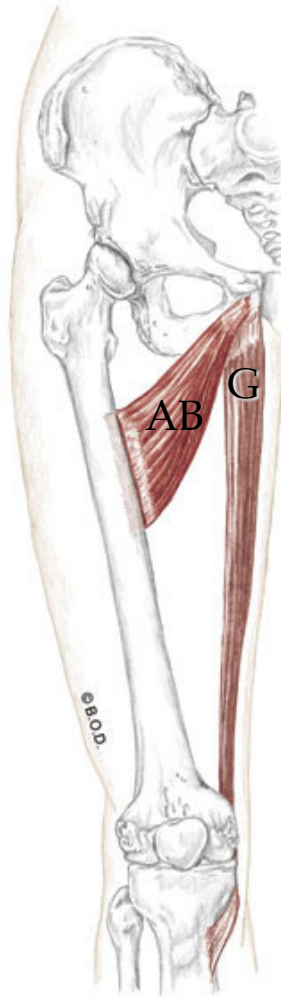
Anterior View

Adductor Group

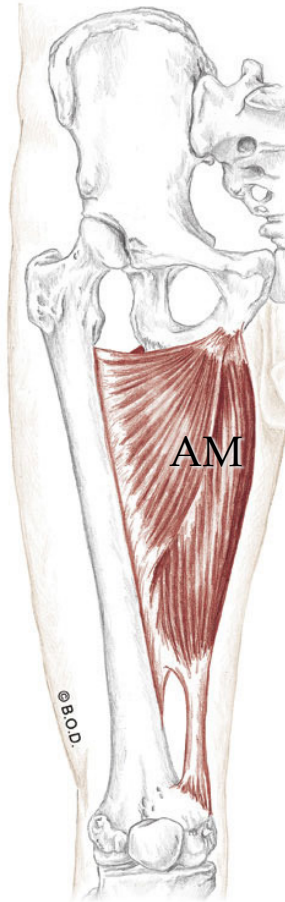
pectineus, adductor brevis, adductor longus, adductor magnus, gracilis
Trail Guide, Page 320



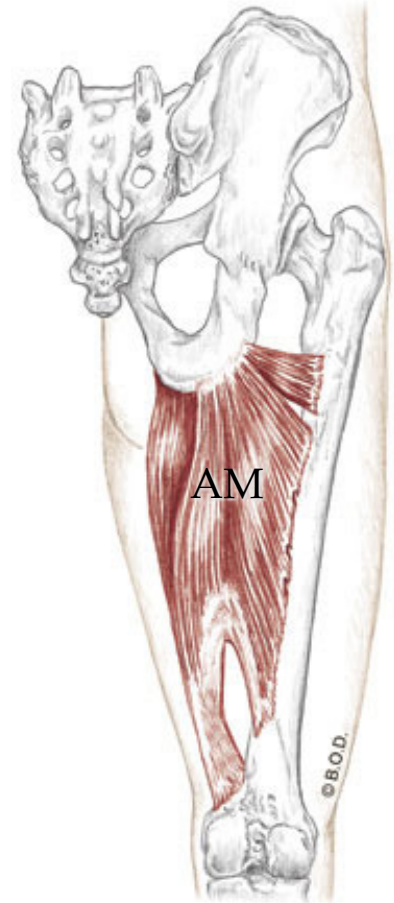
Anterior View



Anterior View



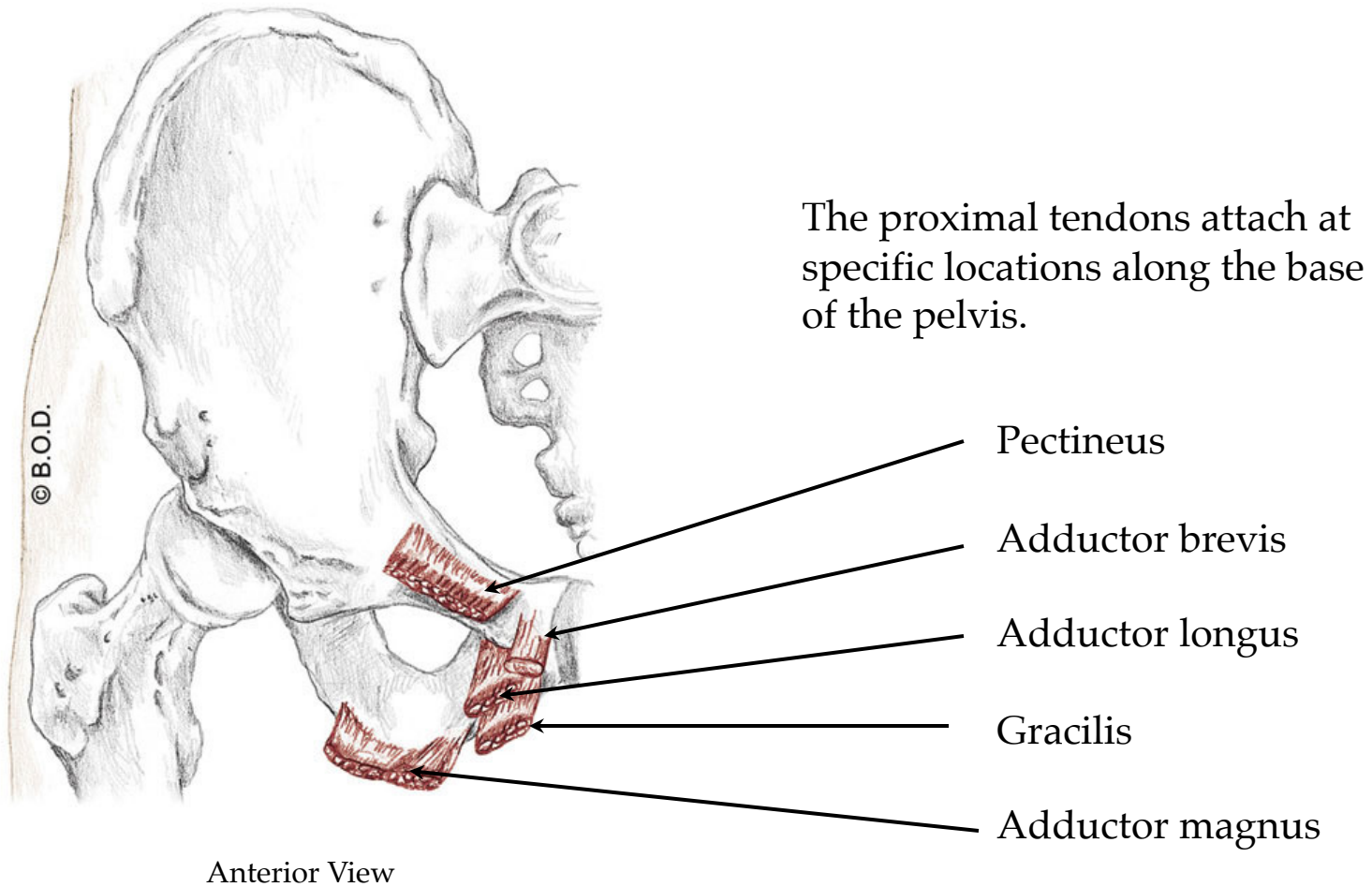
Anterior View



Posterior View

Adductor Group

Trail Guide, Page 321



Adductor Magnus, page 320 *This information is slightly different than what is in the Trail Guide.*

A All fibers:

Adduct the hip (coxal joint)

Anterior Fibers:

Assist to **flex** the hip (coxal joint)

Assist to **medially rotate** the hip (coxal joint)

Posterior fibers:

Extend the hip (coxal joint) from flexed position

Assist to **laterally rotate** the hip (coxal joint)

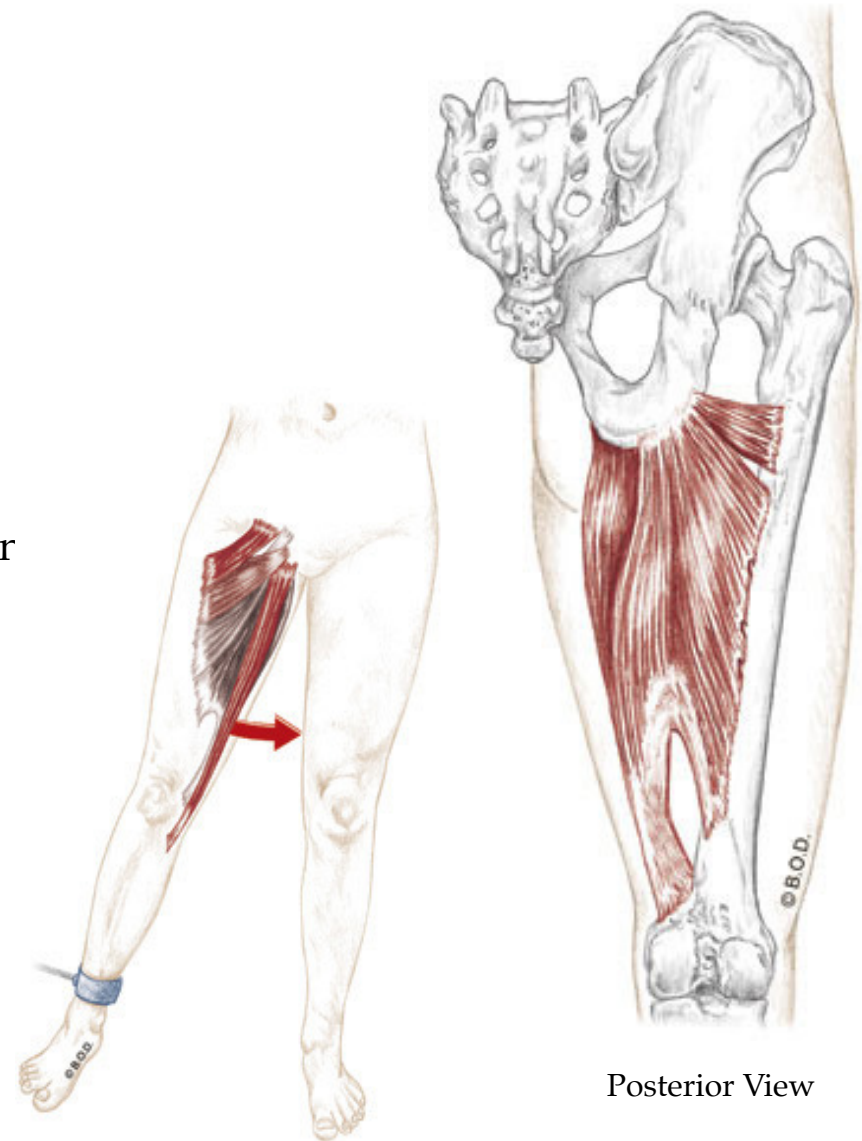
O Inferior ramus of the pubis

Ramus of the ischium

Ischial Tuberosity

I Medial lip of linea aspera

Adductor tubercle



Anterior View

Posterior View

Adductor Magnus, page 320 *This information is slightly different than what is in the Trail Guide.*

A All fibers:

Adduct the hip (coxal joint)

Anterior Fibers:

Assist to **flex** the hip (coxal joint)

Assist to **medially rotate** the hip (coxal joint)

Posterior fibers:

Extend the hip (coxal joint) from flexed position

Assist to **laterally rotate** the hip (coxal joint)

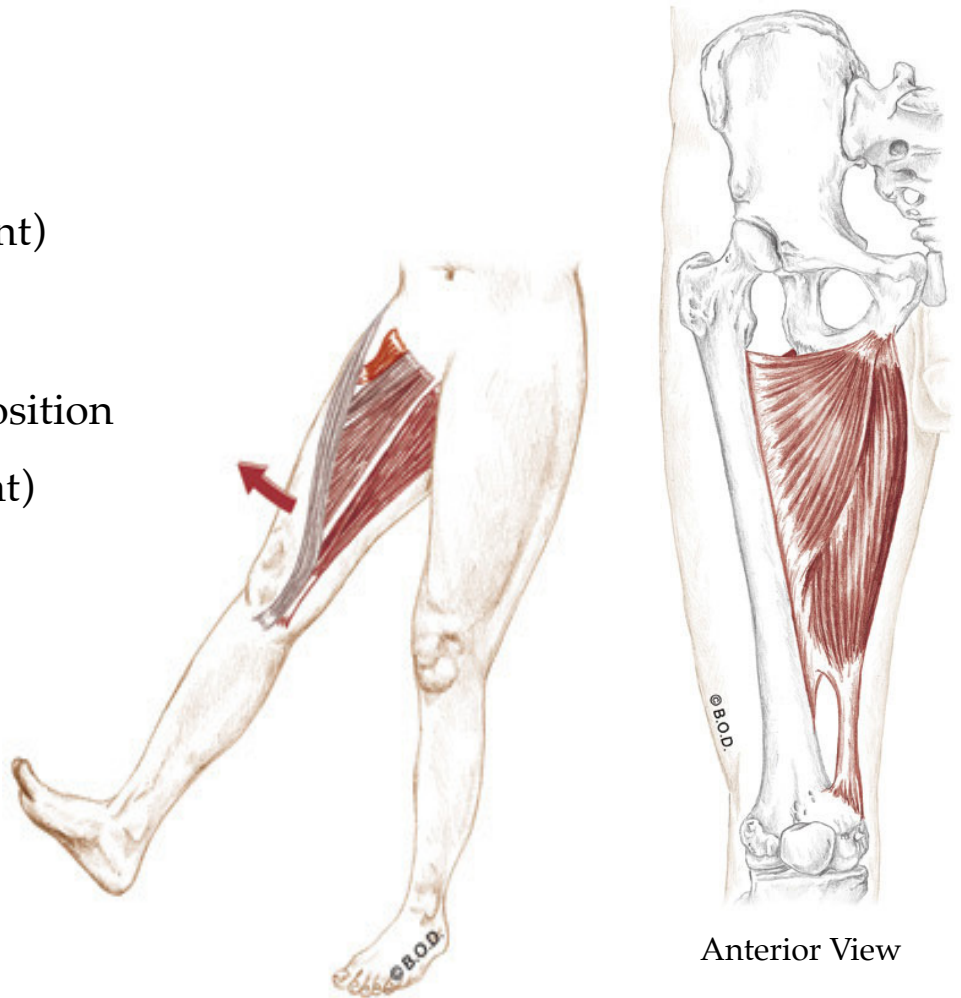
O Inferior ramus of the pubis

Ramus of the ischium

Ischial Tuberosity

I Medial lip of linea aspera

Adductor tubercle



Anterior View

Adductor Magnus, page 320 *This information is slightly different than what is in the Trail Guide.*

A All fibers:

Adduct the hip (coxal joint)

Anterior Fibers:

Assist to **flex** the hip (coxal joint)

Assist to **medially rotate** the hip (coxal joint)

Posterior fibers:

Extend the hip (coxal joint) from flexed position

Assist to **laterally rotate** the hip (coxal joint)

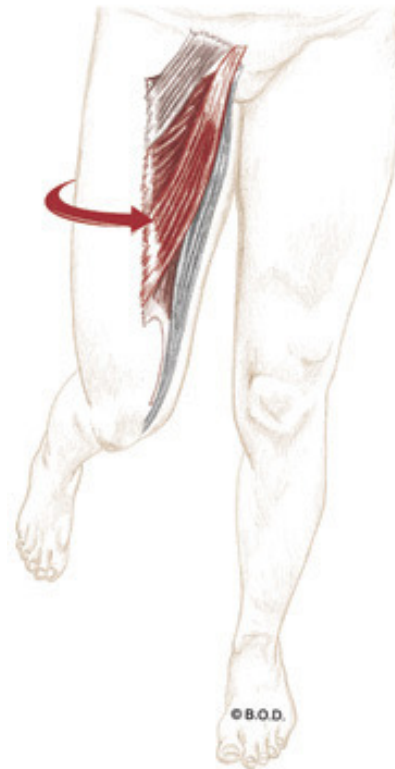
O Inferior ramus of the pubis

Ramus of the ischium

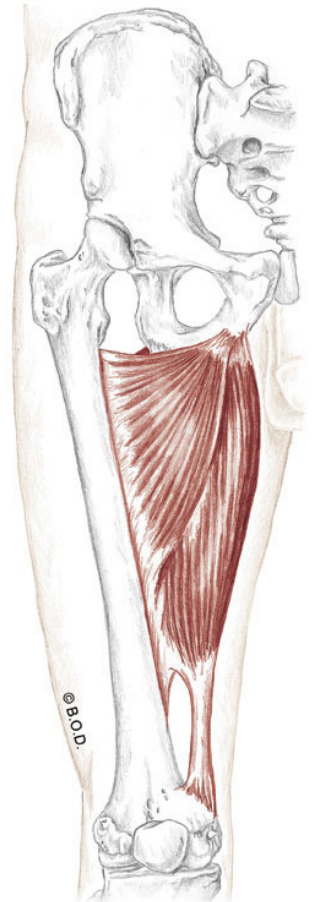
Ischial Tuberosity

I Medial lip of linea aspera

Adductor tubercle



Anterior View



Anterior View

Adductor Magnus, page 320 *This information is slightly different than what is in the Trail Guide.*

A All fibers:

Adduct the hip (coxal joint)

Anterior Fibers:

Assist to **flex** the hip (coxal joint)

Assist to **medially rotate** the hip (coxal joint)

Posterior fibers:

Extend the hip (coxal joint) from flexed position

Assist to **laterally rotate** the hip (coxal joint)

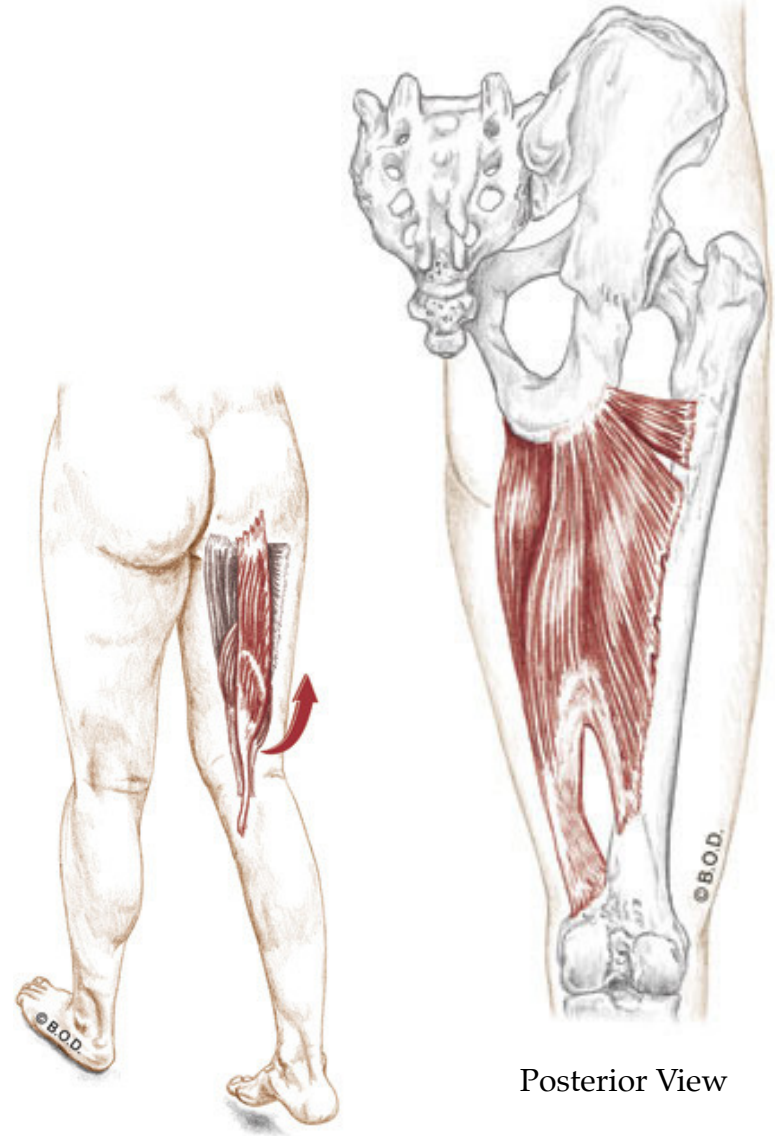
O Inferior ramus of the pubis

Ramus of the ischium

Ischial Tuberosity

I Medial lip of linea aspera

Adductor tubercle



Posterior View

Posterior View

Adductor Magnus, page 320 *This information is slightly different than what is in the Trail Guide.*

A All fibers:

Adduct the hip (coxal joint)

Anterior Fibers:

Assist to **flex** the hip (coxal joint)

Assist to **medially rotate** the hip (coxal joint)

Posterior fibers:

Extend the hip (coxal joint) from flexed position

Assist to **laterally rotate** the hip (coxal joint)

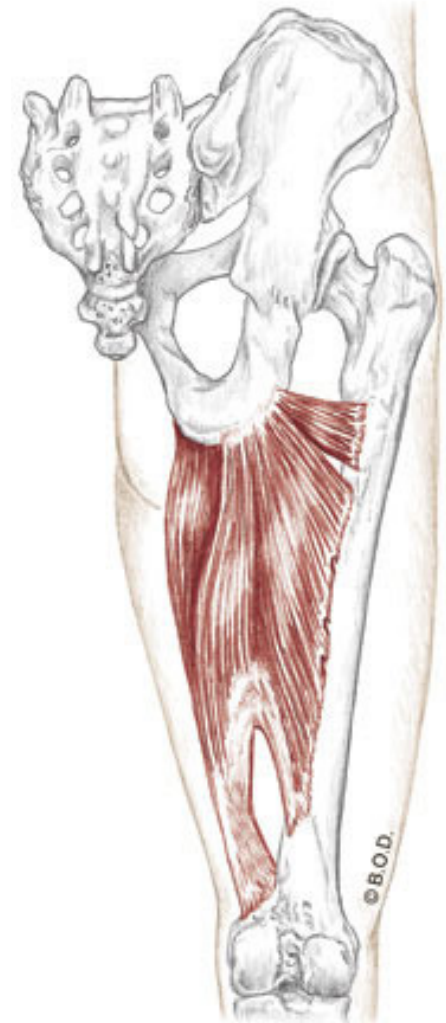
O Inferior ramus of the pubis

Ramus of the ischium

Ischial Tuberosity

I Medial lip of linea aspera

Adductor tubercle



Posterior View

Posterior View

Adductor Magnus, page 320 *This information is slightly different than what is in the Trail Guide.*

A All fibers:

Adduct the hip (coxal joint)

Anterior Fibers:

Assist to **flex** the hip (coxal joint)

Assist to **medially rotate** the hip (coxal joint)

Posterior fibers:

Extend the hip (coxal joint) from flexed position

Assist to **laterally rotate** the hip (coxal joint)

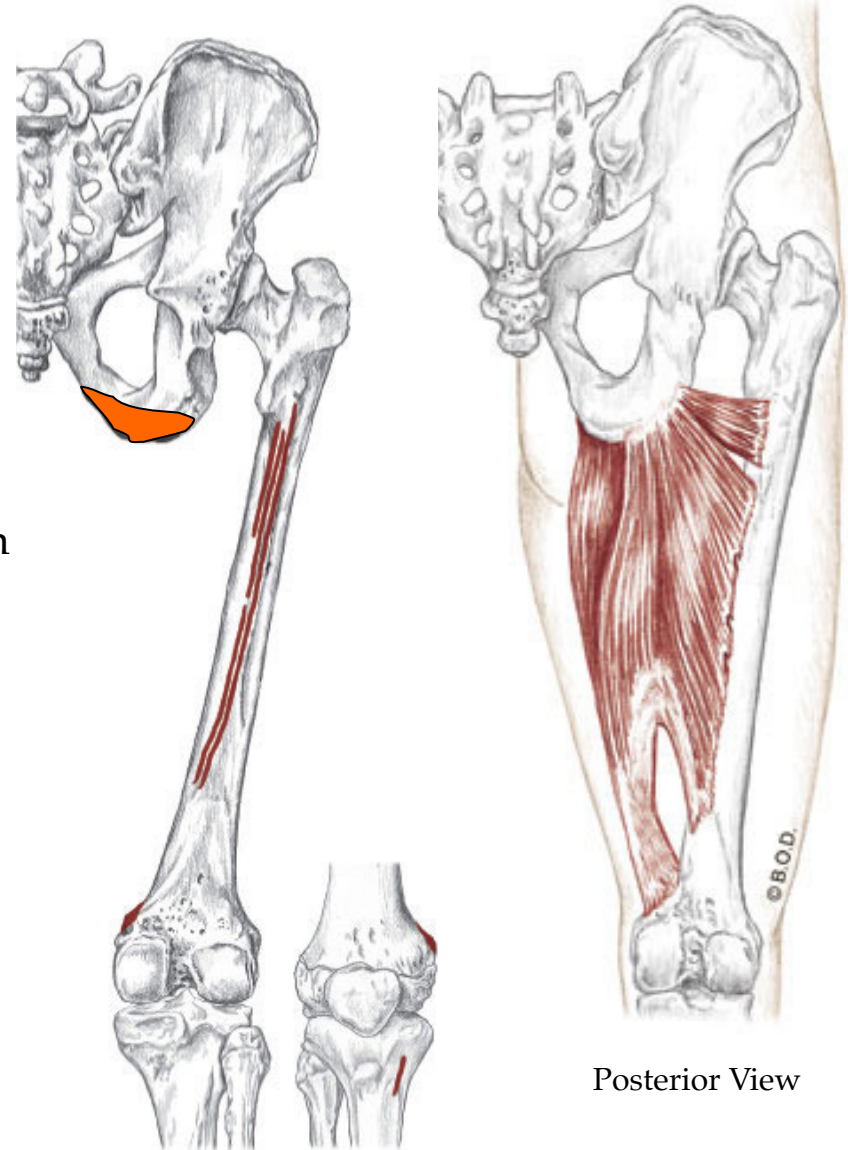
O Inferior ramus of the pubis

Ramus of the ischium

Ischial Tuberosity

I Medial lip of linea aspera

Adductor tubercle



Posterior View

Posterior View

Adductor Magnus, page 320 *This information is slightly different than what is in the Trail Guide.*

A All fibers:

Adduct the hip (coxal joint)

Anterior Fibers:

Assist to **flex** the hip (coxal joint)

Assist to **medially rotate** the hip (coxal joint)

Posterior fibers:

Extend the hip (coxal joint) from flexed position

Assist to **laterally rotate** the hip (coxal joint)

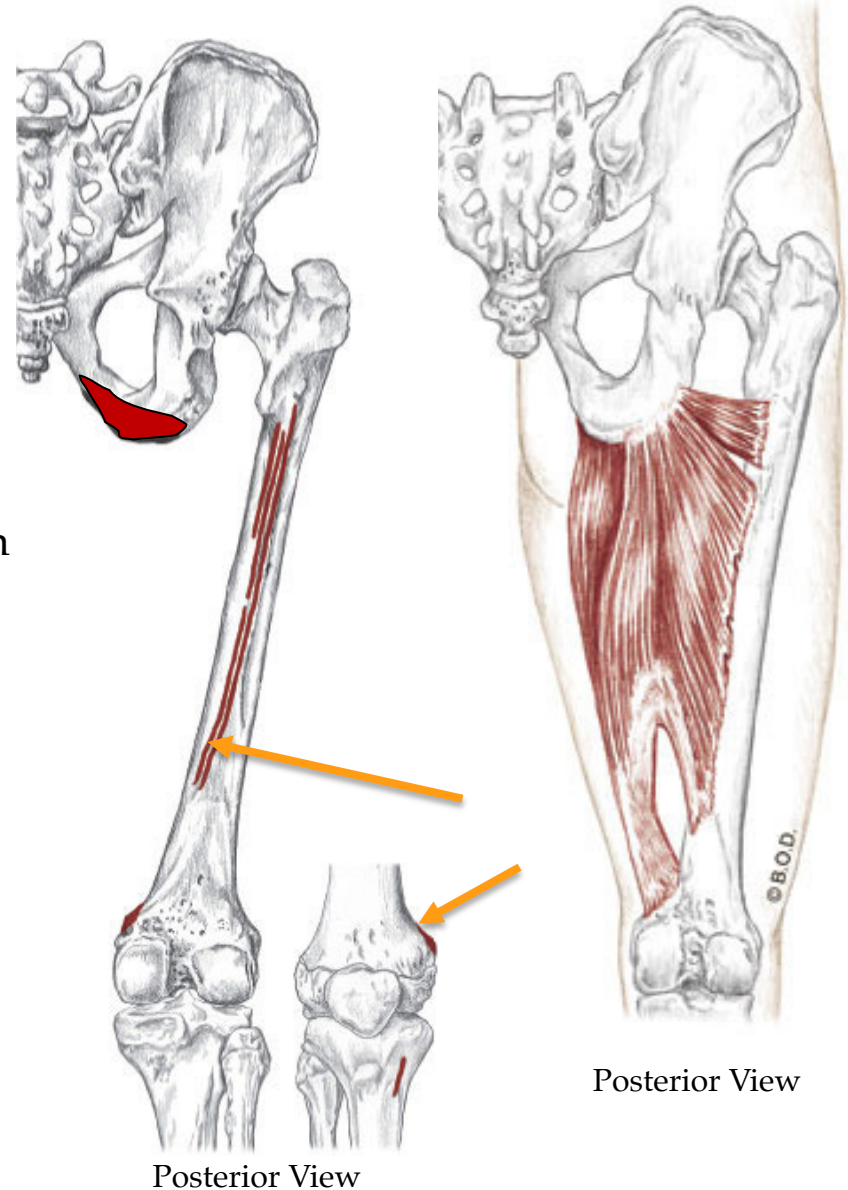
O Inferior ramus of the pubis

Ramus of the ischium

Ischial Tuberosity

I Medial lip of linea aspera

Adductor tubercle



Posterior View

Posterior View

Time to shift gears



From adductor magnus to gracilis . . .

A All fibers:

Adduct the hip (coxal joint)

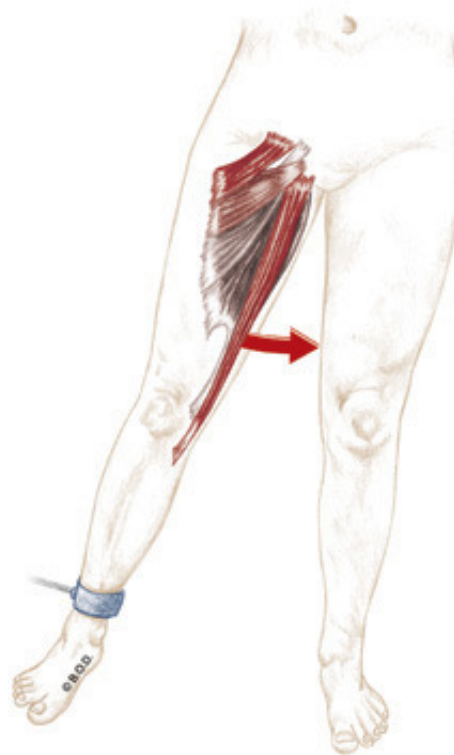
Assist to **flex** the hip (coxal joint)

Flex the knee (tibiofemoral joint)

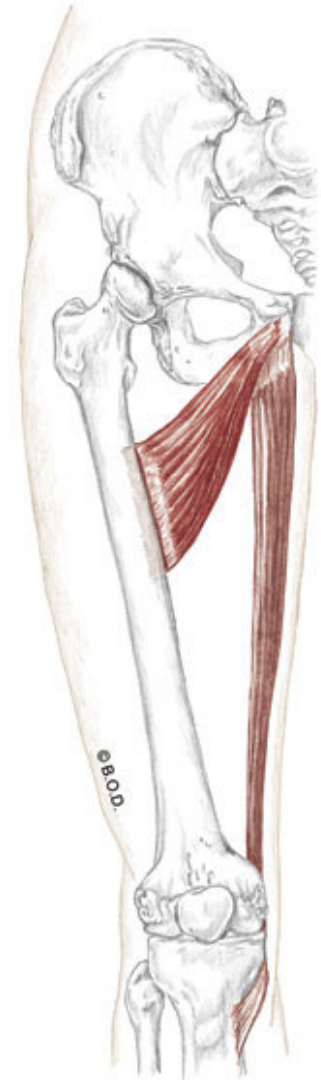
Medially rotate the flexed knee (tibiofemoral joint)

O Inferior ramus of the pubis

I Proximal, medial shaft of tibia
at pes anserinus tendon



Anterior View



Anterior View

Gracilis, page 321

A All fibers:

Adduct the hip (coxal joint)

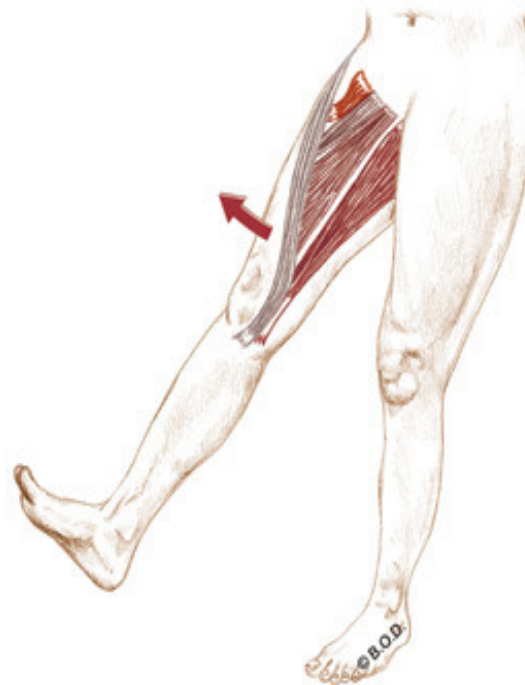Assist to **flex** the hip (coxal joint)

Flex the knee (tibiofemoral joint)

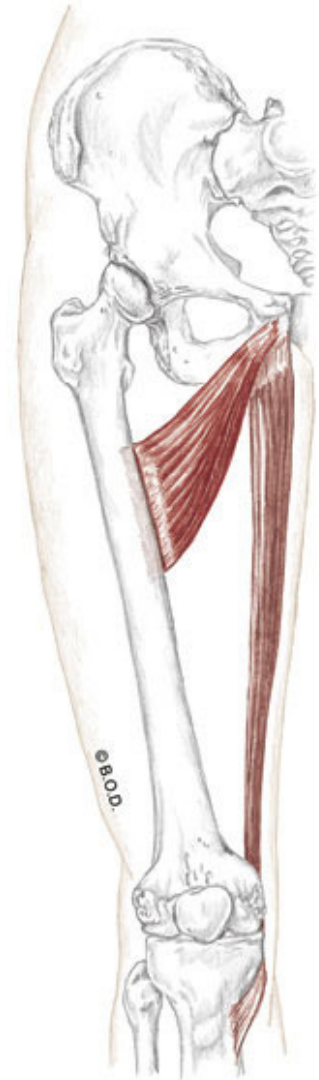
Medially rotate the flexed knee (tibiofemoral joint)

O Inferior ramus of the pubis

I Proximal, medial shaft of tibia
at pes anserinus tendon



Anterior View



Anterior View

Gracilis, page 321

A All fibers:

Adduct the hip (coxal joint)

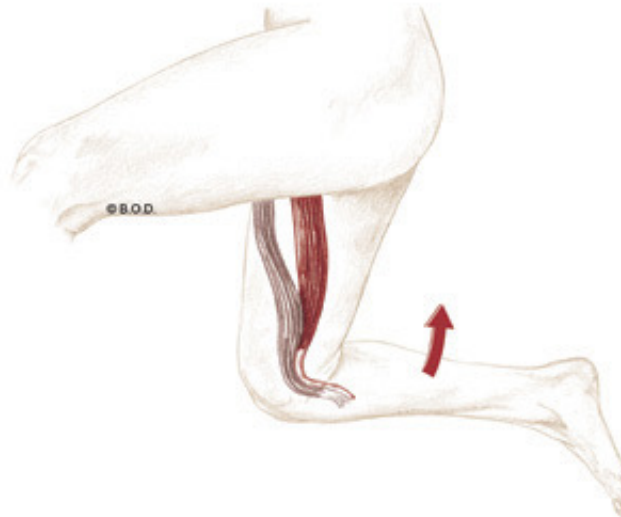
Assist to **flex** the hip (coxal joint)

Flex the knee (tibiofemoral joint)

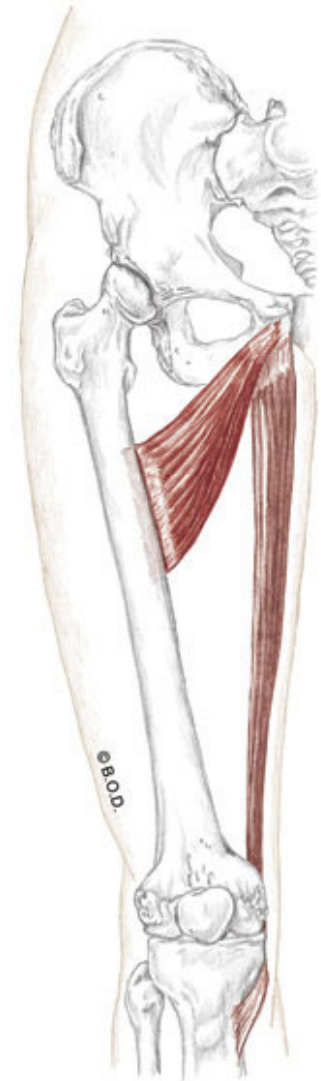
Medially rotate the flexed knee (tibiofemoral joint)

O Inferior ramus of the pubis

I Proximal, medial shaft of tibia
at pes anserinus tendon



Lateral View



Anterior View

Gracilis, page 321

A All fibers:

Adduct the hip (coxal joint)

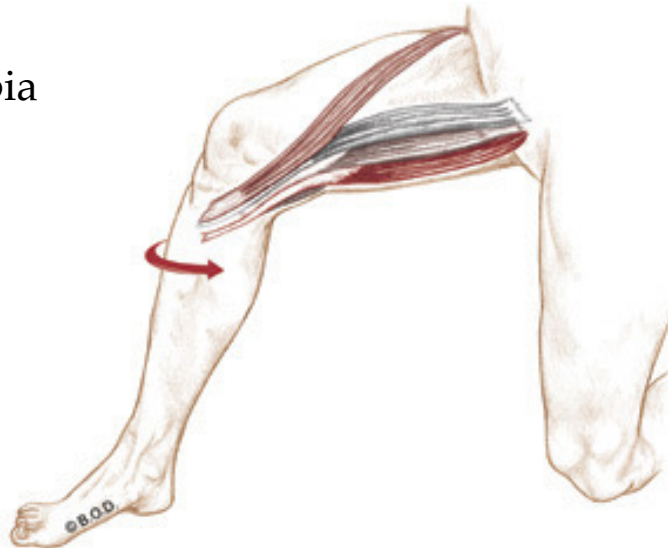
Assist to **flex** the hip (coxal joint)

Flex the knee (tibiofemoral joint)

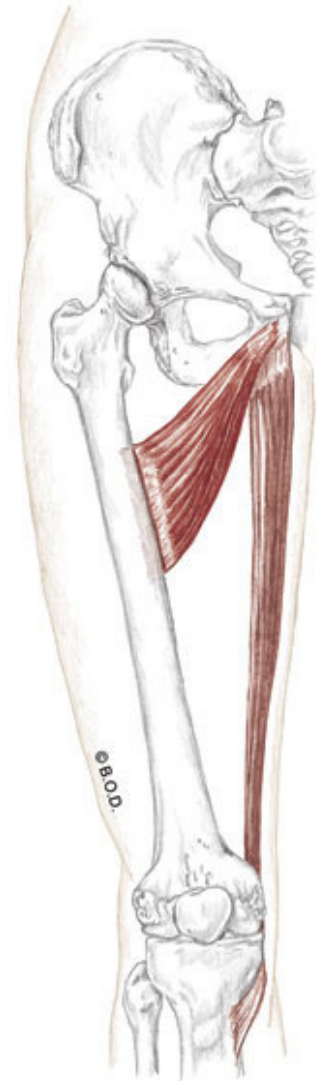
Medially rotate the flexed knee (tibiofemoral joint)

O Inferior ramus of the pubis

I Proximal, medial shaft of tibia
at pes anserinus tendon



Anterolateral View



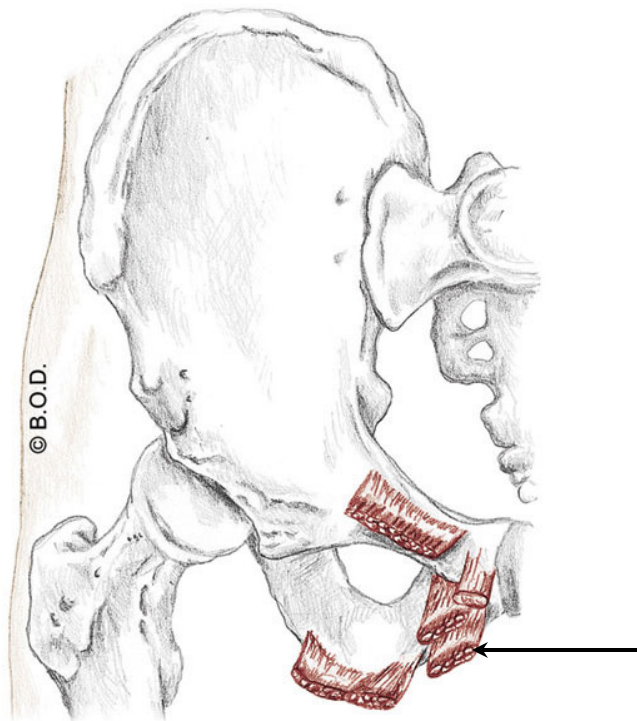
Anterior View

Gracilis, page 321

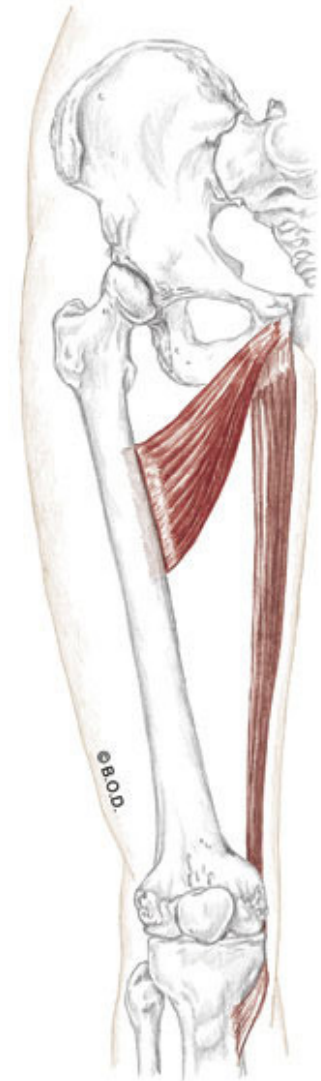
- A** All fibers:
- Adduct** the hip (coxal joint)
 - Assist to **flex** the hip (coxal joint)
 - Flex** the knee (tibiofemoral joint)
 - Medially rotate** the flexed knee (tibiofemoral joint)

O Inferior ramus of the pubis

I Proximal, medial shaft of tibia
at pes anserinus tendon



Anterior View



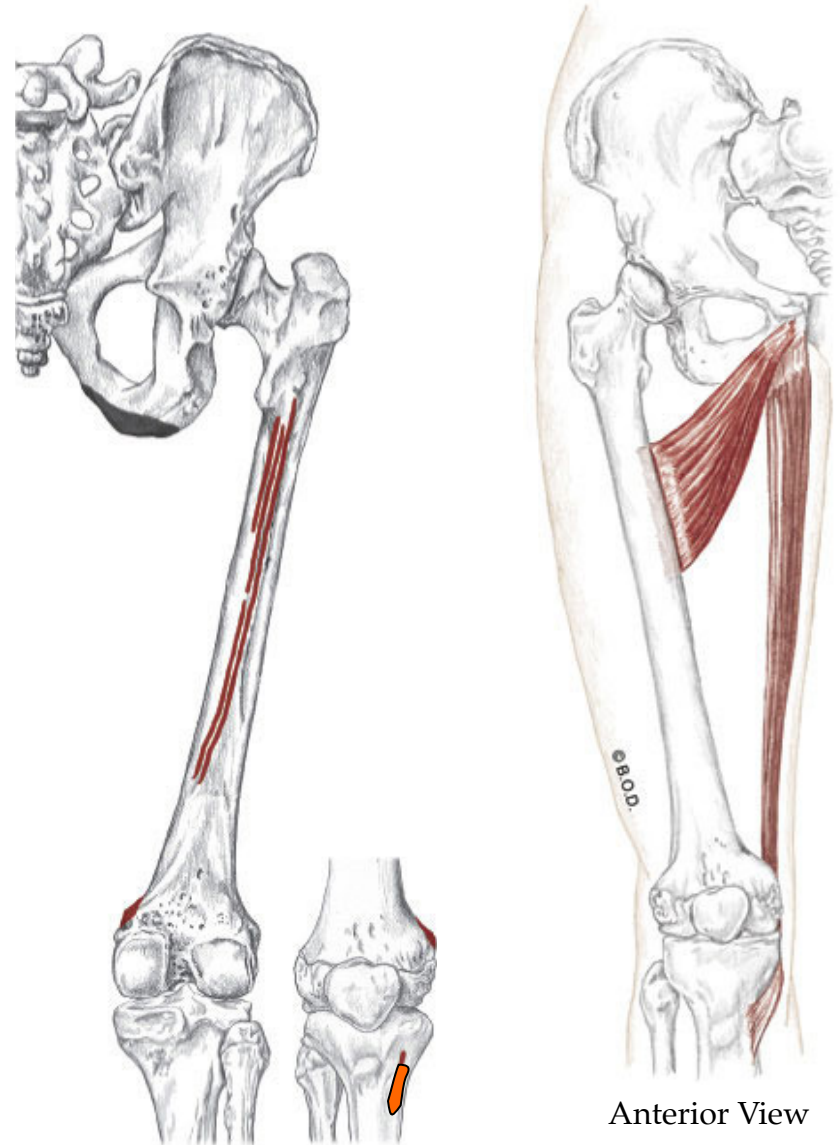
Anterior View

Gracilis, page 321

- A** All fibers:
- Adduct** the hip (coxal joint)
 - Assist to **flex** the hip (coxal joint)
 - Flex** the knee (tibiofemoral joint)
 - Medially rotate** the flexed knee (tibiofemoral joint)

O Inferior ramus of the pubis

I Proximal, medial shaft of tibia
at pes anserinus tendon



Posterior View

Anterior View

SGT- Same actions at the knee and same insertion

Sartorius (hacky-sack muscle!)

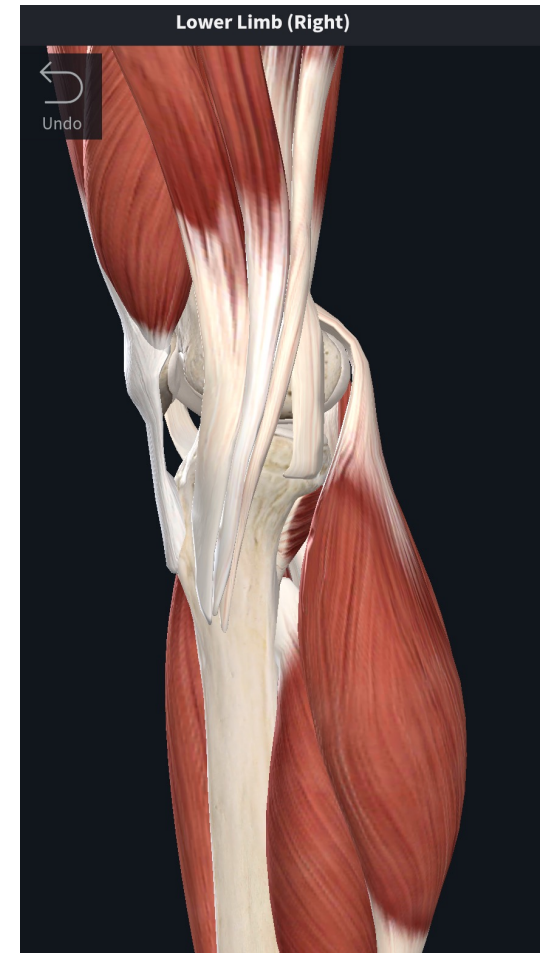Gracilis (adductor)

semiTendinosis (medial hamstring)

A: **Flex** the knee (tibiofemoral joint)

Medially rotate the knee (tibiofemoral joint)

I: Proximal, medial shaft of tibia
at pes anserinus tendon (pictured)





35a Cardiovascular System - Blood Cells, Tissues, and the Heart

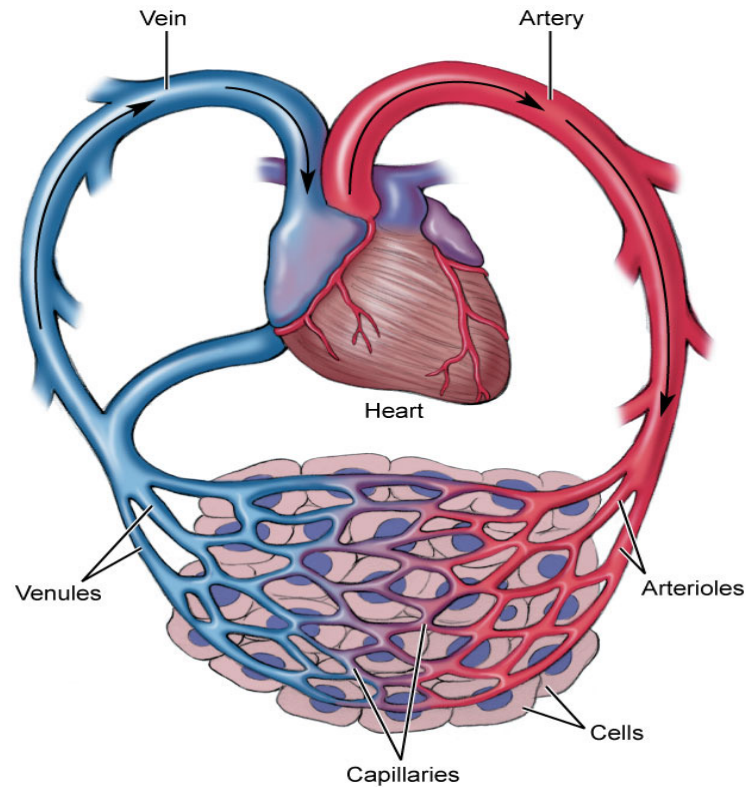
E - 65

Anatomy

Blood

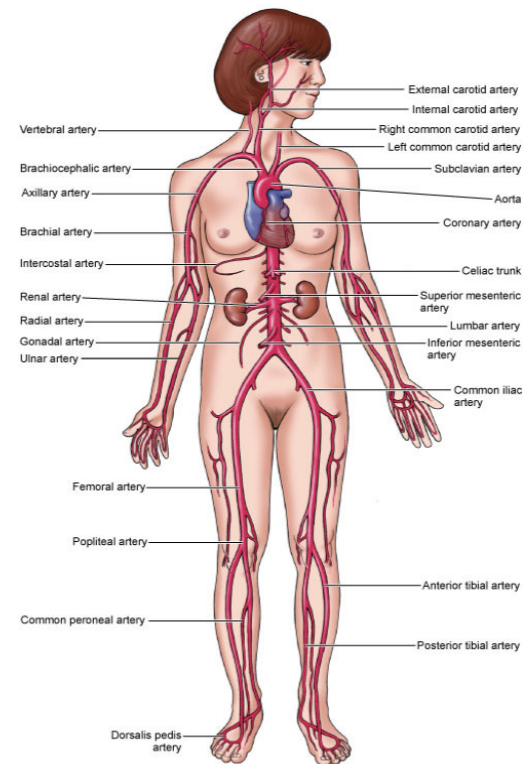
Blood vessels such as arteries, veins, and capillaries

Heart



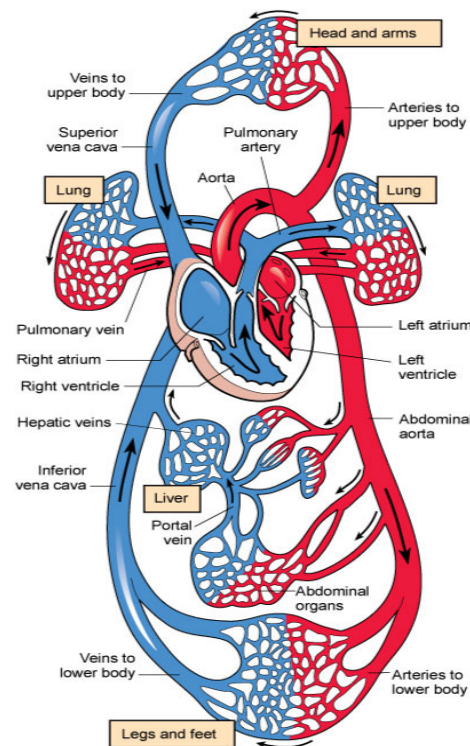
Physiology

Transportation
Protection
Combat hemorrhage



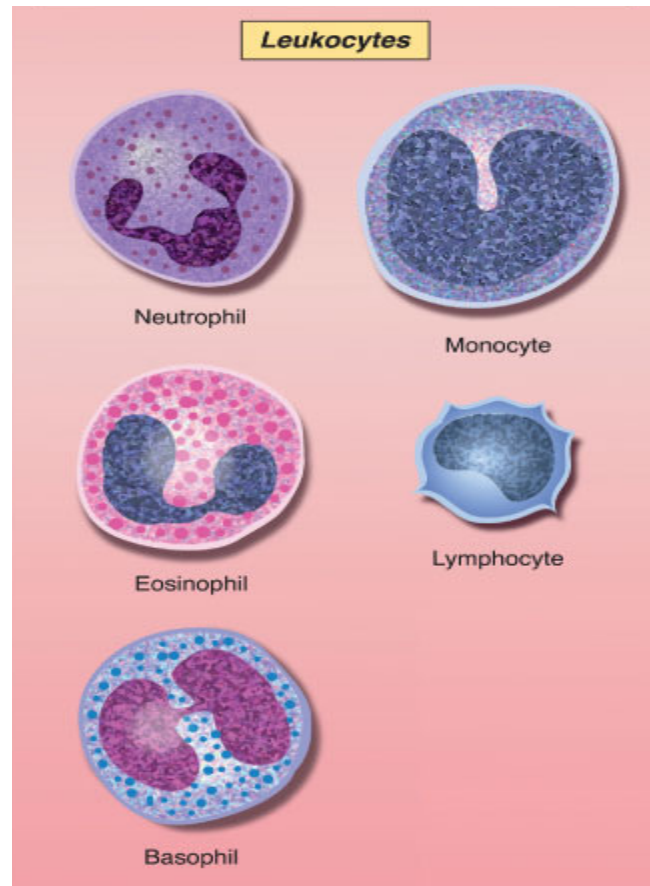
Physiology

Transportation The process of transporting respiratory gases, nutrients from the digestive tract, antibodies, waste materials, and hormones from the endocrine glands, heat from active muscles to the skin.



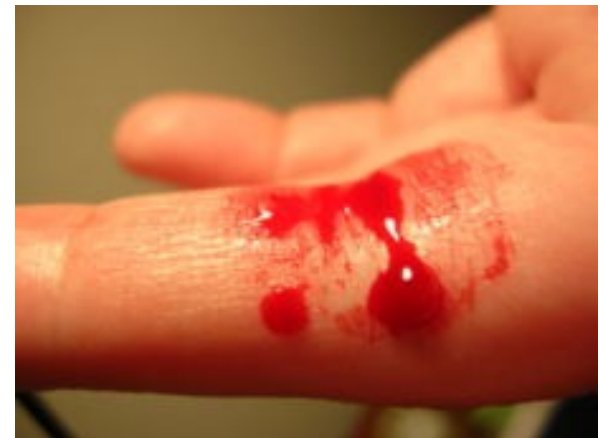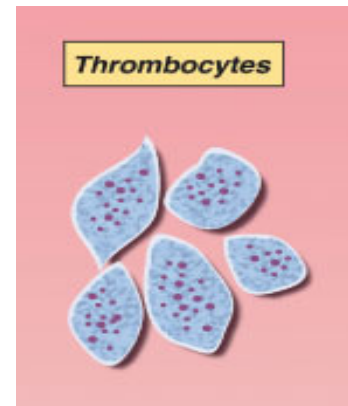
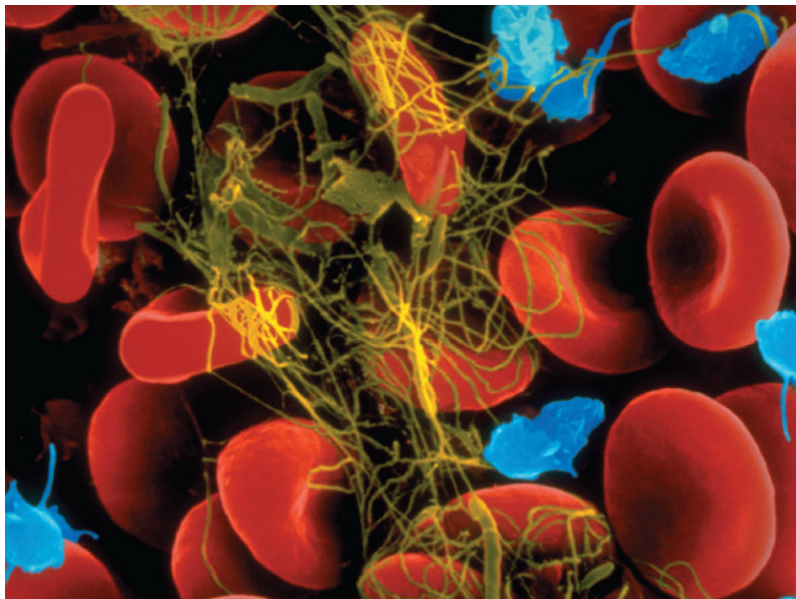
Physiology

Protection The process of protecting the body through disease-fighting white blood cells and the removal of impurities and pathogens.



Physiology

Combat hemorrhage The process of preventing the loss of body fluids from damaged vessels through clotting mechanisms.





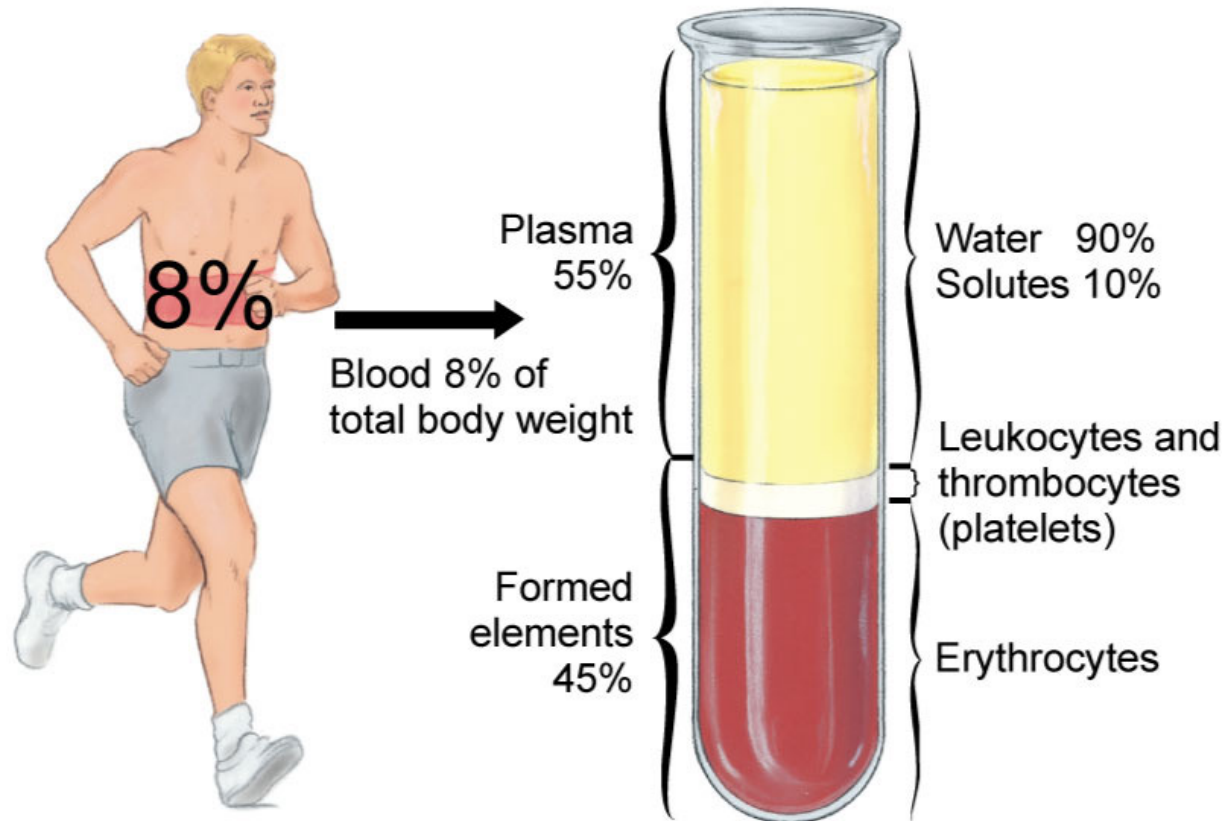
Blood

Formed elements (blood cells)

Plasma (liquid portion)

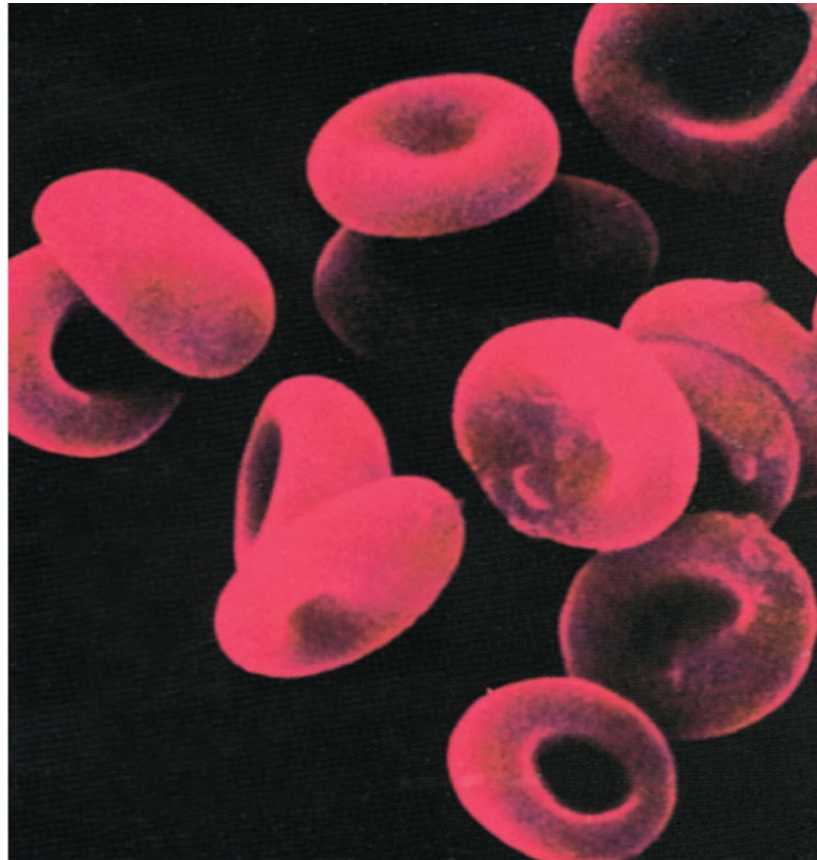
Blood

Blood Liquid connective tissue composed of plasma, erythrocytes, leukocytes, and thrombocytes.



Blood (formed elements)

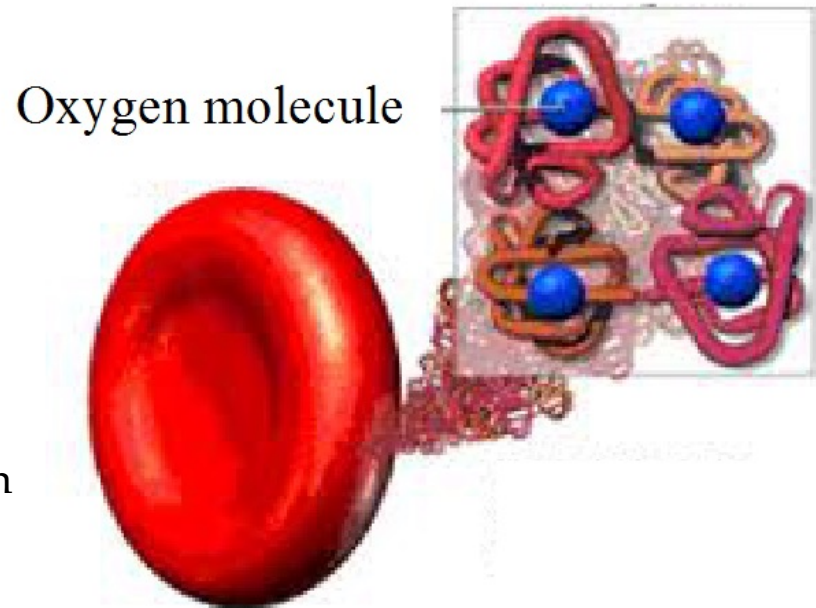
Erythrocyte Red blood cell. Transports oxygen and carbon dioxide.



Blood (formed elements)

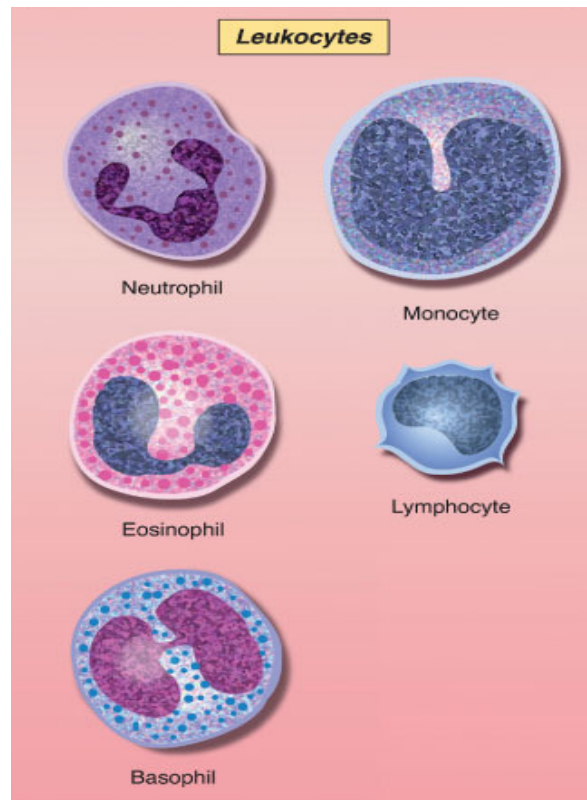
Hemoglobin

- Iron-based protein
- Gives blood its color
- Allows gases to combine with it temporarily so that oxygen or carbon dioxide can be transported and released throughout the body.



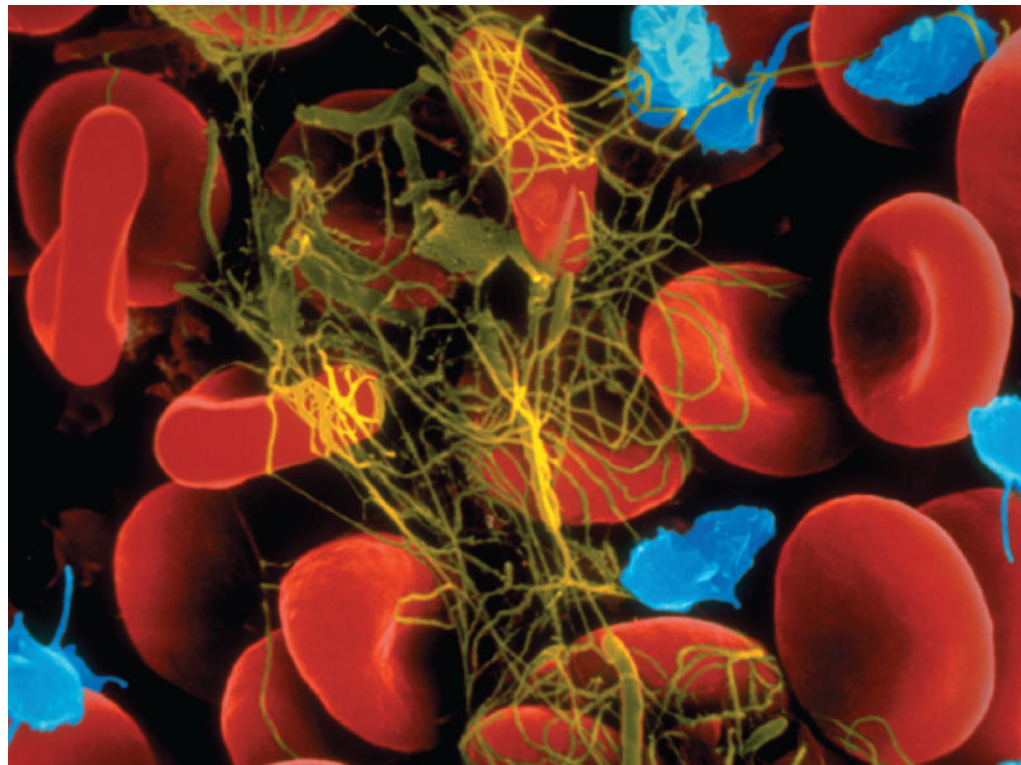
Blood (formed elements)

Leukocyte White blood cell. Serves as a part of the body's immune system.



Blood (formed elements)

Thrombocyte Platelet. Prevents blood loss through clotting mechanisms.

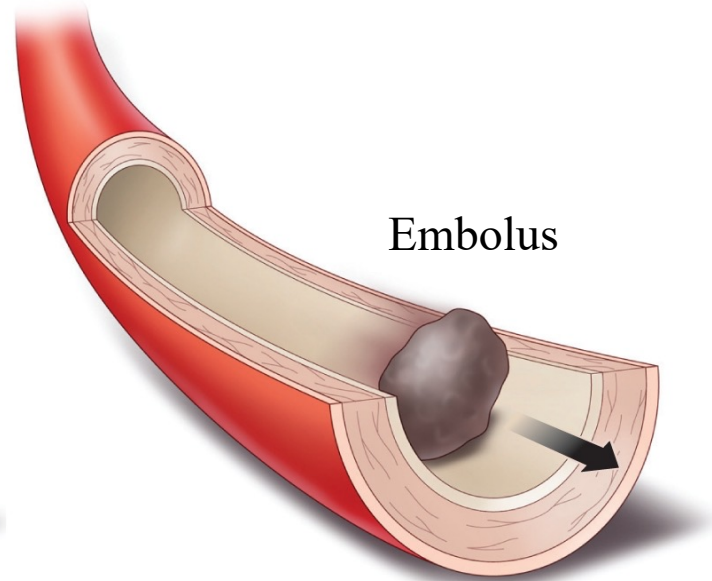
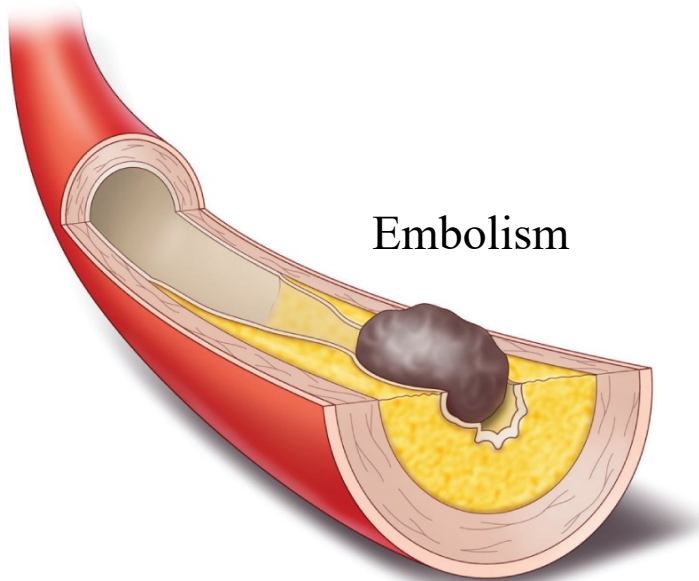


Blood

Thrombus Stationary blood clot.

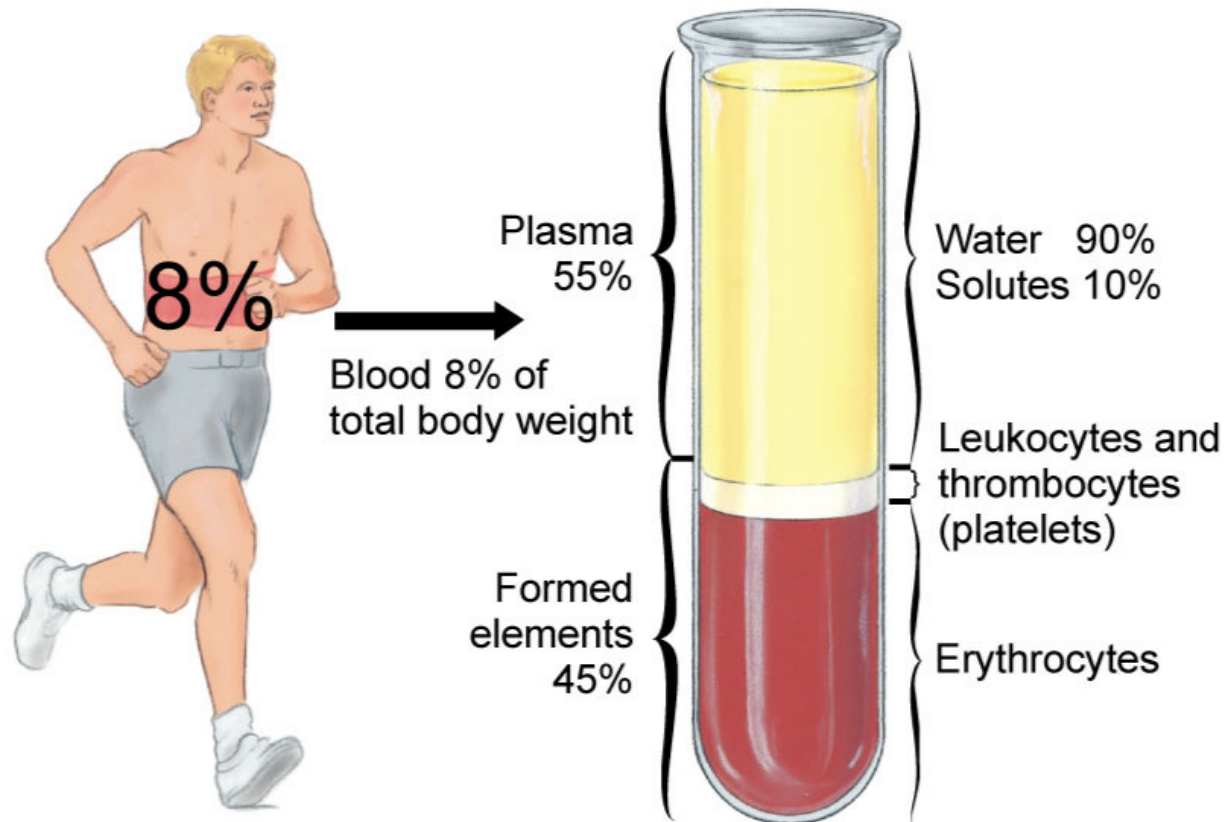
Embolus Floating mass of broken thrombus flowing through the blood stream.

Embolism Blockage of a blood vessel with an embolus.



Blood

Plasma Liquid portion of blood.



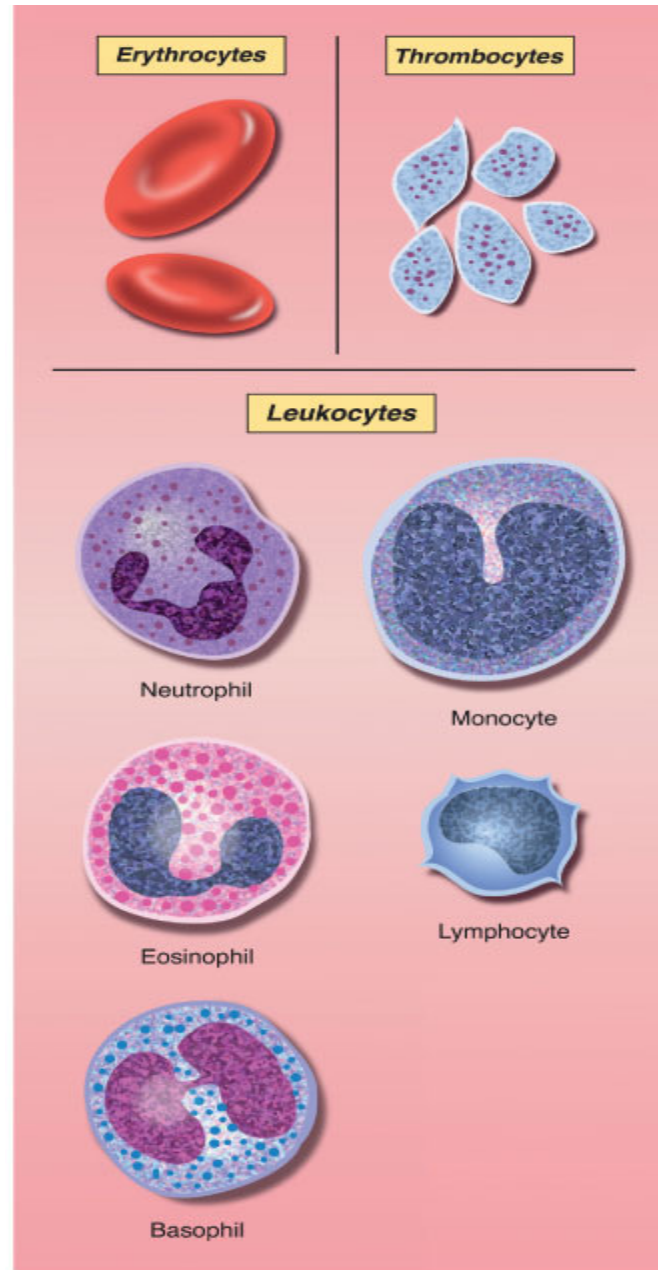
Response Moment

Erythrocytes
or
Red blood cells

Transport oxygen
and carbon dioxide

Leukocytes
or
White blood cells

Fight pathogens

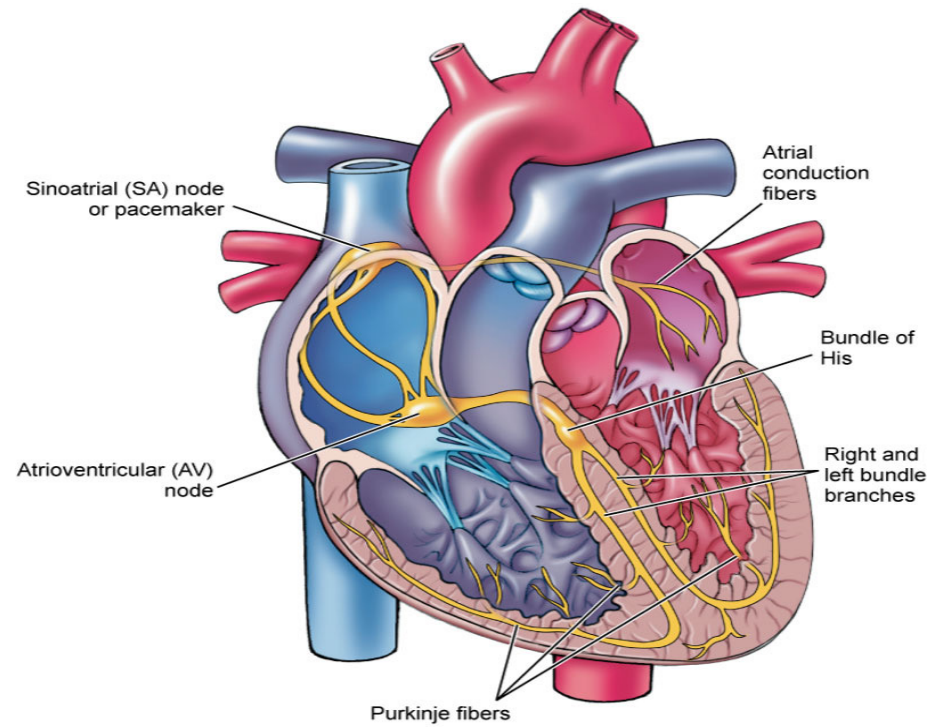


Thrombocytes
or
Platelets

Combat hemorrhage

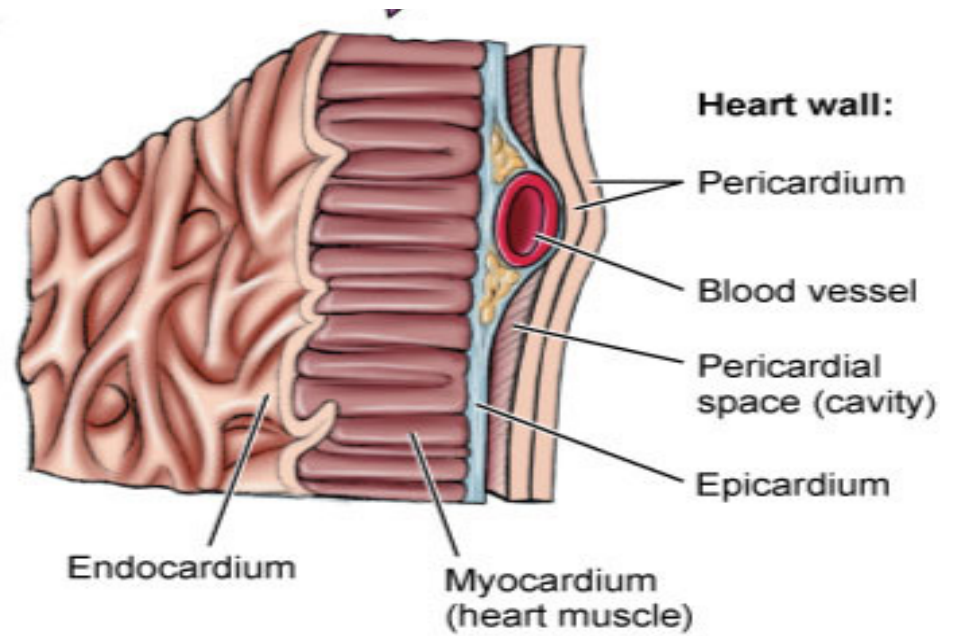
Heart

Wall
Chambers
Valves
Blood flow



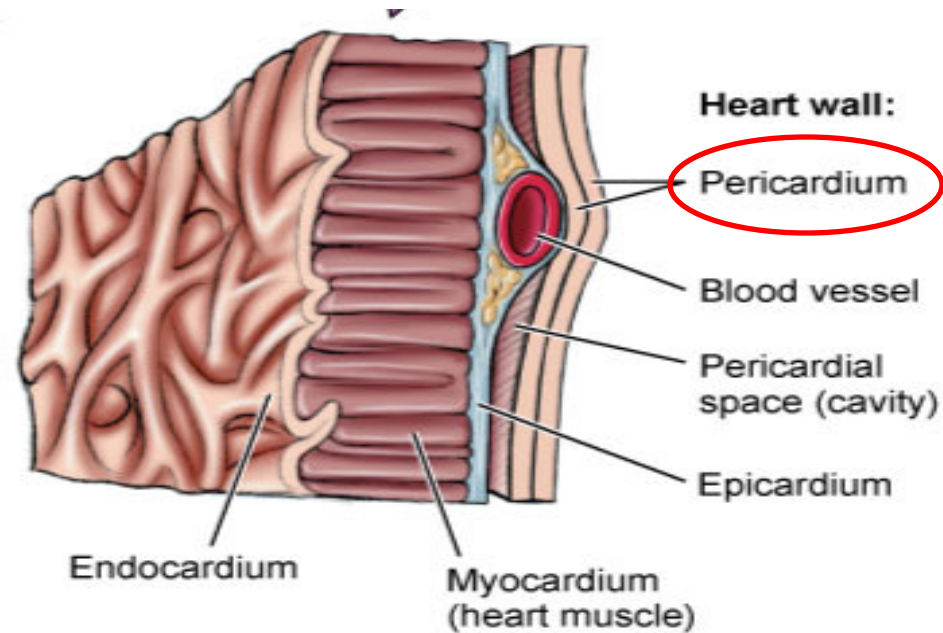
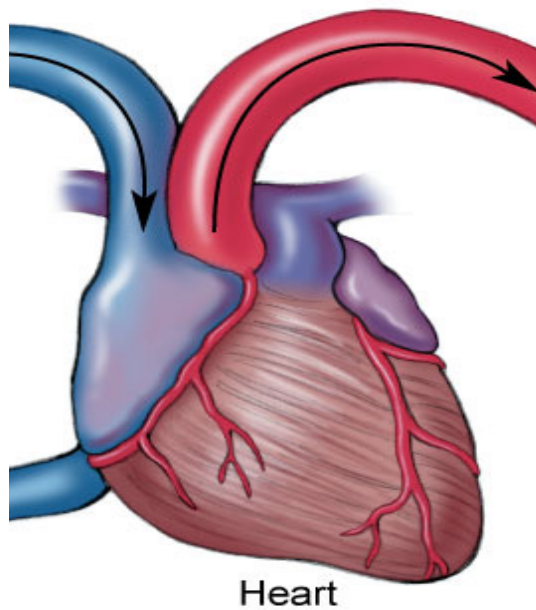
Heart Wall

PERI-cardium
EPI-cardium
MYO-cardium
ENDO-cardium



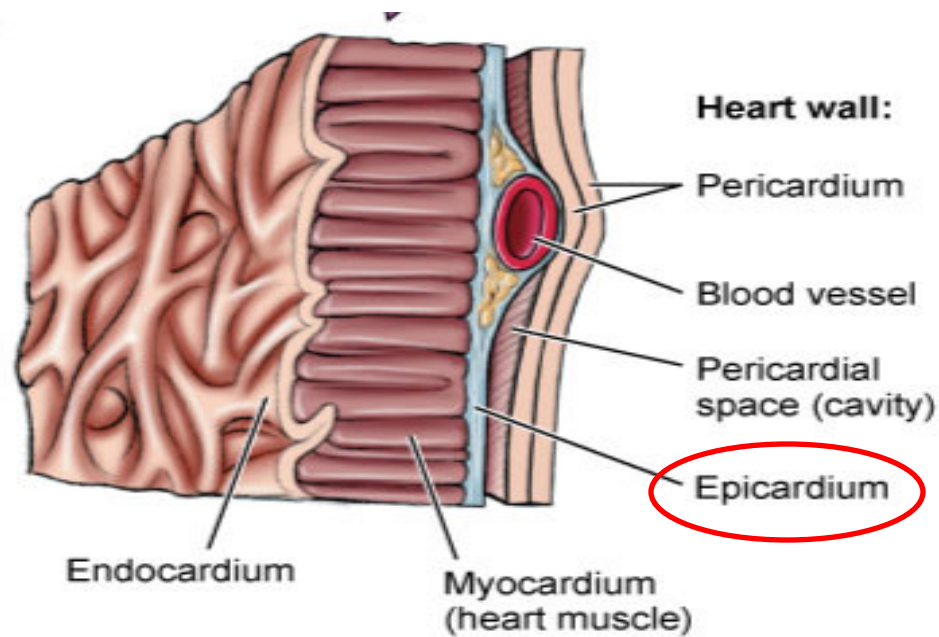
Heart Wall

Pericardium Tissue that surrounds the heart and secretes a lubricating fluid that prevents friction.



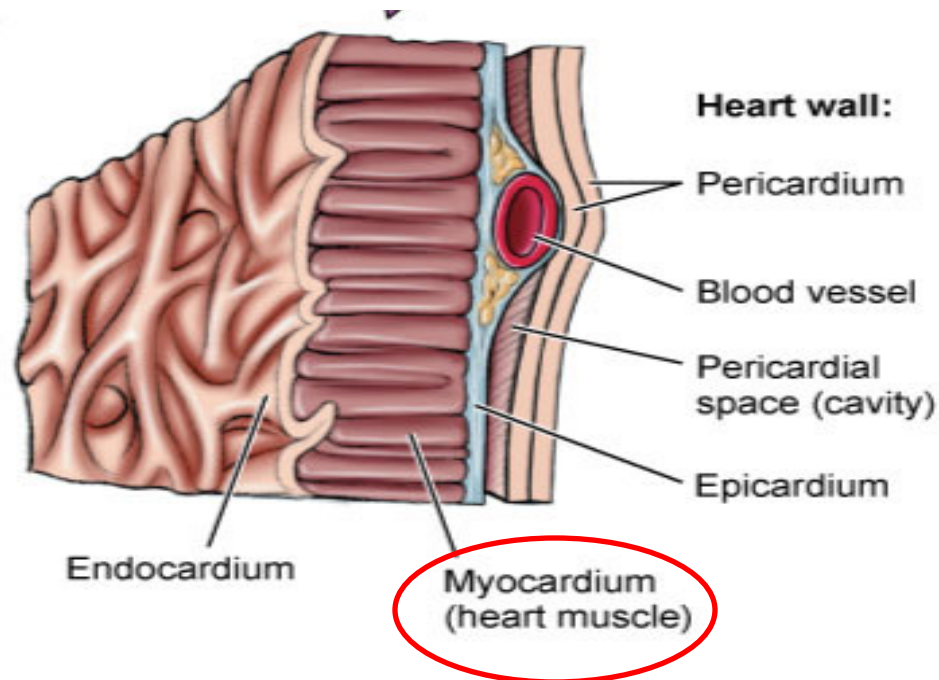
Heart Wall

Epicardium Thin outer connective tissue layer. Possesses adipose tissue and coronary vessels.



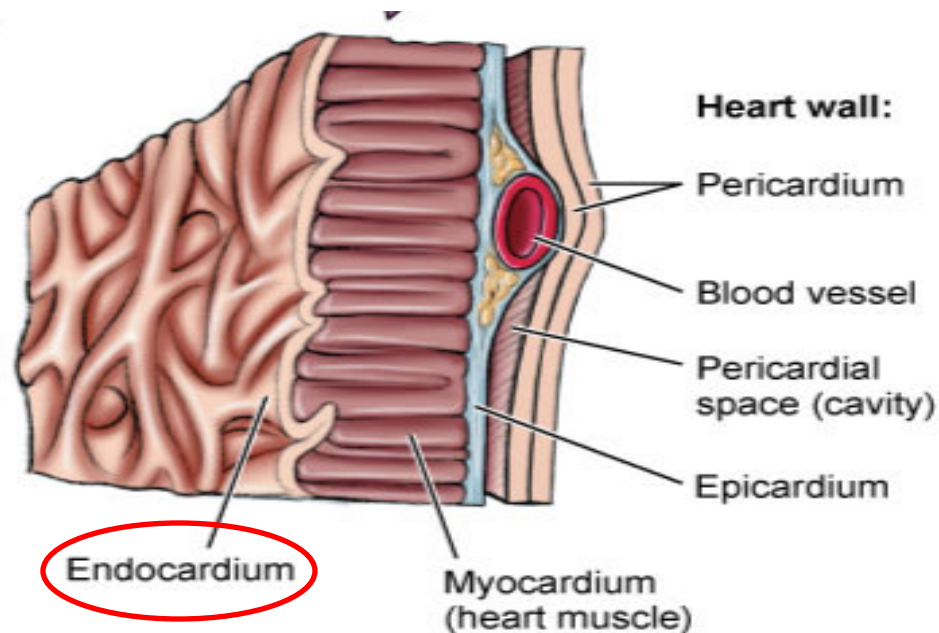
Heart Wall

Myocardium Thick muscular layer that makes up the bulk of the heart wall. Its contraction forces blood out of the ventricles.



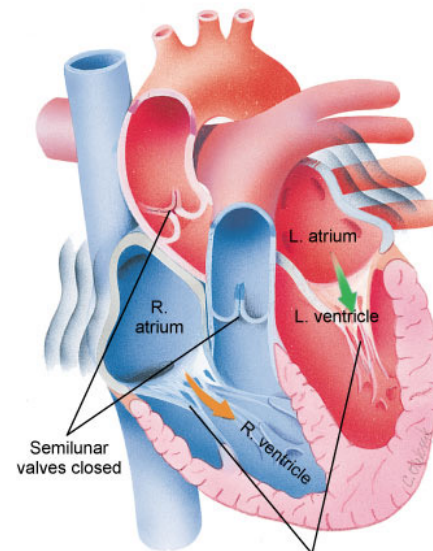
Heart Wall

Endocardium Thin, inner lining of the heart. Continuous with the endothelial lining of the heart chambers and blood vessels, as well as the valves of the heart.



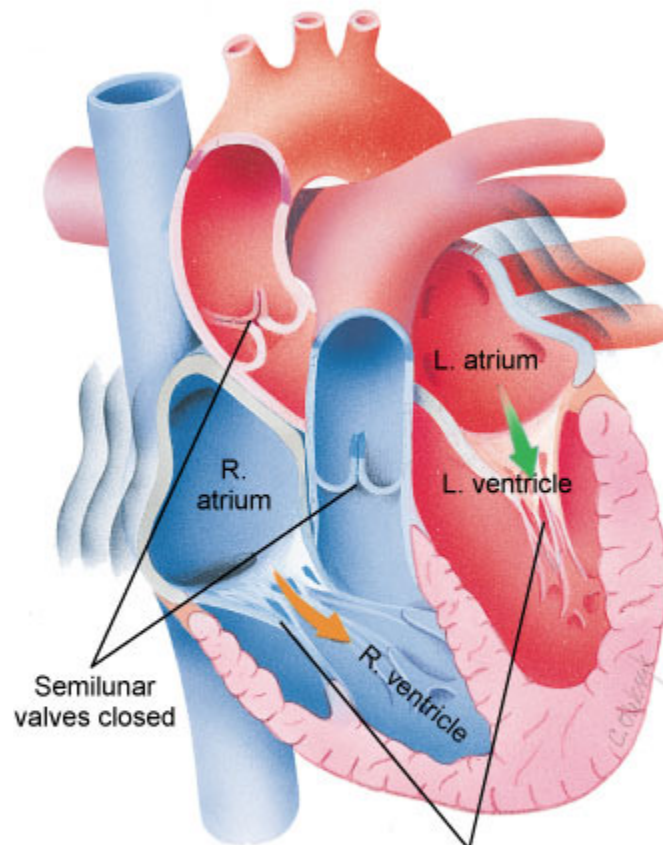
Heart Chambers

Atrium
Ventricle



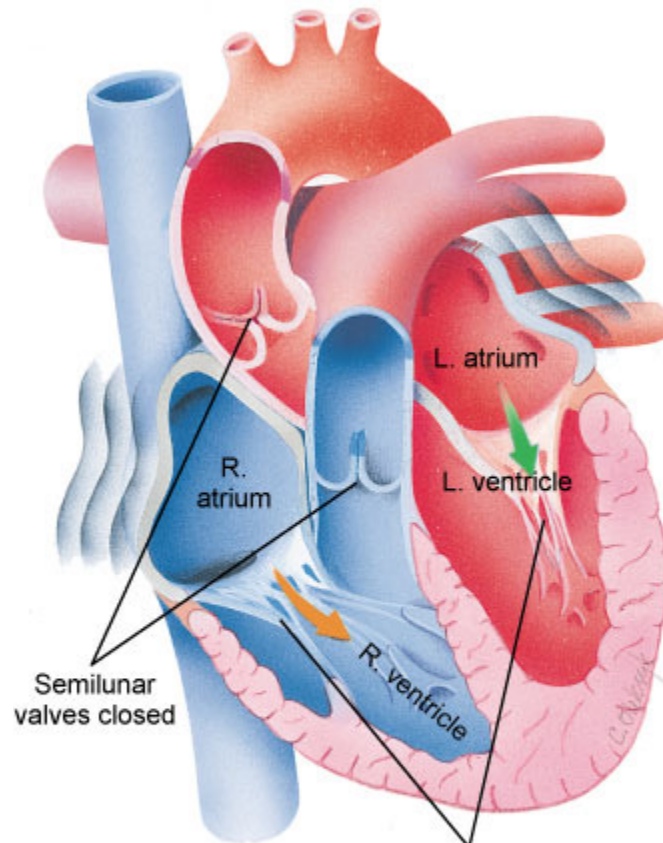
Heart Chambers

Atrium (p. atria) Superior heart chamber.



Heart Chambers

Ventricle Inferior heart chamber.





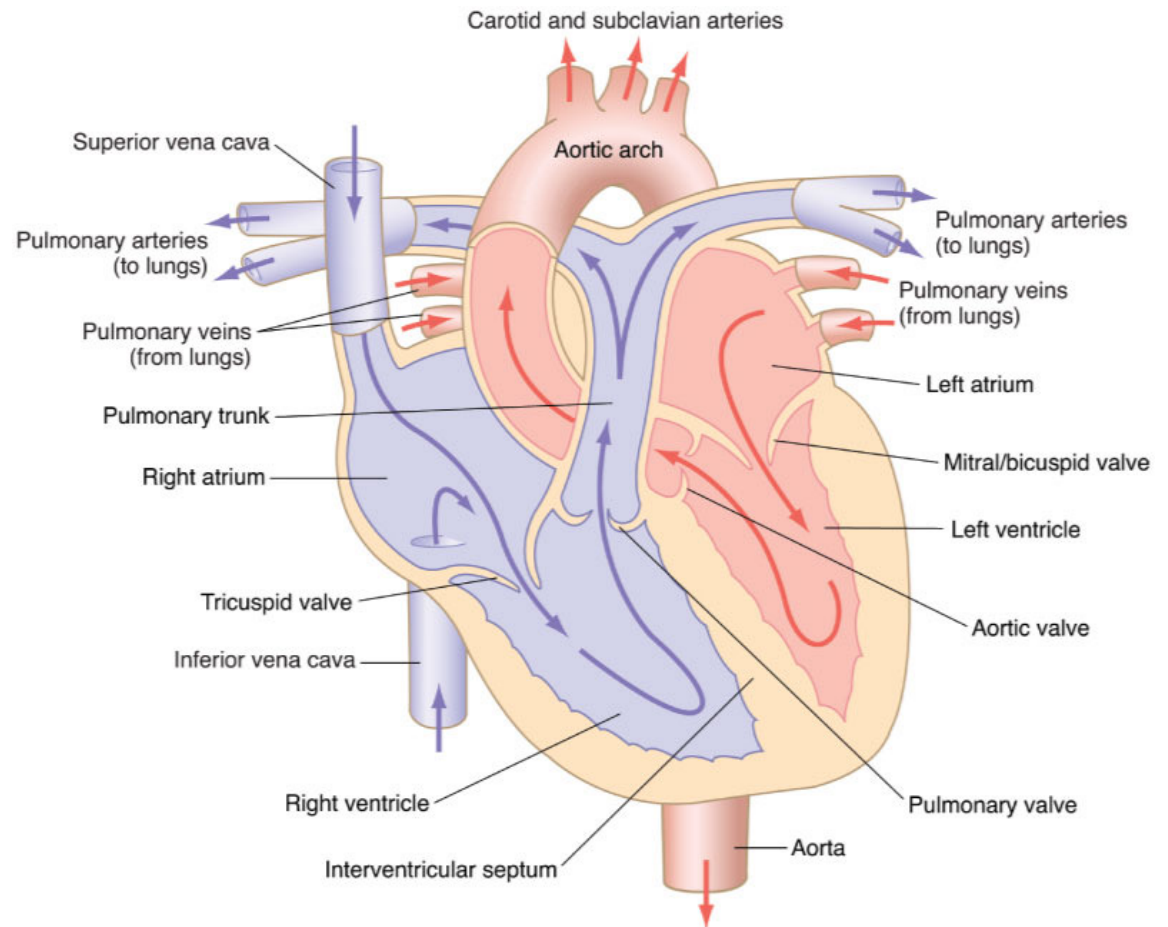
Heart Valves

Atrioventricular (A-V valve)
Semilunar

Heart Valves

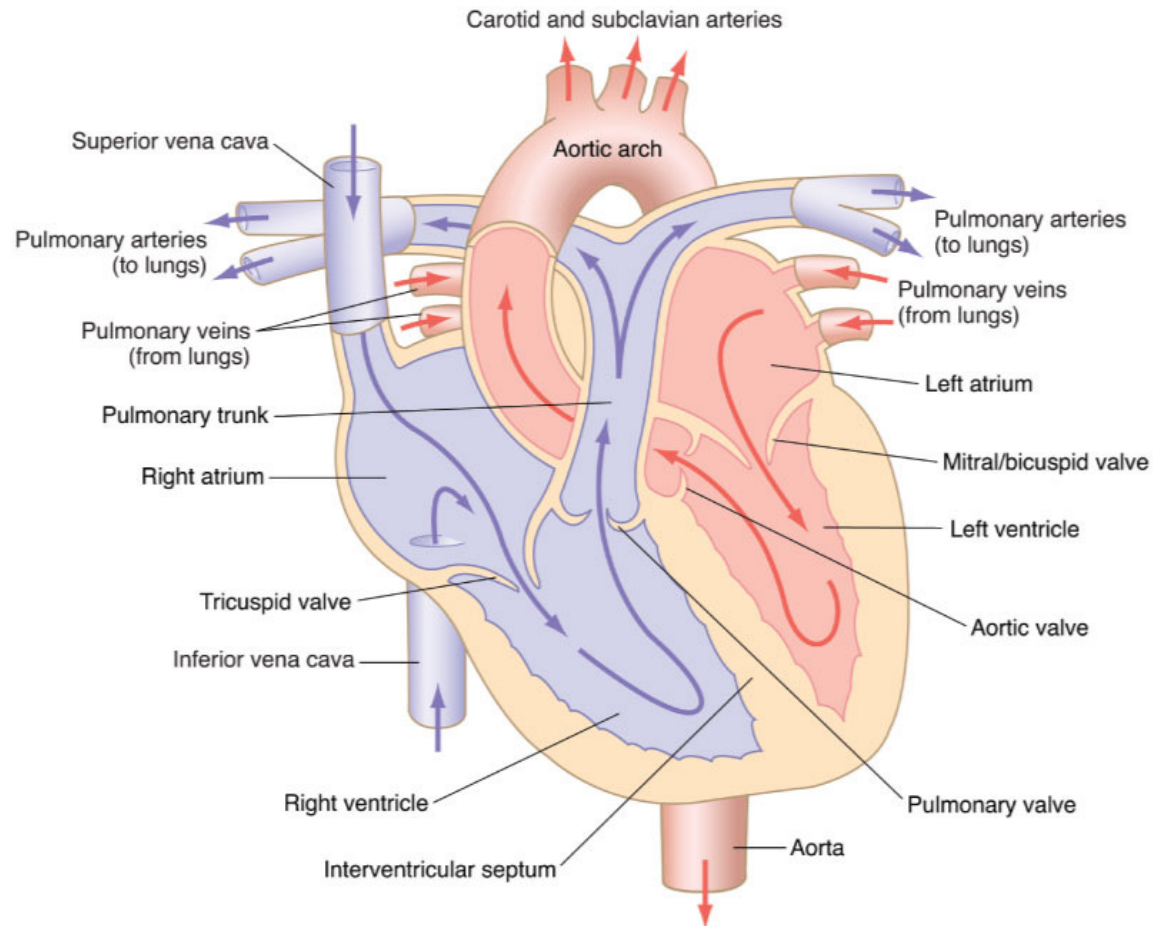
Atrioventricular Valves

- Mitral
- Tricuspid



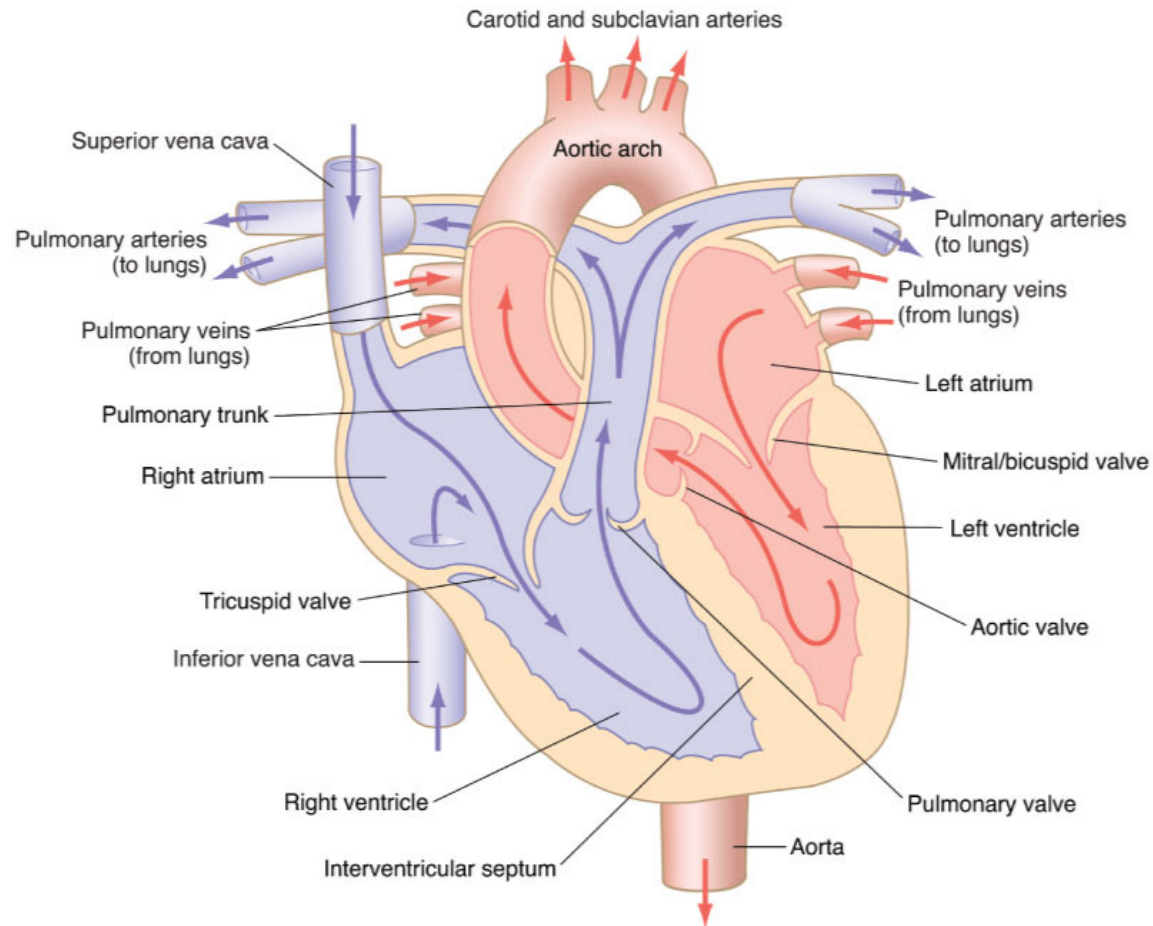
Heart Valves

Mitral valve (AKA: bicuspid valve, left A-V valve) Valve located between the left atrium and left ventricle.



Heart Valves

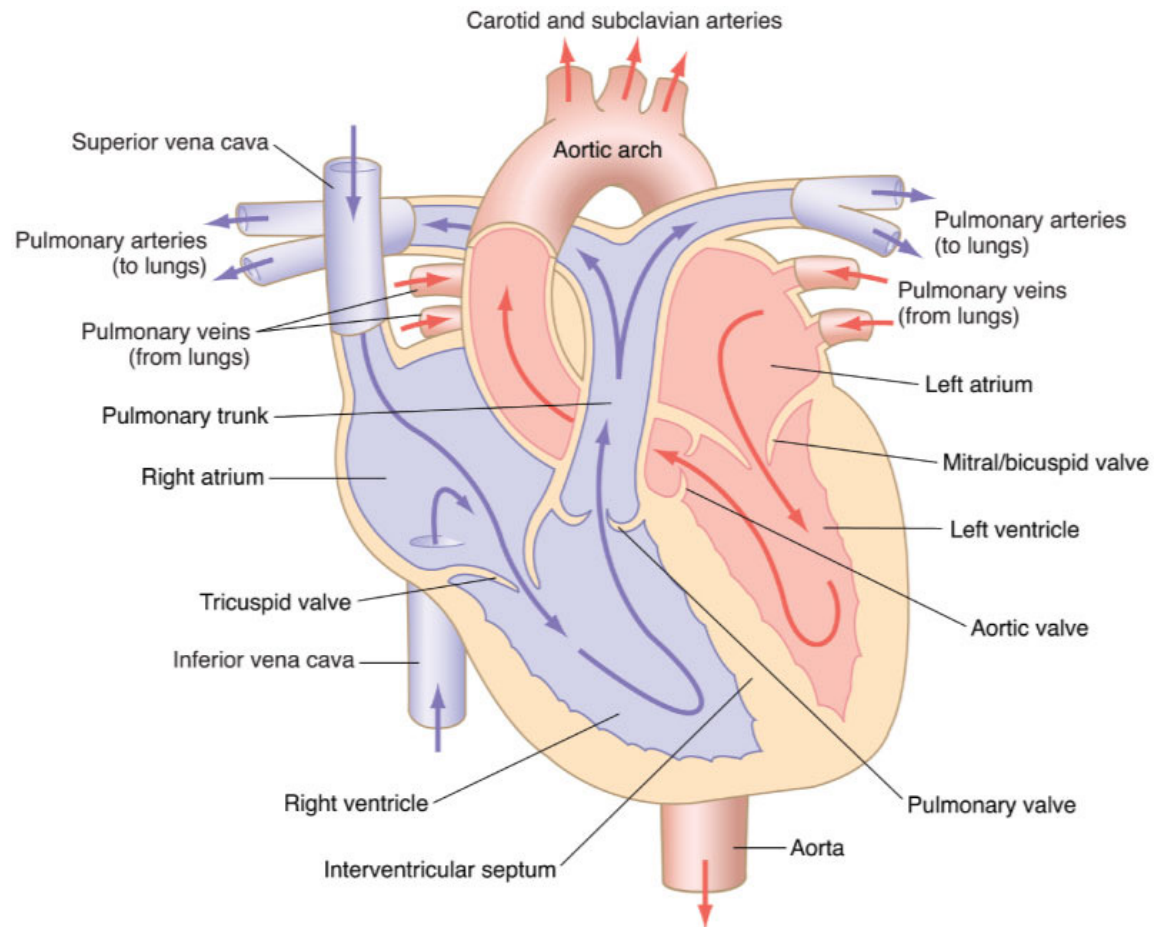
Tricuspid valve (AKA: right A-V valve) Valve located between the right atrium and right ventricle.



Heart Valves

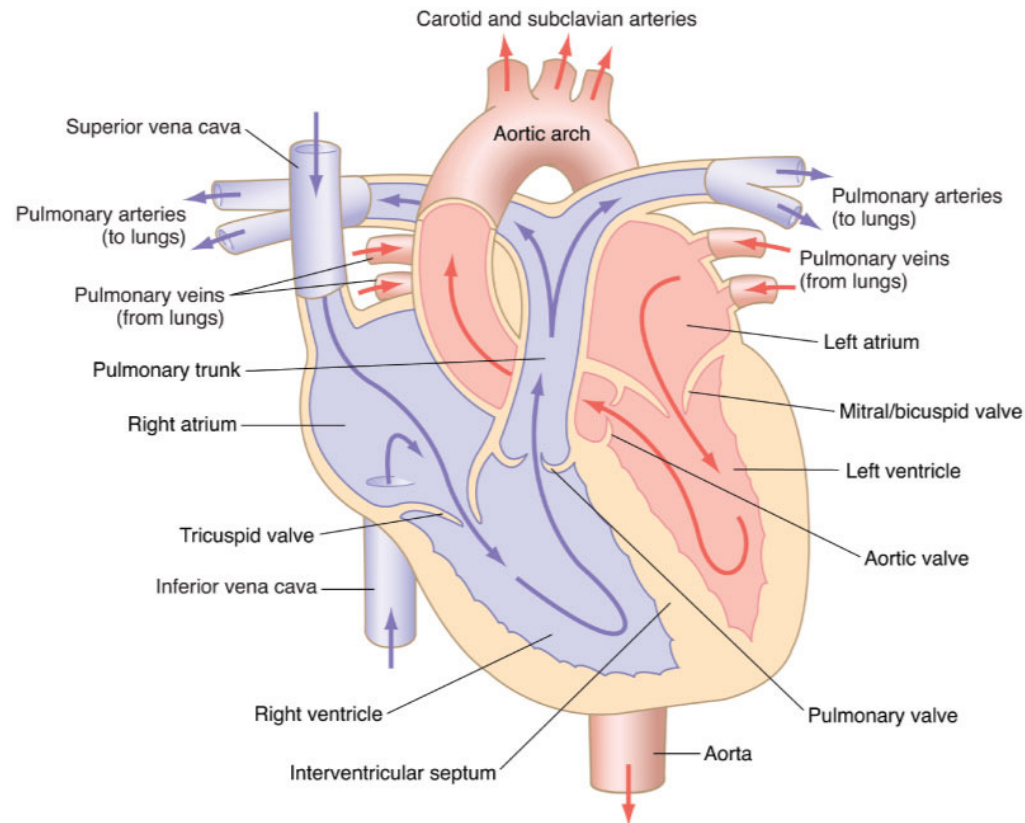
Semilunar Valves

- Pulmonary
- Aortic



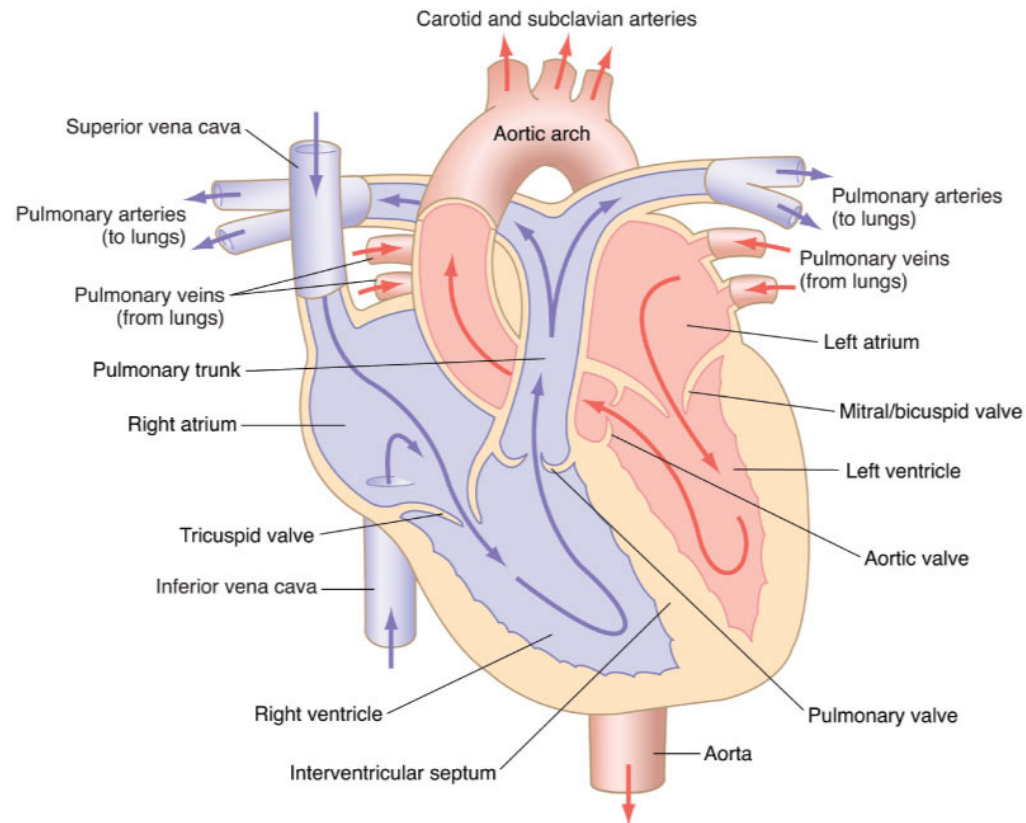
Heart Valves

Pulmonary valve (AKA: right semilunar valve) Valve between the right ventricle and the pulmonary trunk.



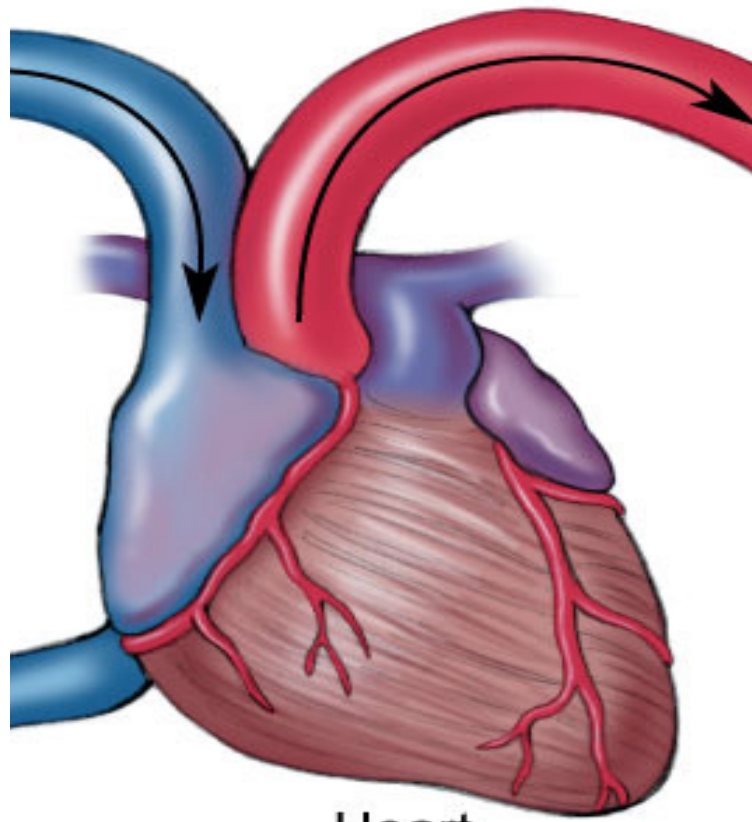
Heart Valves

Aortic valve (AKA: left semilunar valve) Valve between the left ventricle and the aorta.



Coronary vessels

Coronary vessels Arteries and veins that circulate blood to and from the myocardium.



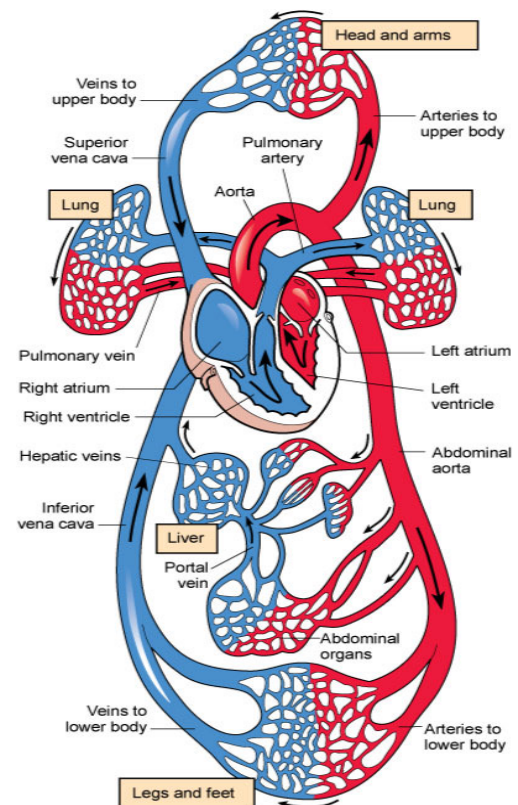
Heart

Blood Flow Through the Heart

Blood arrives at the heart

Blood goes to the lungs and comes back

Blood leaves the heart





Blood Flow Through the Heart

Stage 1 Oxygen-depleted blood enters the superior and inferior vena cava and flows into the right atrium. When the right atrium is full, it empties through the tricuspid valve into the right ventricle.

Occurs at the same time as Stage 3.



Blood Flow Through the Heart

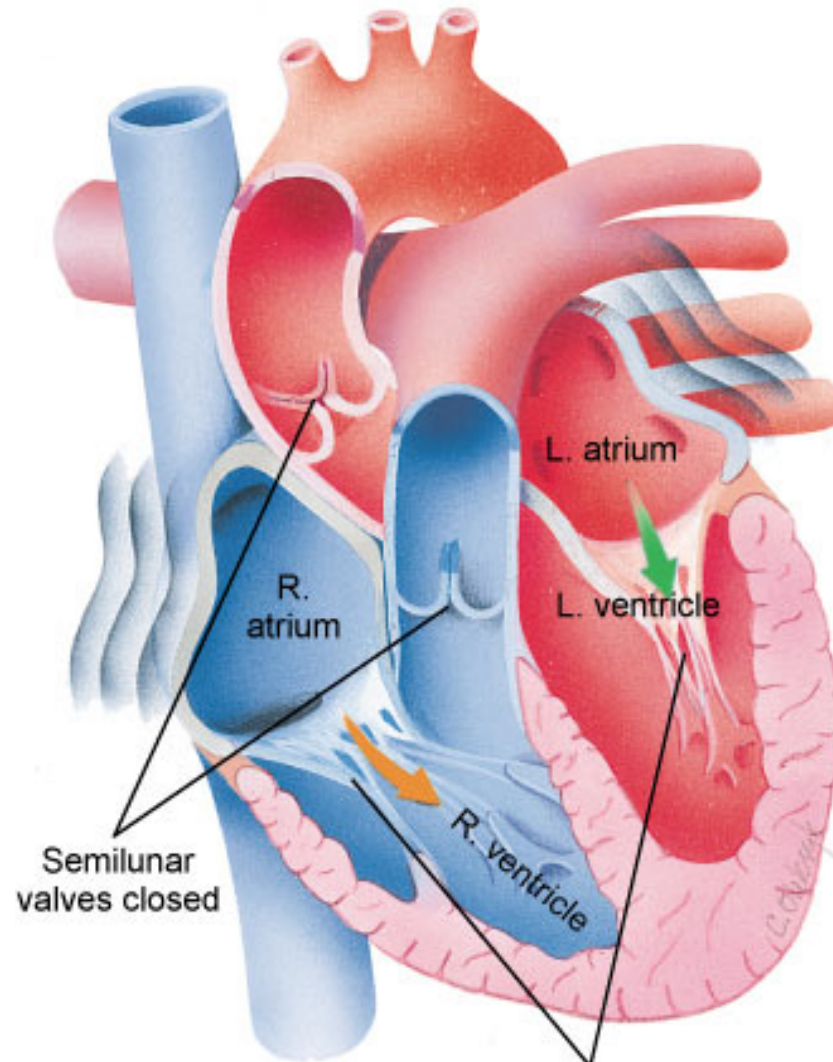
Stage 2 The right ventricle contracts and pushes blood through the pulmonary valve into the pulmonary trunk. The pulmonary trunk then divides into left and right pulmonary arteries which take blood to each lung. Four pulmonary veins leave the lungs and carry oxygen-rich blood back to the left atrium.



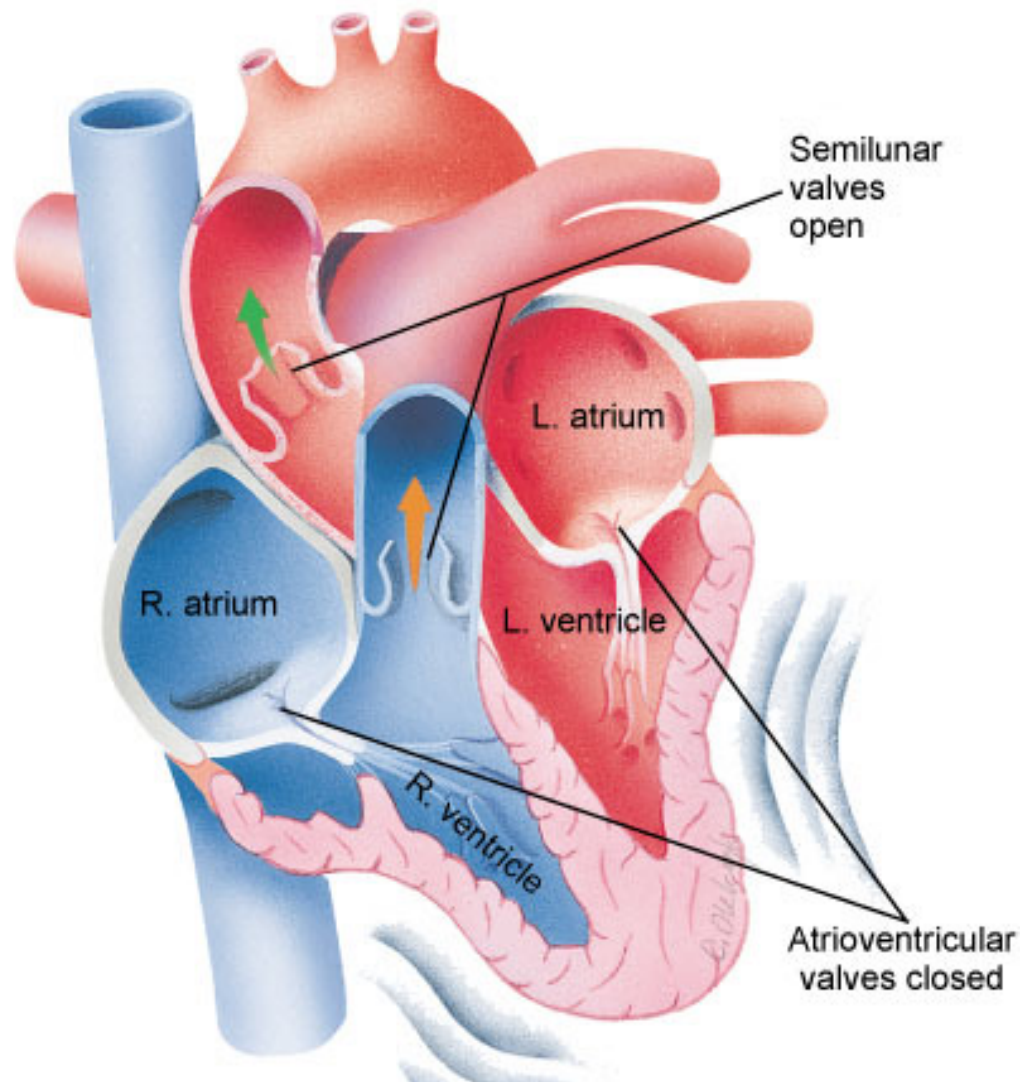
Blood Flow Through the Heart

Stage 3 Blood leaves the left atrium and passes through the left ventricle through the mitral valve. The left ventricle contracts and pushes blood through the aortic valve into the aorta and descending aorta and to all parts of the body except the lungs. Occurs at the same time as Stage 1.

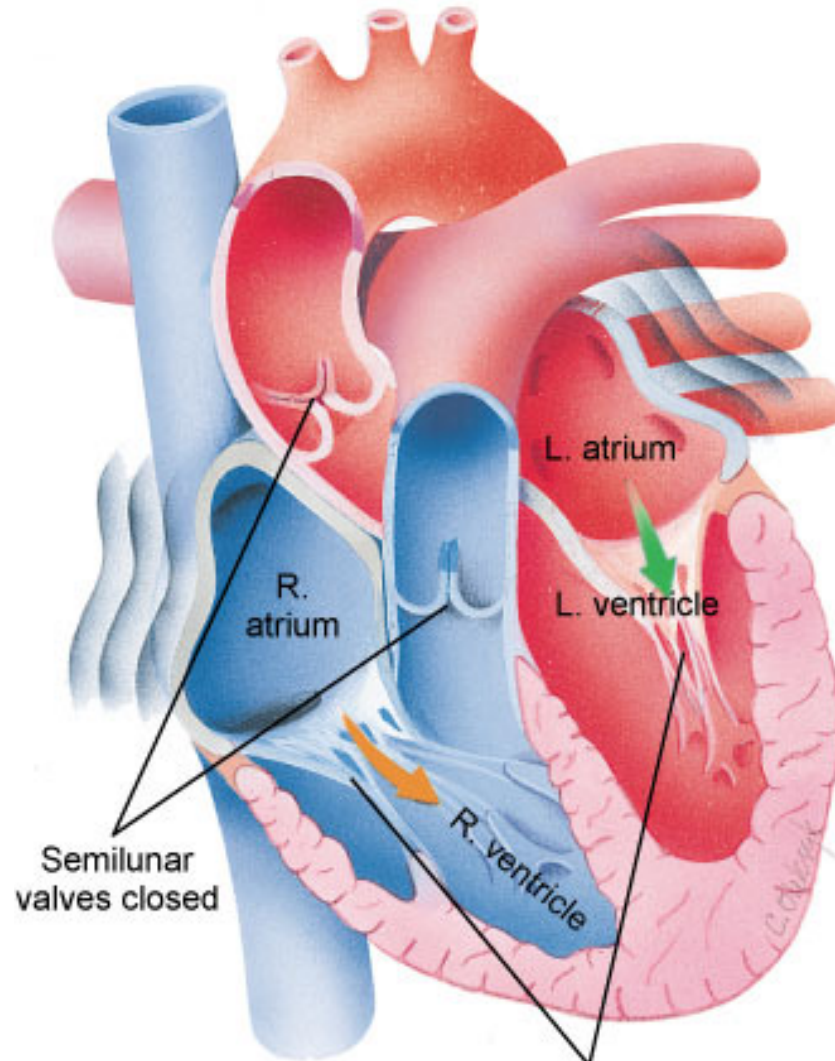
Stage 1: End of Systemic Circuit, Blood fills the right side of the heart



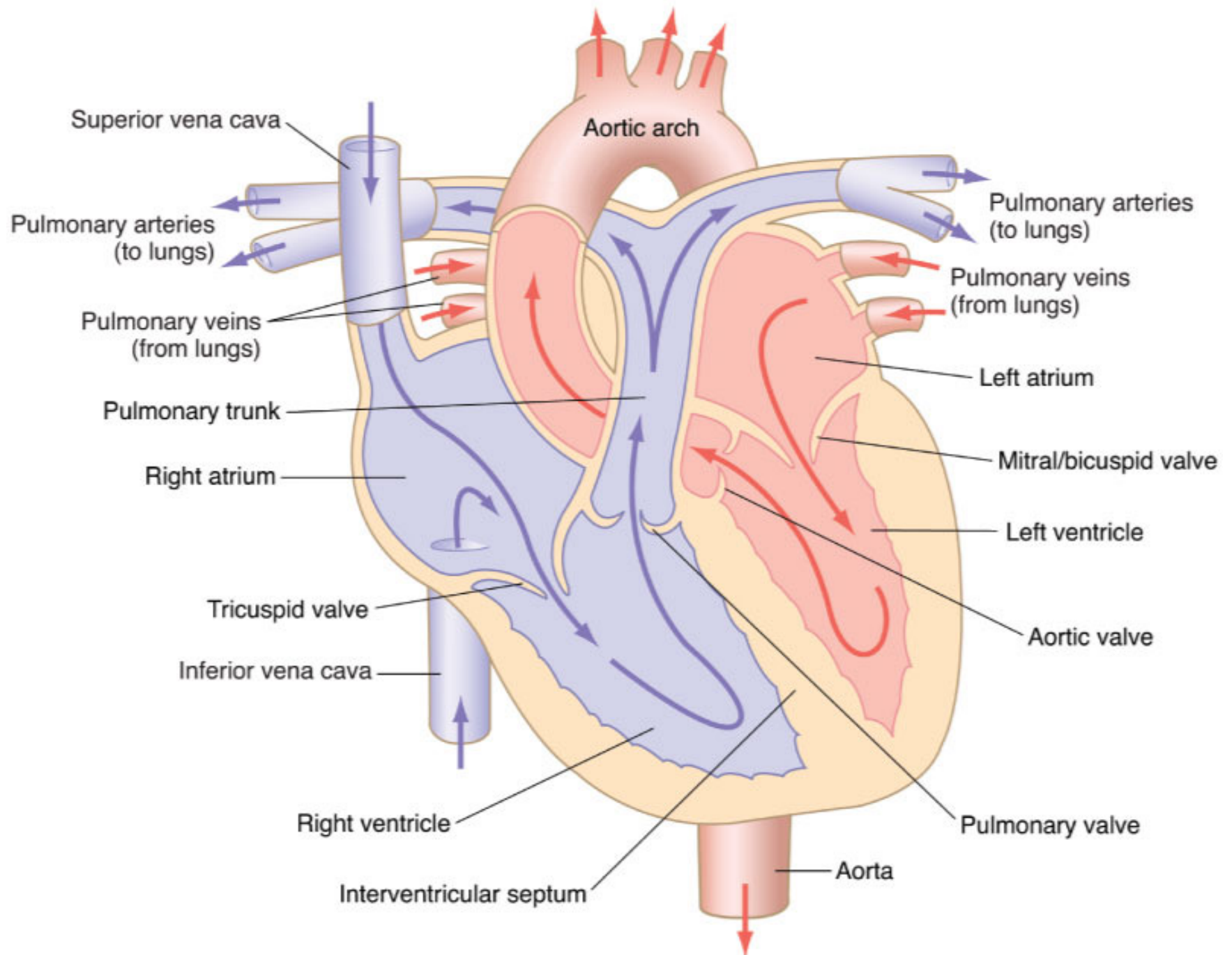
Stage 2: Pulmonary Circuit, Heart pumps blood to lungs and back to the heart

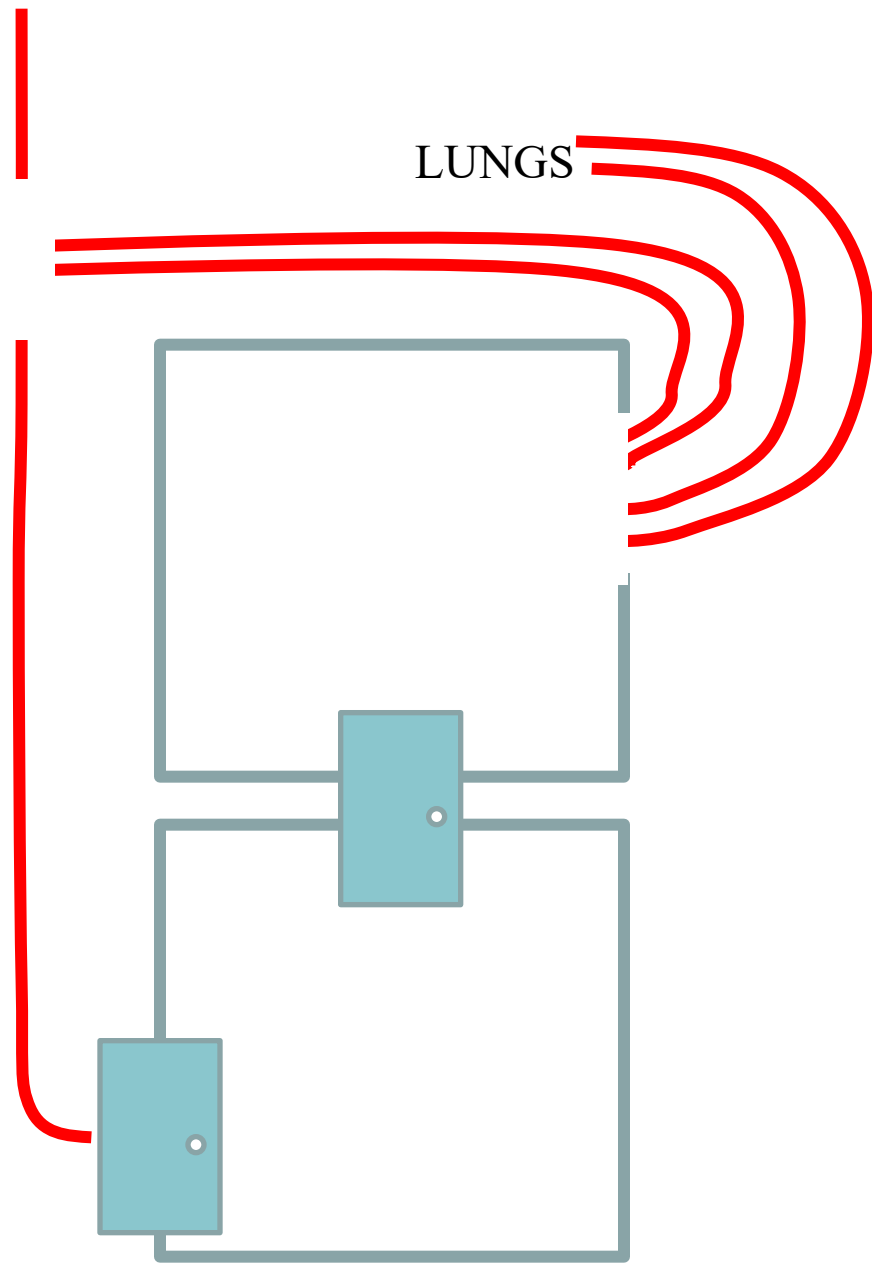
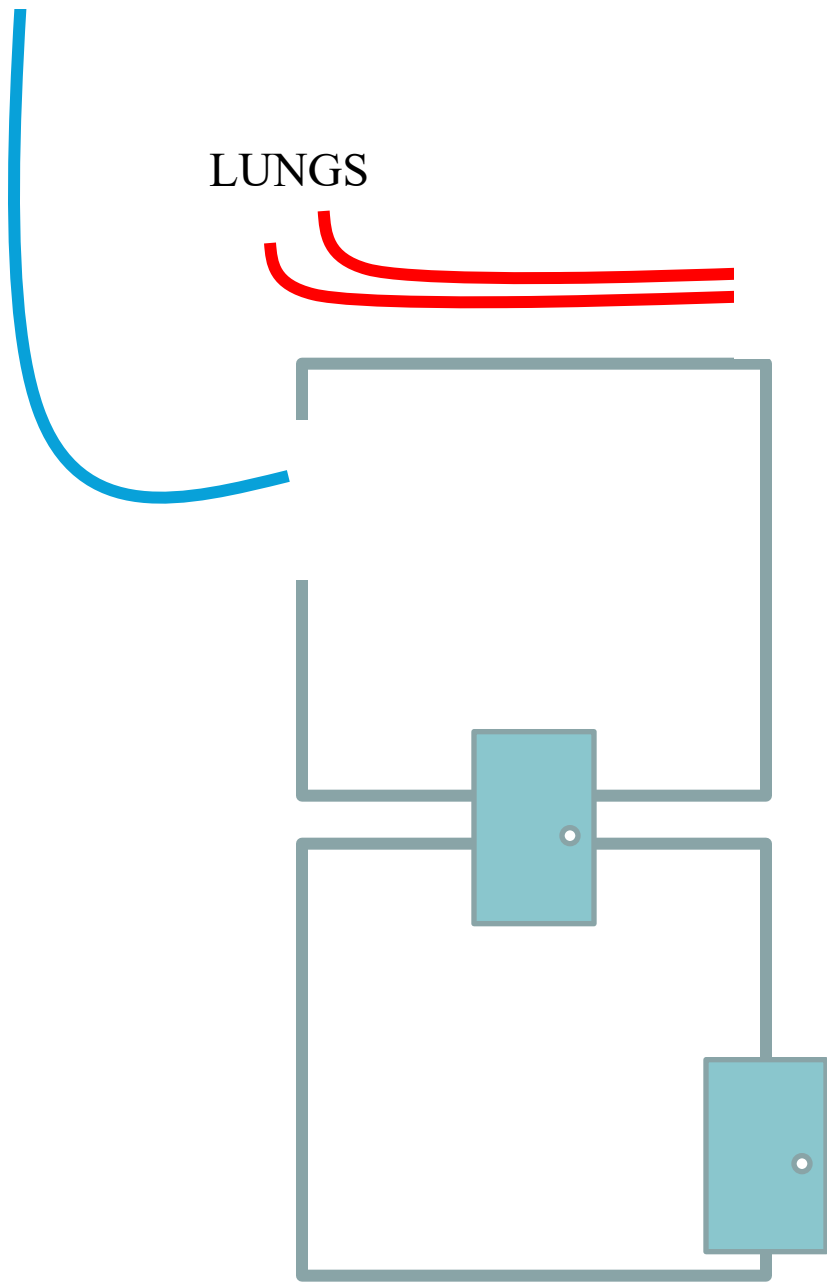


Stage 3: Beginning of Systemic Circuit, Heart pumps blood out to the entire body

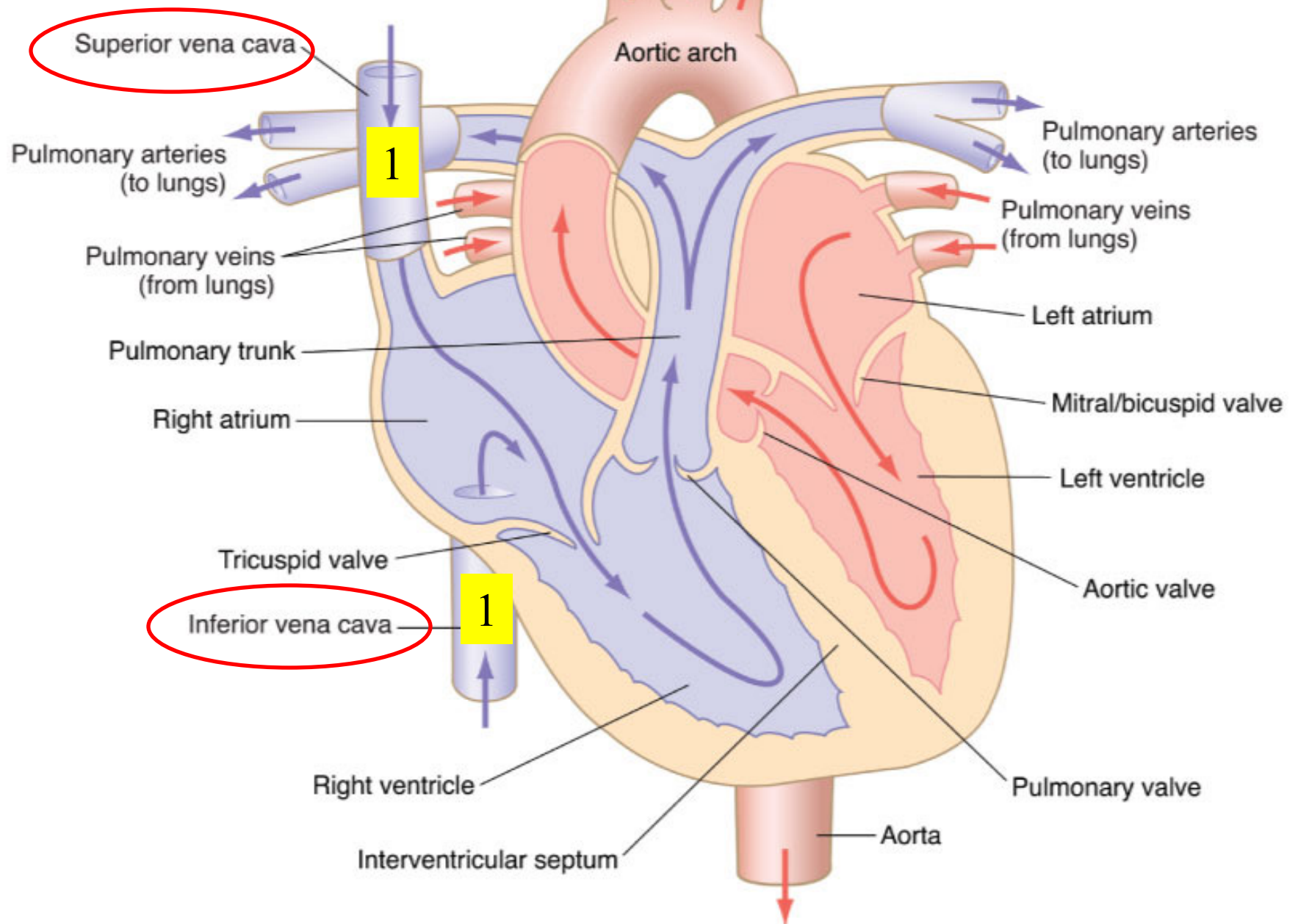


Carotid and subclavian arteries

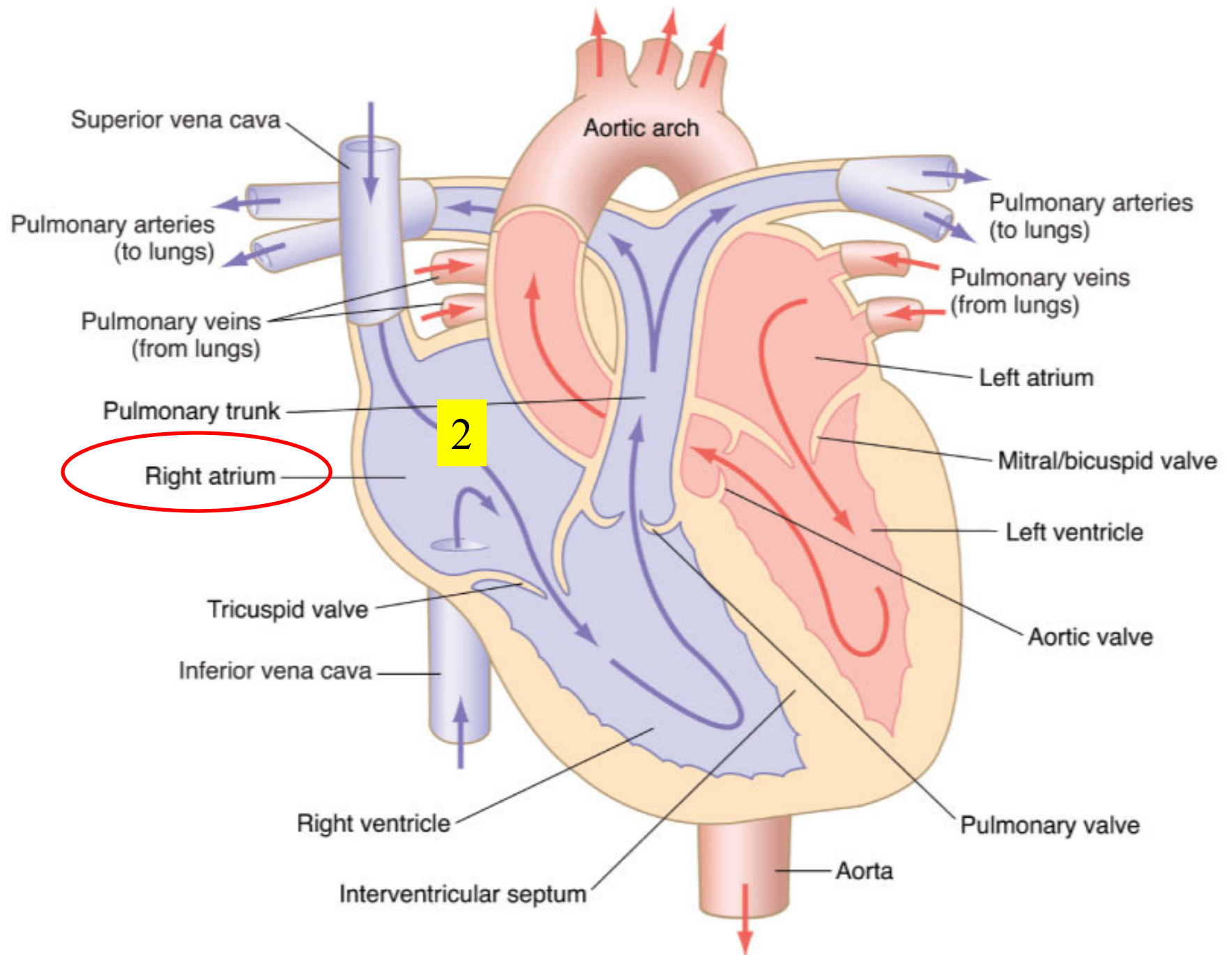




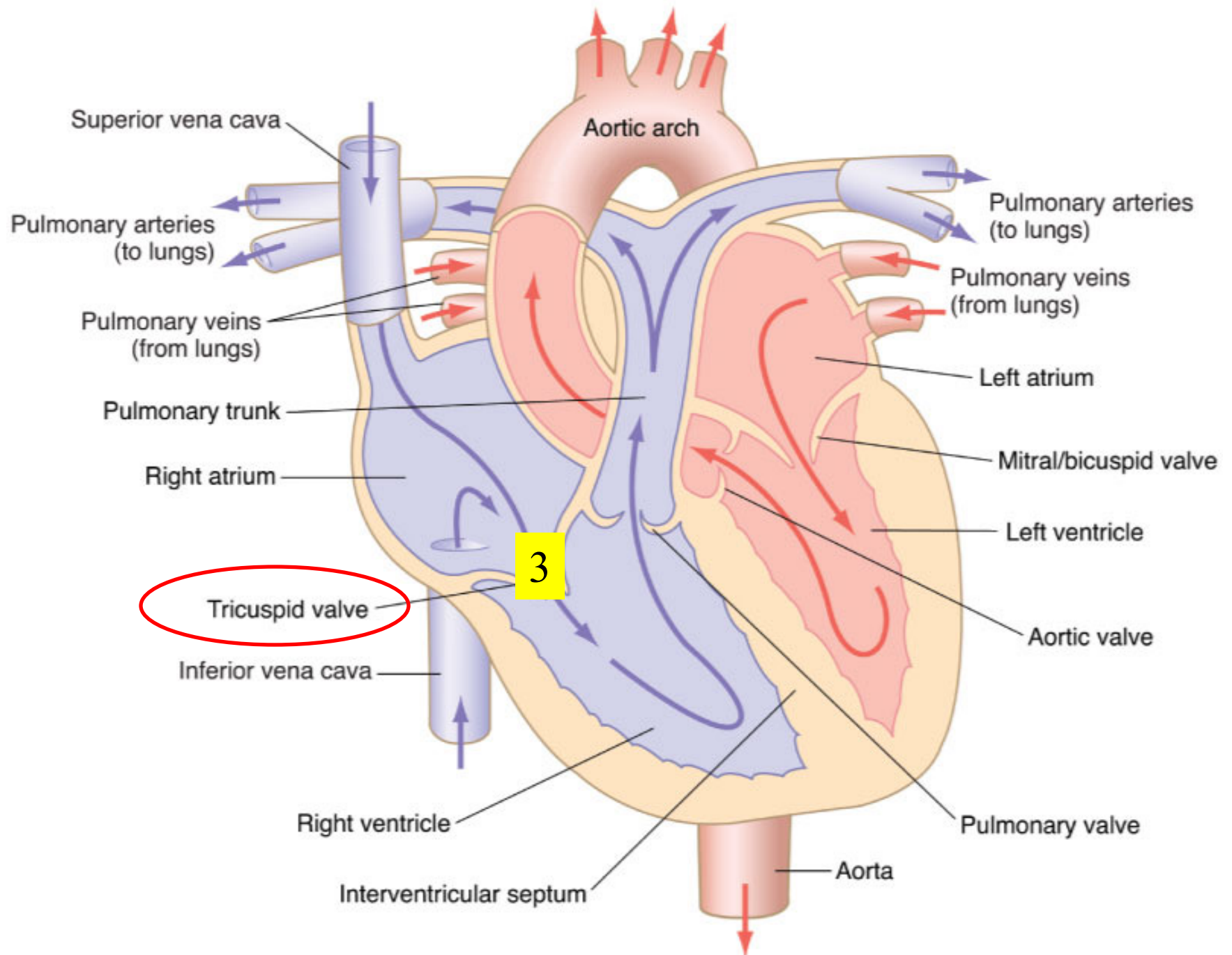
Carotid and subclavian arteries



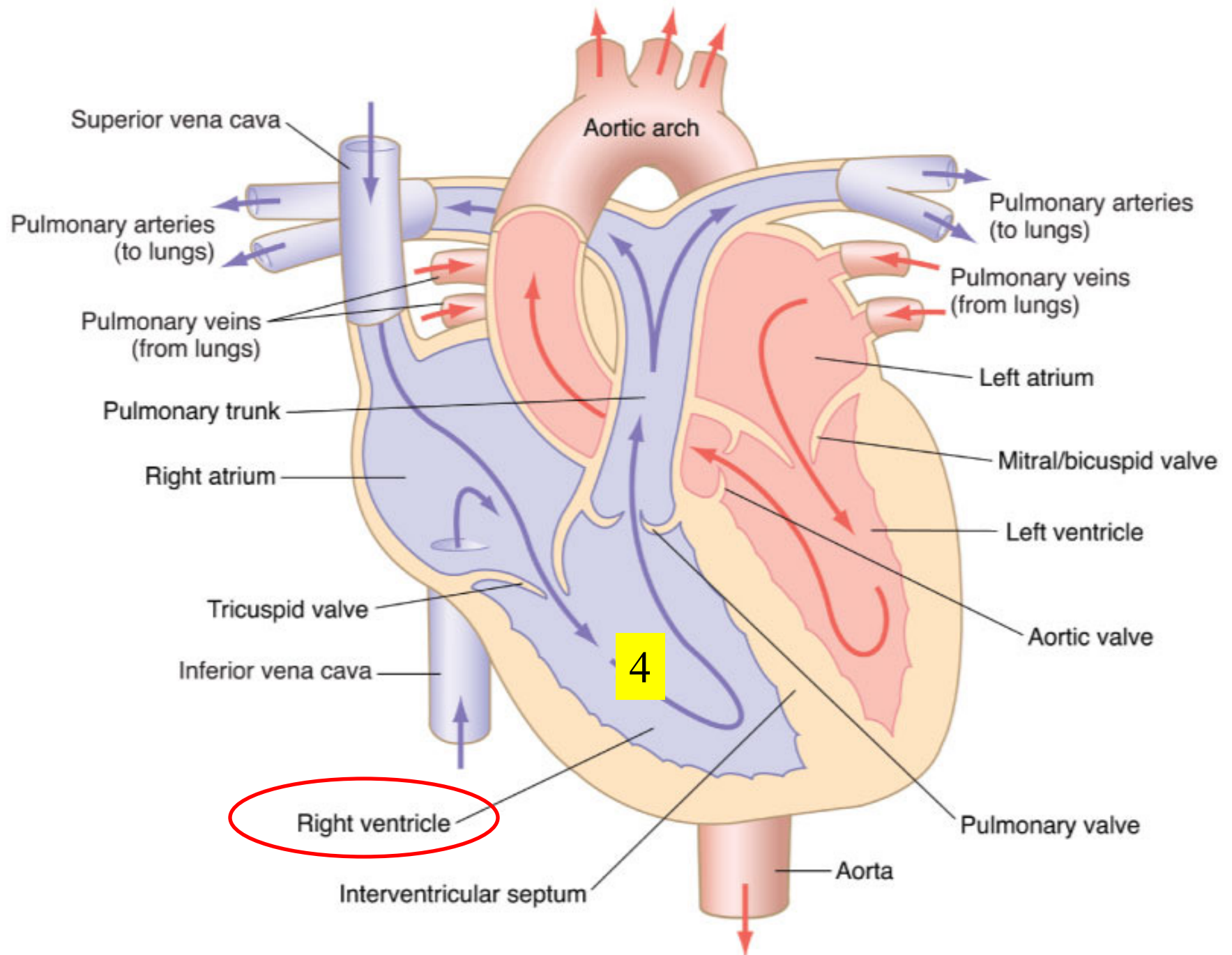
Carotid and subclavian arteries



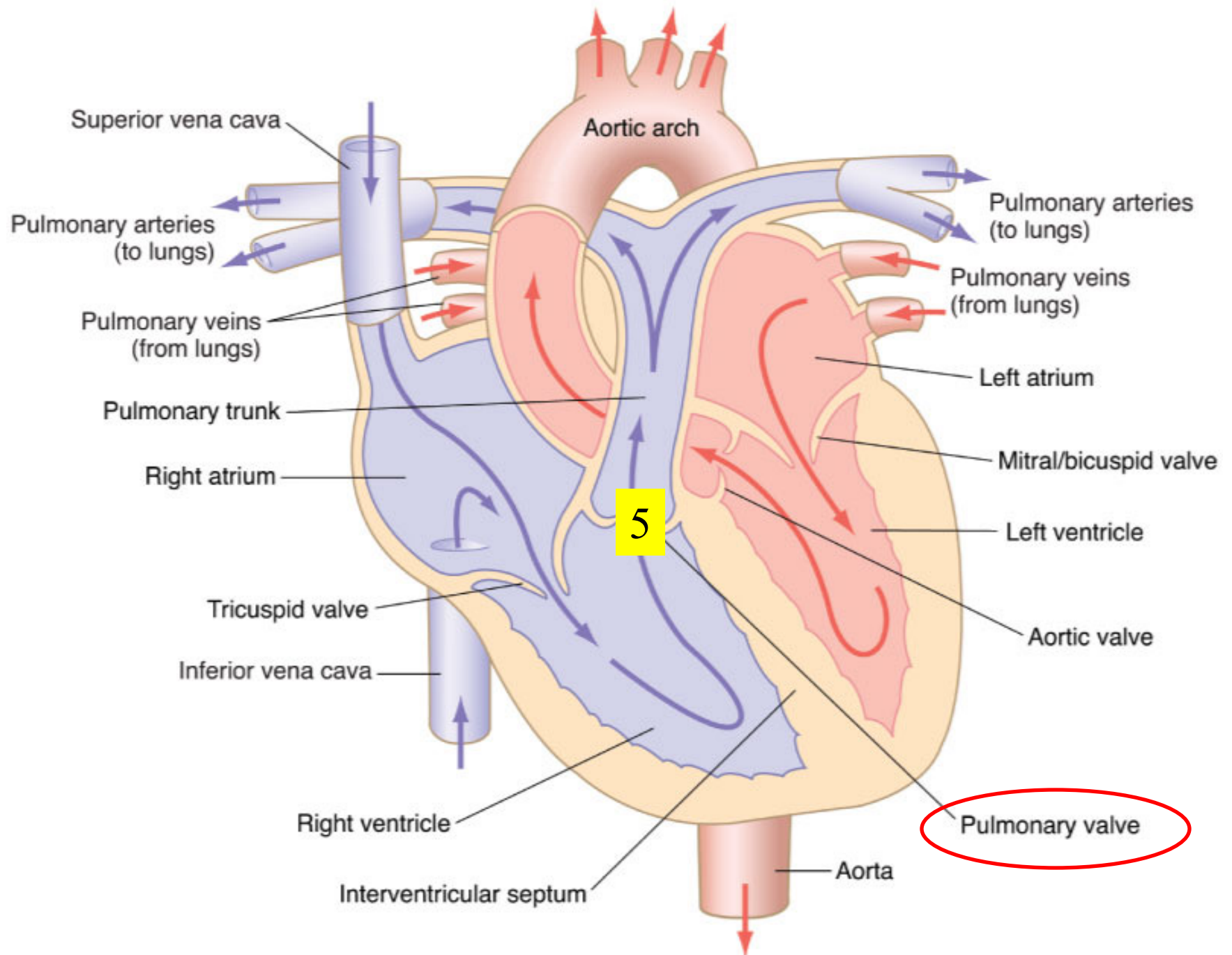
Carotid and subclavian arteries



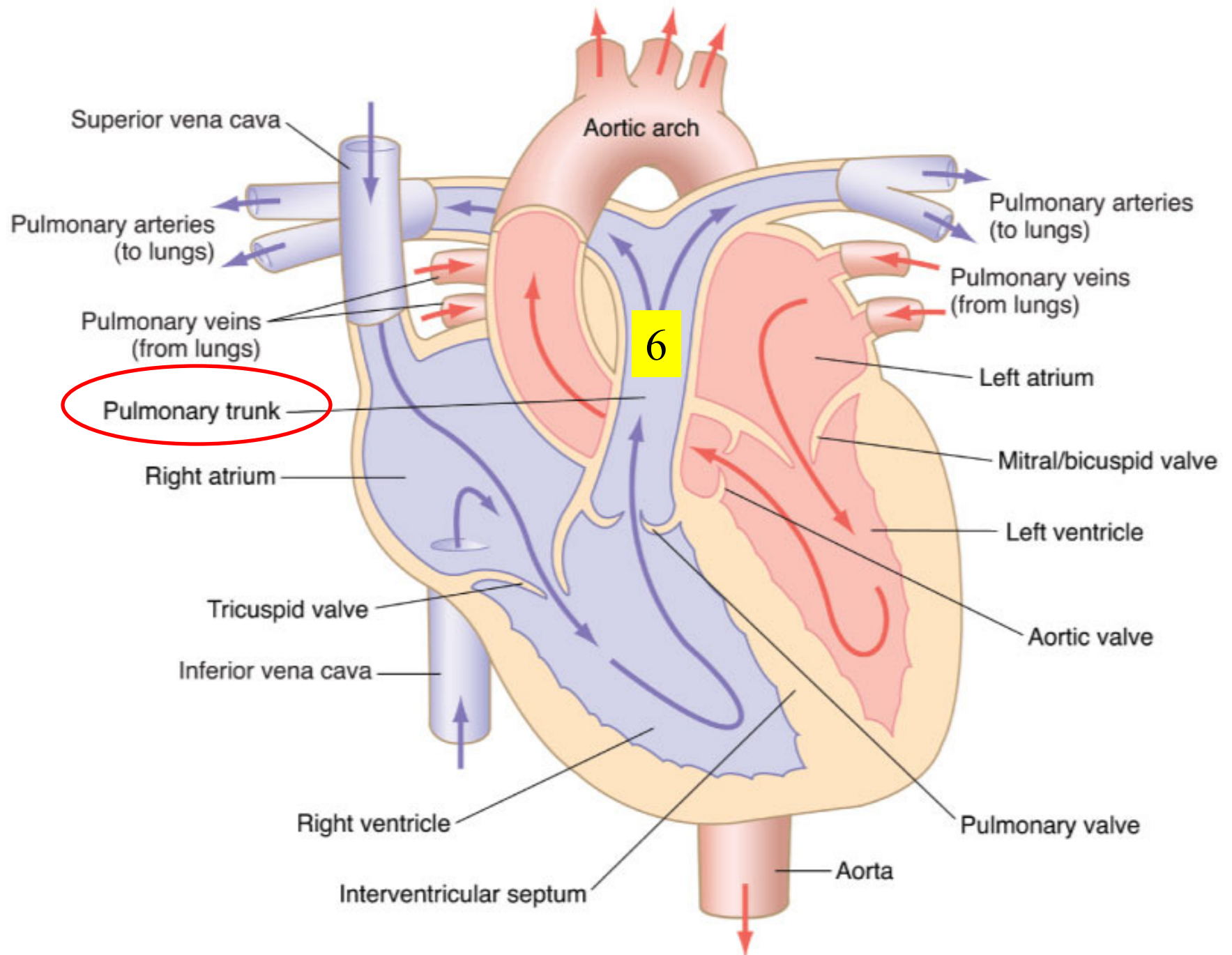
Carotid and subclavian arteries

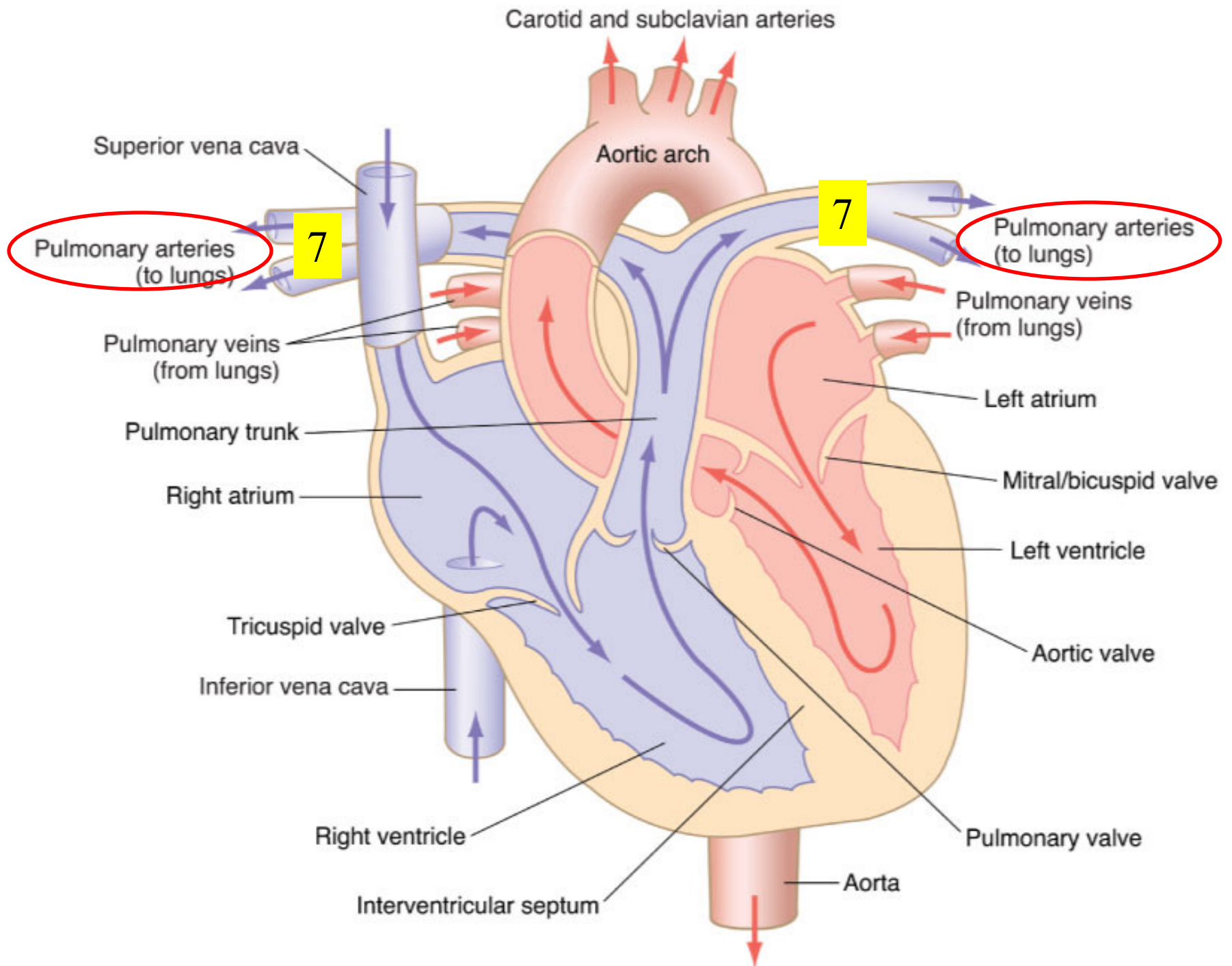


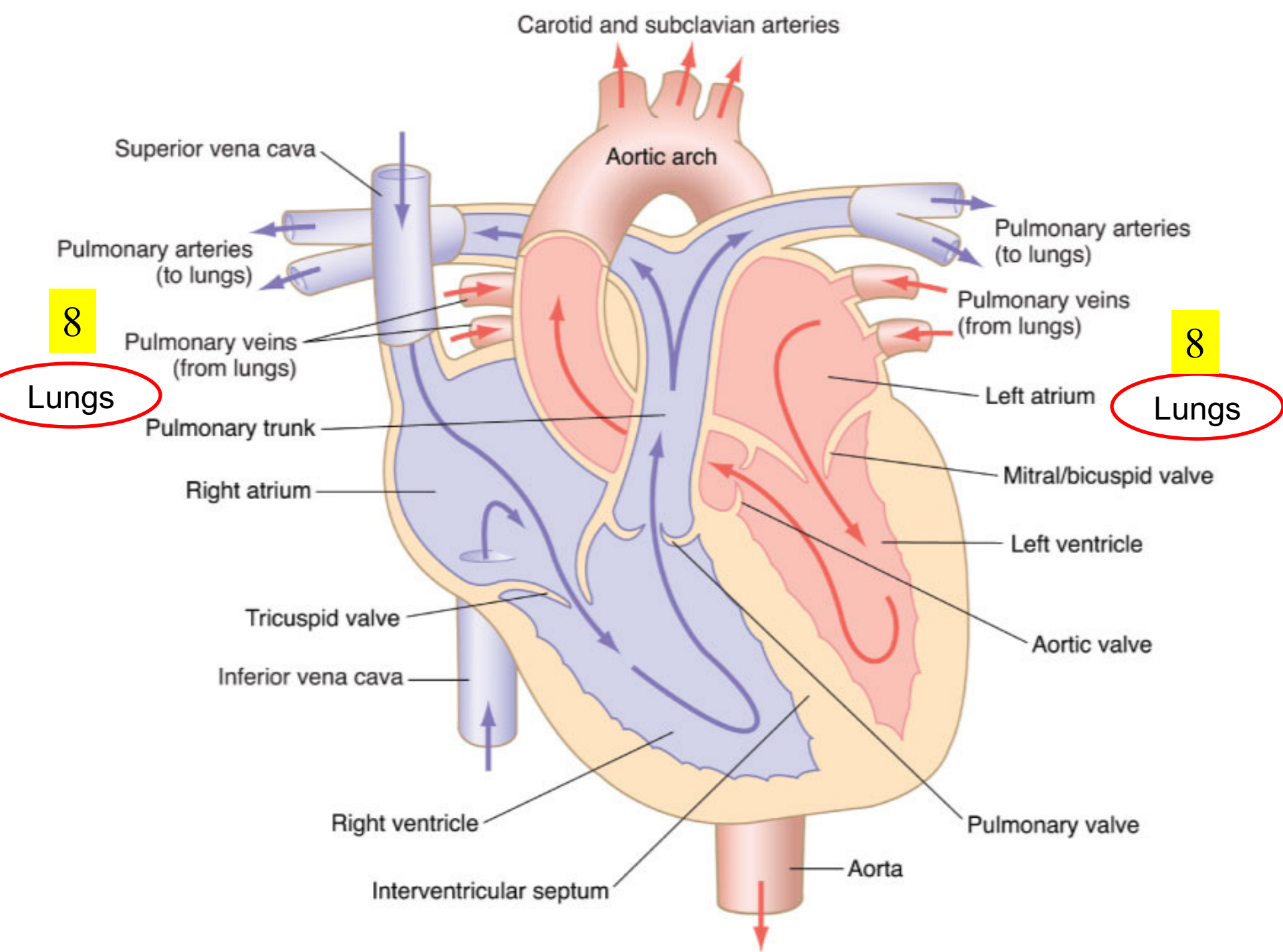
Carotid and subclavian arteries



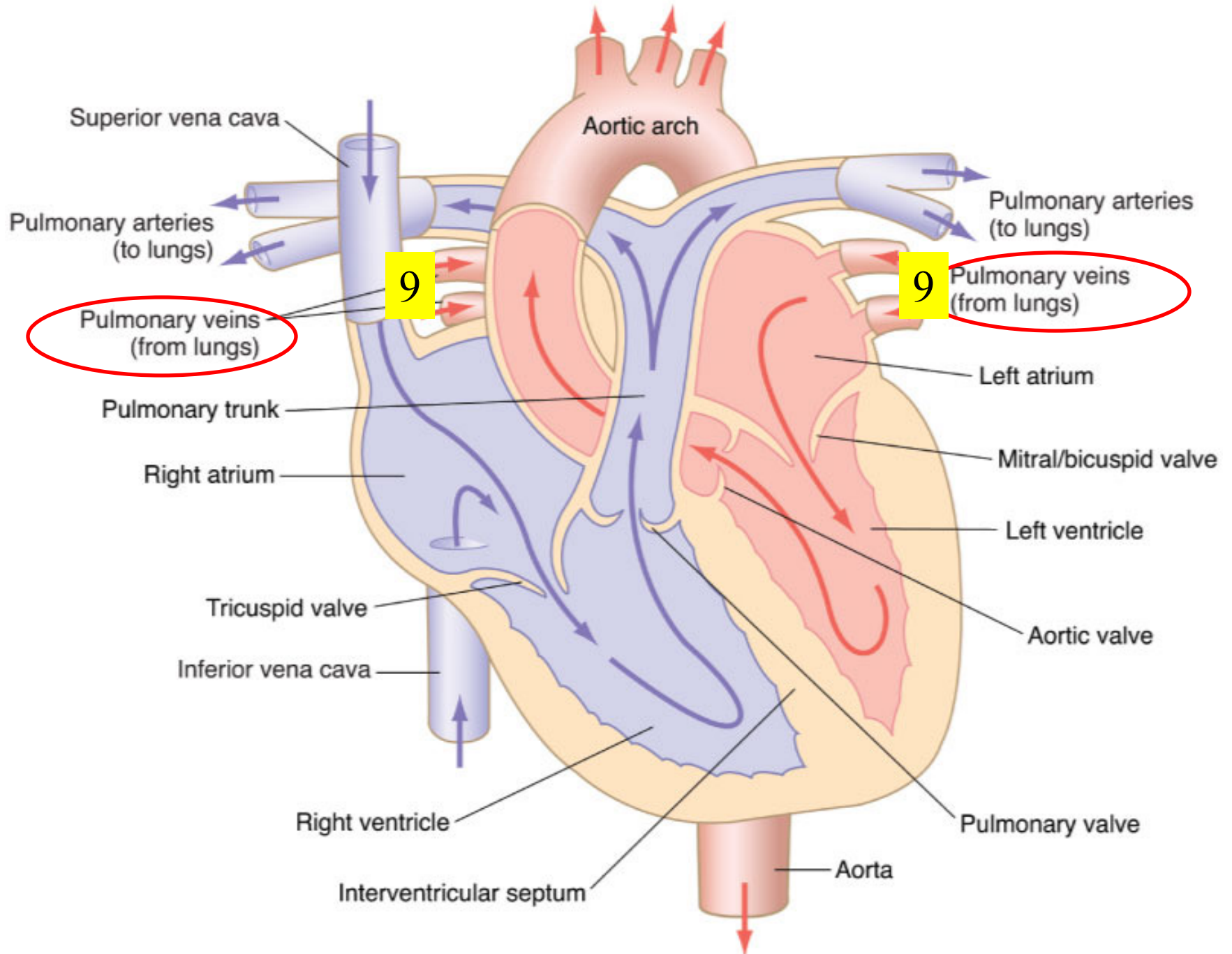
Carotid and subclavian arteries



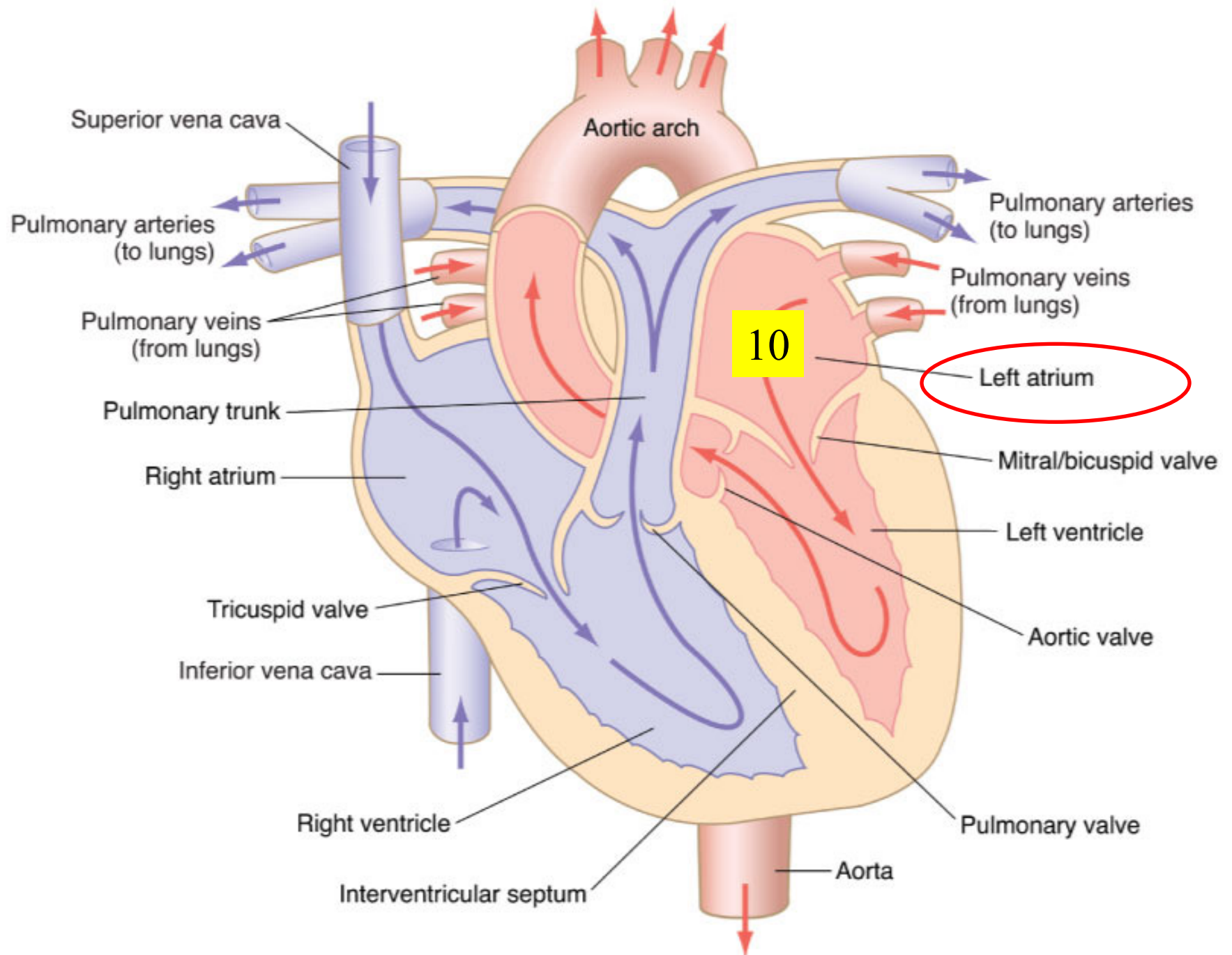




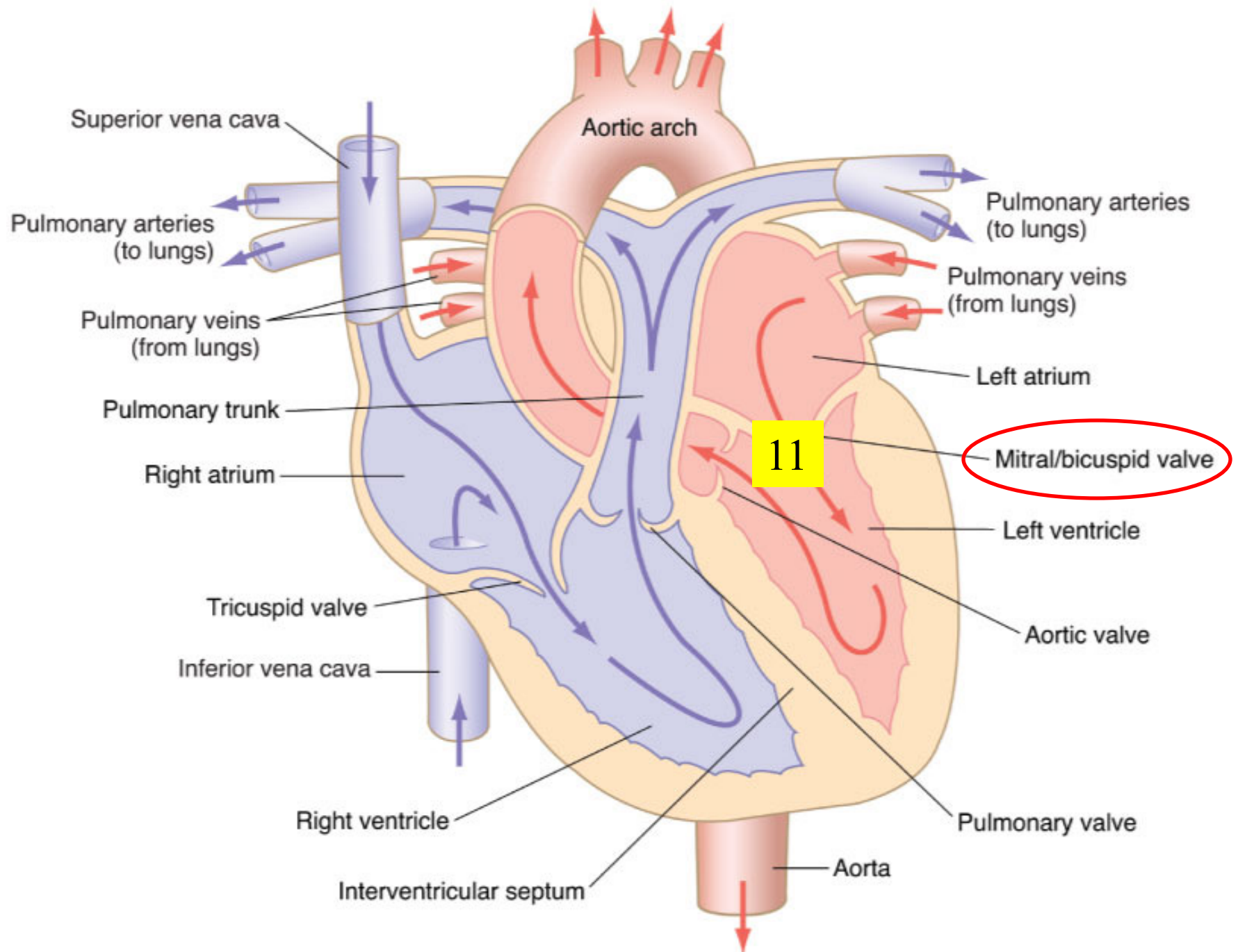
Carotid and subclavian arteries



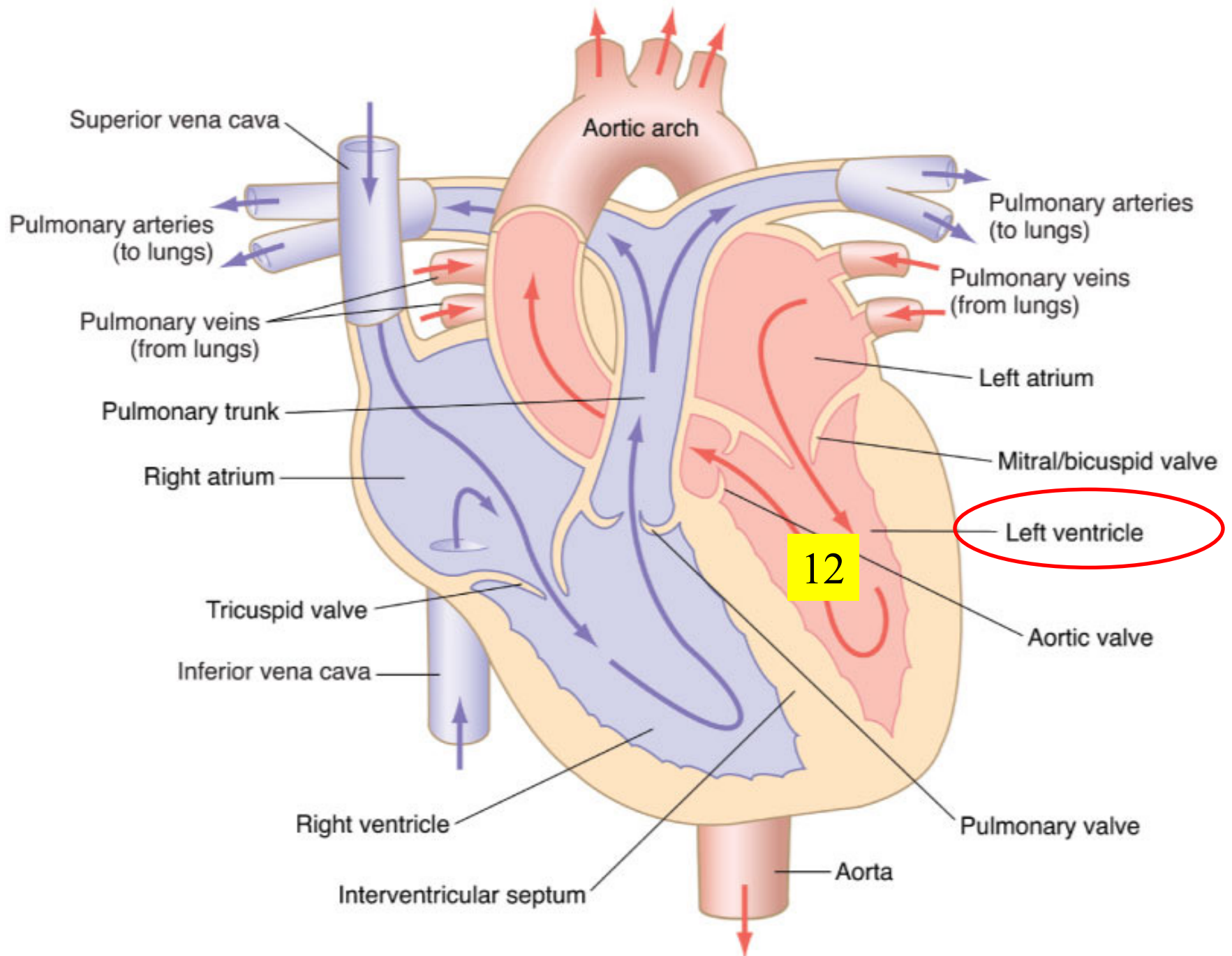
Carotid and subclavian arteries



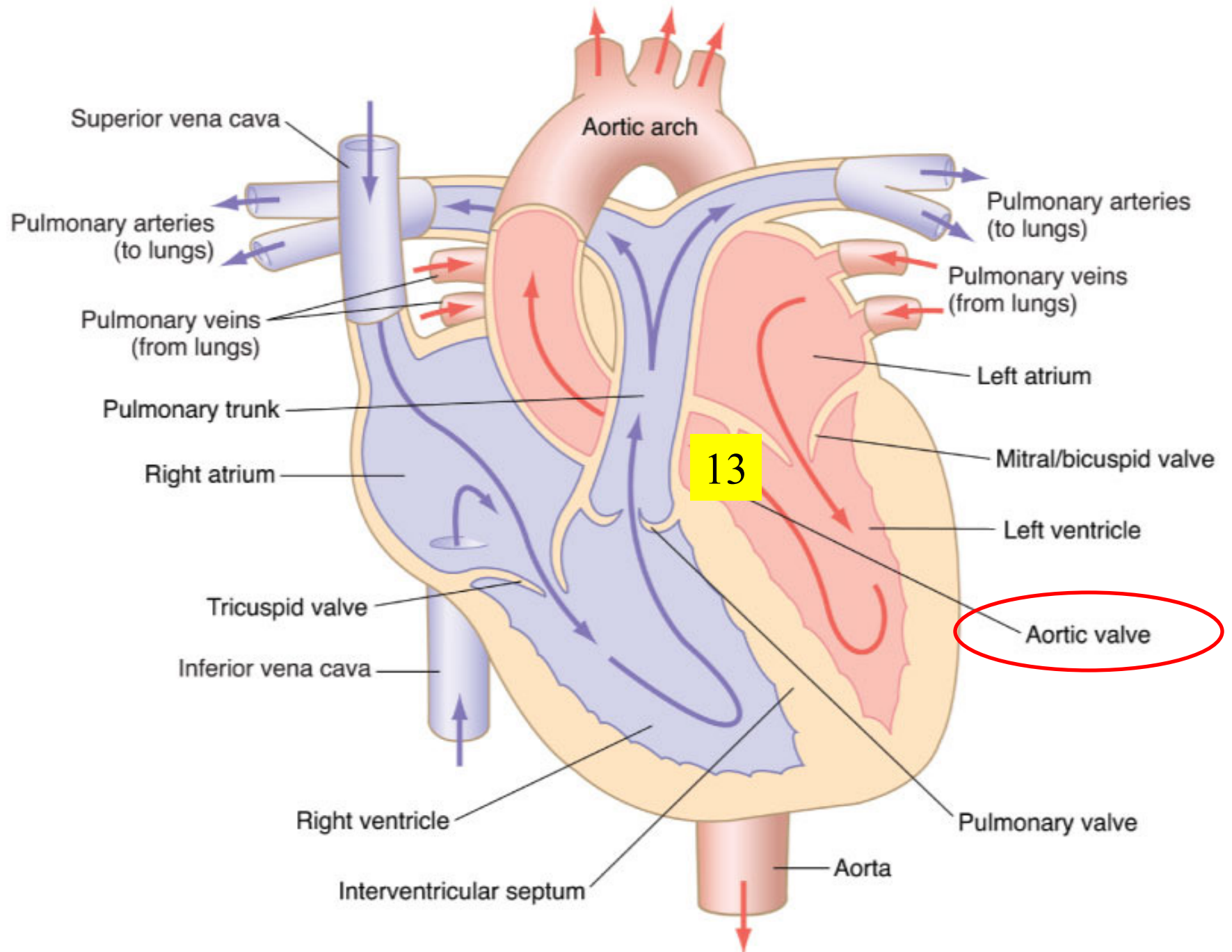
Carotid and subclavian arteries



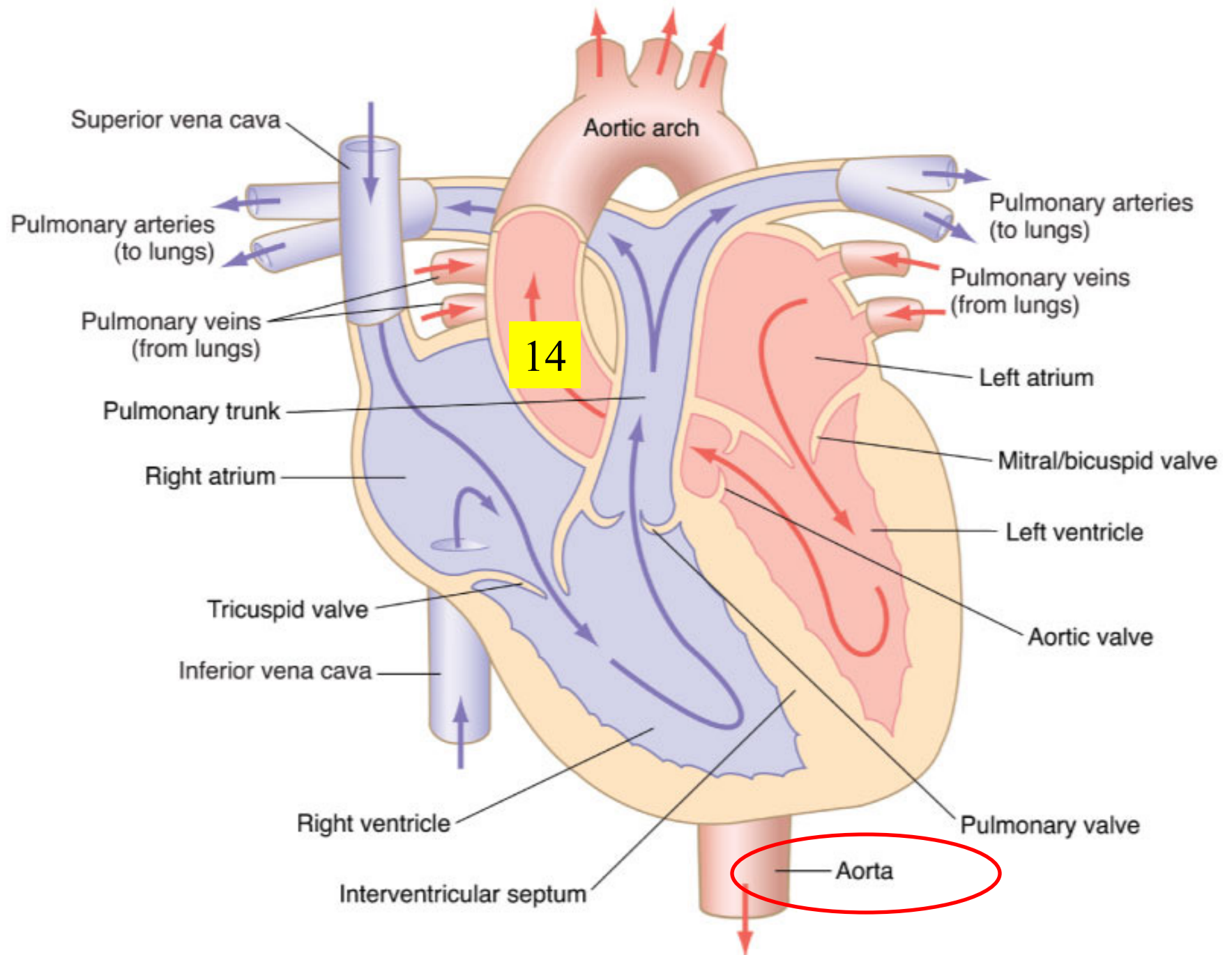
Carotid and subclavian arteries



Carotid and subclavian arteries



Carotid and subclavian arteries





35a Cardiovascular System - Blood Cells, Tissues, and the Heart