



## 36a A&P: Cardiovascular System - Blood Vessel and Paths of Circulation



# 36a A&P: Cardiovascular System - Blood Vessels and Paths of Circulation

## Class Outline

5 minutes	Attendance, Breath of Arrival, and Reminders
10 minutes	Lecture:
25 minutes	Lecture:
15 minutes	Active study skills:
60 minutes	Total



# 36a A&P: Cardiovascular System - Blood Vessels and Paths of Circulation

## Class Reminders

### **Assignments:**

- 36a State Law Review Questions (Packet A: 167-172)
- 41a Review Questions (Packet A: 173-185)
- 43a Swedish: Outside Massages (Packet A: 57-62)

### **Quizzes and Exams:**

- 43a Kinesiology Quiz
  - (adductor magnus, gracilis, iliopsoas, sartorius, TFL, piriformis, quadratus femoris)
- 44a Quiz (33b, 35a, 36a, 37a/b, 38a, 39a, 40a, 41a/b, 42b, and 43a)
- 46a Exam

### **Preparation for upcoming classes:**

- 37a Pathology: Circulatory System
  - Werner: Chapter 5
  - Packet E: 73-74
  - RQ Packet A-169
- 37b Business: State Massage Law and Find a Job
  - Business Mastery: Chapters 7-11
  - Packet B: 33-36
  - RQ Packet A-170



# Classroom Rules

**Punctuality** - everybody's time is precious

- Be ready to learn at the start of class; we'll have you out of here on time
- Tardiness: arriving late, returning late after breaks, leaving during class, leaving early

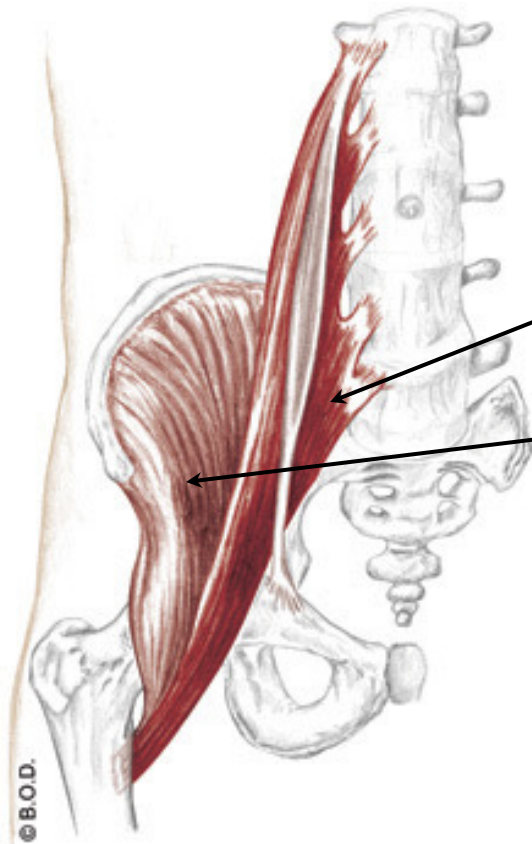
**The following are not allowed:**

- Bare feet
- Side talking
- Lying down
- Inappropriate clothing
- Food or drink except water
- Phones that are visible in the classroom, bathrooms, or internship

*You will receive one verbal warning, then you'll have to leave the room.*

# Iliopsoas

## Trail Guide, Page 332



**Iliopsoas** is the combination of psoas major and iliacus.

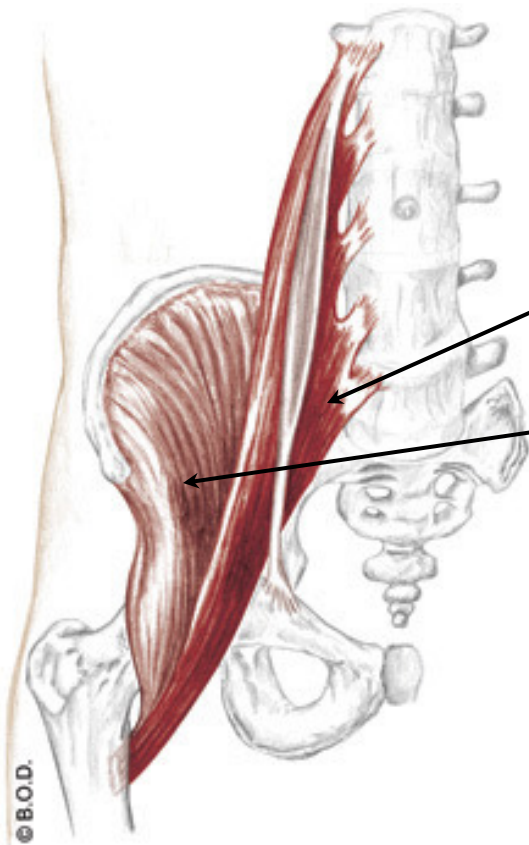
**Psoas major** stretches from the lumbar vertebrae to the lesser trochanter.

**Iliacus** is stockier. It begins in the iliac fossa and also inserts on the lesser trochanter.

Anterior View

# Iliopsoas

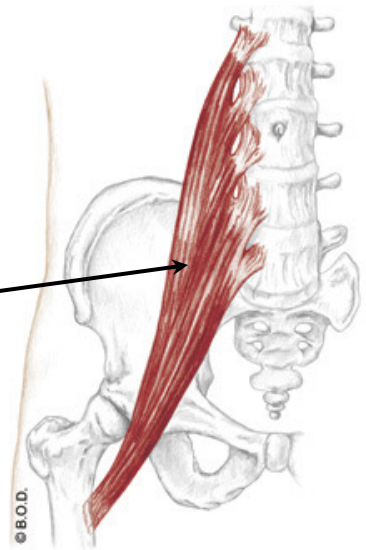
Trail Guide, Page 332



Anterior View

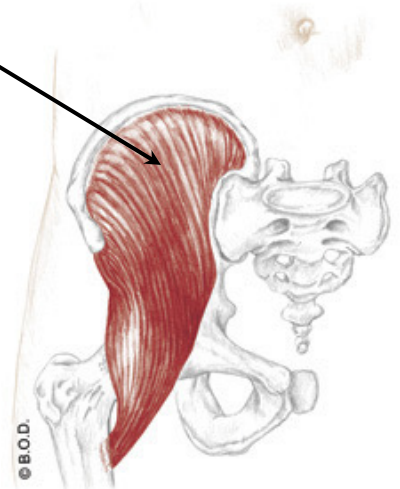**Psoas major**

**Iliacus**



Anterior View

Iliopsoas, what does it do?



Anterior View

# Psoas Major, page 332

**A** *With the origin fixed:*

**Flex** the hip (coxal joint)

May **laterally rotate** the hip (coxal joint)

*With the insertion fixed:*

**Flex** the trunk toward the thigh

**Tilt** the pelvis anteriorly

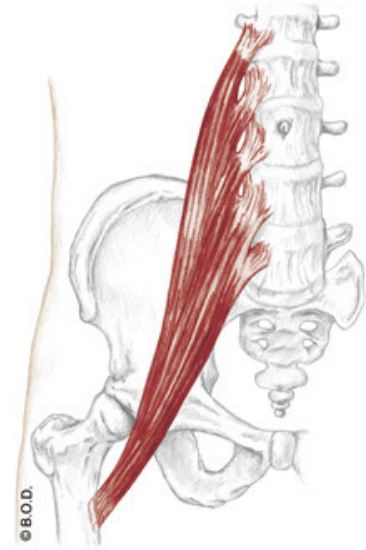
*Unilaterally:*

Assist to **laterally flex** the lumbar spine

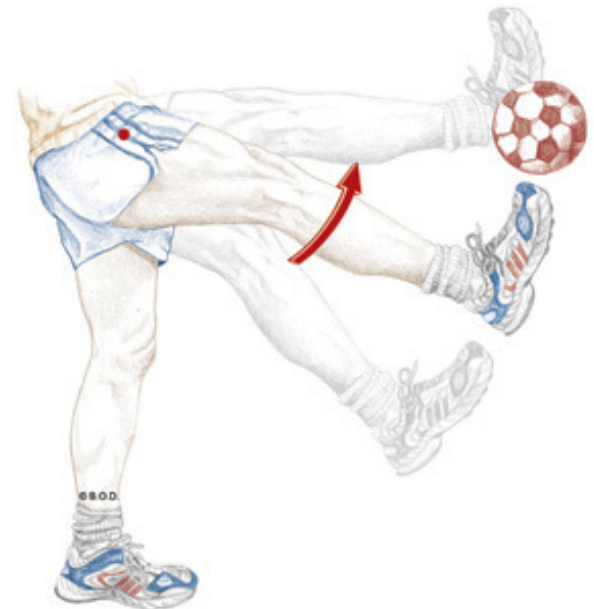**O** Bodies of lumbar vertebrae

Transverse processes of lumbar vertebrae

**I** Lesser trochanter



Anterior View



# Psoas Major, page 332

**A** *With the origin fixed:*  
**Flex** the hip (coxal joint)

May **laterally rotate** the hip (coxal joint)

*With the insertion fixed:*  
**Flex** the trunk toward the thigh

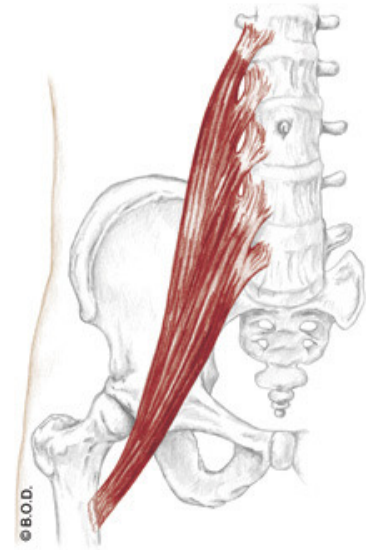
**Tilt** the pelvis anteriorly

*Unilaterally:*  
Assist to **laterally flex** the lumbar spine

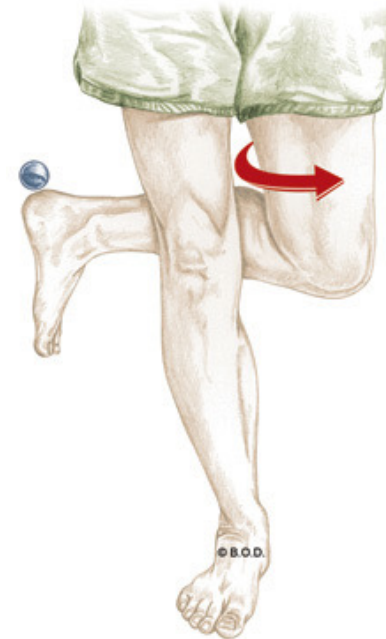
**O** Bodies of lumbar vertebrae

Transverse processes of lumbar vertebrae

**I** Lesser trochanter



Anterior View





# Psoas Major, page 332

**A** *With the origin fixed:*  
**Flex** the hip (coxal joint)

May **laterally rotate** the hip (coxal joint)

*With the insertion fixed:*

**Flex** the trunk toward the thigh

**Tilt** the pelvis anteriorly

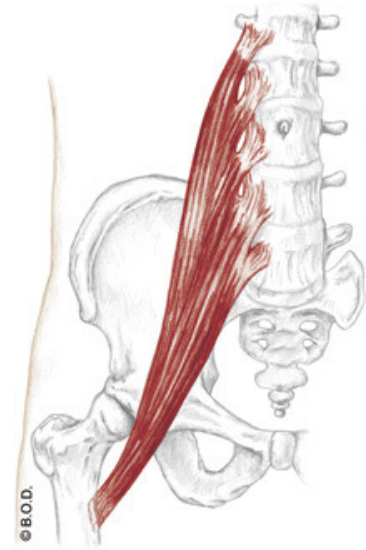
*Unilaterally:*

Assist to **laterally flex** the lumbar spine

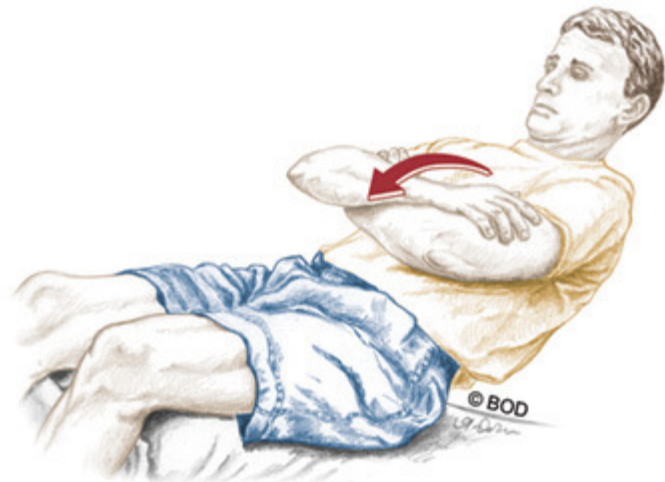**O** Bodies of lumbar vertebrae

Transverse processes of lumbar vertebrae

**I** Lesser trochanter



Anterior View



# Psoas Major, page 332

**A** *With the origin fixed:*  
**Flex** the hip (coxal joint)

May **laterally rotate** the hip (coxal joint)

*With the insertion fixed:*  
**Flex** the trunk toward the thigh

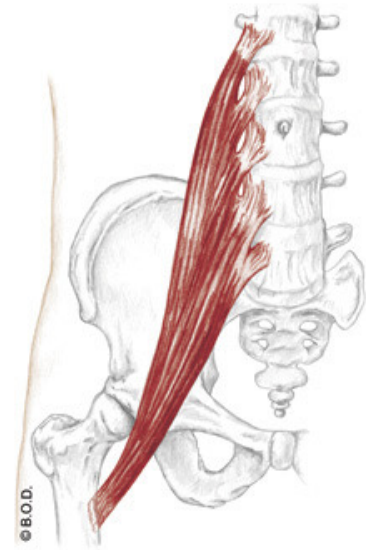
**Tilt** the pelvis anteriorly

*Unilaterally:*  
Assist to **laterally flex** the lumbar spine

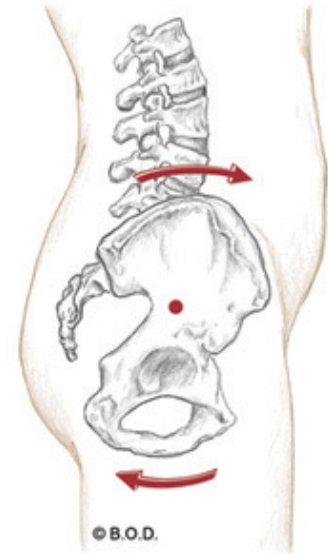
**O** Bodies of lumbar vertebrae

Transverse processes of lumbar vertebrae

**I** Lesser trochanter



Anterior View



Lateral View

# Psoas Major, page 332

**A** *With the origin fixed:*  
**Flex** the hip (coxal joint)

May **laterally rotate** the hip (coxal joint)

*With the insertion fixed:*  
**Flex** the trunk toward the thigh

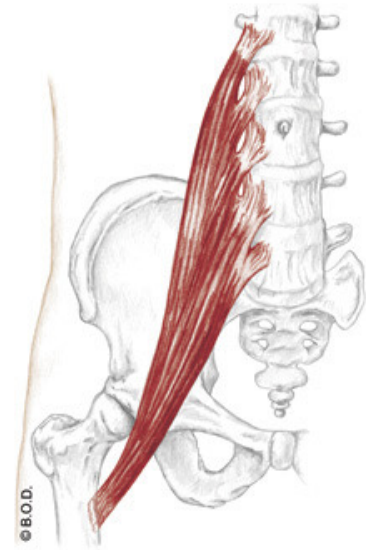
**Tilt** the pelvis anteriorly

*Unilaterally:*  
Assist to **laterally flex** the lumbar spine

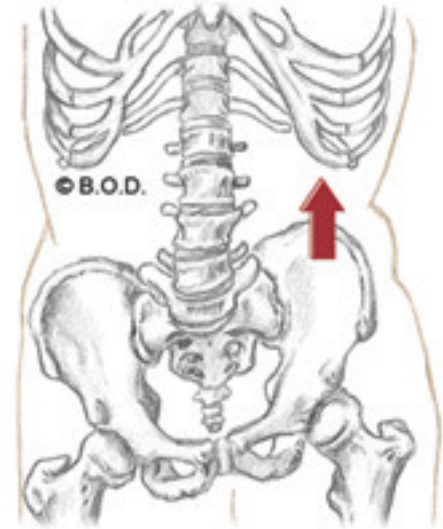
**O** Bodies of lumbar vertebrae

Transverse processes of lumbar vertebrae

**I** Lesser trochanter



Anterior View



# Psoas Major, page 332

**A** *With the origin fixed:*  
**Flex** the hip (coxal joint)

May **laterally rotate** the hip (coxal joint)

*With the insertion fixed:*  
**Flex** the trunk toward the thigh

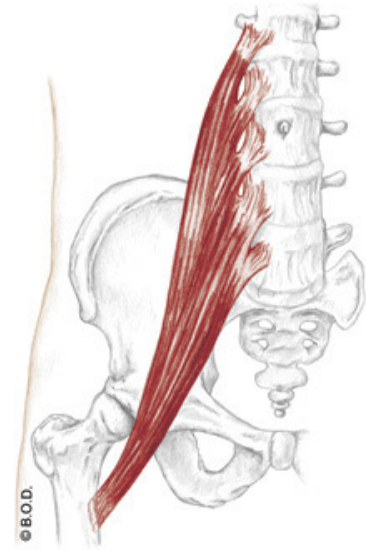
**Tilt** the pelvis anteriorly

*Unilaterally:*  
Assist to **laterally flex** the lumbar spine

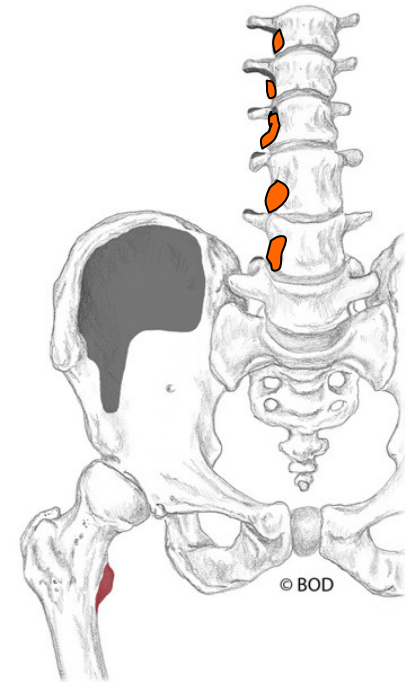
**O** Bodies of lumbar vertebrae

Transverse processes of lumbar vertebrae

**I** Lesser trochanter



Anterior View



# Psoas Major, page 332

**A** *With the origin fixed:*  
**Flex** the hip (coxal joint)

May **laterally rotate** the hip (coxal joint)

*With the insertion fixed:*  
**Flex** the trunk toward the thigh

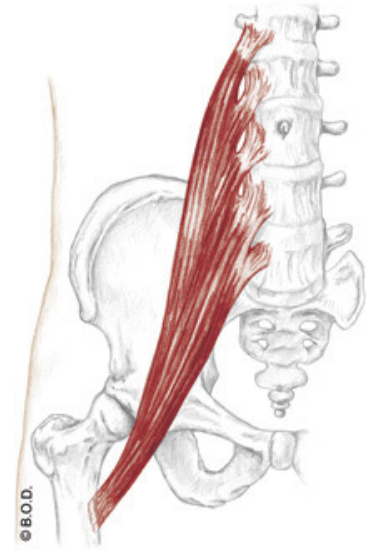
**Tilt** the pelvis anteriorly

*Unilaterally:*  
Assist to **laterally flex** the lumbar spine

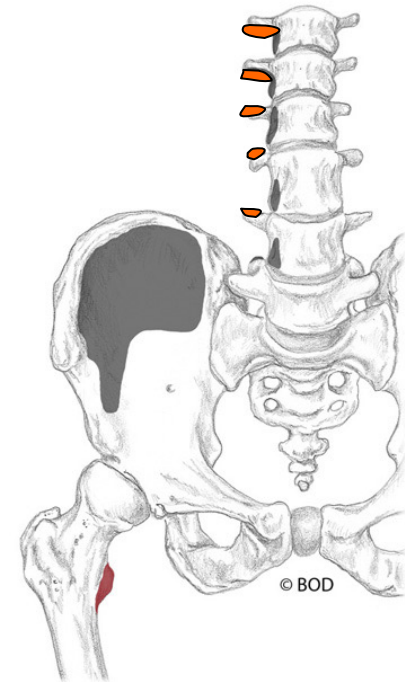
**O** Bodies of lumbar vertebrae

Transverse processes of lumbar vertebrae

**I** Lesser trochanter



Anterior View



# Psoas Major, page 332

**A** *With the origin fixed:*  
**Flex** the hip (coxal joint)

May **laterally rotate** the hip (coxal joint)

*With the insertion fixed:*  
**Flex** the trunk toward the thigh

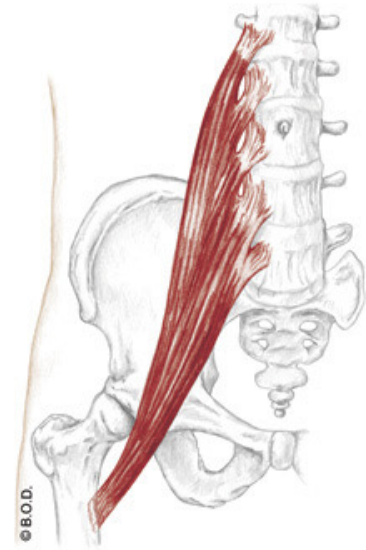
**Tilt** the pelvis anteriorly

*Unilaterally:*  
Assist to **laterally flex** the lumbar spine

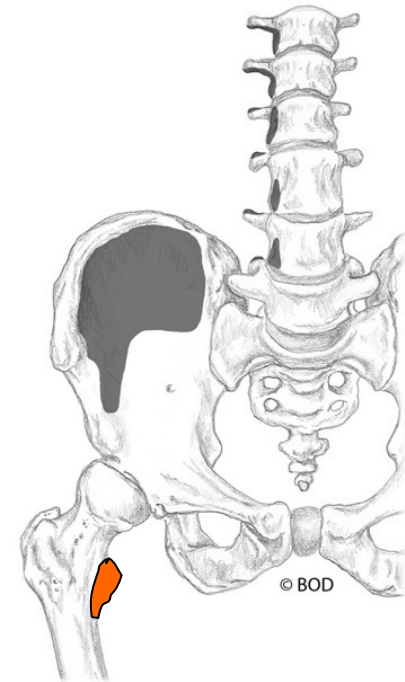
**O** Bodies of lumbar vertebrae

Transverse processes of lumbar vertebrae

**I** Lesser trochanter



Anterior View



Time to shift gears



From psoas major to iliacus . . .



# Iliacus, page 332

**A** *With the origin fixed:*

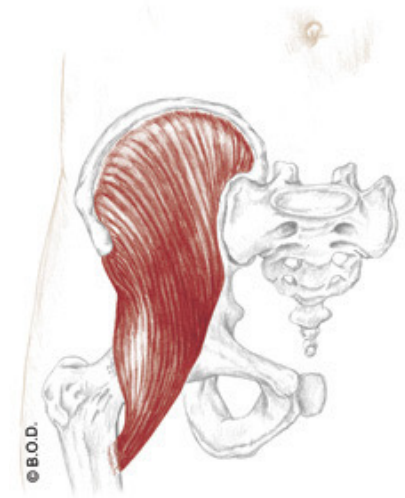
**Flex** the hip (coxal joint)

May **laterally rotate** the hip (coxal joint)

*With the insertion fixed:*

**Flex** the trunk toward the thigh

**Tilt** the pelvis anteriorly



Anterior View

**O** Iliac fossa

**I** Lesser trochanter





# Iliacus, page 332

**A** *With the origin fixed:*  
**Flex** the hip (coxal joint)

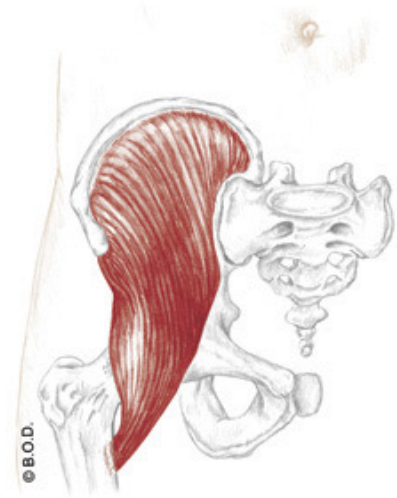
May **laterally rotate** the hip (coxal joint)

*With the insertion fixed:*  
**Flex** the trunk toward the thigh

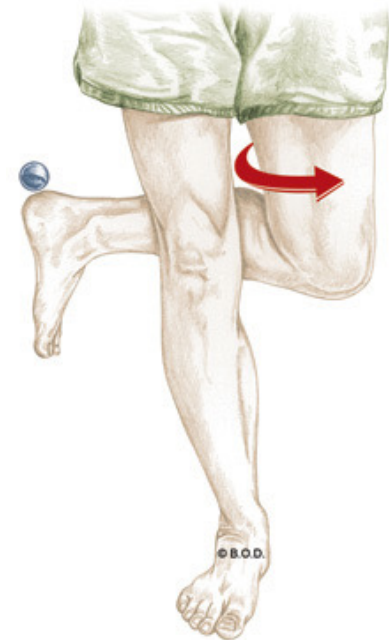
**Tilt** the pelvis anteriorly

**O** Iliac fossa

**I** Lesser trochanter



Anterior View



# Iliacus, page 332

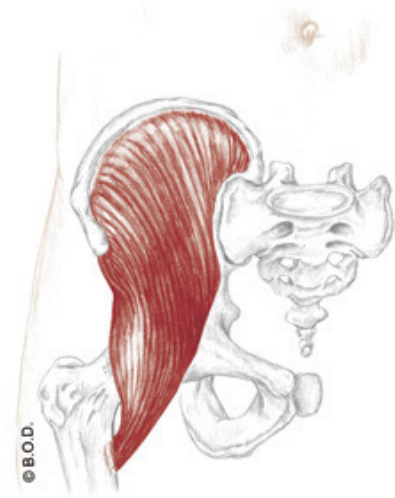
**A** *With the origin fixed:*  
**Flex** the hip (coxal joint)

May **laterally rotate** the hip (coxal joint)

*With the insertion fixed:*

**Flex** the trunk toward the thigh

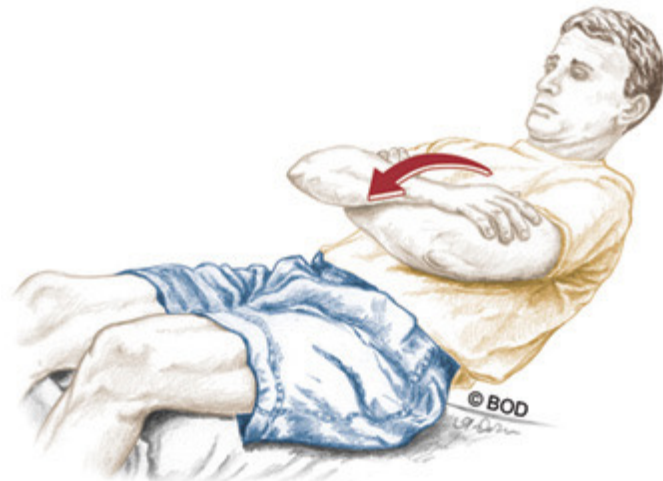**Tilt** the pelvis anteriorly



Anterior View

**O** Iliac fossa

**I** Lesser trochanter



# Iliacus, page 332

**A** *With the origin fixed:*  
**Flex** the hip (coxal joint)

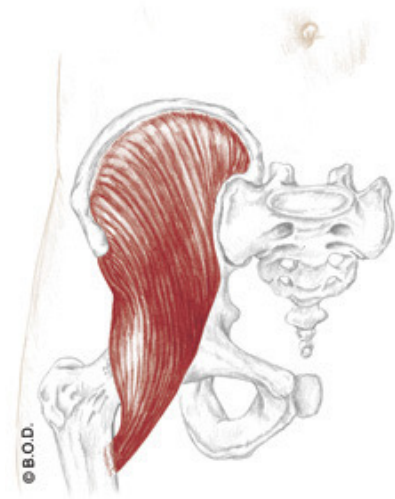
May **laterally rotate** the hip (coxal joint)

*With the insertion fixed:*  
**Flex** the trunk toward the thigh

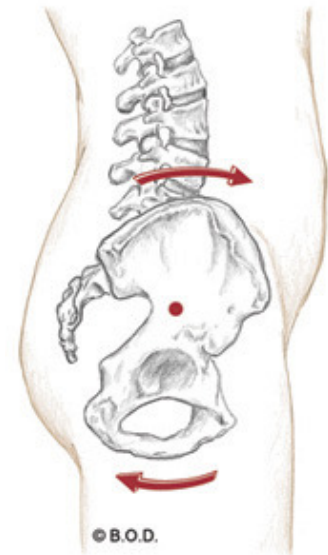
**Tilt** the pelvis anteriorly

**O** Iliac fossa

**I** Lesser trochanter



Anterior View



# Iliacus, page 332

**A** *With the origin fixed:*  
**Flex** the hip (coxal joint)

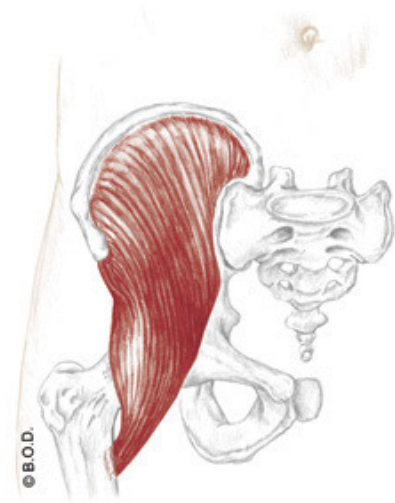
May **laterally rotate** the hip (coxal joint)

*With the insertion fixed:*  
**Flex** the trunk toward the thigh

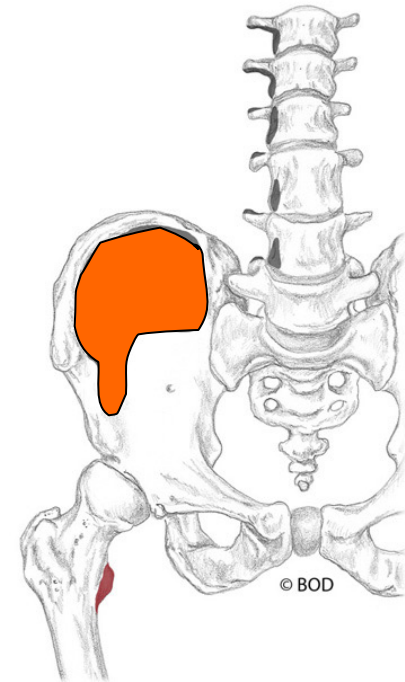
**Tilt** the pelvis anteriorly

**O** Iliac fossa

**I** Lesser trochanter



Anterior View



# Iliacus, page 332

**A** *With the origin fixed:*  
**Flex** the hip (coxal joint)

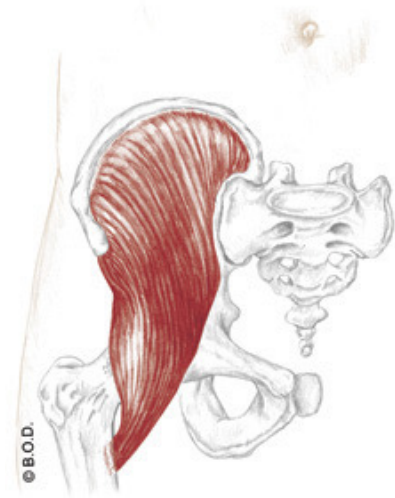
May **laterally rotate** the hip (coxal joint)

*With the insertion fixed:*  
**Flex** the trunk toward the thigh

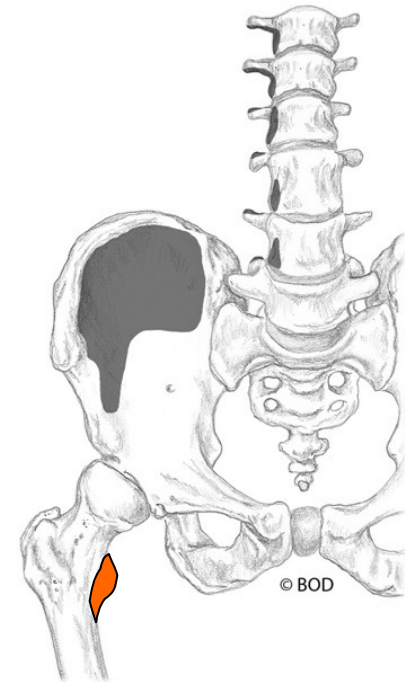
**Tilt** the pelvis anteriorly

**O** Iliac fossa

**I** Lesser trochanter



Anterior View





## 36a A&P: Cardiovascular System - Blood Vessels and Paths of Circulation

E - 69



# Blood Vessels

Walls of Arteries and Veins

Arteries

Pulse

Capillary

Veins

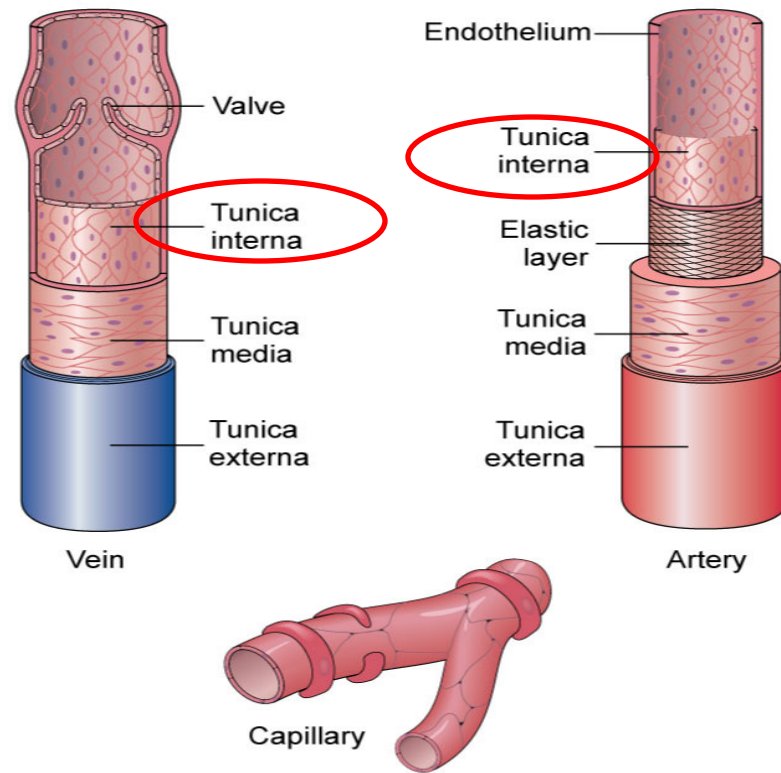
Venous Return

# Walls of Arteries and Veins

**Tunica interna (AKA: tunica intima)** Innermost layer of a blood vessel.

Endothelium fused with a small quantity of elastic connective tissue.

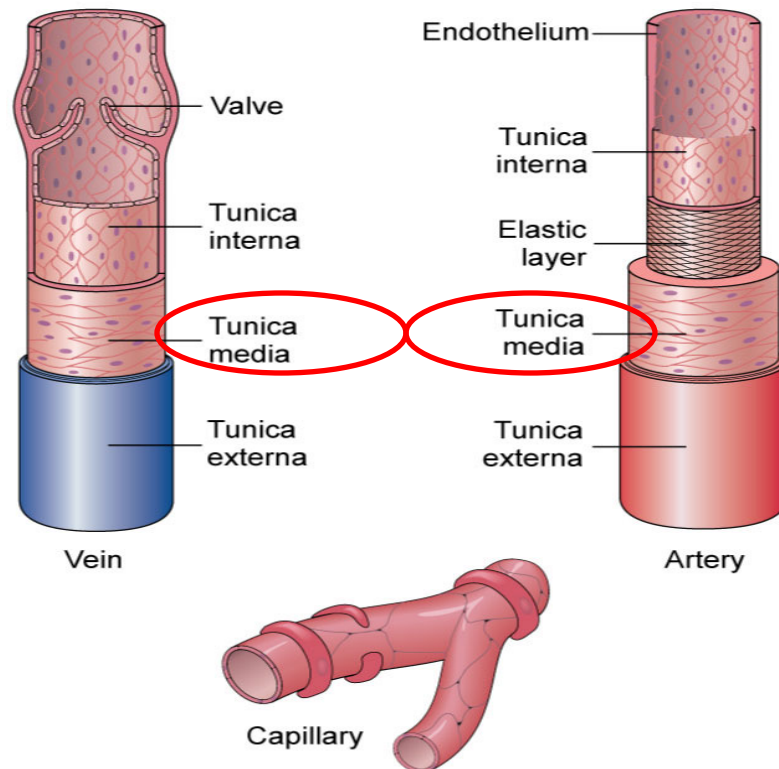
Valves assists venous return by only allowing blood to move back toward the heart.





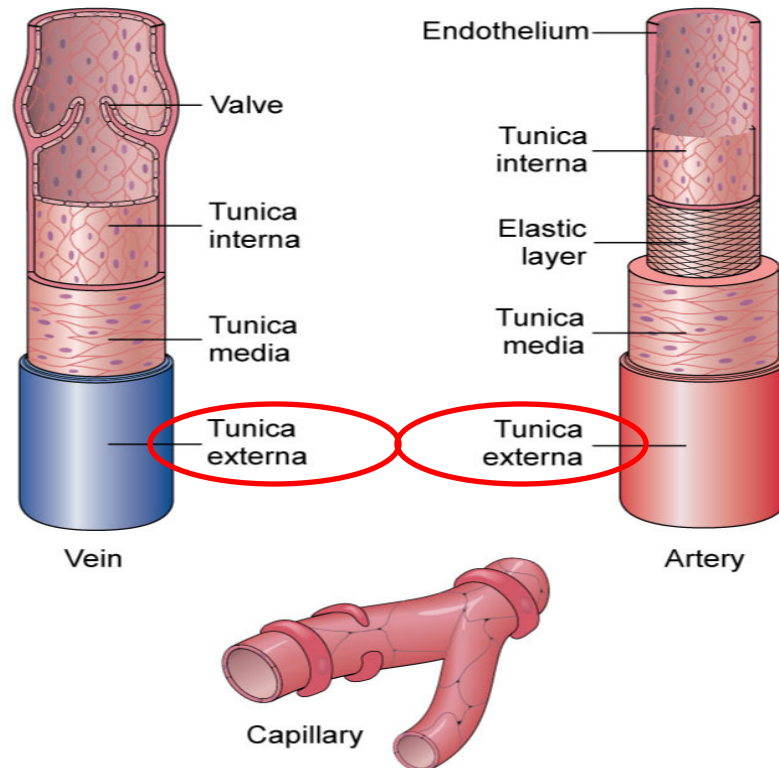
# Walls of Arteries and Veins

**Tunica media** Middle layer of a blood vessel. Contains both connective tissue and smooth muscle.



# Walls of Arteries and Veins

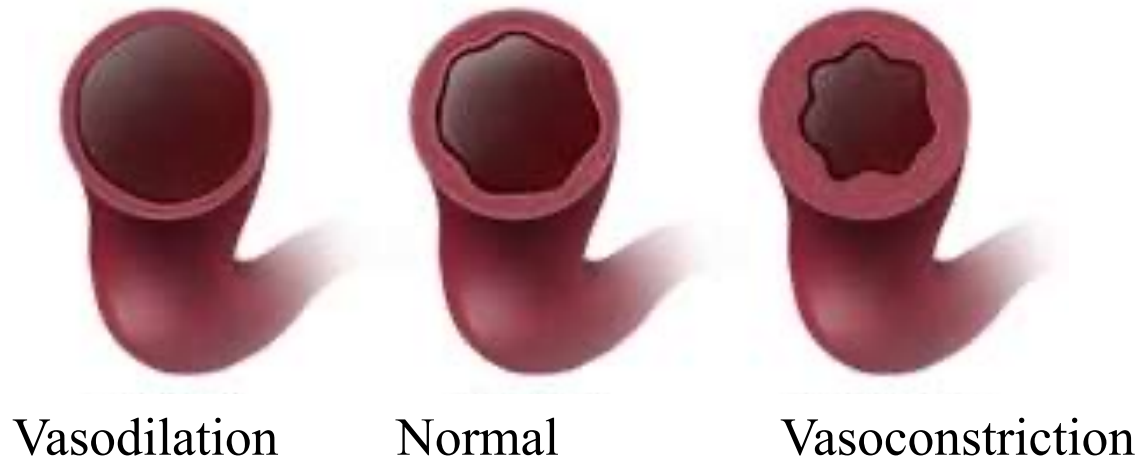
**Tunica externa (AKA: tunica adventitia)** Outer layer of a blood vessel. Possesses mostly dense connective tissue.



# Walls of Arteries and Veins

**Vasodilation** Enlargement of the vascular lumen's diameter.

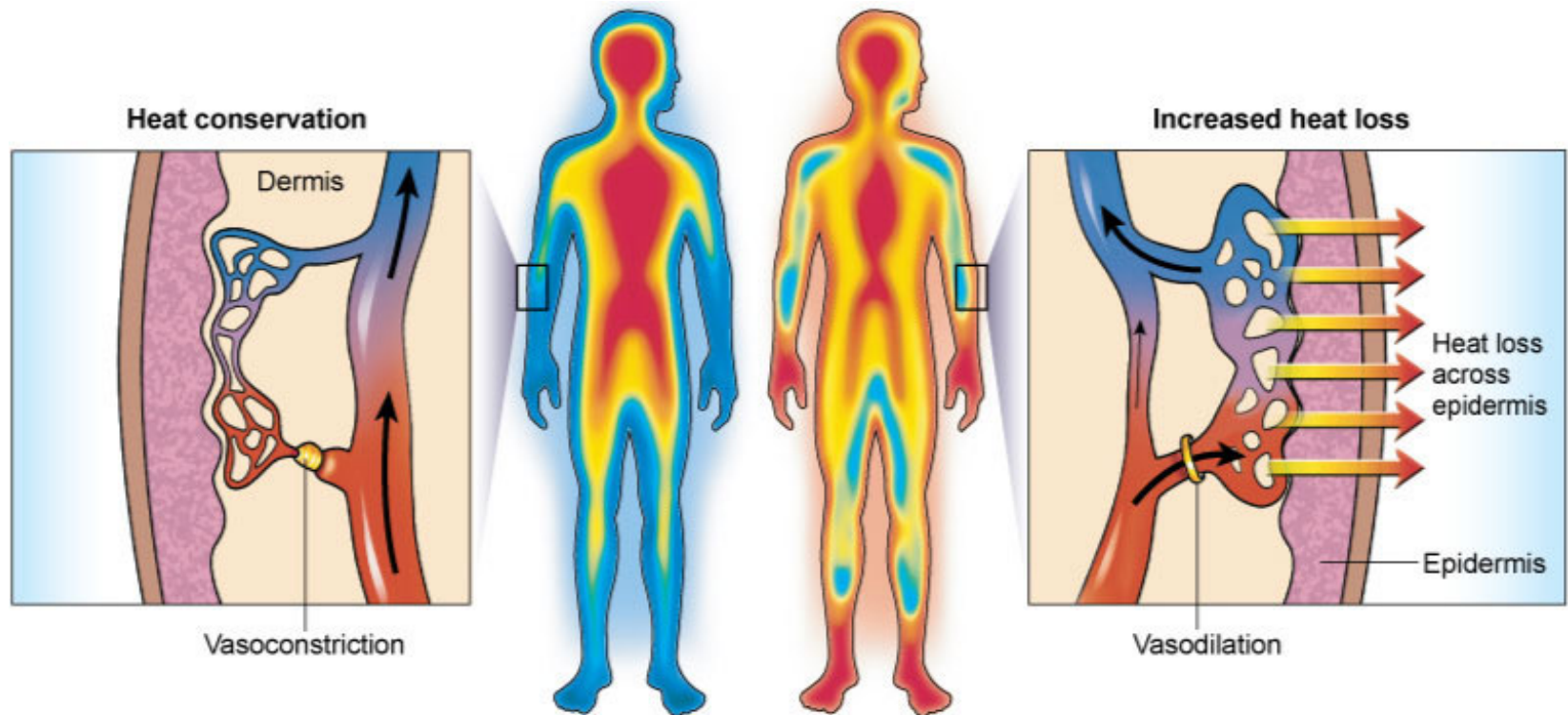
**Vasoconstriction** Narrowing of the vascular lumen's diameter.



# Walls of Arteries and Veins

**Vasodilation** Enlargement of the vascular lumen's diameter.

**Vasoconstriction** Narrowing of the vascular lumen's diameter.





## Walls of Arteries and Veins

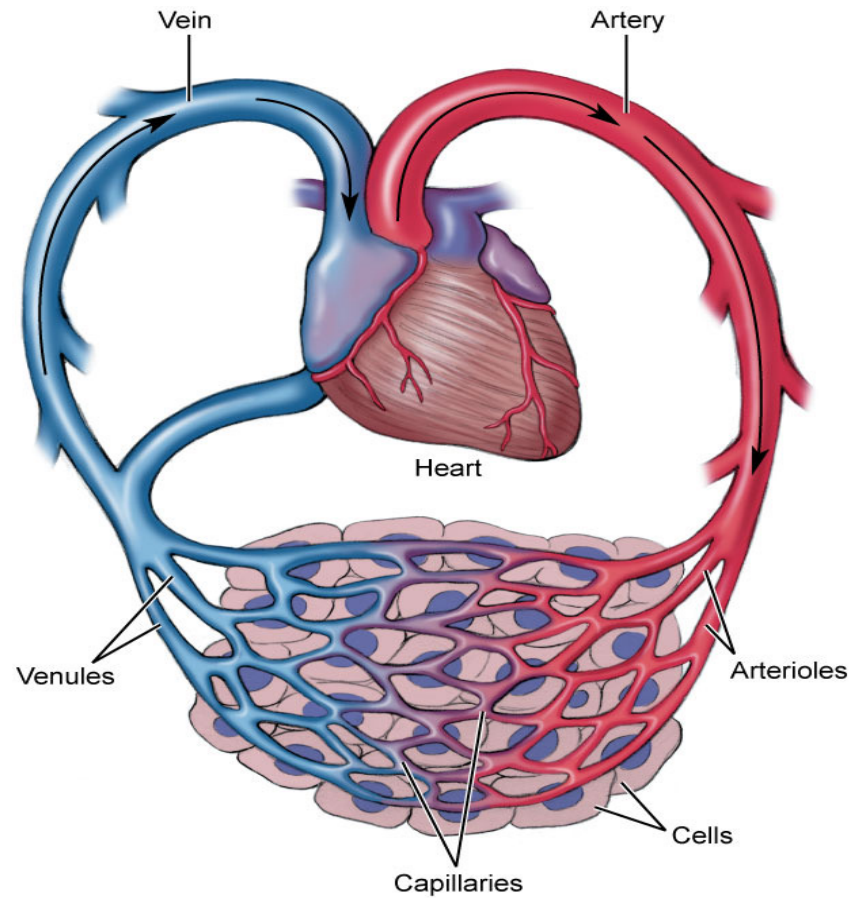
**Hyperemia** Increased local blood flow causing the skin to become reddened and warm.

**Ischemia** Local abnormal decrease in blood flow. Often marked by pain and tissue dysfunction.

# Arteries

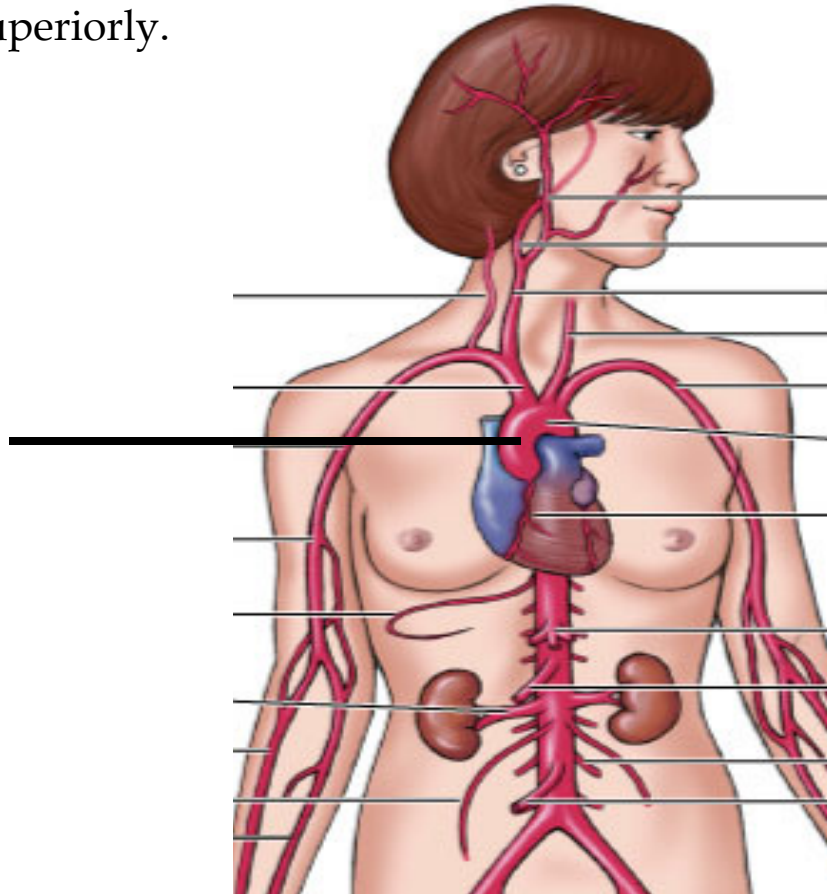
**Artery** Vessel that carries blood away from the heart to the tissues of the body.

**Arterioles** Small-sized arteries.



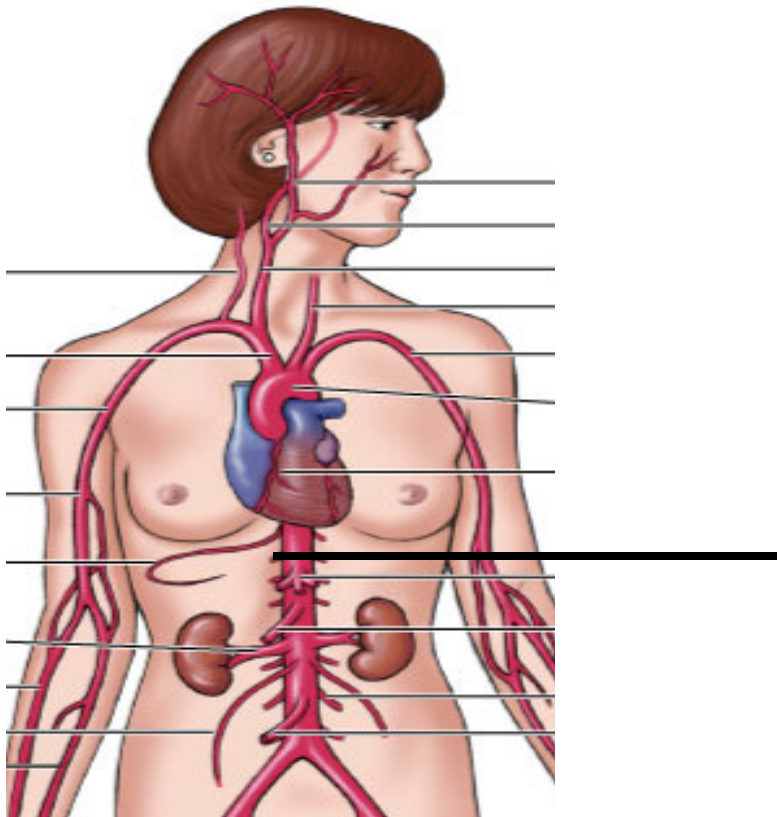
# Arteries

**Ascending aorta** Very large artery that begins at the left ventricle and travels superiorly.



# Arteries

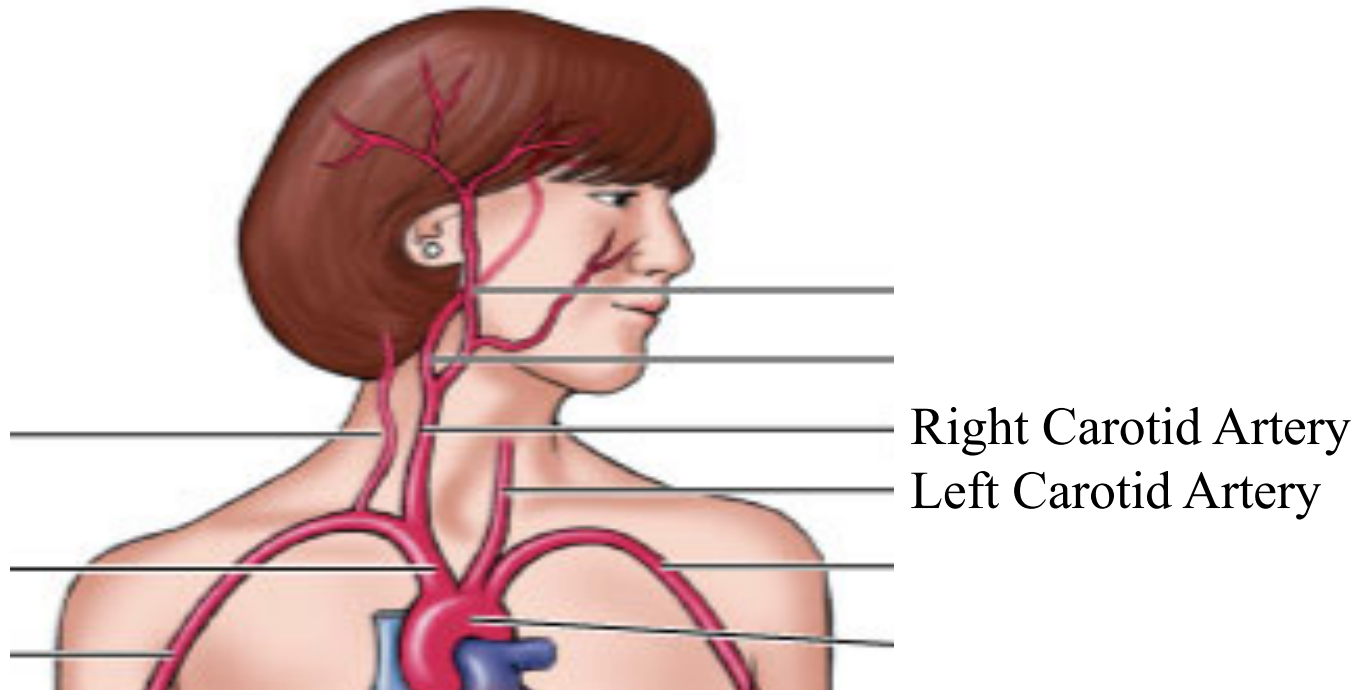
**Descending aorta** Very large artery that is a continuation of the ascending aorta that branches off and travels inferiorly.





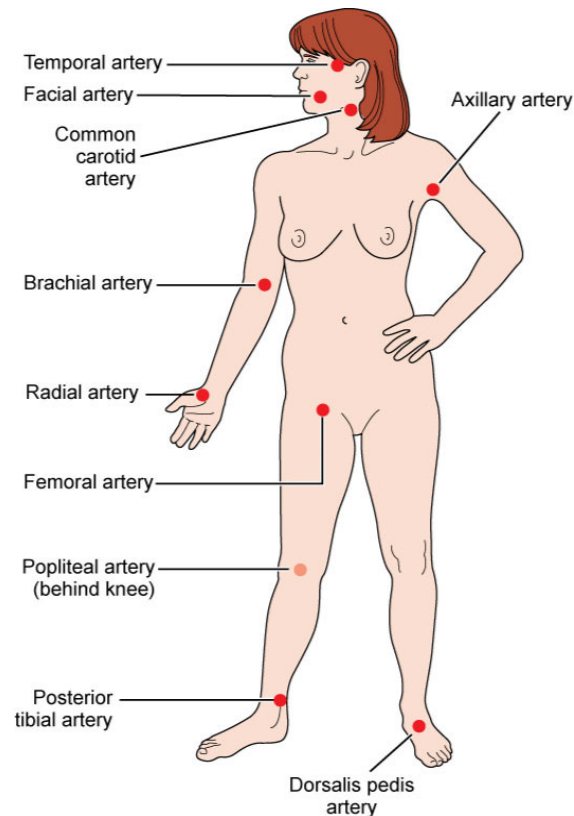
# Arteries

**Common carotid arteries** Two arteries located in the throat.



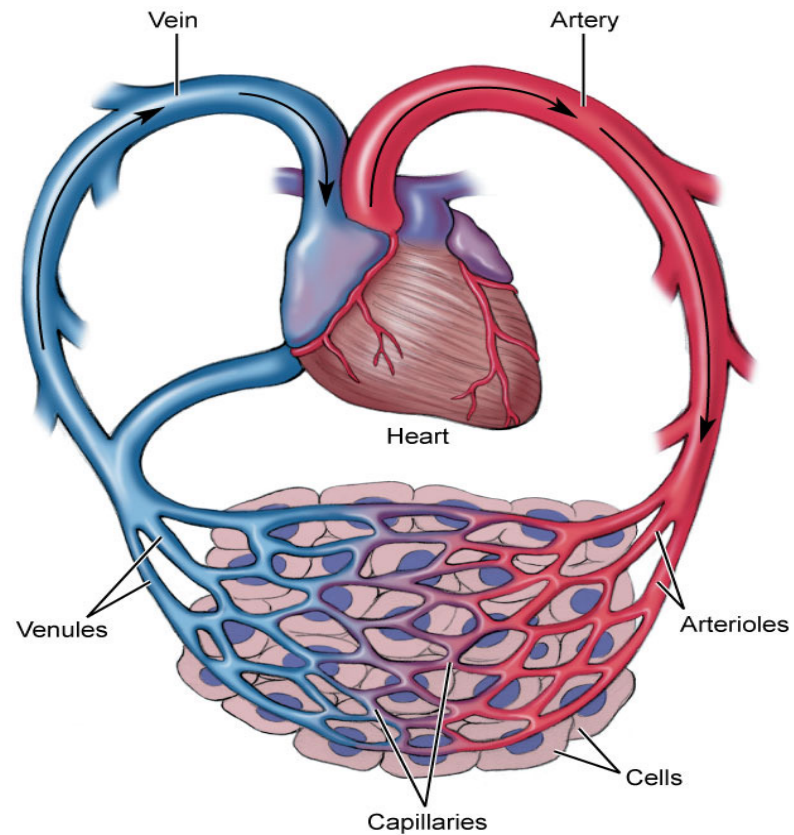
# Arteries

**Pulse** Expansion effect of arteries that occurs when the left ventricle contracts and produces a \_\_\_\_\_ wave \_\_\_\_\_ of blood that surges through and expands arterial walls.



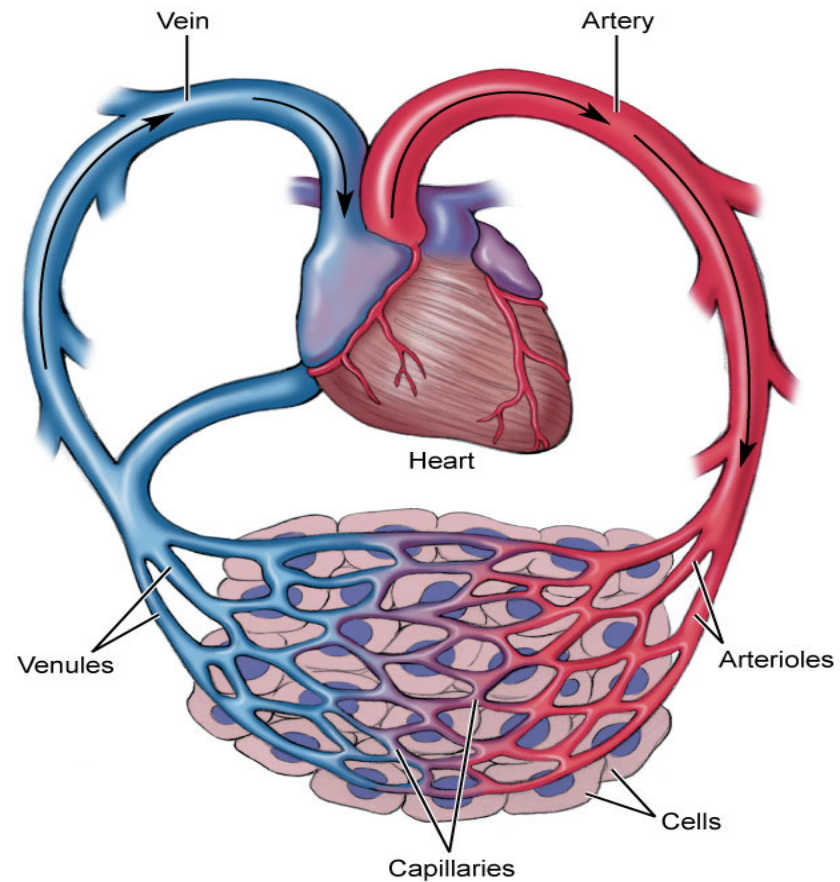
# Capillaries

**Capillary** Vessel between an arteriole and a venule. Possesses a thin, permeable membrane for efficient gas exchange with tissues.



# Capillaries

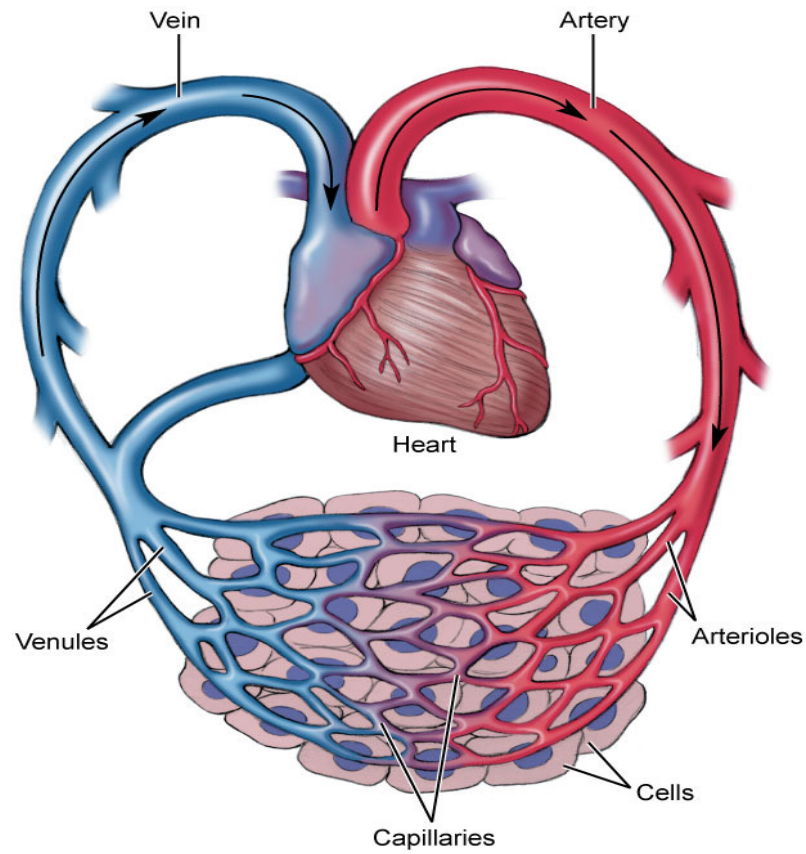
**Microcirculation** Flow of blood through a capillary bed.



# Veins

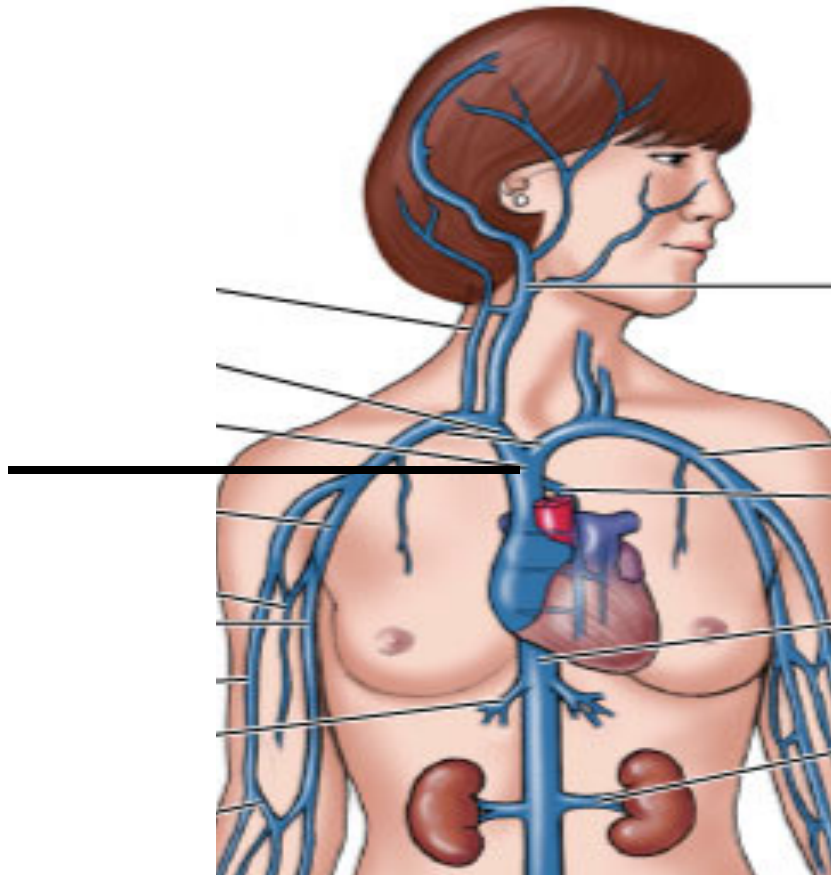
**Vein** Vessel that carries blood toward the heart.

**Venules** Small-sized vein that connects with capillaries.



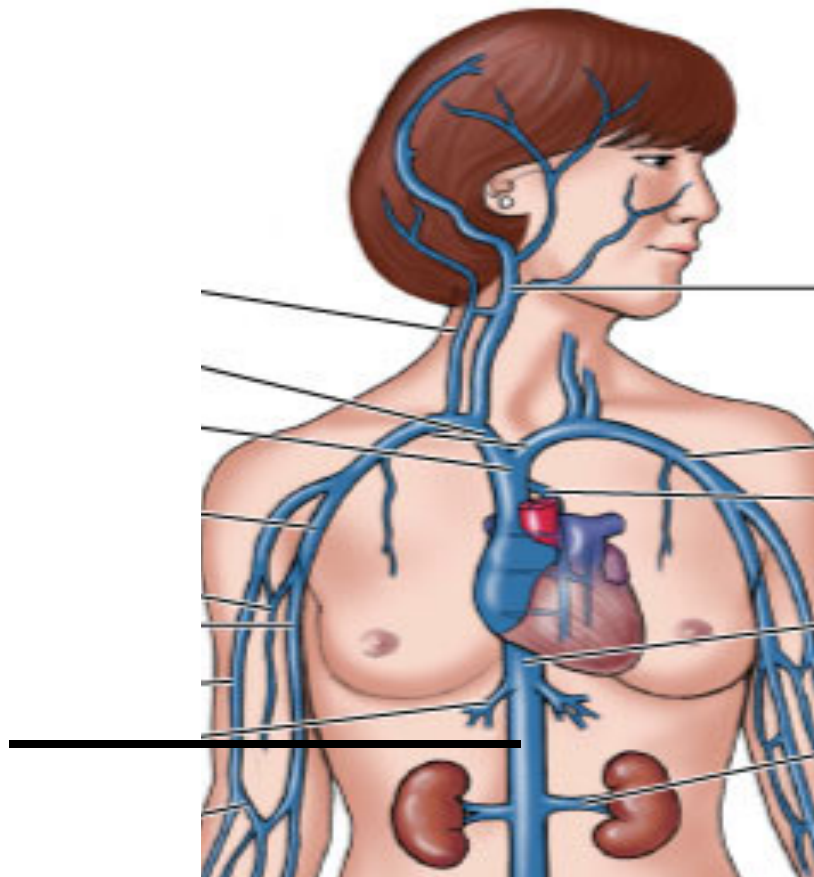
# Veins

**Superior vena cava** Very large vein that empties blood from the head and arms into the right atrium.



# Veins

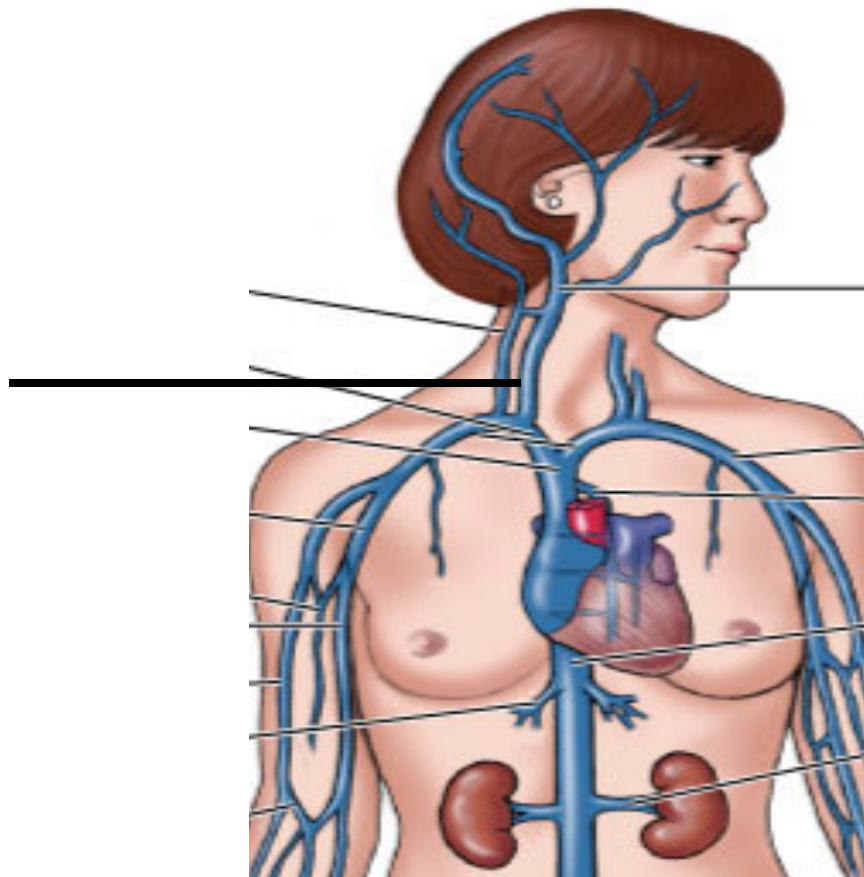
**Inferior vena cava** Very large vein that empties blood from the abdomen into the right atrium.





# Veins

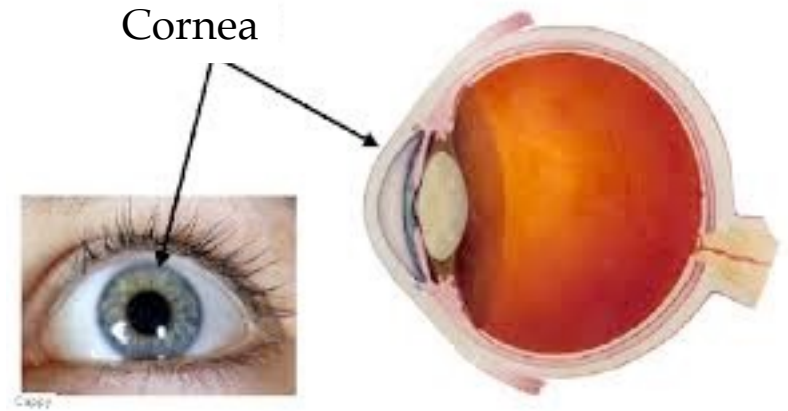
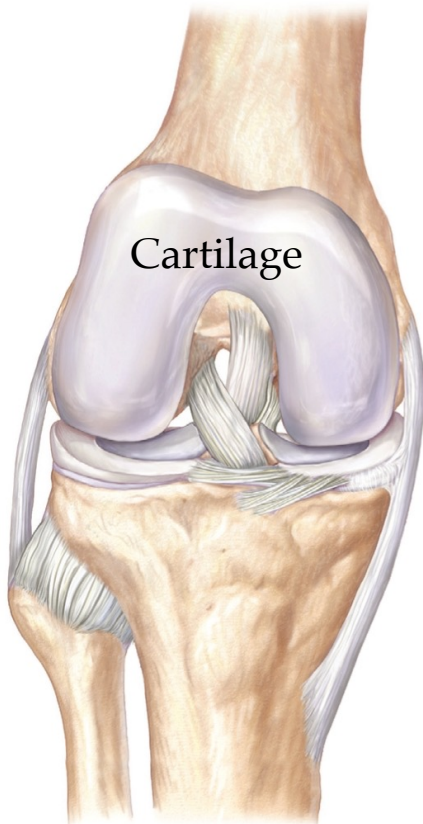
**Jugular** Vein in the throat that drains blood from the face, head, neck, and brain.



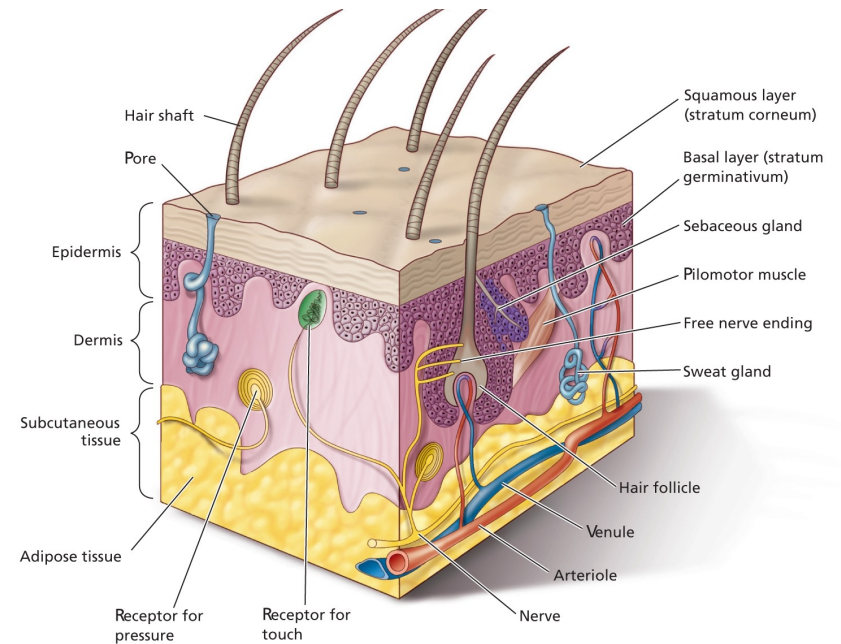


# Blood Vessels

**Avascular** Lacking blood vessels.



## Epithelial tissues of the epidermis





# Venous Return

**Venous return** Veins return blood to the heart passively.

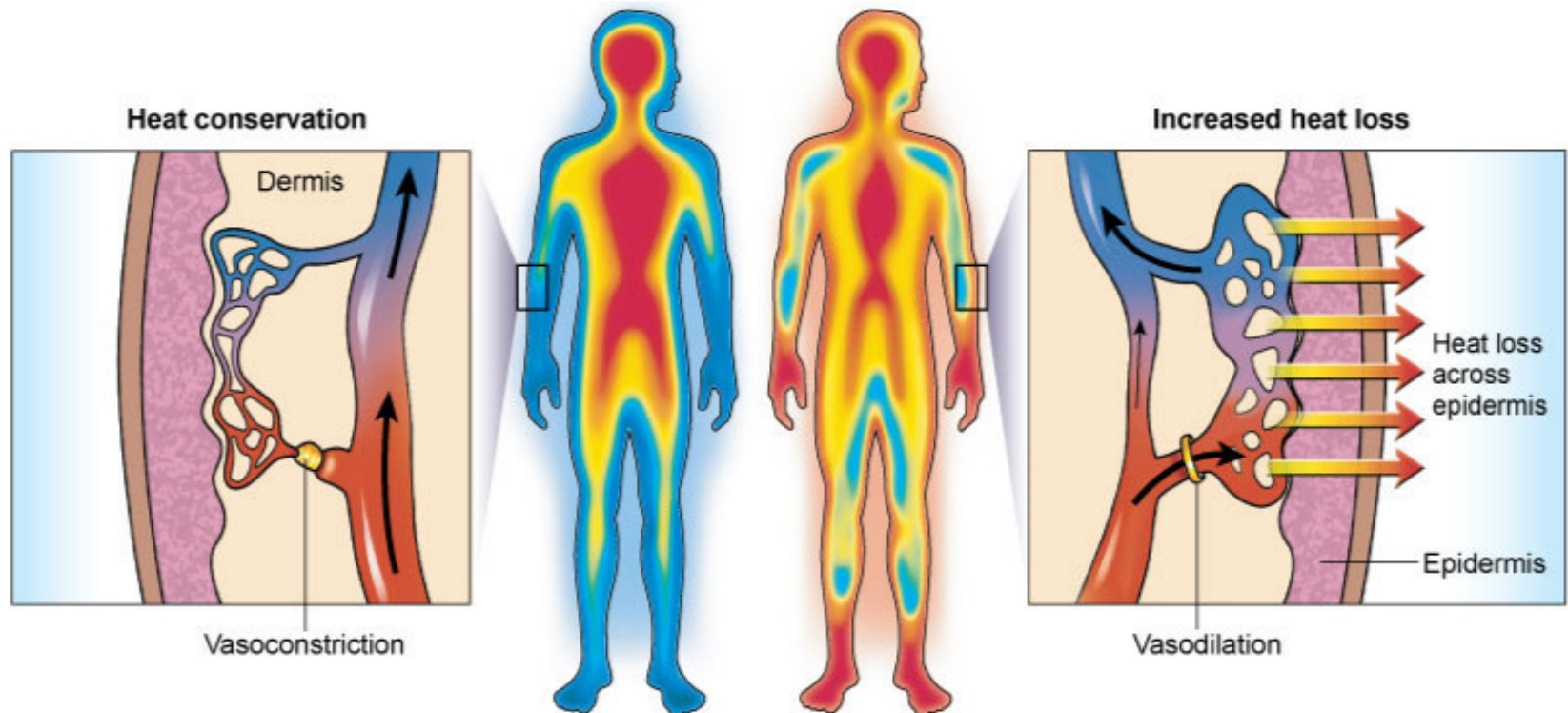
Venomotor tone

Skeletal muscle pump

Respiratory pump

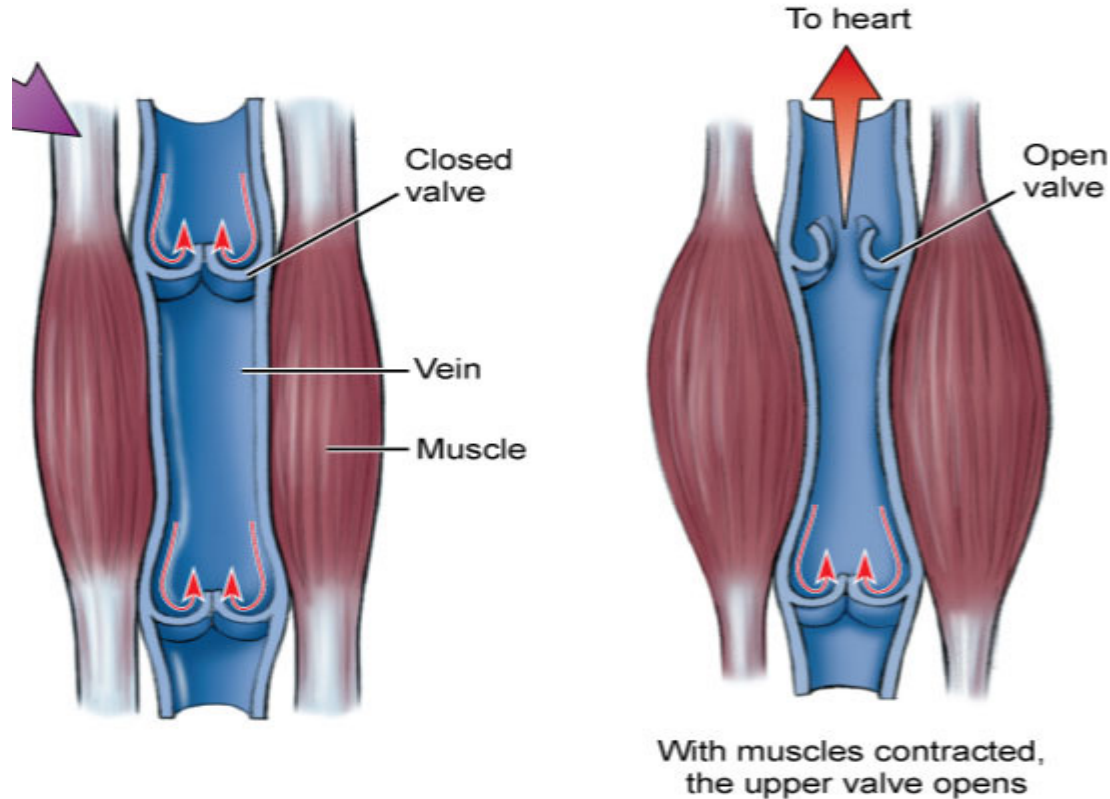
# Venous Return

**Venomotor tone** Changes in smooth muscle tone in the walls of veins can increase or decrease venous circulation.



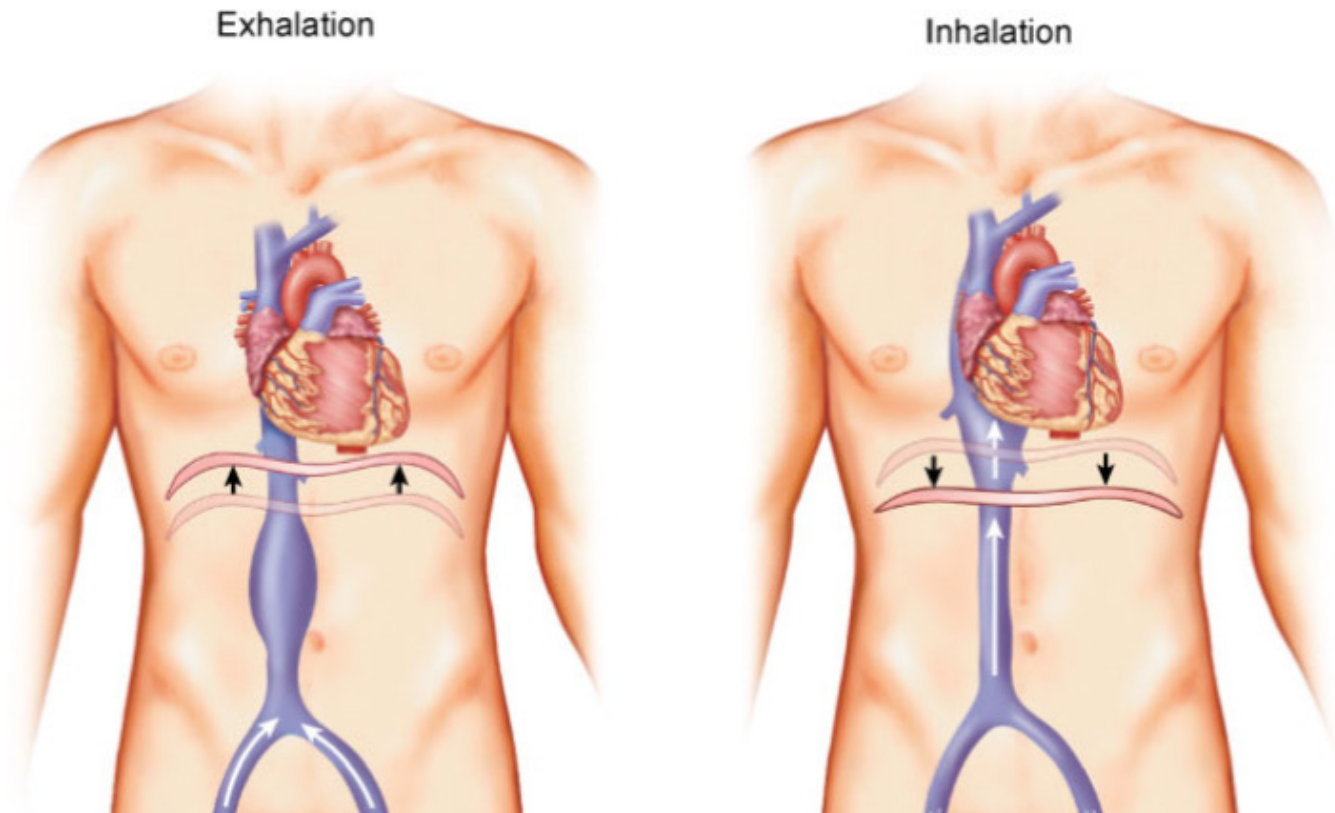
# Venous Return

**Skeletal muscle pump** Skeletal muscle contract and squeeze venous walls which moves blood toward the heart.



# Venous Return

**Respiratory pump** Pressure changes in the thorax and abdomen, caused by skeletal muscular contractions of breathing muscles that act as a mechanism to assist venous return.





# Blood Pressure

Systolic pressure

Diastolic pressure

High blood pressure

Average blood pressure

Low blood pressure



# Blood Pressure

**Blood pressure** Pressure exerted by blood on the blood vessel walls.

**Systolic pressure** Maximal pressure in blood pressure measurement.

Occurs when the left ventricle contracts.

**Diastolic pressure** Lowest pressure in blood pressure measurement.

Occurs when the left ventricle relaxes.



# Blood Pressure

**High blood pressure (AKA: hypertension)** Persistently more than 140/90.

**Average blood pressure** 120/80.

**Low blood pressure (AKA: hypotension)** Persistently less than 90/60.





# Paths of Circulation

Pulmonary circuit

Systemic circuit



# Paths of Circulation

**Pulmonary circuit** Circuit that brings de-oxygenated blood from the right ventricle of the heart to the lungs to release carbon dioxide and regain oxygen, then transports the oxygenated blood to the left atrium.



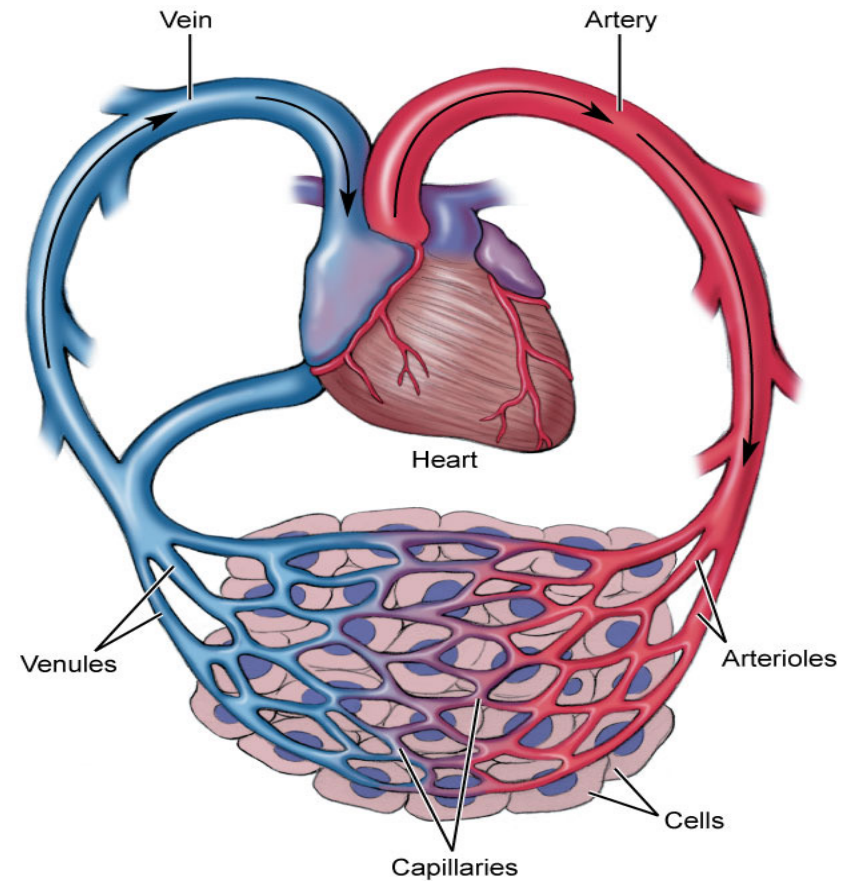
# Paths of Circulation

**Systemic circuit** Circuit that brings oxygenated blood from the left ventricle of the heart through numerous arteries into the capillaries, then moves it through the veins and returns the now de-oxygenated blood to the right atrium of the heart.

# Paths of Circulation

## Systemic Circuit

1. Left ventricle
2. Aortic semilunar valve
3. Aorta
4. Ascending and descending aortae
5. Arteries
6. Arterioles
7. Capillaries
8. Venules
9. Veins
10. Inferior and superior venae cavae
11. Right atrium





## 36a A&P: Cardiovascular System - Blood Vessels and Paths of Circulation