




82a Orthopedic Massage Introduction - Thoracic Outlet



82a Orthopedic Massage Introduction - Thoracic Outlet Class Outline

5 minutes	Attendance, Breath of Arrival, and Reminders
35 minutes	Lecture:
15 minutes	Active study skills:
60 minutes	Total



82a Orthopedic Massage

Introduction - Thoracic Outlet

Class Reminders

Early Warning:

- 85a Orthopedic Massage: Outside Massages – Begin these now!

Quizzes:

- 84a Kinesiology Quiz (pec major and minor, coracobrachialis, biceps, SCM, scalenes, rotator cuff, flex. Dig. Super., ext. dig., flex. Pollicis longus, flex dig. profundis)
– 50 questions in 40 minutes

Spot Checks and Assessments:

- 84b Orthopedic Massage: Spot Check – Thoracic Outlet

Assignments:

- 85a Orthopedic Massage: Outside Massages (2 due at the start of class)

Preparation for upcoming classes:

- 82b Orthopedic Massage: Technique Demo and Practice – Thoracic Outlet
- 83a Clinical Assessment: Structural Anatomy (Part II)
- 83b Orthopedic Massage: Technique Review and Practice – Thoracic Outlet
- 84a Kinesiology Quiz
- 84b Orthopedic Massage: Spot Check – Thoracic Outlet



Classroom Rules

Punctuality - everybody's time is precious

- Be ready to learn at the start of class; we'll have you out of here on time
- Tardiness: arriving late, returning late after breaks, leaving during class, leaving early

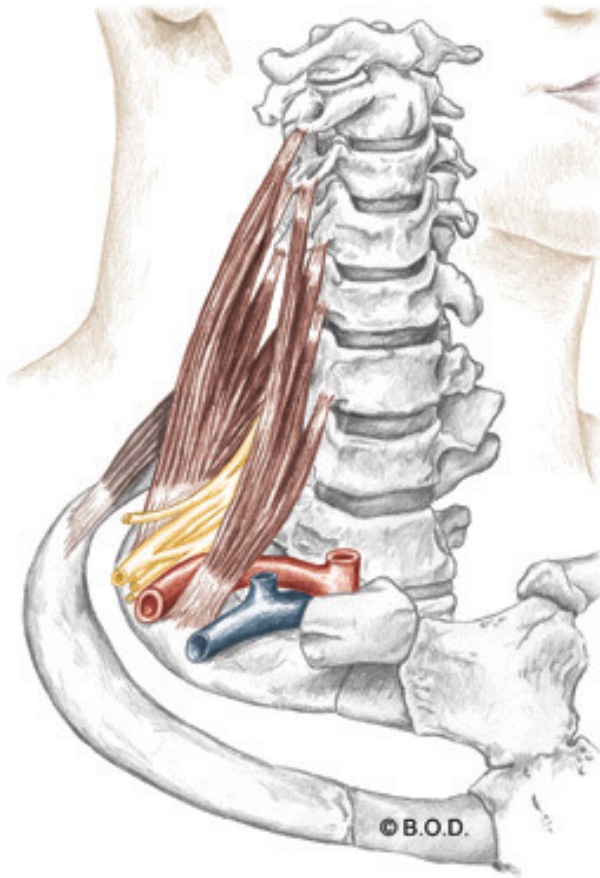
The following are not allowed:

- Bare feet
- Side talking
- Lying down
- Inappropriate clothing
- Food or drink except water
- Phones that are visible in the classroom, bathrooms, or internship

You will receive one verbal warning, then you'll have to leave the room.

Scalenes

Trail Guide, Page 247



Anterolateral View

Scalenes

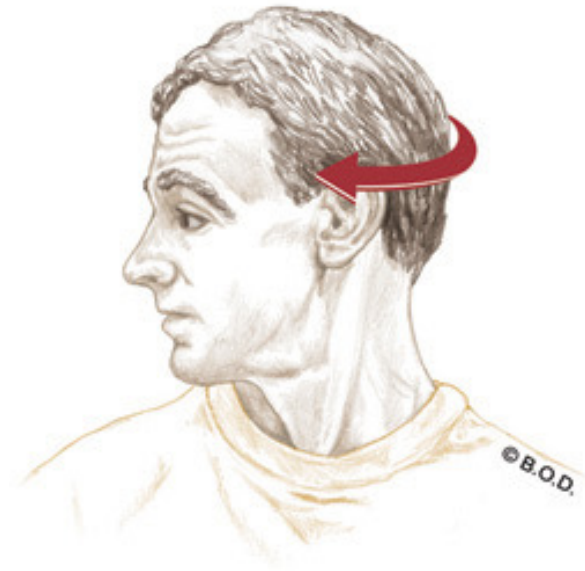
are sandwiched between the SCM and the anterior flap of the trapezius.

During inhalation, the scalenes perform the vital task of elevating the upper ribs.

Unilateral actions of the Scalenes

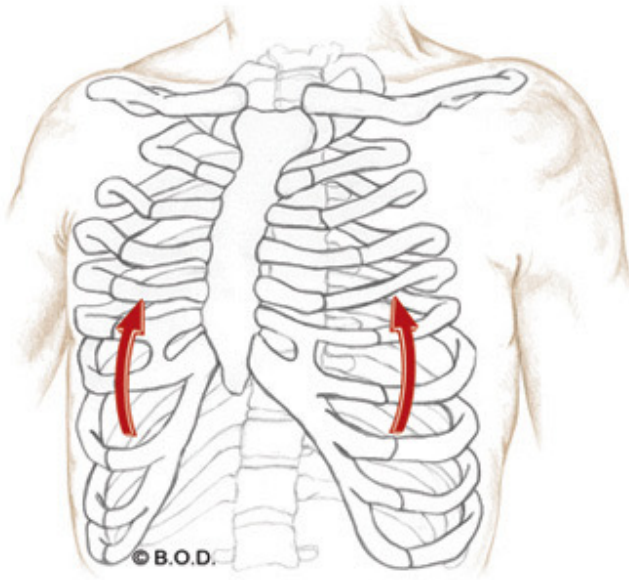


Lateral flexion of the head and neck

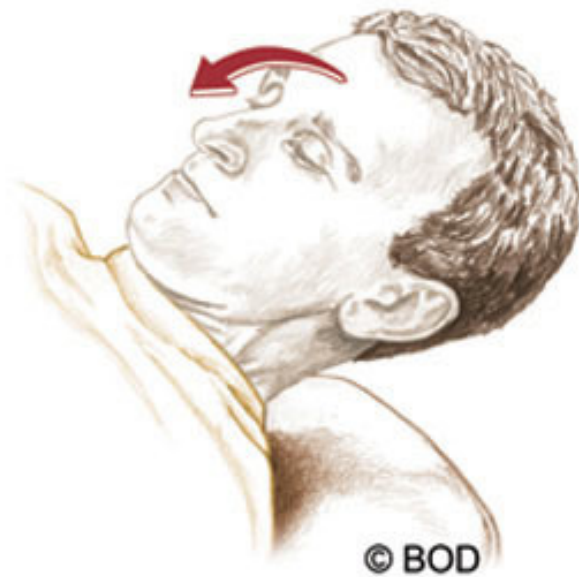

Rotation of the head and neck to the opposite

Bilateral actions of the Scalenes



Elevate the ribs during inhalation



Flexion of the head and neck

Anterior Scalenes, page 247

A *Unilaterally:*

With the ribs fixed, **laterally flex** the head and neck to the same side

Rotate the head and neck to the opposite side

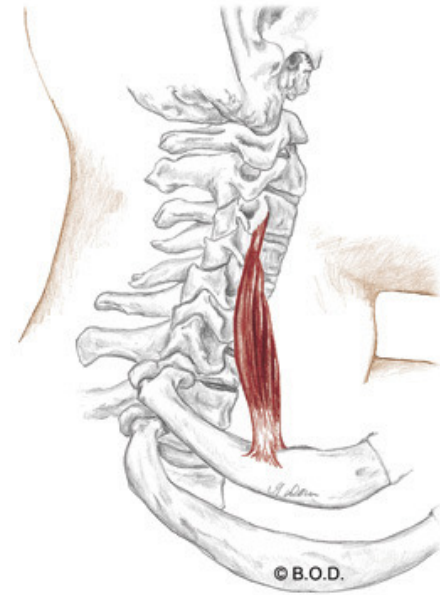
Bilaterally:

Elevate the ribs during inhalation

Flex the head and neck (anterior only)

O Transverse processes of third through sixth cervical vertebrae (anterior tubercles)

I First rib



Lateral View



Anterior Scalenes, page 247

A *Unilaterally:*

With the ribs fixed, **laterally flex** the head and neck to the same side

Rotate the head and neck to the opposite side

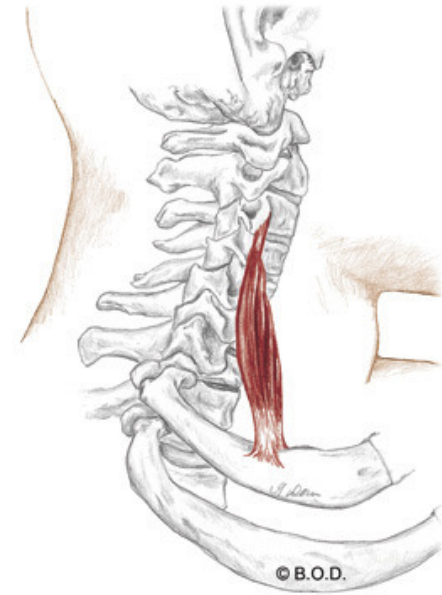
Bilaterally:

Elevate the ribs during inhalation

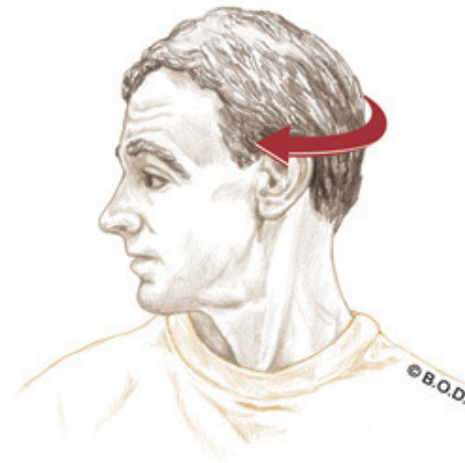
Flex the head and neck (anterior only)

O Transverse processes of third through sixth cervical vertebrae (anterior tubercles)

I First rib



Lateral View



Anterior Scalenes, page 247

A Unilaterally:

With the ribs fixed, **laterally flex** the head and neck to the same side
Rotate the head and neck to the opposite side

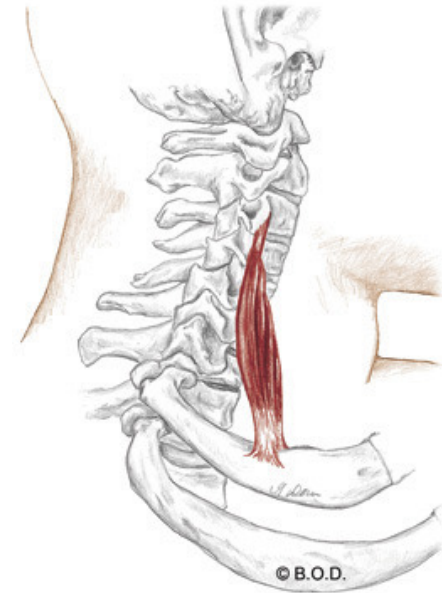
Bilaterally:

Elevate the ribs during inhalation

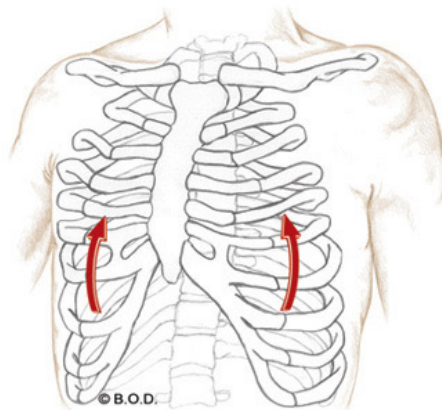
Flex the head and neck (anterior only)

O Transverse processes of third through sixth cervical vertebrae (anterior tubercles)

I First rib



Lateral View



Anterior Scalenes, page 247

A *Unilaterally:*

With the ribs fixed, **laterally flex** the head and neck to the same side
Rotate the head and neck to the opposite side

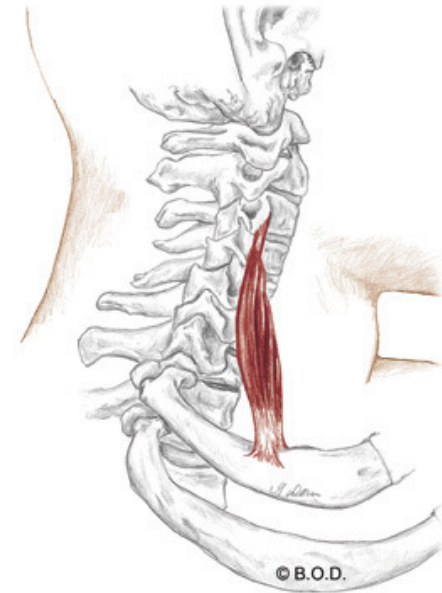
Bilaterally:

Elevate the ribs during inhalation

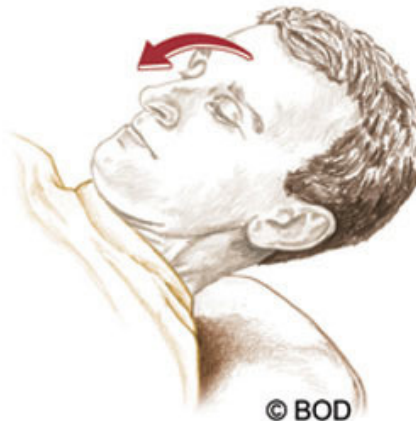
Flex the head and neck (anterior only)

O Transverse processes of third through sixth cervical vertebrae (anterior tubercles)

I First rib



Lateral View



Anterior Scalenes, page 247

A *Unilaterally:*

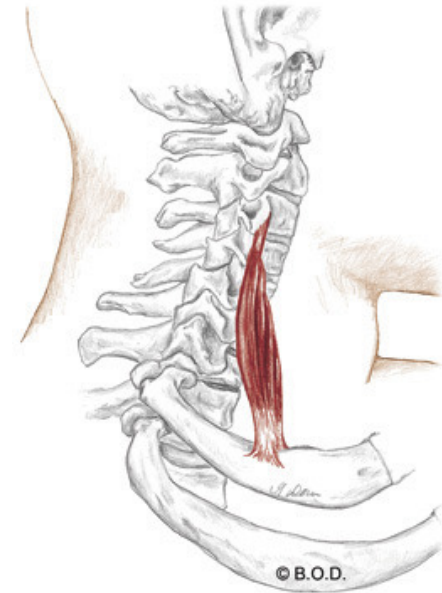
With the ribs fixed, **laterally flex** the head and neck to the same side
Rotate the head and neck to the opposite side

Bilaterally:

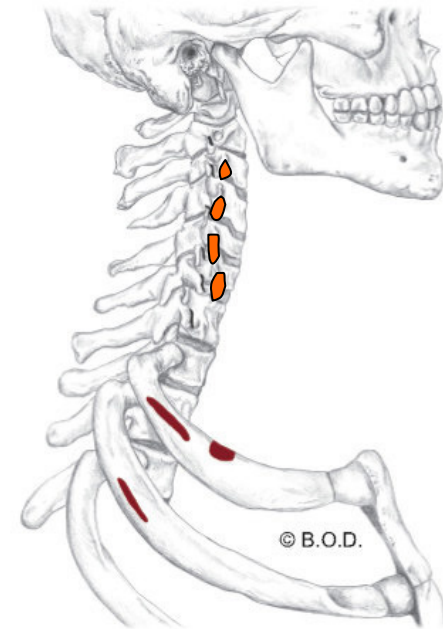
Elevate the ribs during inhalation
Flex the head and neck (anterior only)

O Transverse processes of third through sixth cervical vertebrae (anterior tubercles)

I First rib



Lateral View



Anterior Scalenes, page 247

A *Unilaterally:*

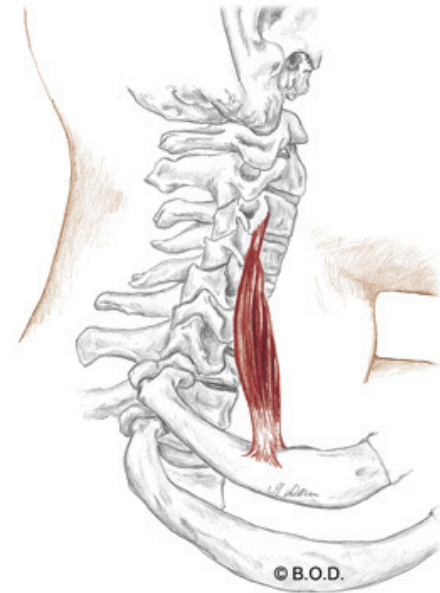
With the ribs fixed, **laterally flex** the head and neck to the same side
Rotate the head and neck to the opposite side

Bilaterally:

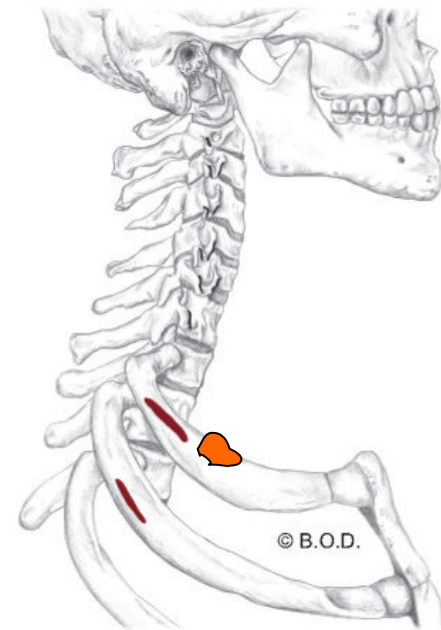
Elevate the ribs during inhalation
Flex the head and neck (anterior only)

O Transverse processes of third through sixth cervical vertebrae (anterior tubercles)

I First rib



Lateral View



Middle Scalenes, page 247

A *Unilaterally:*

With the ribs fixed, **laterally flex** the head and neck to the same side

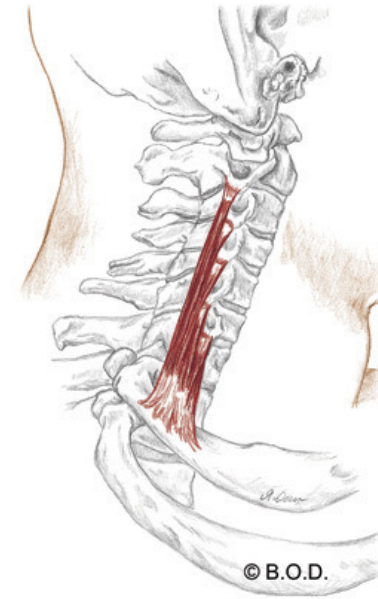
Rotate the head and neck to the opposite side

Bilaterally:

Elevate the ribs during inhalation

O Transverse processes of second through seventh cervical vertebrae (posterior tubercles)

I First rib



Lateral View



Middle Scalenes, page 247

A *Unilaterally:*

With the ribs fixed, **laterally flex** the head and neck to the same side

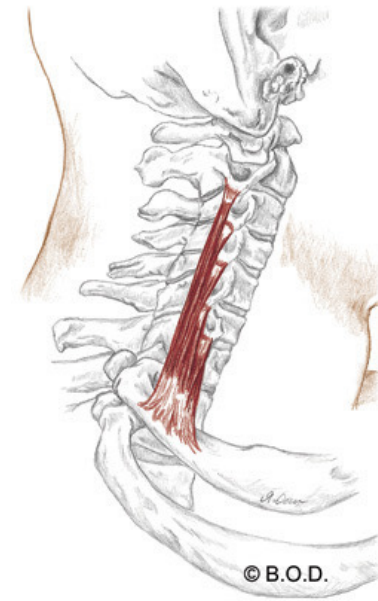
Rotate the head and neck to the opposite side

Bilaterally:

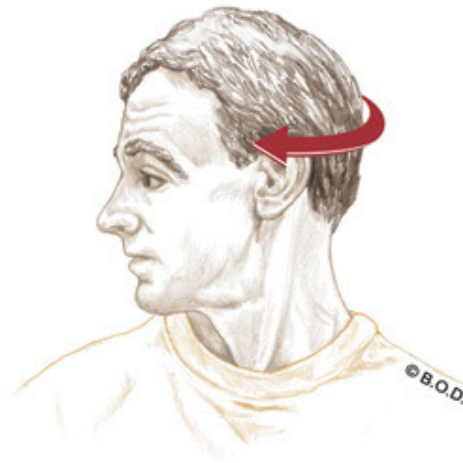
Elevate the ribs during inhalation

O Transverse processes of second through seventh cervical vertebrae (posterior tubercles)

I First rib



Lateral View



Middle Scalenes, page 247

A *Unilaterally:*

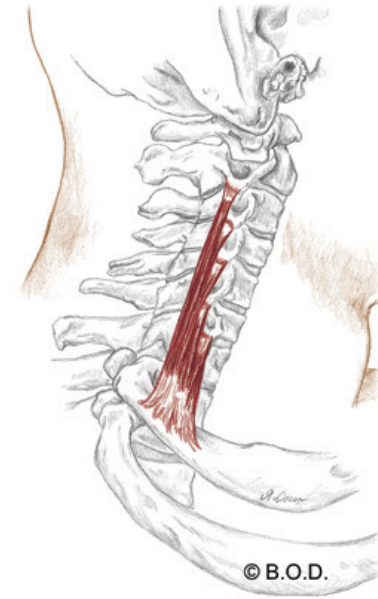
With the ribs fixed, **laterally flex** the head and neck to the same side
Rotate the head and neck to the opposite side

Bilaterally:

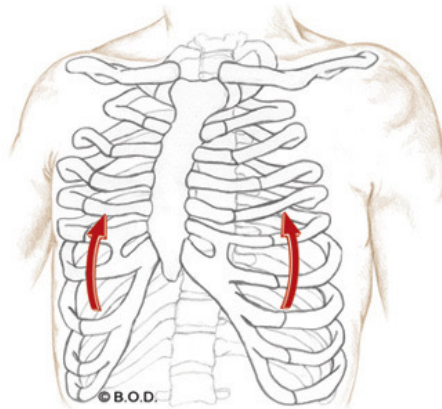
Elevate the ribs during inhalation

O Transverse processes of second through seventh cervical vertebrae (posterior tubercles)

I First rib



Lateral View



Middle Scalenes, page 247

A *Unilaterally:*

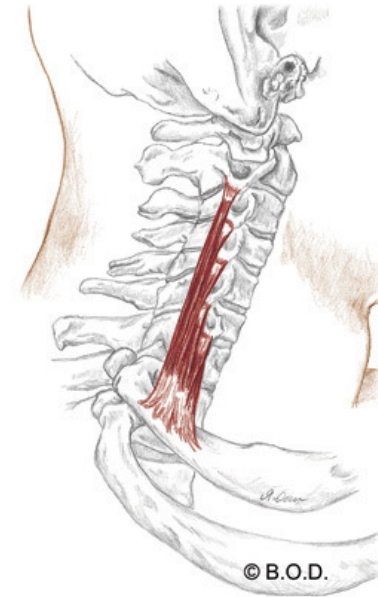
With the ribs fixed, **laterally flex** the head and neck to the same side
Rotate the head and neck to the opposite side

Bilaterally:

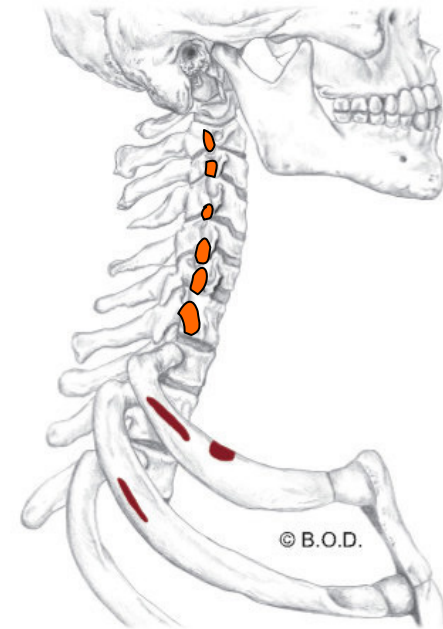
Elevate the ribs during inhalation

O Transverse processes of second through seventh cervical vertebrae (posterior tubercles)

I First rib



Lateral View



Middle Scalenes, page 247

A *Unilaterally:*

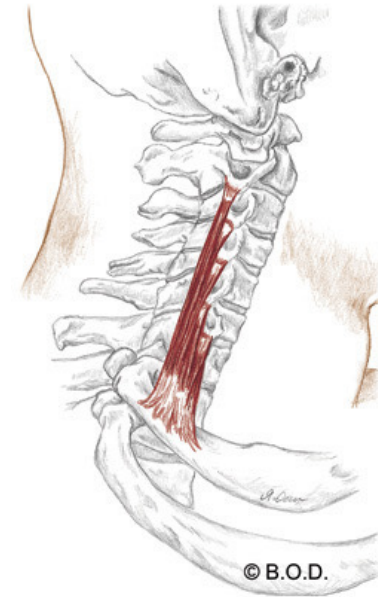
With the ribs fixed, **laterally flex** the head and neck to the same side
Rotate the head and neck to the opposite side

Bilaterally:

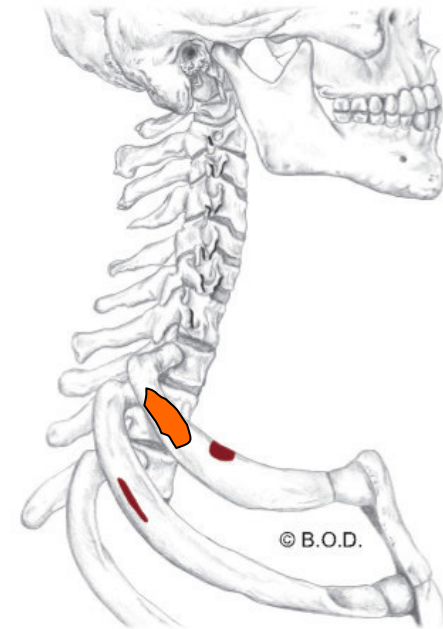
Elevate the ribs during inhalation

O Transverse processes of second through seventh cervical vertebrae (posterior tubercles)

I First rib



Lateral View



Posterior Scalenes, page 247

A *Unilaterally:*

With the ribs fixed, **laterally flex** the head and neck to the same side

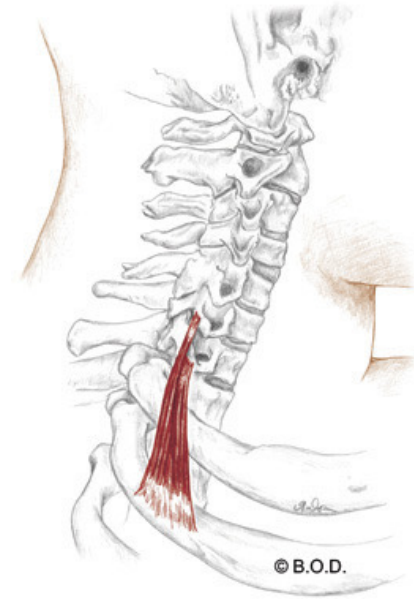
Rotate the head and neck to the opposite side

Bilaterally:

Elevate the ribs during inhalation

O Transverse processes of sixth and seventh cervical vertebrae (posterior tubercles)

I Second rib



Lateral View



Posterior Scalenes, page 247

A *Unilaterally:*

With the ribs fixed, **laterally flex** the head and neck to the same side

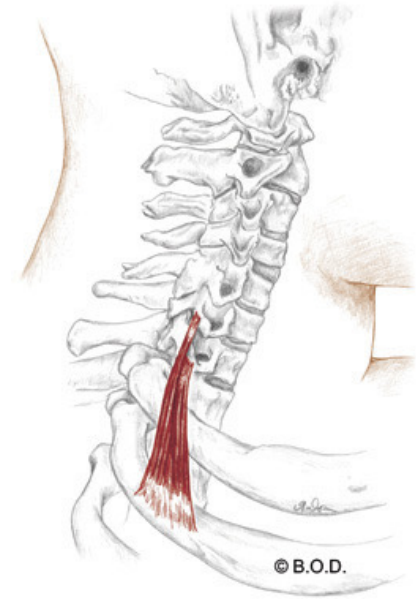
Rotate the head and neck to the opposite side

Bilaterally:

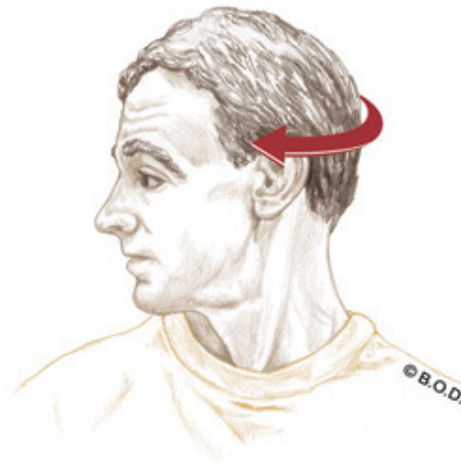
Elevate the ribs during inhalation

O Transverse processes of sixth and seventh cervical vertebrae (posterior tubercles)

I Second rib



Lateral View



Posterior Scalenes, page 247

A *Unilaterally:*

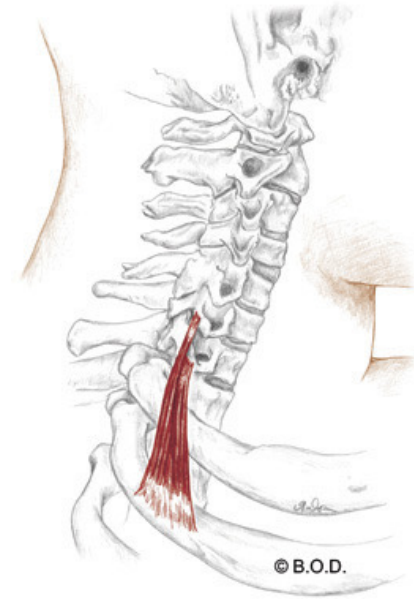
With the ribs fixed, **laterally flex** the head and neck to the same side
Rotate the head and neck to the opposite side

Bilaterally:

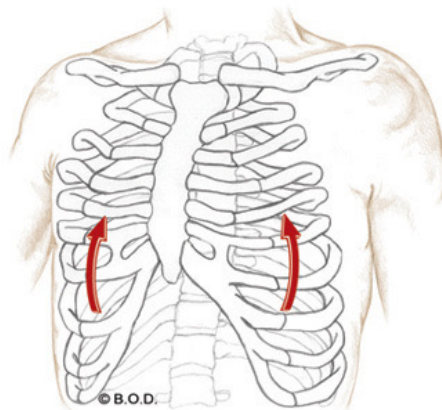
Elevate the ribs during inhalation

O Transverse processes of sixth and seventh cervical vertebrae (posterior tubercles)

I Second rib



Lateral View



Posterior Scalenes, page 247

A *Unilaterally:*

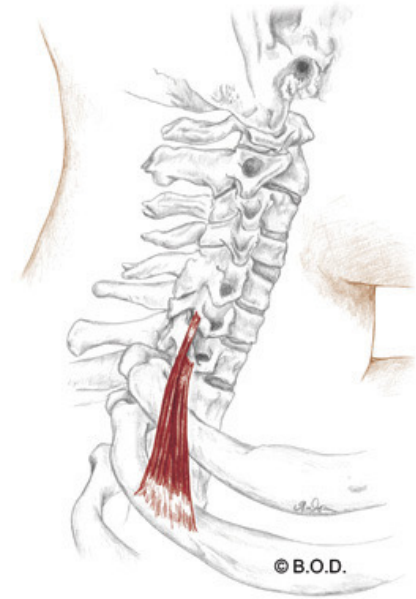
With the ribs fixed, **laterally flex** the head and neck to the same side
Rotate the head and neck to the opposite side

Bilaterally:

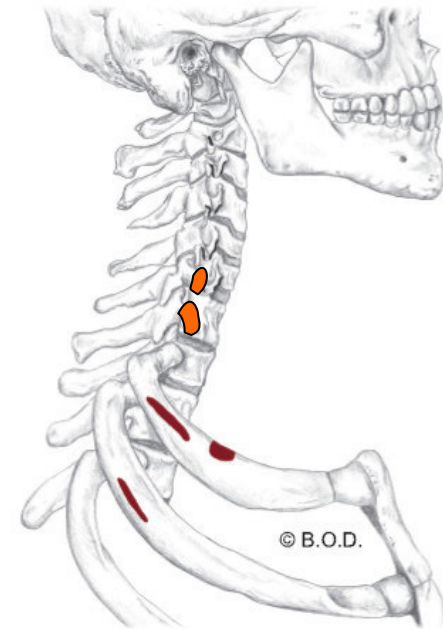
Elevate the ribs during inhalation

O Transverse processes of sixth and seventh cervical vertebrae (posterior tubercles)

I Second rib



Lateral View



Posterior Scalenes, page 247

A *Unilaterally:*

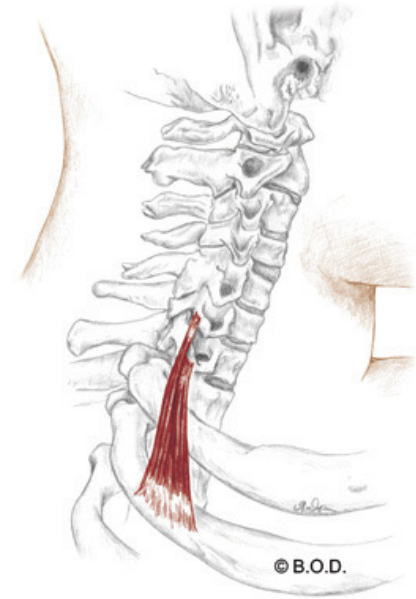
With the ribs fixed, **laterally flex** the head and neck to the same side
Rotate the head and neck to the opposite side

Bilaterally:

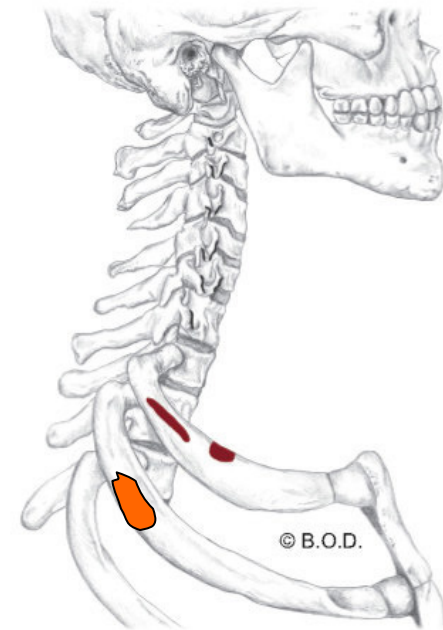
Elevate the ribs during inhalation

O Transverse processes of sixth and seventh cervical vertebrae (posterior tubercles)

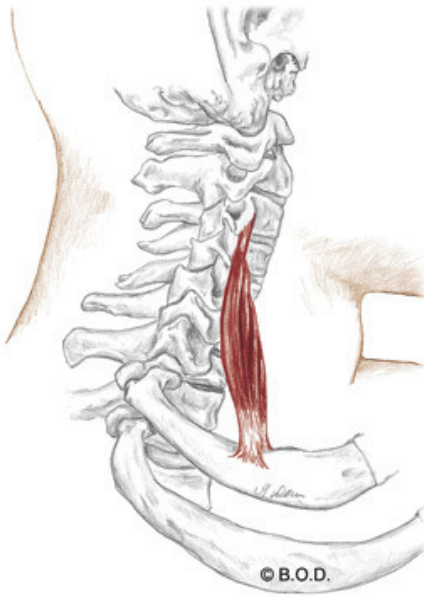
I Second rib



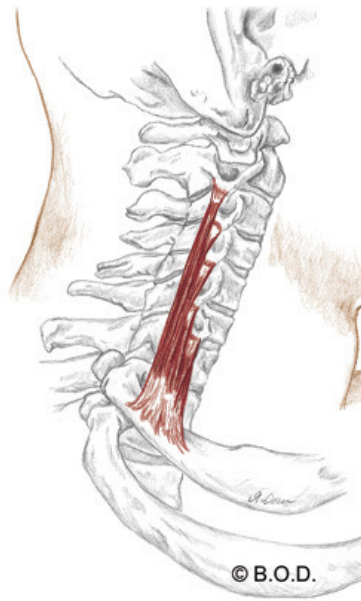
Lateral View



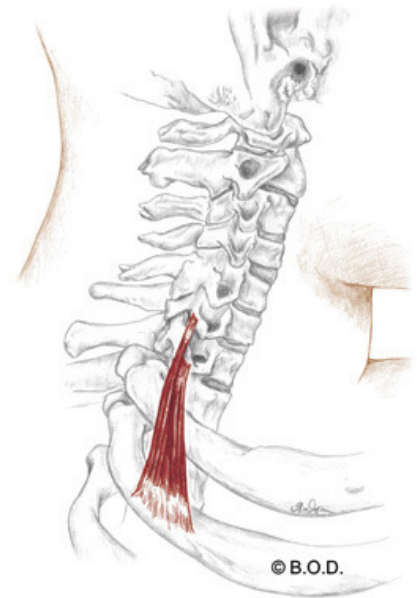
Anterior scalene



Middle scalene



Posterior scalene



Pectoralis Minor

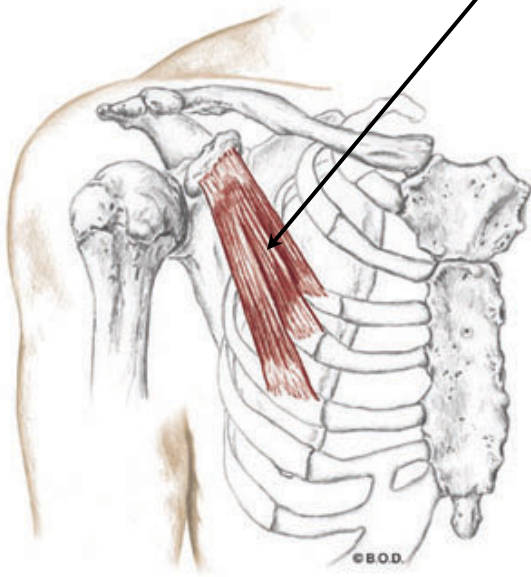
Trail Guide, Page 92

Pectoralis minor lies next to the ribcage deep to the pectoralis major.

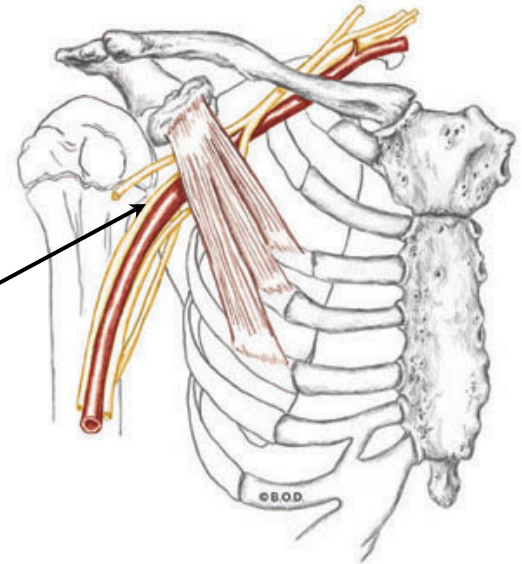
During aerobic activity the pectoralis minor helps to elevate the rib cage for inhalation.

Major vessels such as the brachial plexus, axillary artery and axillary vein pass underneath the pectoralis minor. This can create the potential for neurovascular compression.

Pectoralis minor, what does it do?



Anterolateral View



Anterolateral View

Pectoralis Minor, page 92

A Depress the scapula (scapulothoracic joint)

Abduct the scapula (S/T joint)

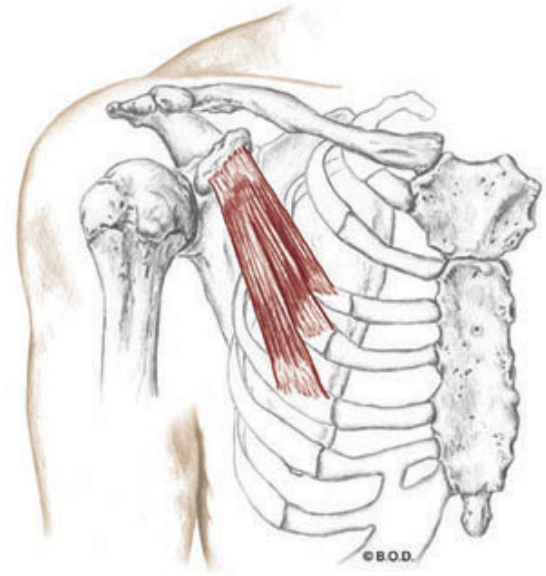
Downwardly rotate the scapula (S/T joint)

With the scapula fixed:

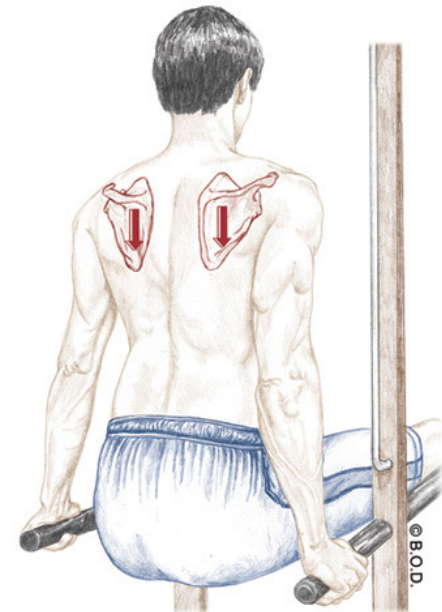
Assist to **elevate** the thorax during forced inhalation

O Third, fourth, and fifth ribs

I Medial surface of coracoid process of the scapula



Anterior View



Pectoralis Minor, page 92

A Depress the scapula (scapulothoracic joint)

Abduct the scapula (S/T joint)

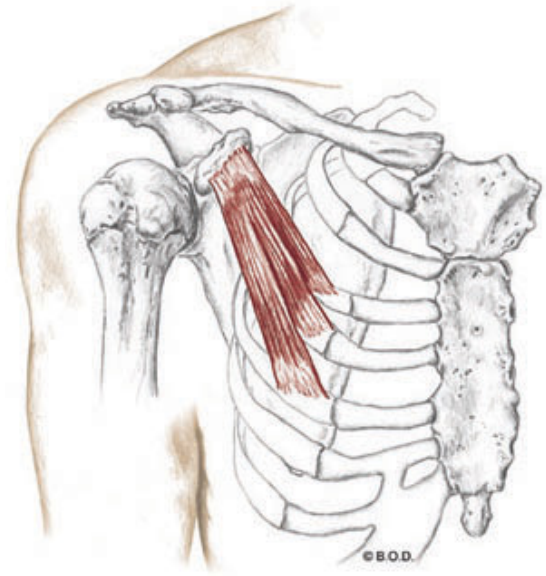
Downwardly rotate the scapula (S/T joint)

With the scapula fixed:

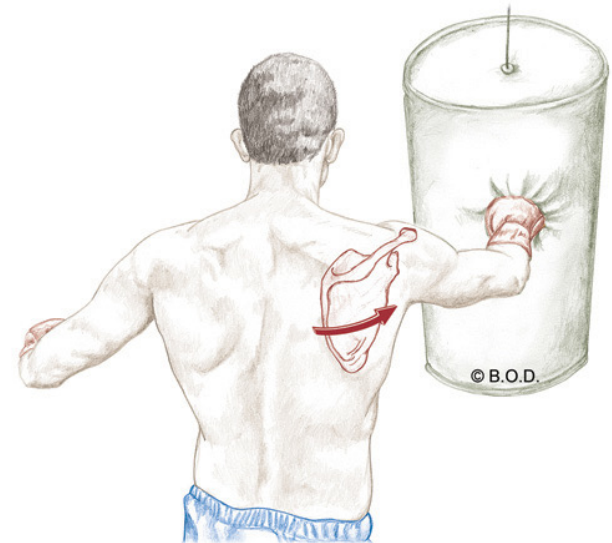
Assist to **elevate** the thorax during forced inhalation

O Third, fourth, and fifth ribs

I Medial surface of coracoid process of the scapula



Anterior View



Pectoralis Minor, page 92

A **Depress** the scapula (scapulothoracic joint)

Abduct the scapula (S/T joint)

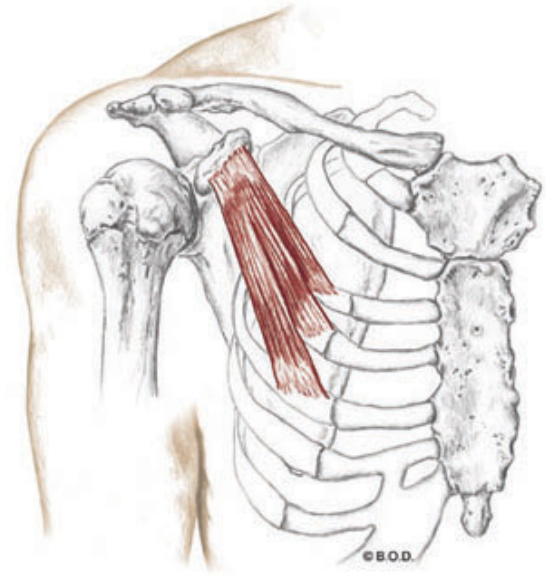
Downwardly rotate the scapula (S/T joint)

With the scapula fixed:

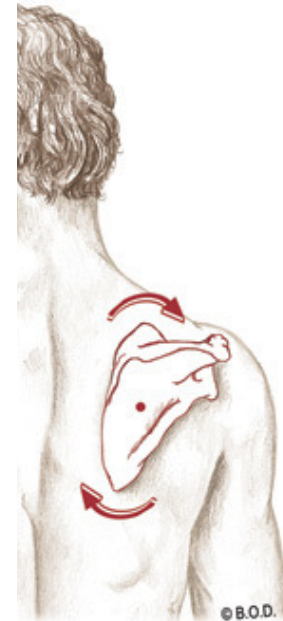Assist to **elevate** the thorax during forced inhalation

O Third, fourth, and fifth ribs

I Medial surface of coracoid process of the scapula



Anterior View



Pectoralis Minor, page 92

A **Depress** the scapula (scapulothoracic joint)

Abduct the scapula (S/T joint)

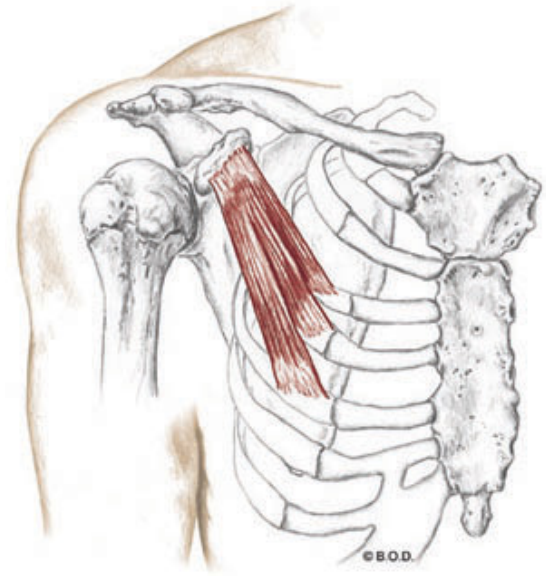
Downwardly rotate the scapula (S/T joint)

With the scapula fixed:

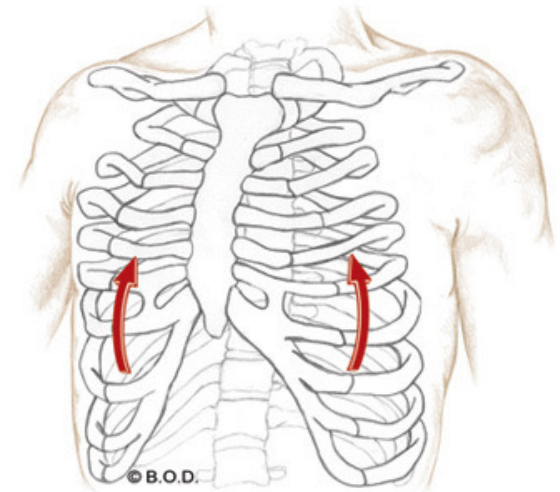
Assist to **elevate** the thorax during forced inhalation

O Third, fourth, and fifth ribs

I Medial surface of coracoid process of the scapula



Anterior View



Pectoralis Minor, page 92

A Depress the scapula (scapulothoracic joint)

Abduct the scapula (S/T joint)

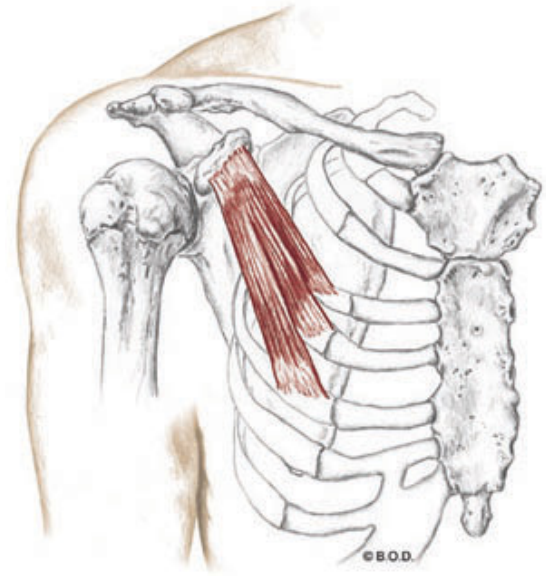
Downwardly rotate the scapula (S/T joint)

With the scapula fixed:

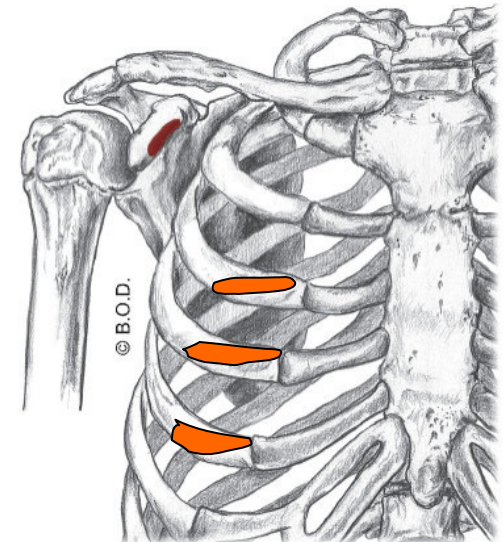
Assist to **elevate** the thorax during forced inhalation

O Third, fourth, and fifth ribs

I Medial surface of coracoid process of the scapula



Anterior View



Pectoralis Minor, page 92

A Depress the scapula (scapulothoracic joint)

Abduct the scapula (S/T joint)

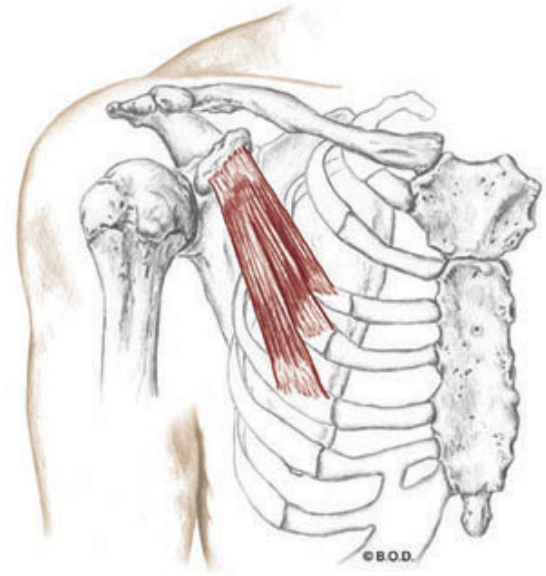
Downwardly rotate the scapula (S/T joint)

With the scapula fixed:

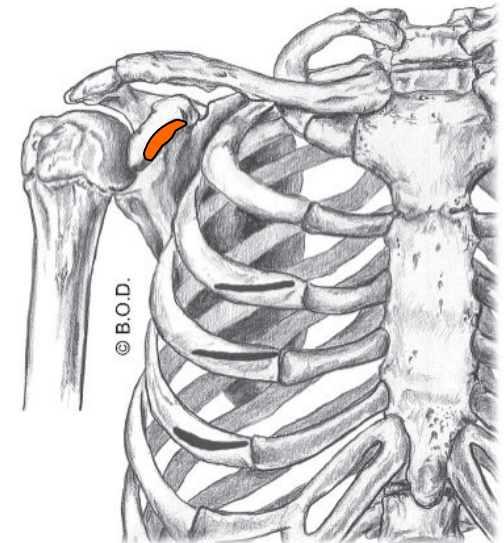
Assist to **elevate** the thorax during forced inhalation

O Third, fourth, and fifth ribs

I Medial surface of coracoid process of the scapula



Anterior View



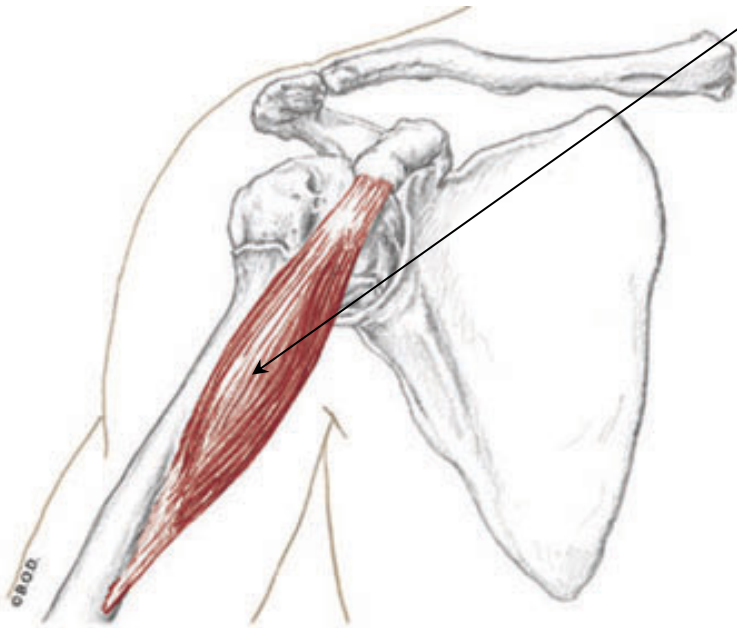
Coracobrachialis

Trail Guide, Page 99

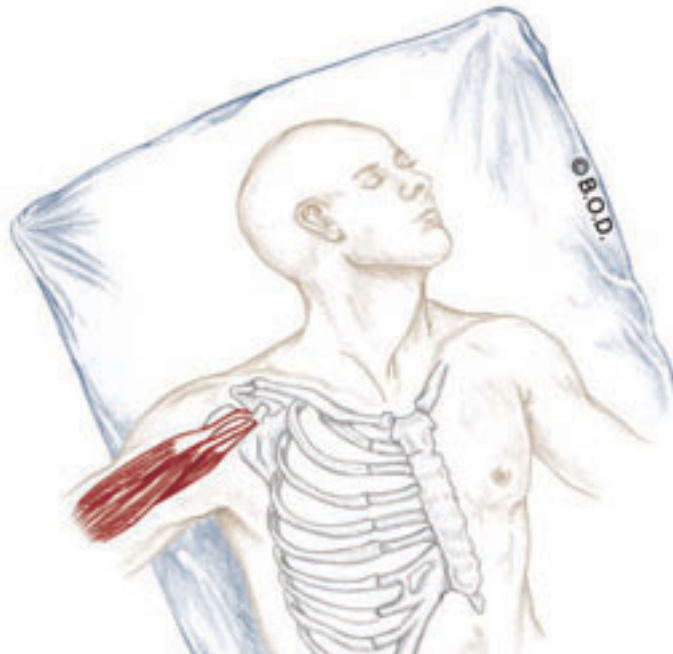
Coracobrachialis

is a small, tubular muscle located in the axilla, or armpit.

Let's take a closer look at the axilla . . .



Anterior View



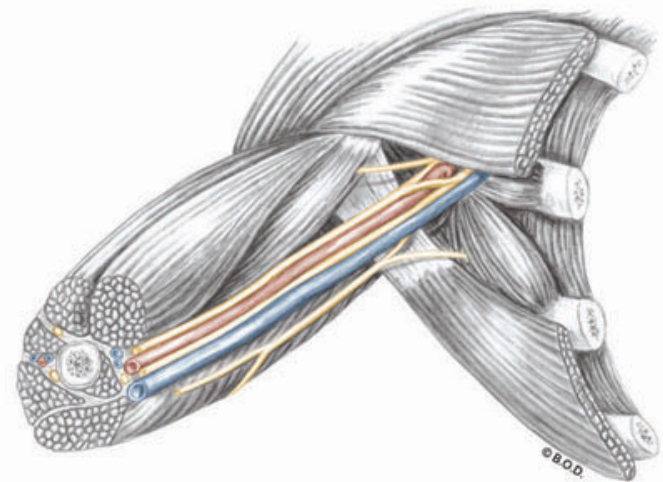
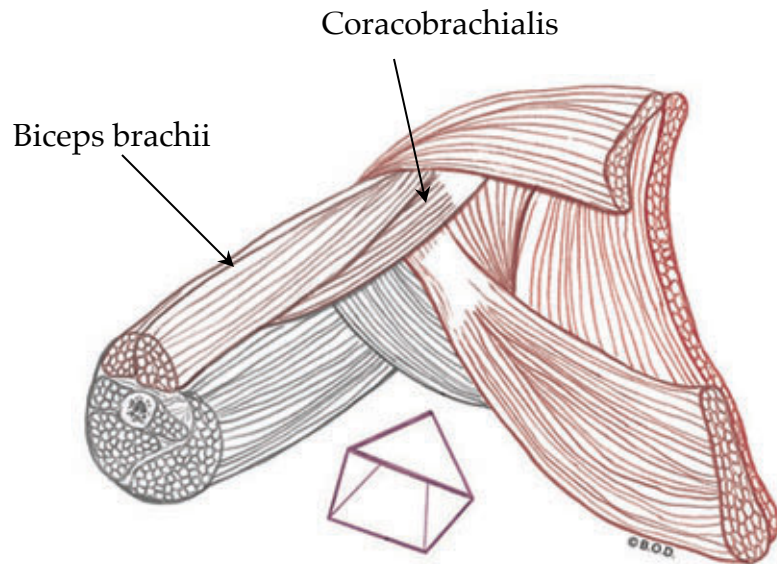
Axilla

Trail Guide, Page 100

The **axilla** is a cone-shaped area commonly called the armpit.

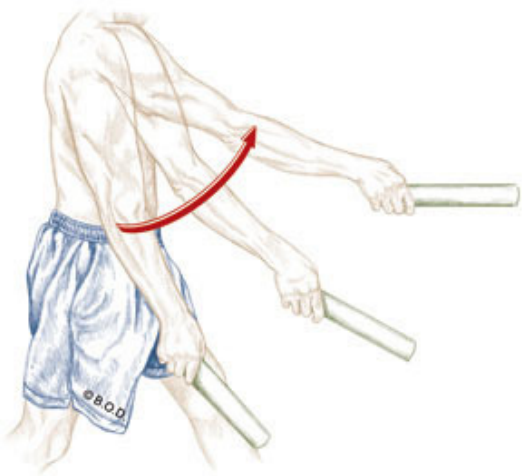
It is formed by four walls:

- Lateral wall: biceps brachii and coracobrachialis
- Posterior wall: subscapularis and latissimus dorsi / teres major
- Anterior wall: pectoralis major
- Medial wall: rib cage and serratus anterior

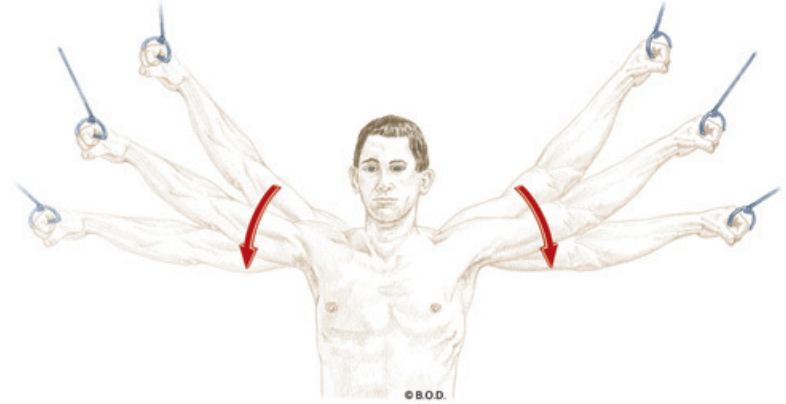


Anterolateral View

Actions of the Coracobrachialis



Glenohumeral flexion



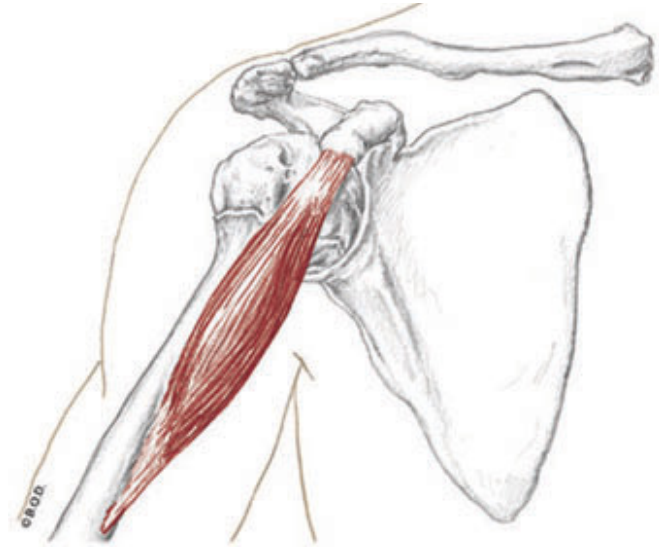
Glenohumeral adduction

Coracobrachialis, page 99

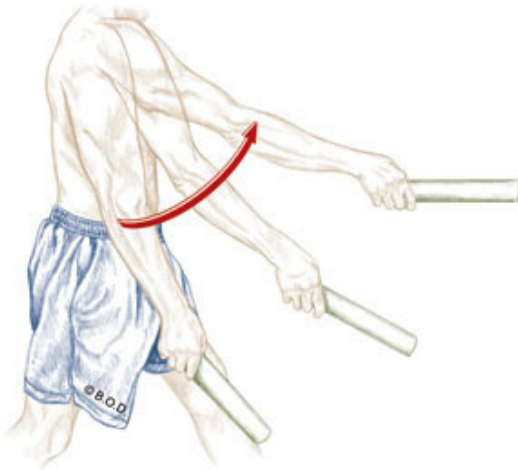
A Flex the shoulder or glenohumeral joint
Adduct shoulder or glenohumeral joint

O Coracoid process of scapula

I Medial surface of mid-humeral shaft



Anterior View



Coracobrachialis, page 99

A

Flex the shoulder or glenohumeral joint

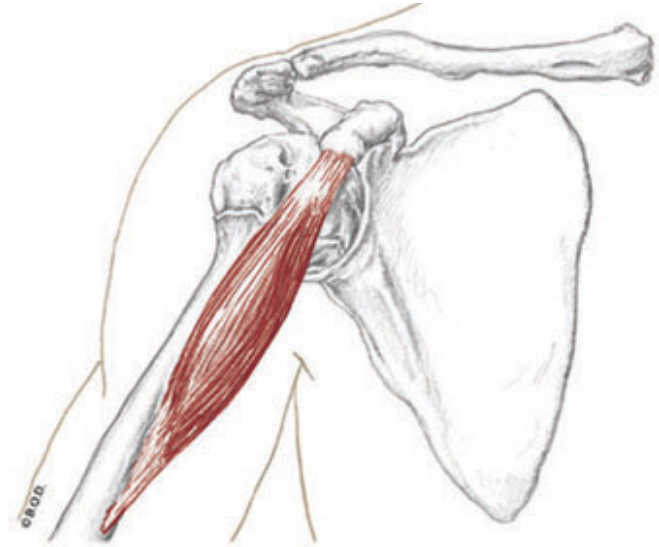
Adduct shoulder or glenohumeral joint

O

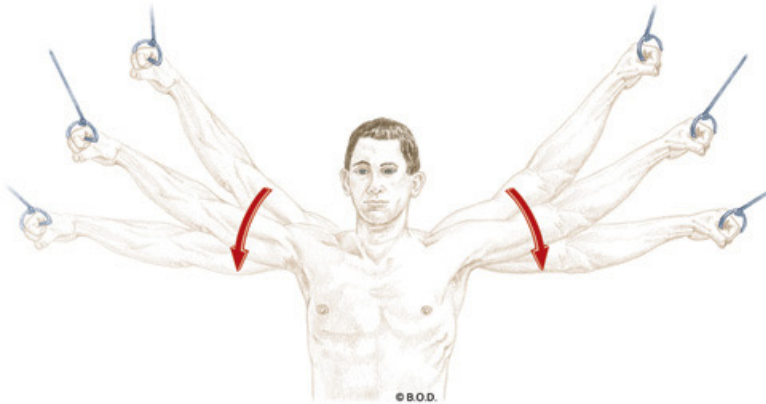
Coracoid process of scapula

I

Medial surface of mid-humeral shaft



Anterior View

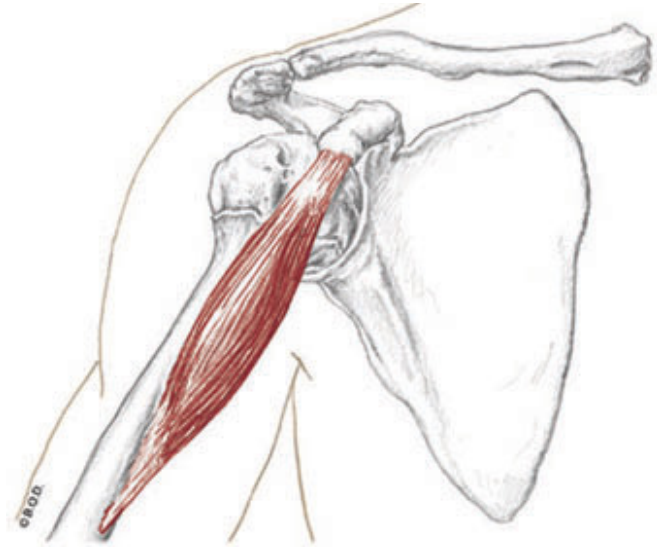


Coracobrachialis, page 99

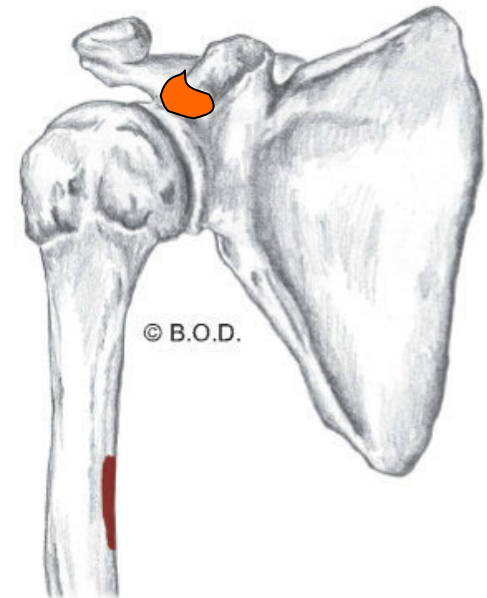
A **Flex** the shoulder or glenohumeral joint
Adduct shoulder or glenohumeral joint

O Coracoid process of scapula

I Medial surface of mid-humeral shaft



Anterior View

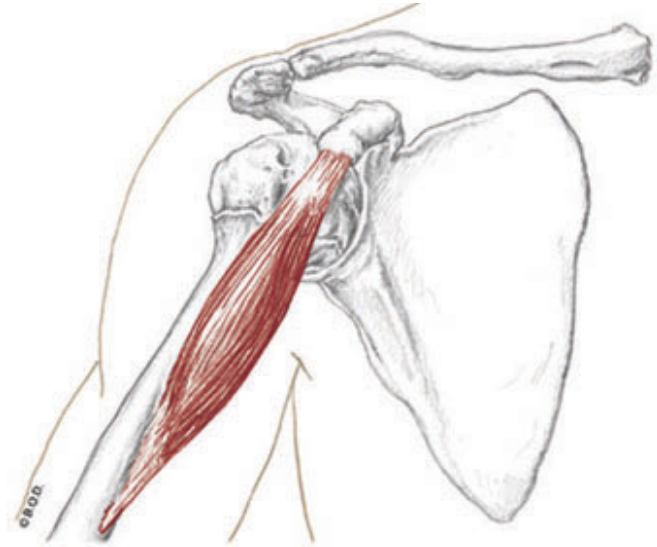


Coracobrachialis, page 99

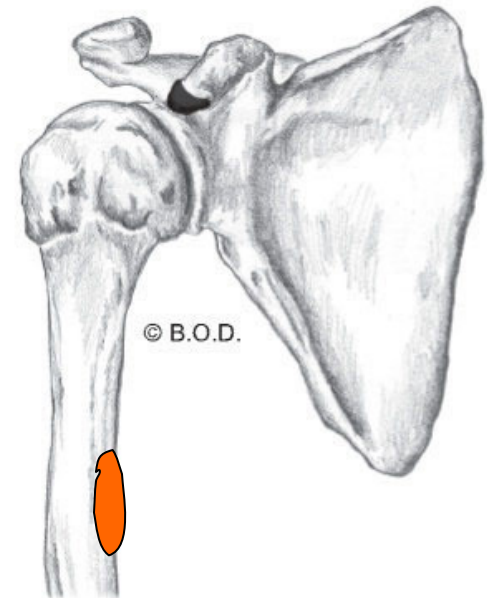
A Flex the shoulder or glenohumeral joint
Adduct shoulder or glenohumeral joint

O Coracoid process of scapula

I Medial surface of mid-humeral shaft



Anterior View





82a Orthopedic Massage Introduction - Thoracic Outlet

J - 97

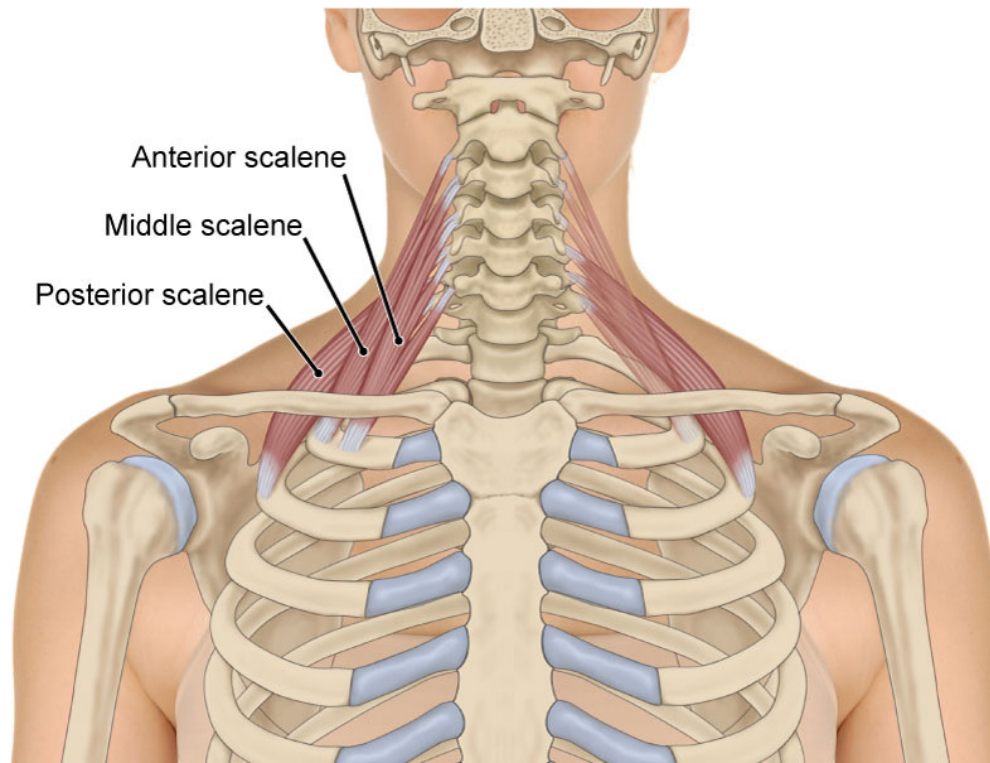


Thoracic Outlet Syndrome

Thoracic outlet syndrome (AKA: TOS) Several pathologies involving compression of arteries, veins, or nerves near the thoracic outlet. A complex condition that is often overlooked or misdiagnosed.

What is a thoracic outlet?

Thoracic outlet Upper border of the thoracic rib cage where structures either exit or enter.

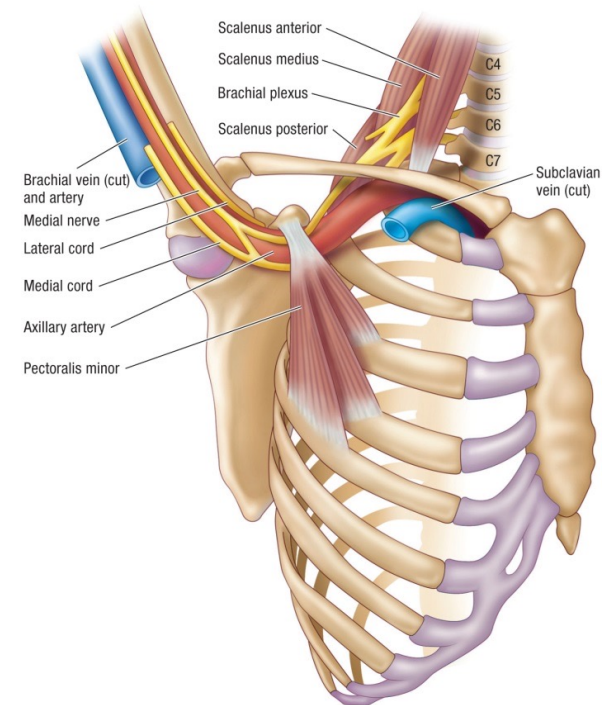


Anterior View

Thoracic Outlet Syndrome

Structures that may be involved in TOS:

- Brachial plexus
- Subclavian artery
- Subclavian vein

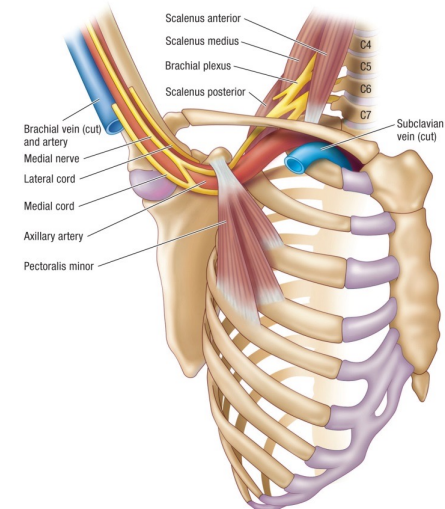
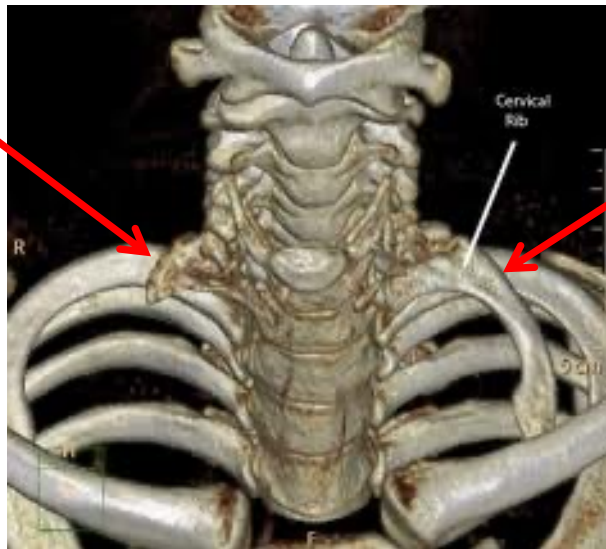


Anterolateral View

Four different TOS pathologies

1. True neurogenic TOS

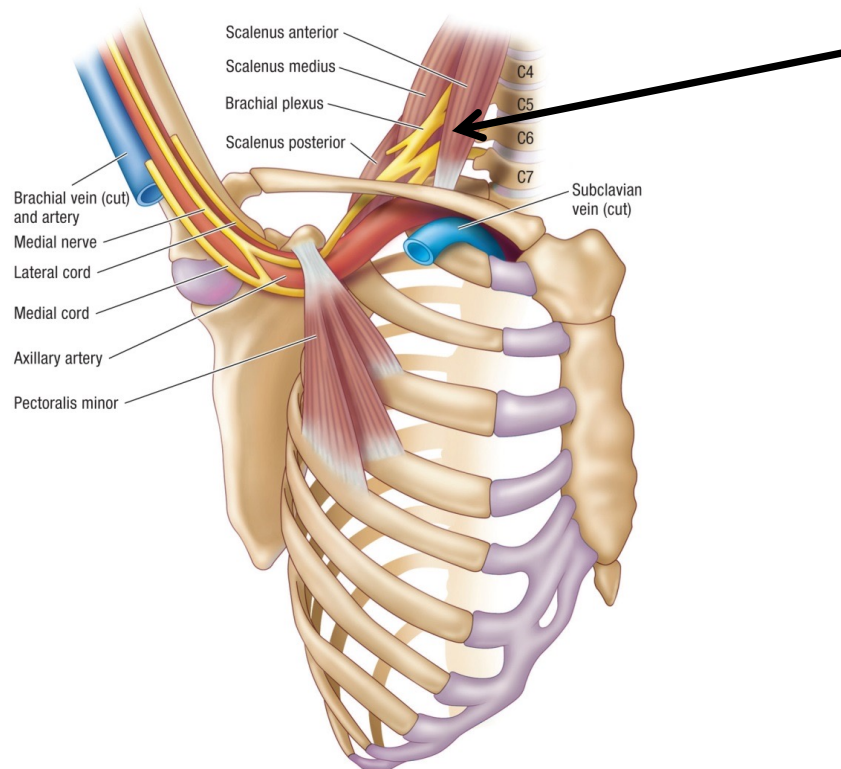
- Rare. Brachial plexus compression between C7 “rib” and clavicle.
- **Neurogenic** Originating in nervous tissue.
- No soft tissue treatment can remove the cervical rib obstruction.
- The techniques for the other syndromes can help this syndrome.



Four different TOS pathologies

2. Anterior scalene syndrome

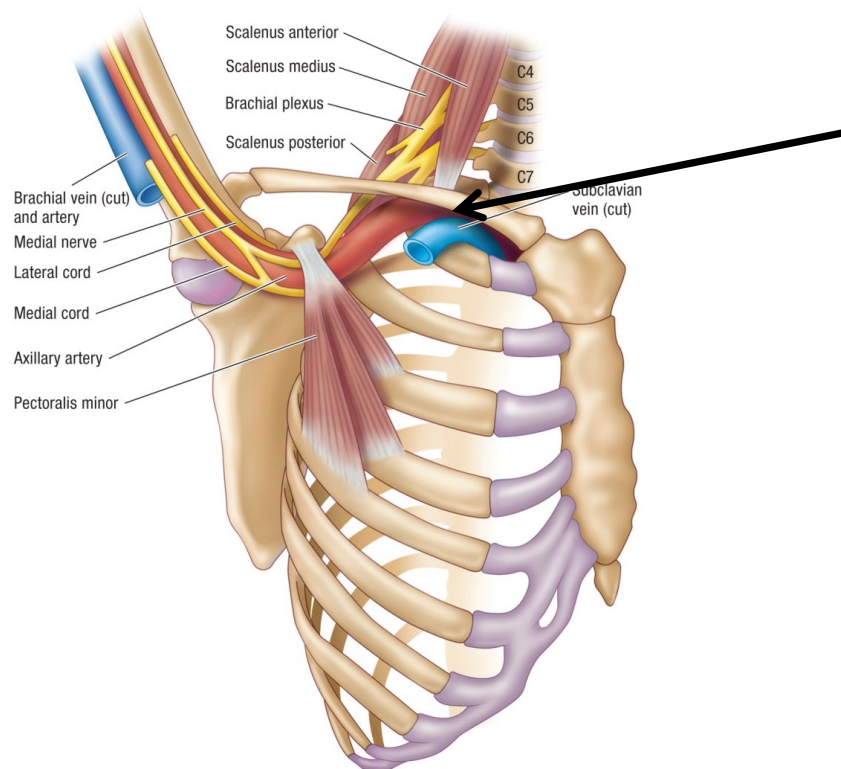
- Neurovascular compression between anterior and middle scalenes.



Four different TOS pathologies

3. Costoclavicular syndrome

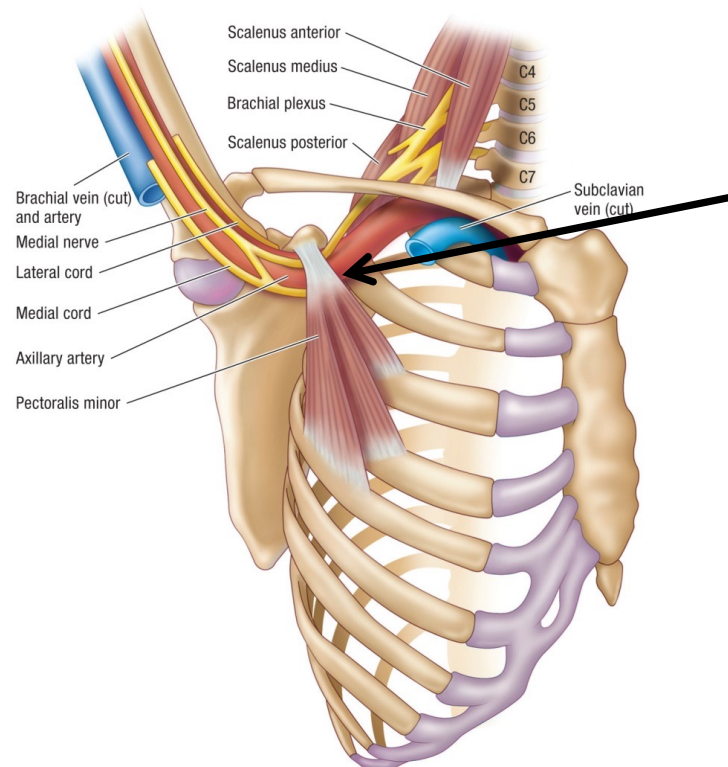
- Neurovascular compression between the clavicle and first rib.



Four different TOS pathologies

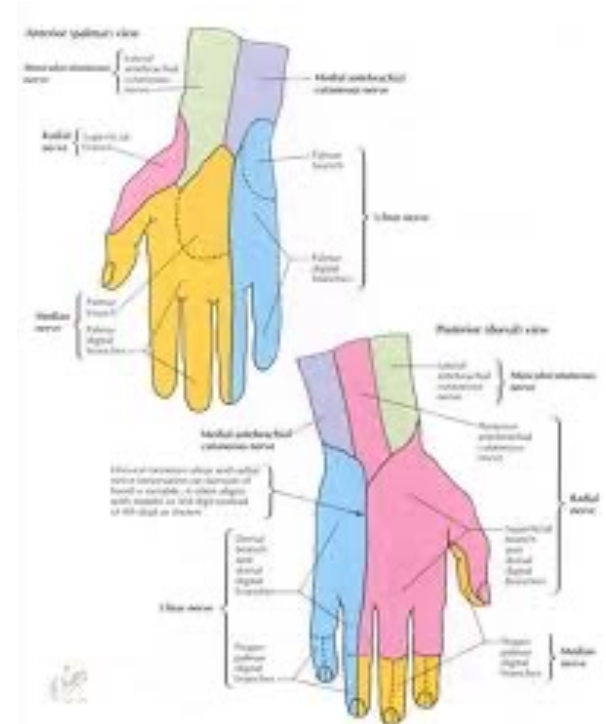
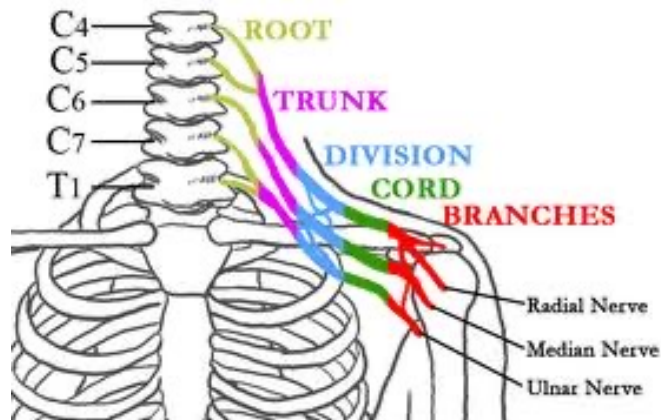4. Pectoralis minor syndrome

- Neurovascular compression between pectoralis minor and ribs.



Brachial plexus cords

- Medial cord: ulnar 1/3 of the fingers and hand.
- Lateral cord: radial 2/3 of the fingers and hand (dorsum of hand excepted).
- Posterior cord: radial 2/3 of dorsum of the hand.



Onset and Etiology of TOS

Acute: often caused by a direct blow to the clavicle

Chronic: postural distortions with resultant muscular dysfunction

- Prolonged shoulder abduction (hairstyling, playing the violin)
- Wearing a heavy backpack or carrying heavy objects





Signs and Symptoms of TOS

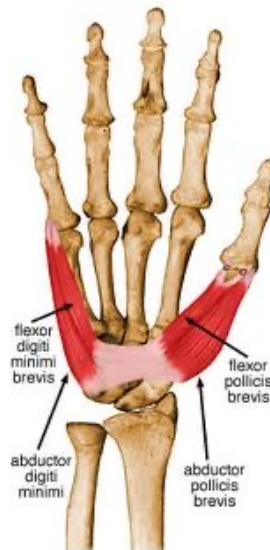Upper extremity

- Pain
- **Paresthesia** Sensation of pins and needles.
- Feeling of heaviness
- Coldness
- Discoloration

Signs and Symptoms of TOS

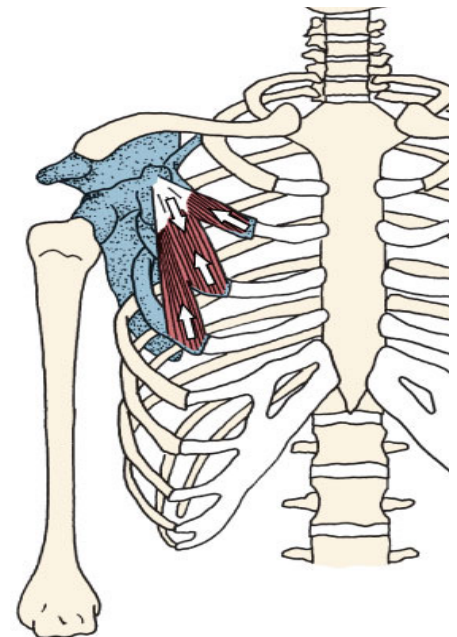
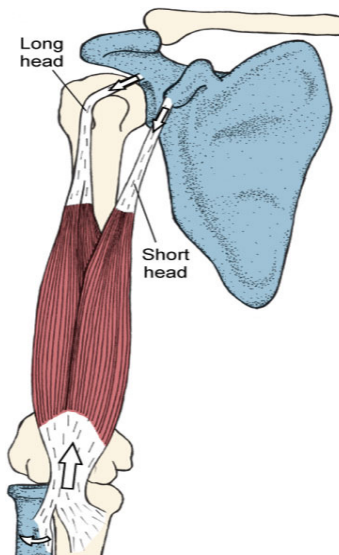
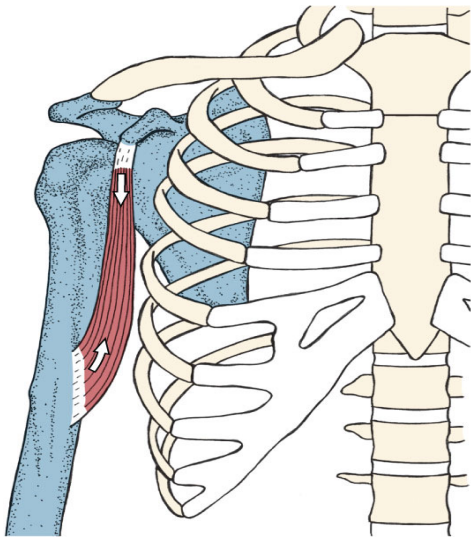
Thenar muscle atrophy

- **Thenar muscles** First and fifth finger abductors and flexors.
- **Atrophy** Wasting away of or reduction in the mass of tissue.
- Anterior and middle scalene tension compresses the brachial plexus.



Signs and Symptoms of TOS

Coracobrachialis and biceps brachii tension pull the coracoid process inferiorly. This causes the pectoralis minor to shorten and become hypertonic resulting in compression of the brachial plexus against the ribcage.



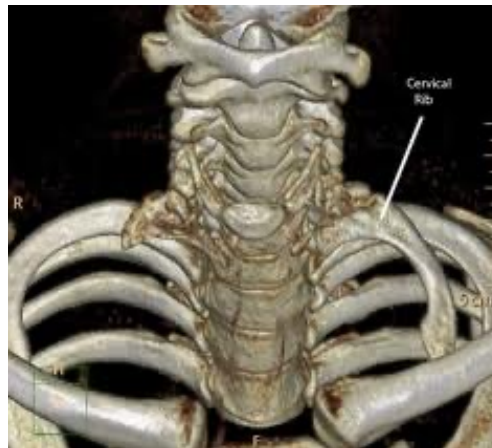Traditional Treatments of TOS

Postural re-education, stretching, and strengthening

- Effective.

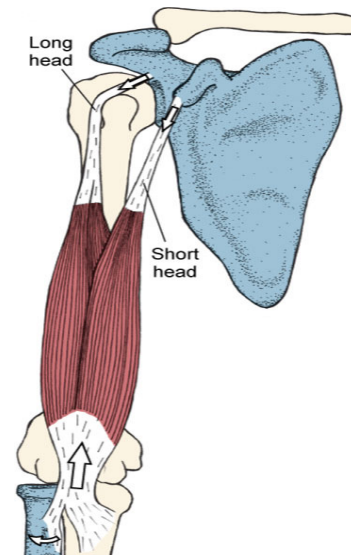
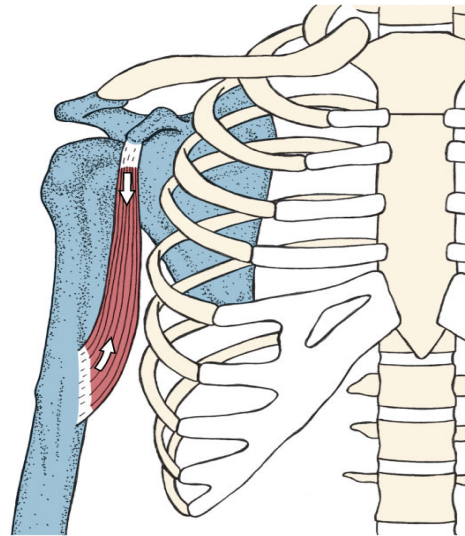
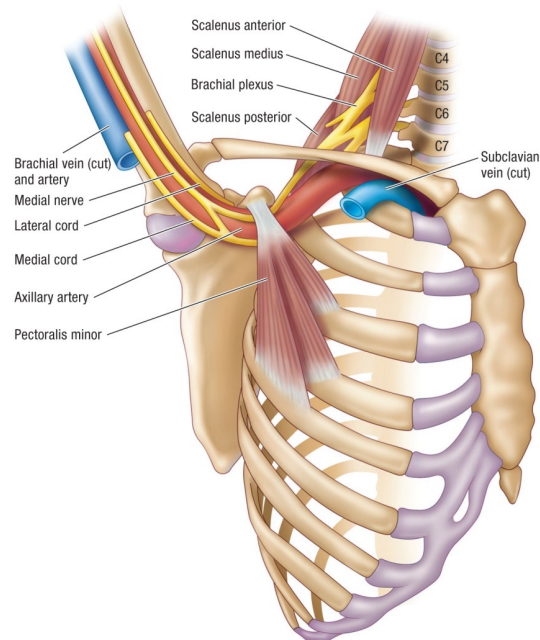
Surgery

- Variable effectiveness: most effective for true neurologic TOS.



Considerations and Cautions for TOS

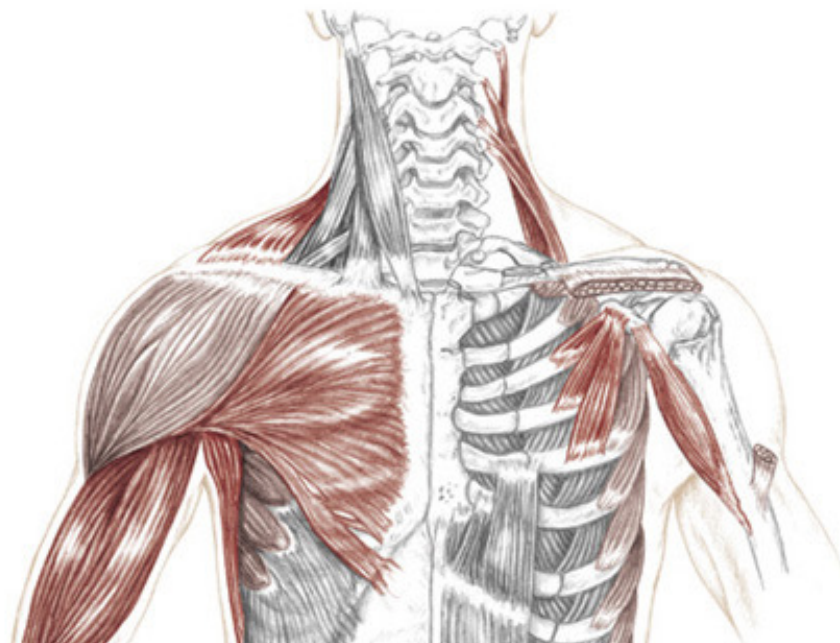
- Treat the soft tissues in ALL possible areas of compression.



- Address postural dysfunctions by using frequent postural corrections.

Considerations and Cautions for TOS

- Stretch cervical and shoulder girdle muscles to the point of mild pain or discomfort. This elongates the connective tissue component of the muscle, and changes the rate of stimulation in the neuromuscular component of the muscle, thus reducing tension.





Considerations and Cautions for TOS

- Exacerbation of neurological symptoms during muscular stretching may be due to stretching of neural tissues. Neural stretching may help to improve neural mobility. It is repetition, not tensile load that encourages greater mobility of the nerve between it and adjacent structures. Only perform the neural mobility technique after the entire upper extremity has been treated because it is more effective when the soft tissue along the path of the nerve is relaxed.



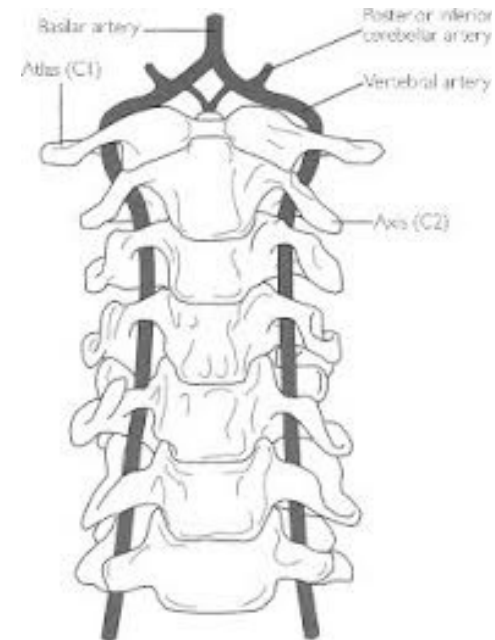
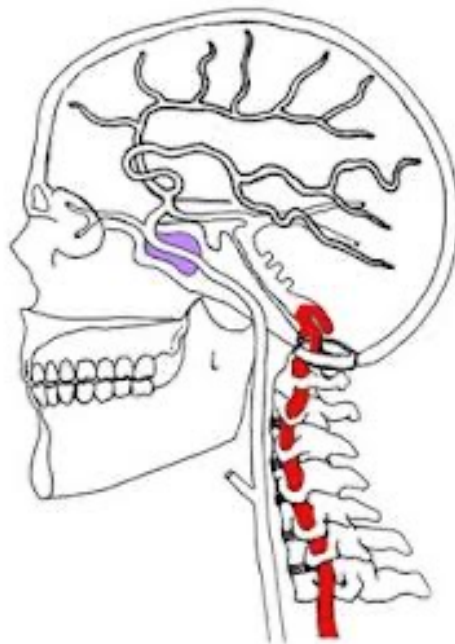
Considerations and Cautions for TOS

- In more severe cases where the suggested techniques aggravate the symptoms, simply reduce the pressure applied and focus on using the muscle energy techniques (MET) described in the protocols.

Muscle Energy Techniques (MET) are gentle manual therapies where a patient actively uses their own muscles (gentle isometric contractions) against a therapist's counterforce (resistance) to relax tight muscles, mobilize joints, improve range of motion, and reduce pain by utilizing neurological reflexes like reciprocal inhibition (contracting one muscle relaxes the opposite) and autogenic inhibition (contracting a muscle helps it relax deeper).

Considerations and Cautions for TOS

Vertebrobasilar insufficiency (AKA: VBI) Decreased blood flow to the brain. Caused by compression of the vertebral artery by the combined actions of neck rotation and hyperextension. Symptoms are dizziness, vertigo, blurred vision, or fainting.





Soft-Tissue Manipulation Seated Details



SEATED DETAILS - Thoracic Outlet Syndrome

Vertebrobasilar insufficiency test (VBI test)

- Perform while client is seated during interview
- Instruct the client:
 - “Look up and over your shoulder to one side”
 - “Hold this position for 30 seconds”
- The test is positive if the client experiences any of the following:
 - **Vertigo** Perception of a spinning motion (due to dysfunction of the vestibular system)
 - **Dizziness** Sensation of feeling off balance
 - **Nausea** Sensation of unease and discomfort in the upper stomach with an involuntary urge to vomit
 - Double vision or blurred vision
- **NOTE:** Vertebrobasilar insufficiency is a contraindication for active cervical flexion with longitudinal stripping



82a Orthopedic Massage Introduction - Thoracic Outlet