




17a Quiz and A&P: Skeletal System - Joint Actions and Articulations



17a A&P:

Skeletal System - Joint Actions and Articulations and Quiz Class Outline

| | |
|------------|--|
| 5 minutes | Attendance, Breath of Arrival, and Reminders |
| 20 minutes | 17a Quiz |
| 10 minutes | Lecture: AOI- Occipitalis, Frontalis, Temporalis, Masseter |
| 25 minutes | Lecture: |
| 60 minutes | Total |



17a Quiz and A&P: Skeletal System - Joint Actions and Articulations Class Reminders

Assignments:

- 17a Review Questions (A: 131-140) **DUE NOW!!**

Quizzes and Exams:

- 17a Quiz - **NOW!!**
(study all material from classes 9a, 9b, 11a, 12a, and 13b)
- 18a Kinesiology Quiz
(biceps, coracobrachialis, SCM, levator, scalenes, occipitofrontalis, temporalis, masseter)
- 19a Quiz
(study all material from classes 13a, 15a, 16a, 17a, and 18a)
- 21a Exam
(1b, 2a, 2b, 3a, 3b, 4a, 5a, 6a, 7a, 8b, 9a, 9b, 11a, 12a, 13a, 13b, 15a, 16a, 17a, 17b, and 18a)

Preparation for upcoming classes:

- 18a H&H: Therapeutic Relationships- Conflict, Transference, Dual Relationship, and Sexual Misconduct
- 18b Swedish: Technique Review and Practice - Chest, Arms, Neck, Face, and Scalp
 - Packet F: 55-56, and 58
- 21b CPR/ First Aid: **This class cannot be made in the make-up room.** To schedule a sit-in, students should contact the Student Administrator. To be exempt, bring a copy of your CPR & first aid certificate.



Classroom Rules

Punctuality - everybody's time is precious

- Be ready to learn at the start of class; we'll have you out of here on time
- Tardiness: arriving late, returning late after breaks, leaving during class, leaving early

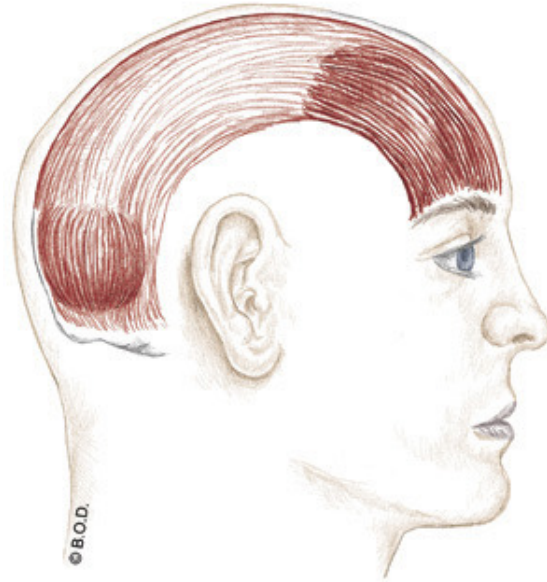The following are not allowed:

- Bare feet
- Side talking
- Lying down
- Inappropriate clothing
- Food or drink except water
- Phones that are visible in the classroom, bathrooms, or internship

You will receive one verbal warning, then you'll have to leave the room.

Frontalis and Occipitalis

Trail Guide, Page 258



Lateral View

Frontalis and Occipitalis together form the occipitofrontalis.

They are responsible for raising the forehead into an expression of surprise.

Although they are superficial, their thin fibers cannot be isolated.

Occipitofrontalis, page 258

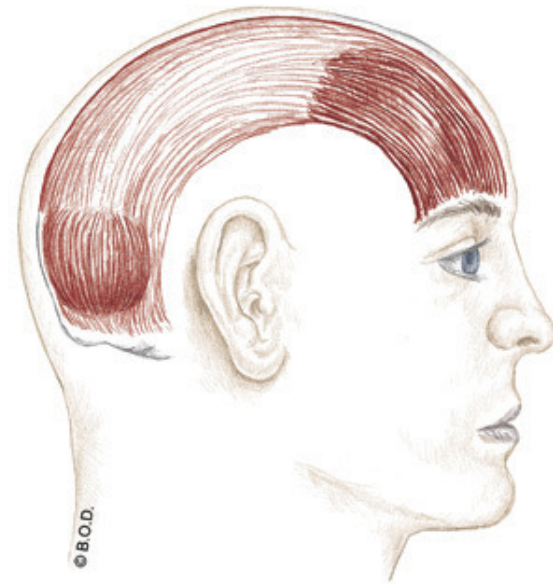A *Frontalis:*
Raise the eyebrows and wrinkle the forehead

Occipitalis:
Anchor and **retract** the galea posteriorly

O *Both:* Galea aponeurotica

I *Frontalis:*
Skin superior to eyebrows

Occipitalis:
Superior nuchal line of the occiput



Lateral View

Occipitofrontalis, page 258

A *Frontalis:*
Raise the eyebrows and wrinkle the forehead

Occipitalis:
Anchor and **retract** the galea posteriorly

O *Both:* Galea aponeurotica

I *Frontalis:*
Skin superior to eyebrows

Occipitalis:
Superior nuchal line of the occiput



Lateral View

Occipitofrontalis, page 258

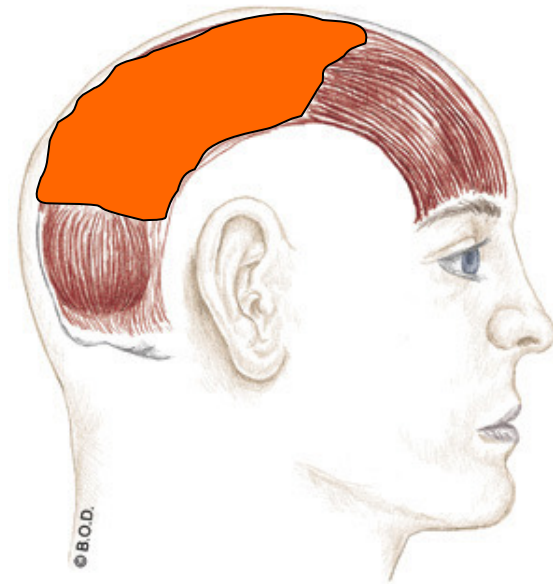A *Frontalis:*
Raise the eyebrows and wrinkle the forehead

Occipitalis:
Anchor and **retract** the galea posteriorly

O *Both: Galea aponeurotica*

I *Frontalis:*
Skin superior to eyebrows

Occipitalis:
Superior nuchal line of the occiput



Lateral View

Occipitofrontalis, page 258

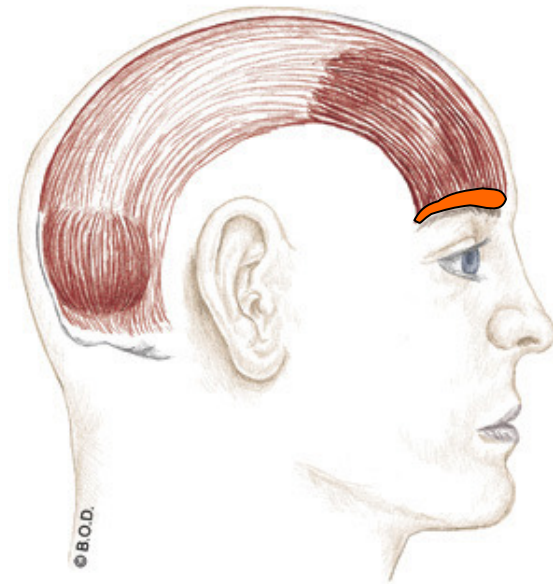A *Frontalis:*
Raise the eyebrows and wrinkle the forehead

Occipitalis:
Anchor and **retract** the galea posteriorly

O *Both:* Galea aponeurotica

I *Frontalis:*
Skin superior to eyebrows

Occipitalis:
Superior nuchal line of the occiput



Lateral View

Occipitofrontalis, page 258

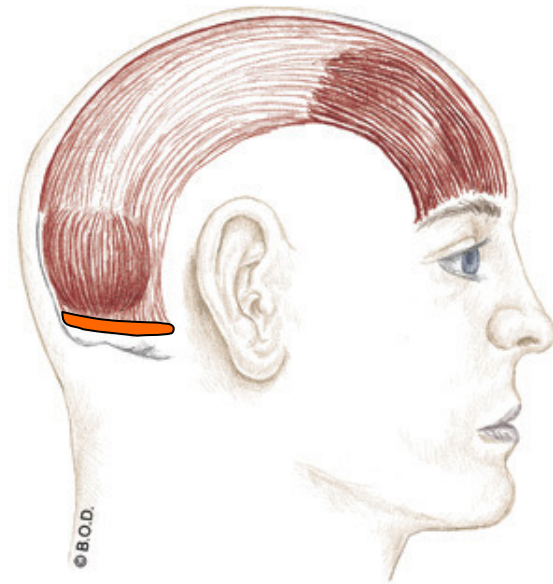A *Frontalis*:
Raise the eyebrows and wrinkle the forehead

Occipitalis:
Anchor and **retract** the galea posteriorly

O *Both*: Galea aponeurotica

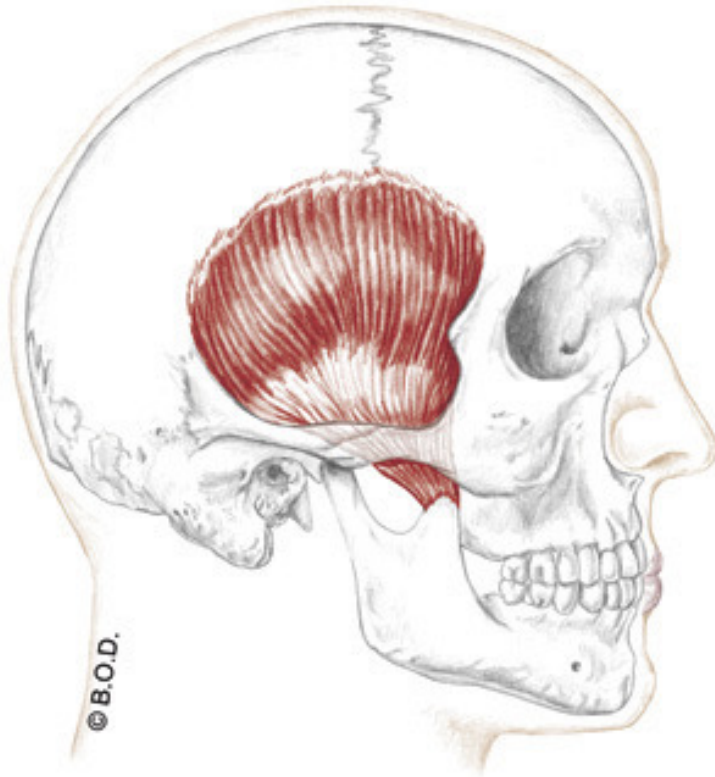
I *Frontalis*:
Skin superior to eyebrows

Occipitalis:
Superior nuchal line of the occiput



Lateral View

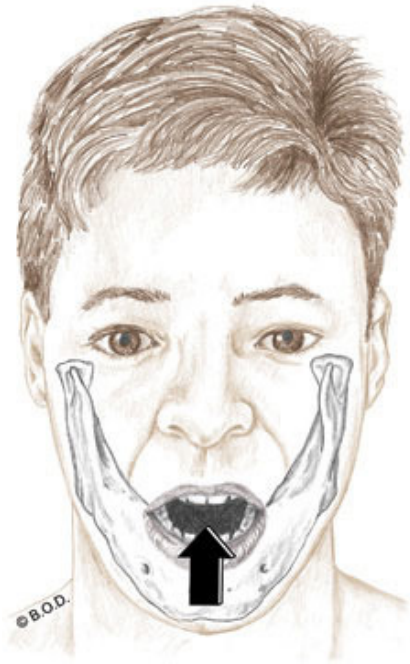Temporalis, page 251



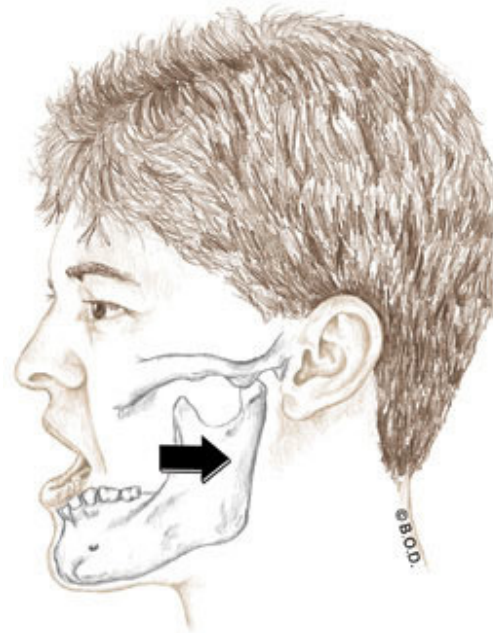
Lateral View

Temporalis is located on the temporal aspect of the cranium with its broad origin attaching to the frontal, temporal, and parietal bones.

Actions of the Temporalis



Elevation of the mandible



Retraction of the mandible

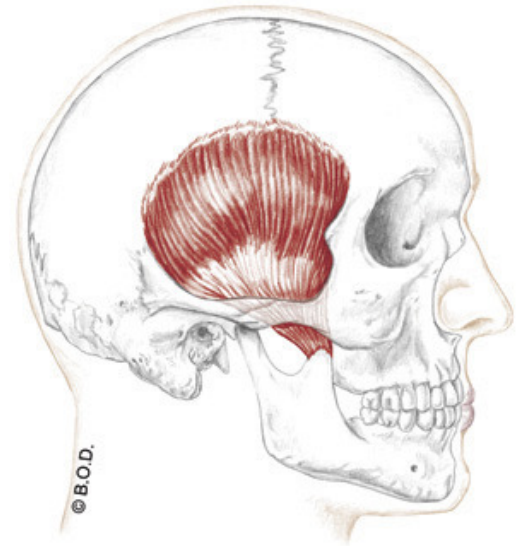
Temporalis, page 251

A Elevate the mandible (temporomandibular joint)

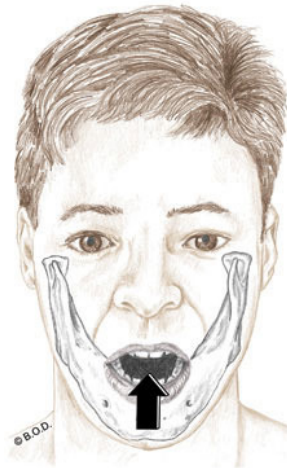Retract the mandible (temporomandibular joint)

O Temporal fossa
Temporal fascia

I Coronoid process of the mandible
Anterior edge of the ramus of the mandible



Lateral View



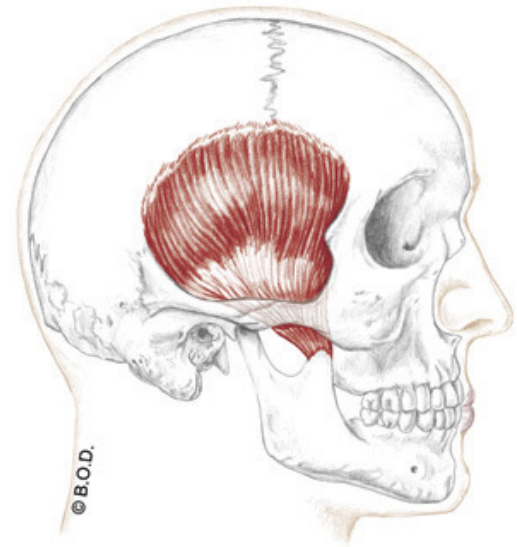
Temporalis, page 251

A Elevate the mandible (temporomandibular joint)

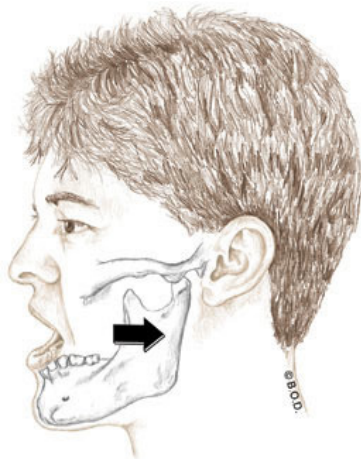
R Retract the mandible (temporomandibular joint)

O Temporal fossa
Temporal fascia

I Coronoid process of the mandible
Anterior edge of the ramus of the mandible



Lateral View



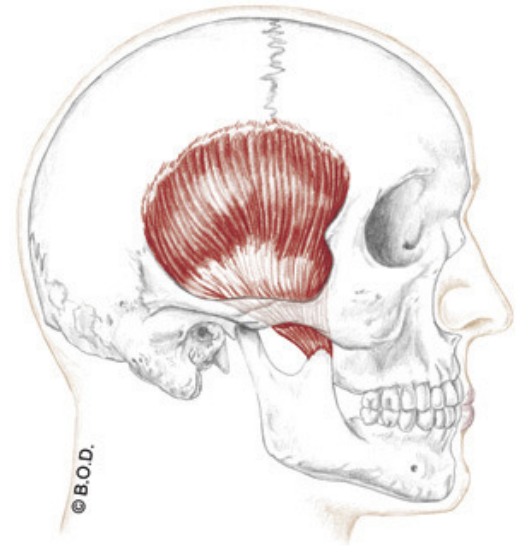
Temporalis, page 251

A Elevate the mandible (temporomandibular joint)

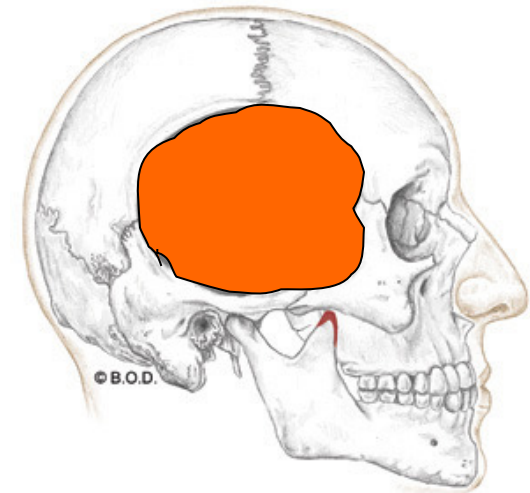
Retract the mandible (temporomandibular joint)

O Temporal fossa
Temporal fascia

I Coronoid process of the mandible
Anterior edge of the ramus of the mandible



Lateral View



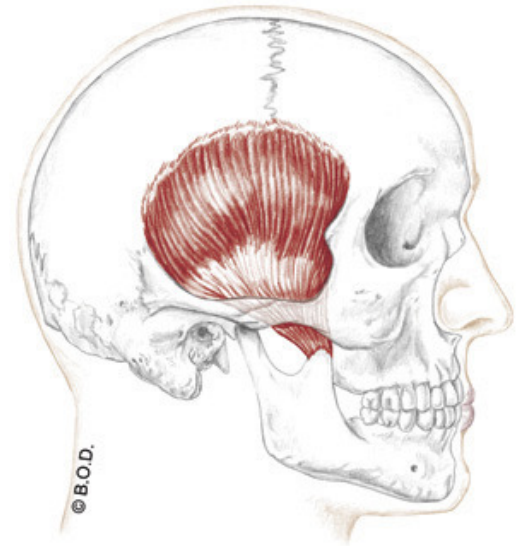
Temporalis, page 251

A Elevate the mandible (temporomandibular joint)

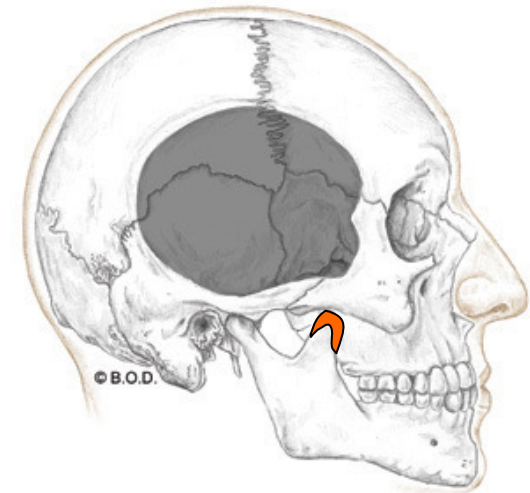
Retract the mandible (temporomandibular joint)

O Temporal fossa
Temporal fascia

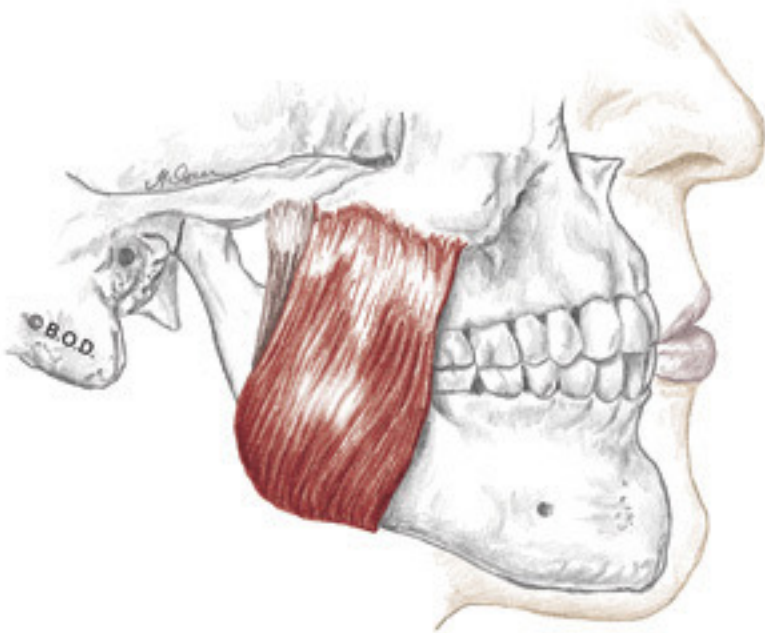
I Coronoid process of the mandible
Anterior edge of the ramus of the mandible



Lateral View



Masseter, page 250



Lateral View

Masseter is the strongest muscle in the body relative to its size.

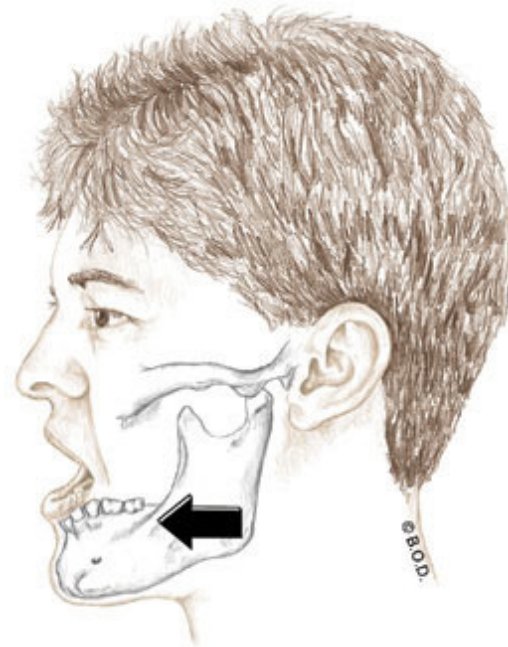
The two masseters together exert nearly one-hundred-fifty pounds of pressure.

Along with temporalis, masseter is a muscle of mastication.

Actions of the Masseter



Elevation of the mandible



Protraction of the mandible

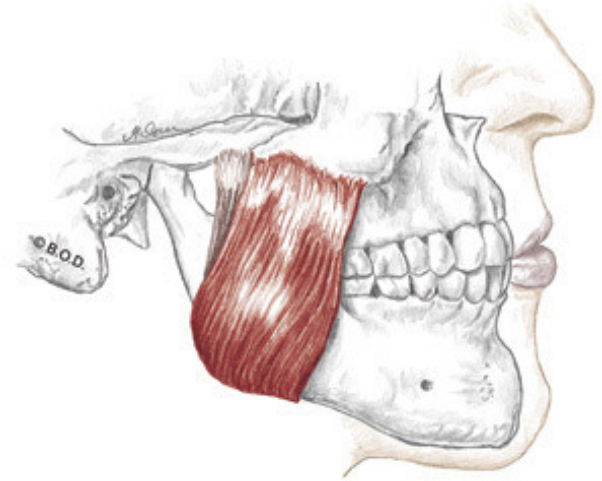
Masseter, page 250

A Elevate the mandible (temporomandibular joint)

May assist to **protract** the mandible (TM joint)

O Zygomatic arch

I Angle of the mandible
Ramus of the mandible



Lateral View



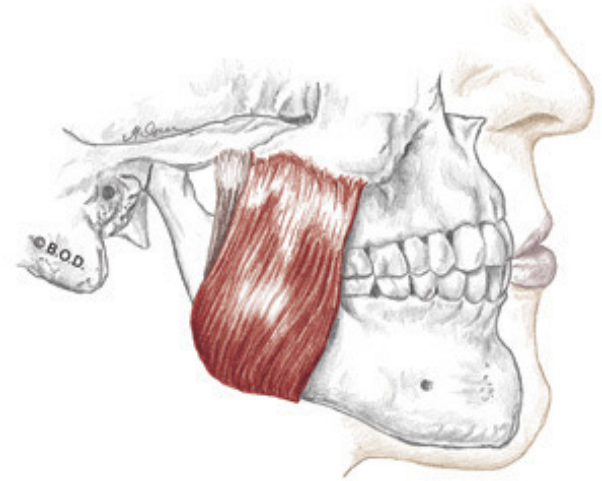
Masseter, page 250

A Elevate the mandible (temporomandibular joint)

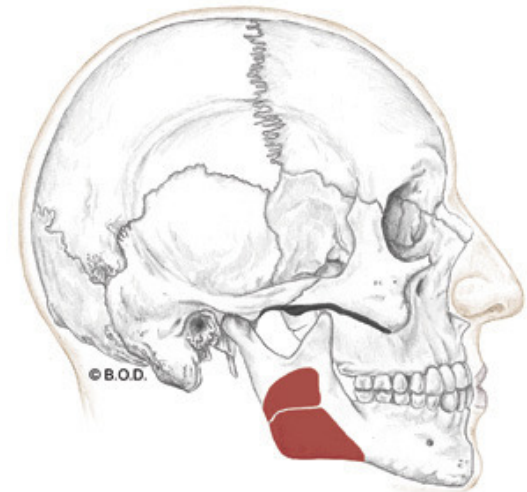
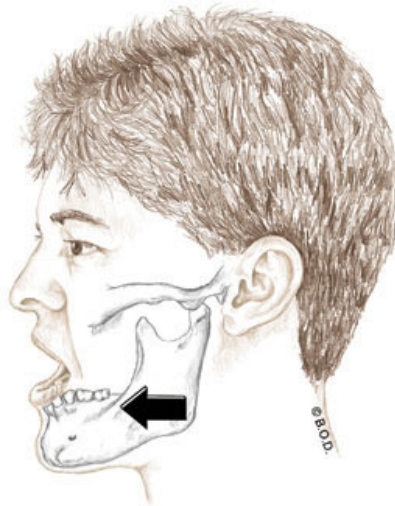
May assist to **protract** the mandible (TM joint)

O Zygomatic arch

I Angle of the mandible
Ramus of the mandible



Lateral View



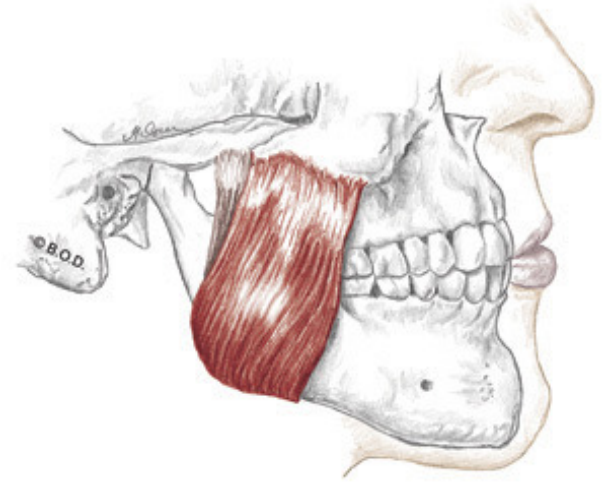
Masseter, page 250

A Elevate the mandible (temporomandibular joint)

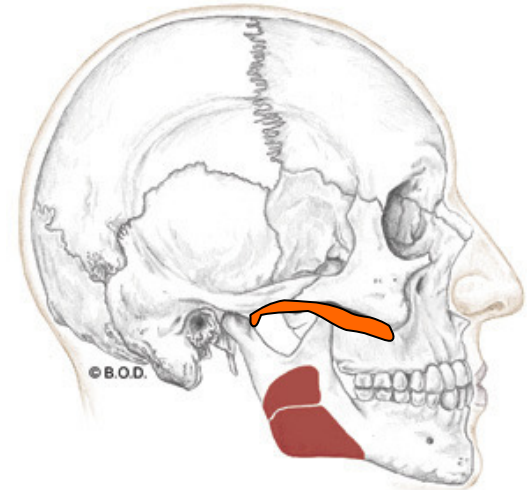
May assist to **protract** the mandible (TM joint)

O Zygomatic arch

I Angle of the mandible
Ramus of the mandible



Lateral View



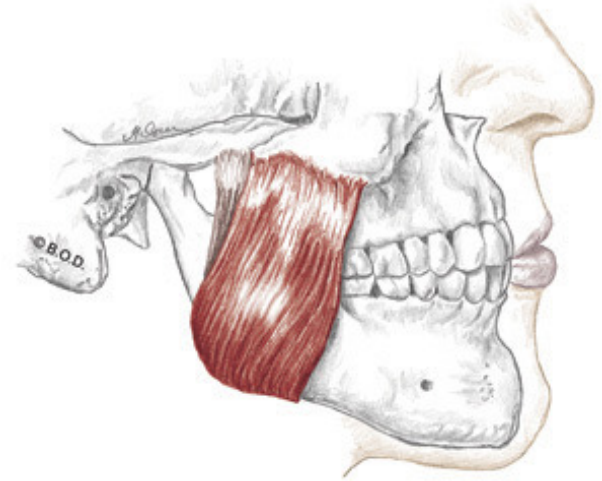
Masseter, page 250

A Elevate the mandible (temporomandibular joint)

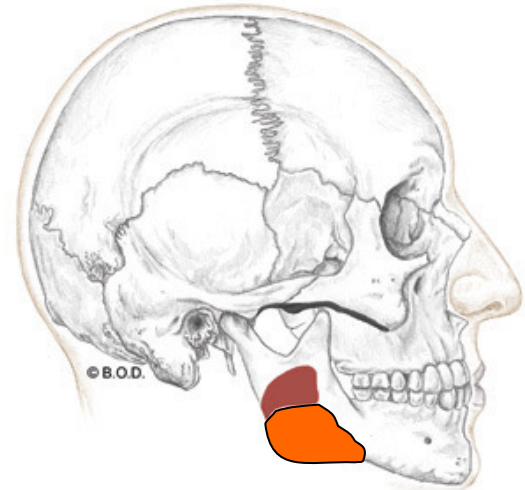
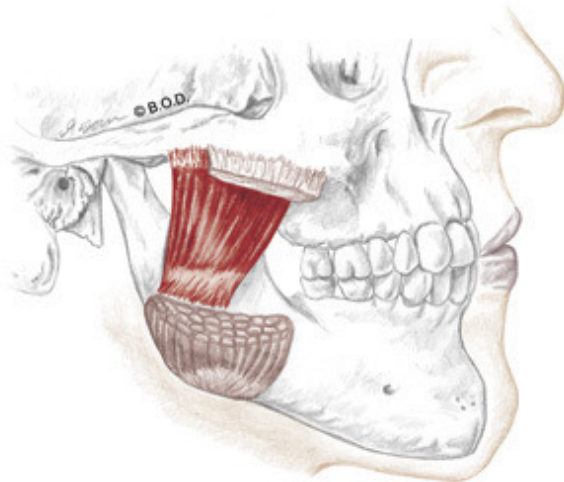
May assist to **protract** the mandible (TM joint)

O Zygomatic arch

I Angle of the mandible
Ramus of the mandible



Lateral View



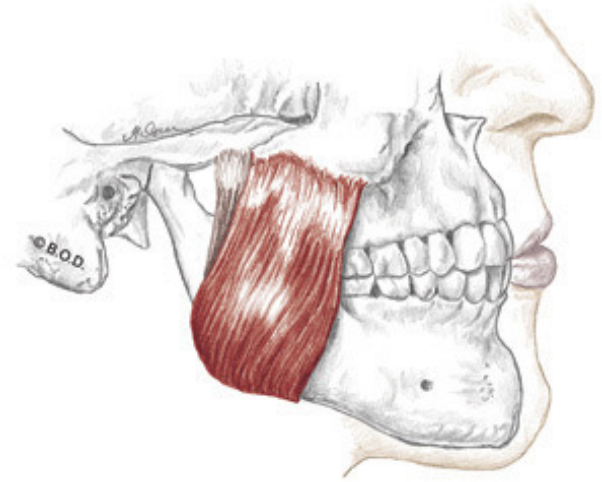
Masseter, page 250

A Elevate the mandible (temporomandibular joint)

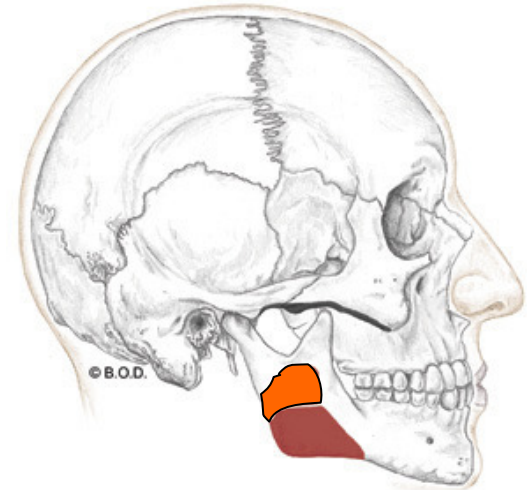
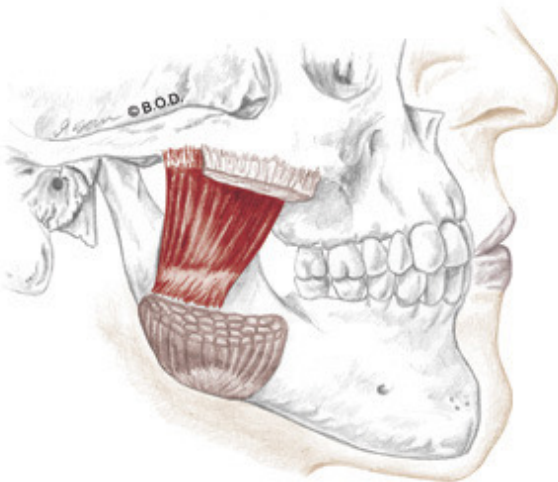
May assist to **protract** the mandible (TM joint)

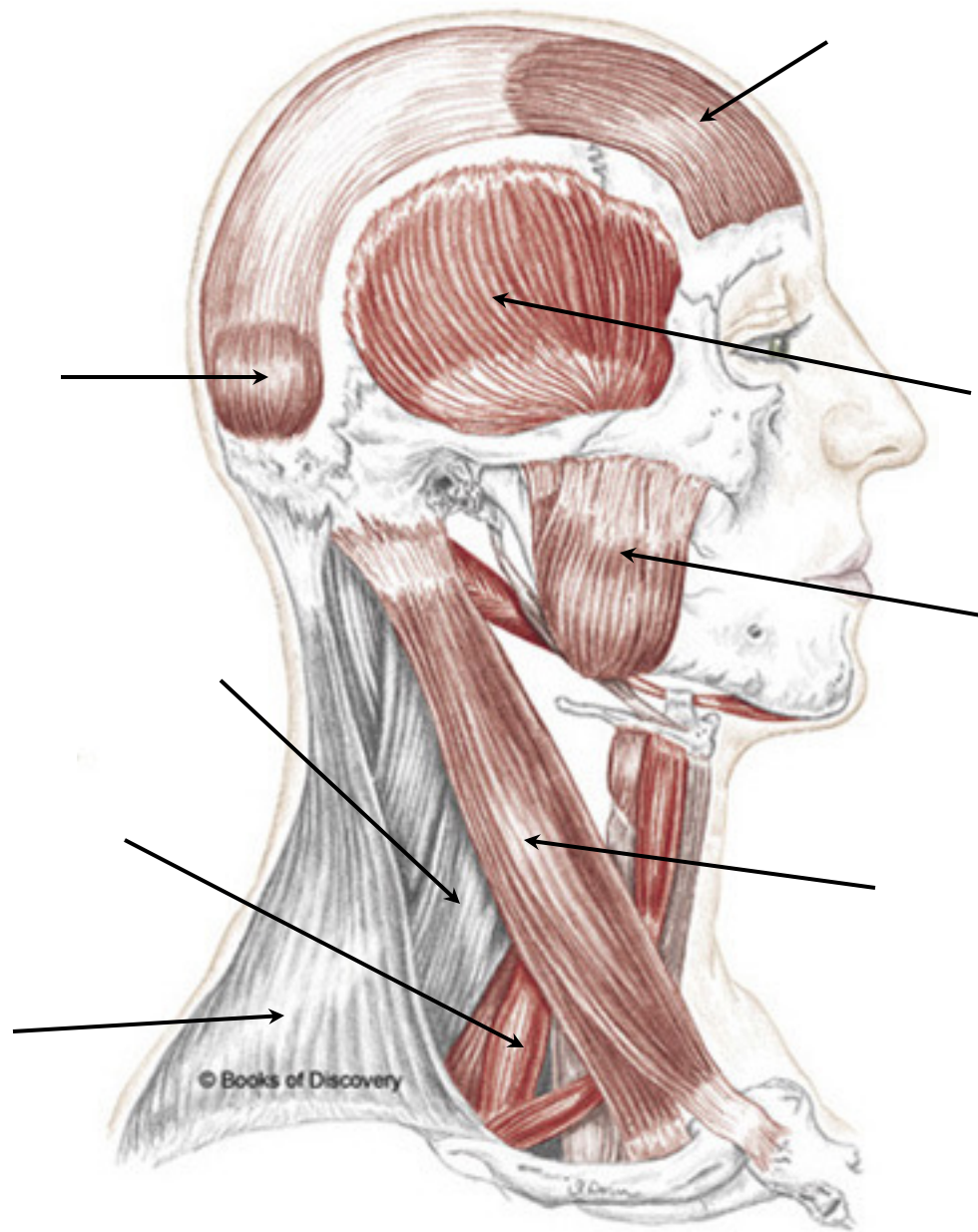
O Zygomatic arch

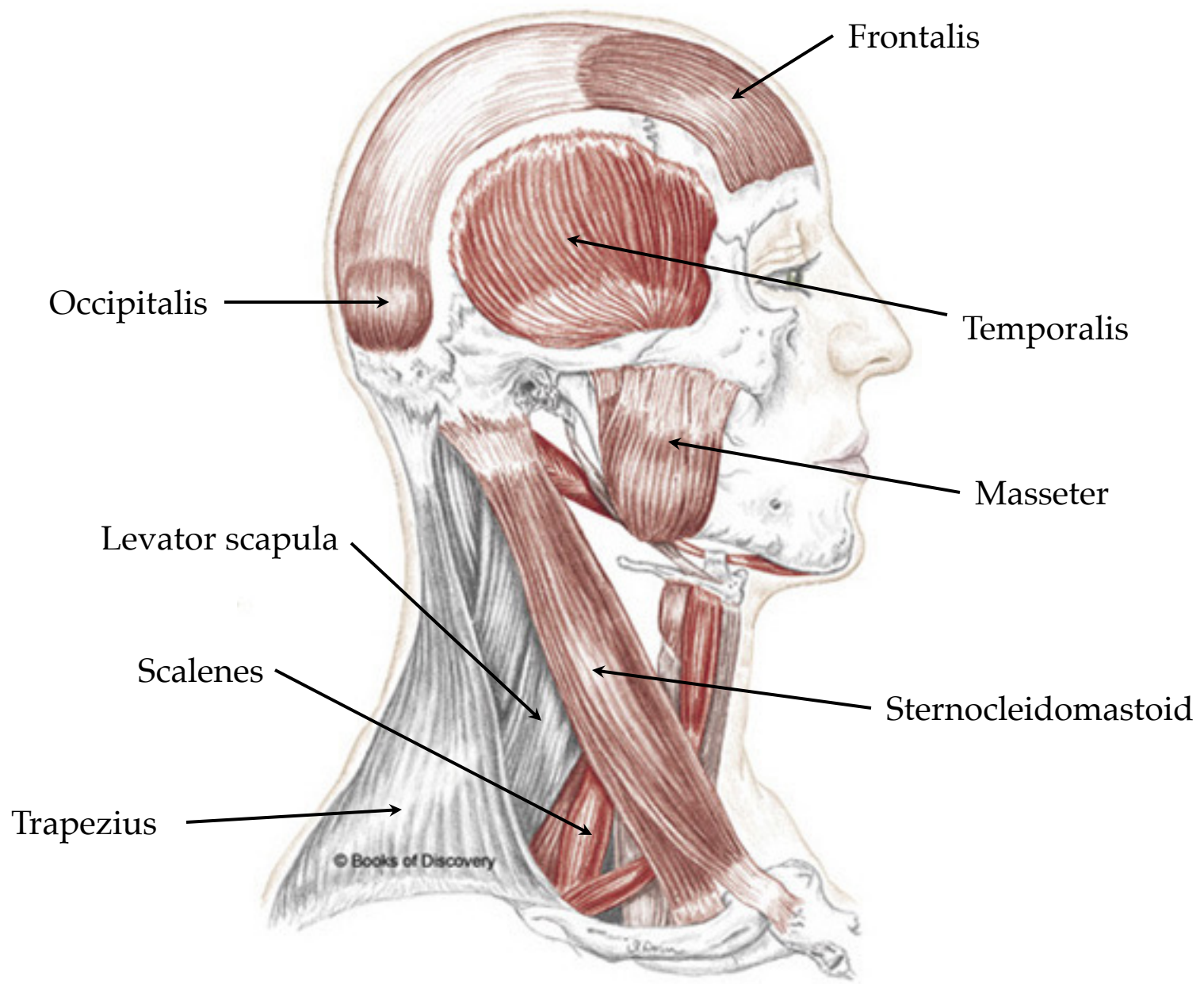
I Angle of the mandible
Ramus of the mandible




Lateral View









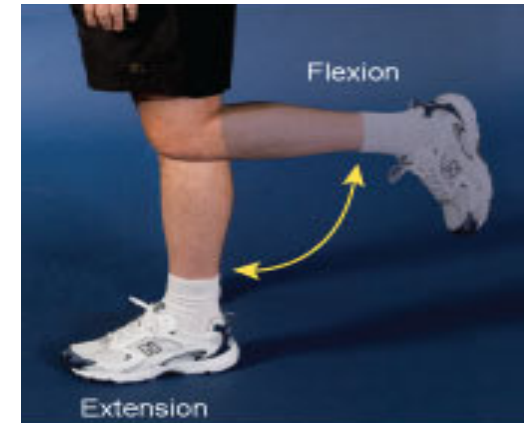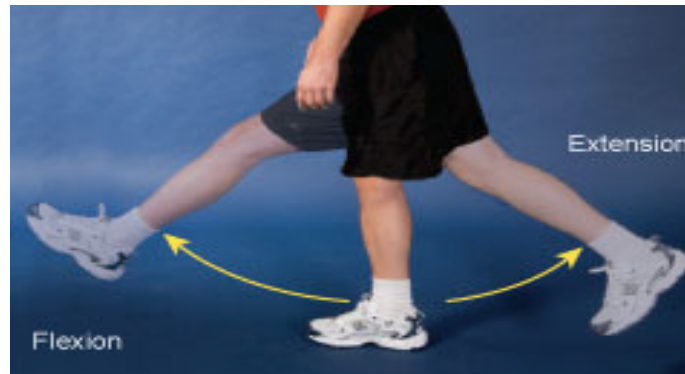17a A&P: Skeletal System - Joint Actions and Articulations and Quiz

E-25

Actions and Articulations

Flexion Bending or decreasing the angle of a joint.

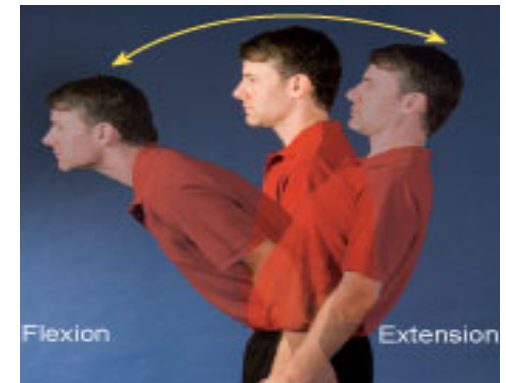
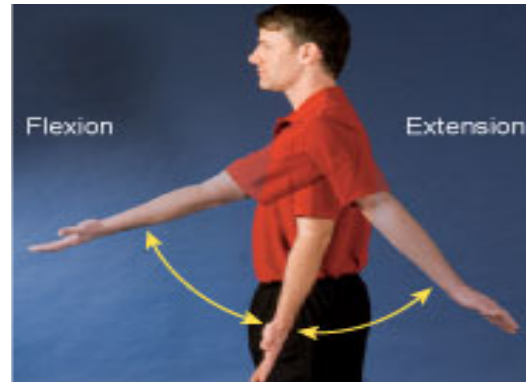
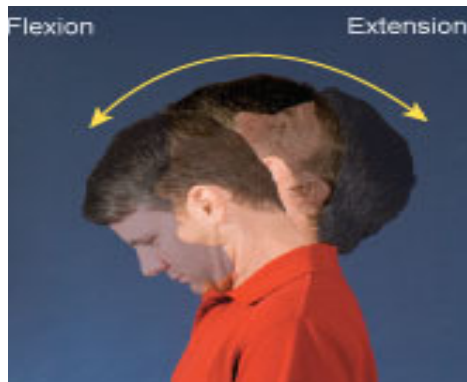Extension Straightening or increasing the angle of a joint.



Actions and Articulations

Flexion Bending or decreasing the angle of a joint.

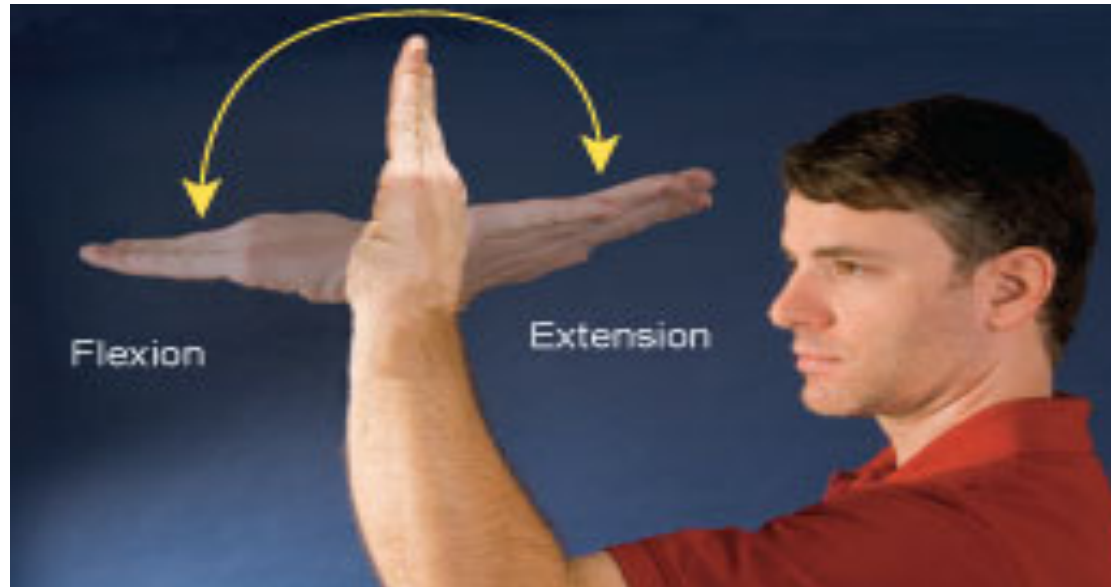Extension Straightening or increasing the angle of a joint.



Actions and Articulations

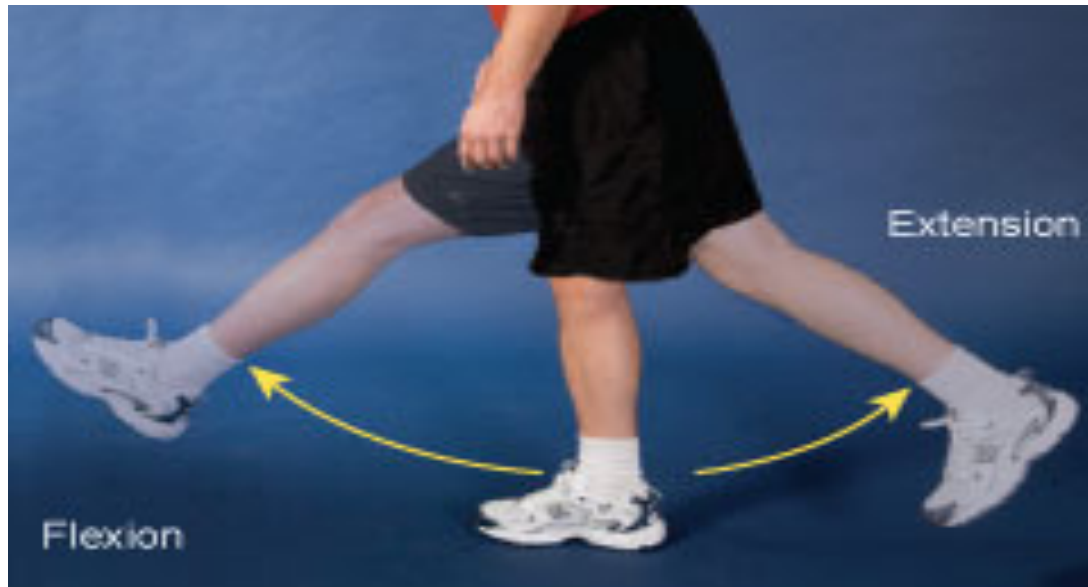Flexion Bending or decreasing the angle of a joint.

Extension Straightening or increasing the angle of a joint.



Actions and Articulations

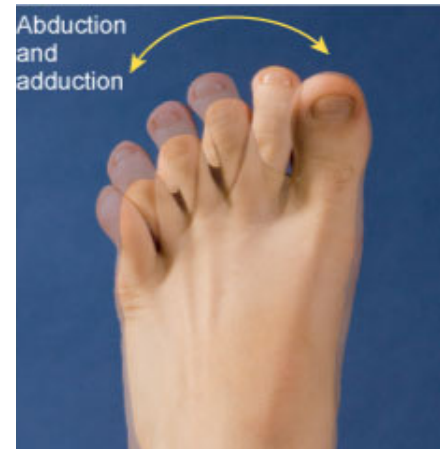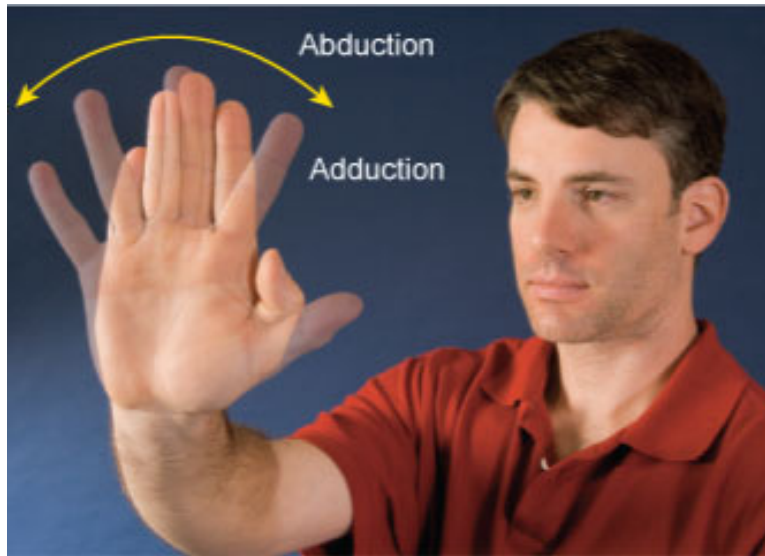Hyperextension A continuation of extension beyond anatomic position.



Actions and Articulations

Abduction Movement away from the median plane.

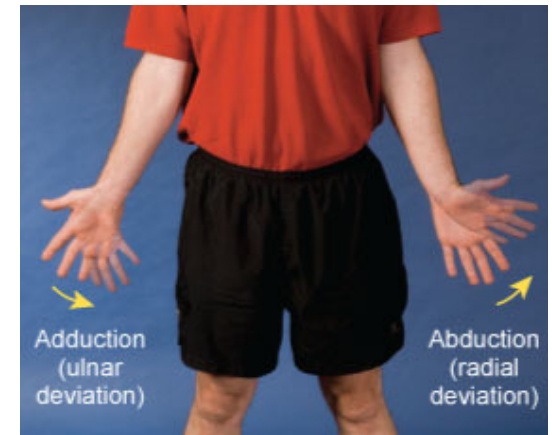Adduction Movement toward the median plane.



Actions and Articulations

Abduction Movement away from the median plane.

Adduction Movement toward the median plane.



Actions and Articulations

Supination Lateral rotation of the forearm so that the palm is turned up.

Pronation Medial rotation of the forearm so that the palm is turned down.

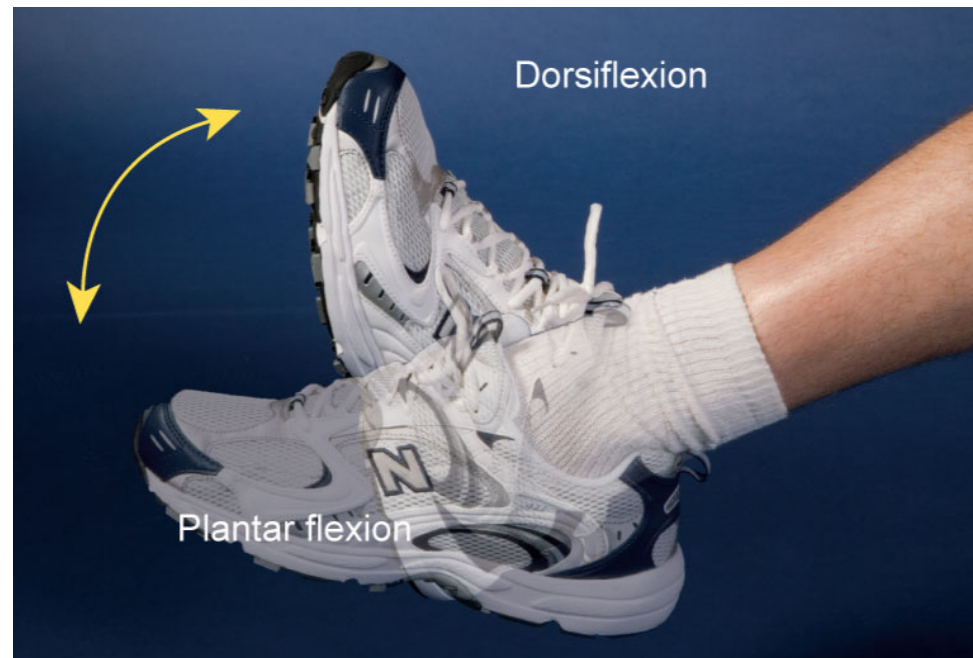

Actions and Articulations

Plantarflexion Extension of the ankle such that the toes are pointing downward

:

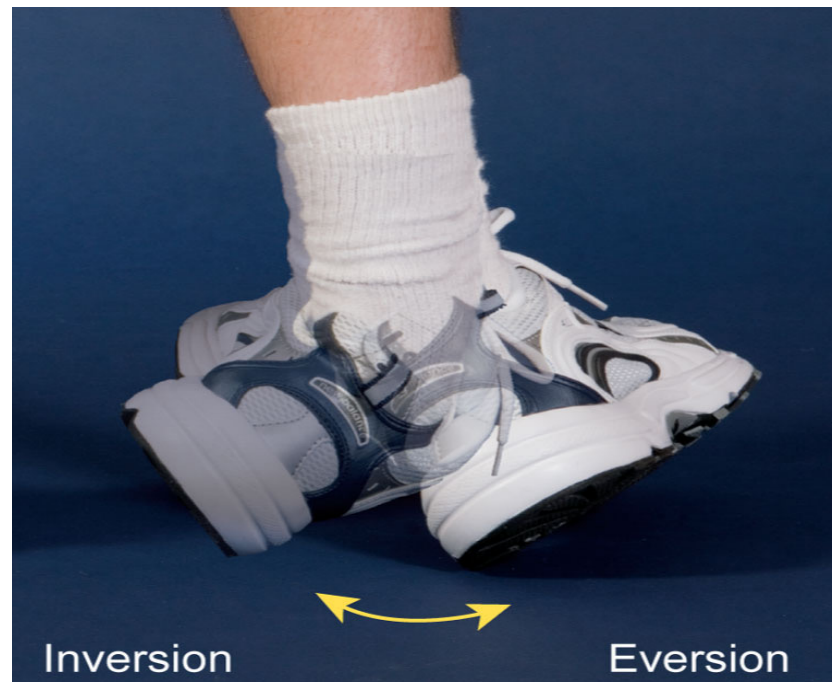Dorsiflexion Flexing the ankle dorsally.
Toes are moving toward the shin.



Actions and Articulations

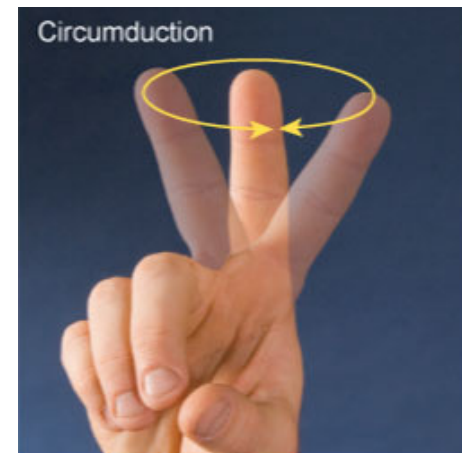
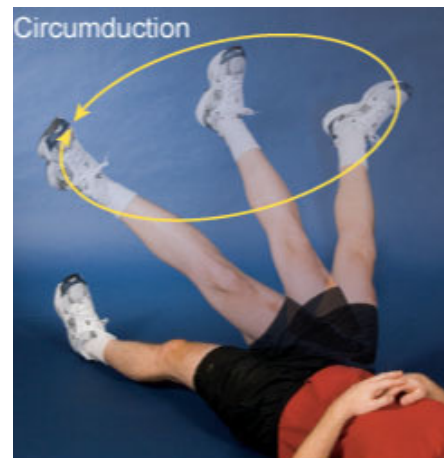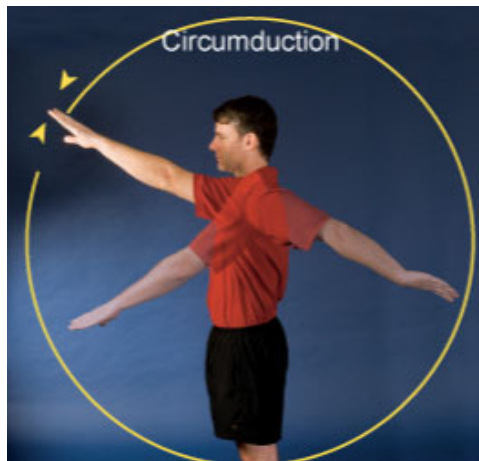
Inversion Elevation of the medial, edge of the foot. Sole is turned inward.

Eversion Elevation of the lateral, edge of the foot. Sole is turned outward.



Actions and Articulations

Circumduction Cone-shaped range of motion that occurs when the distal end moves in a circle and the proximal end is fixed.



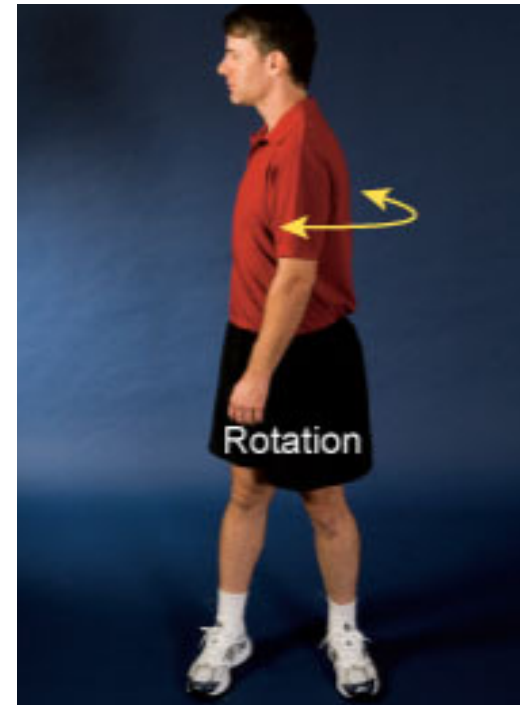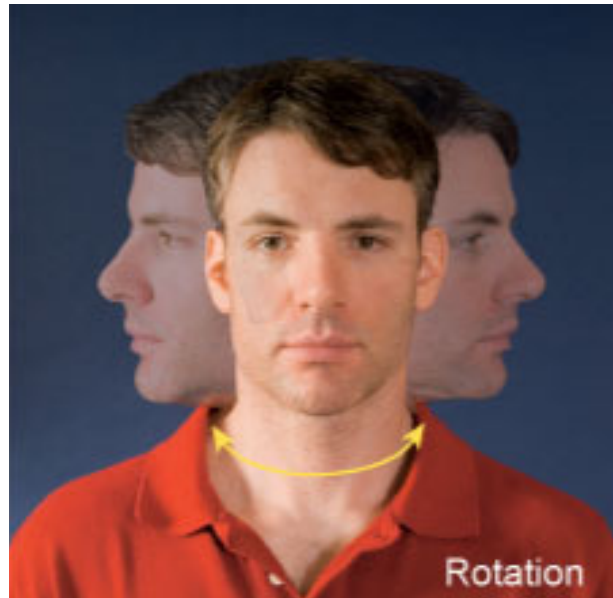


Actions and Articulations

Rotation Circular movement when a bone moves around its own central axis.

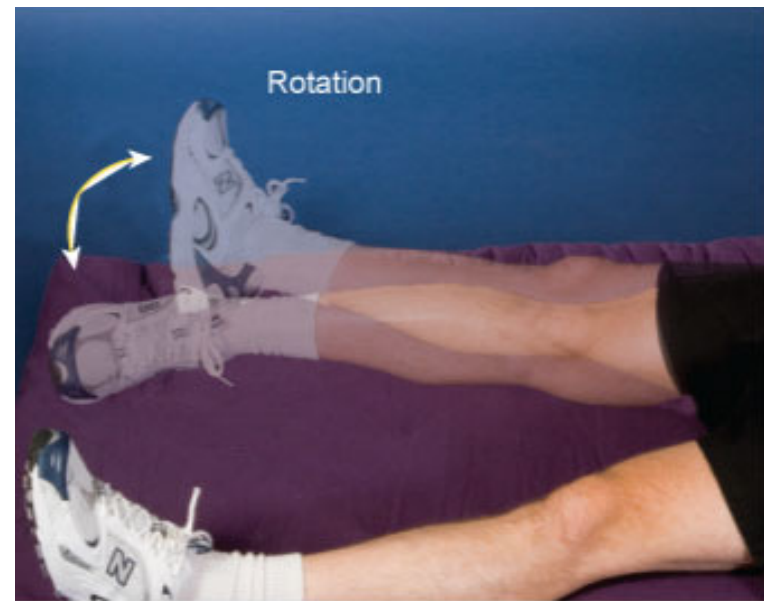
Actions and Articulations

Left and right rotation Rotation for joints within the median axis.



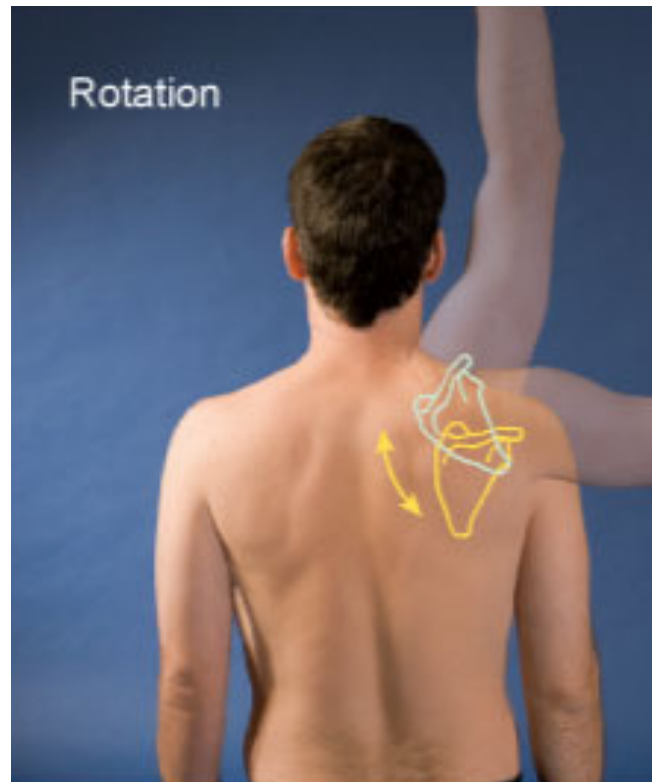
Actions and Articulations

Lateral and medial rotation Rotation for joints outside of the median axis.



Actions and Articulations

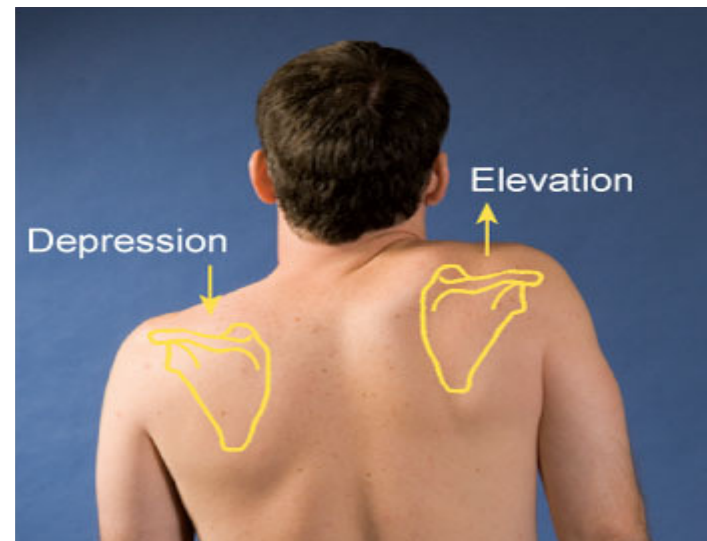
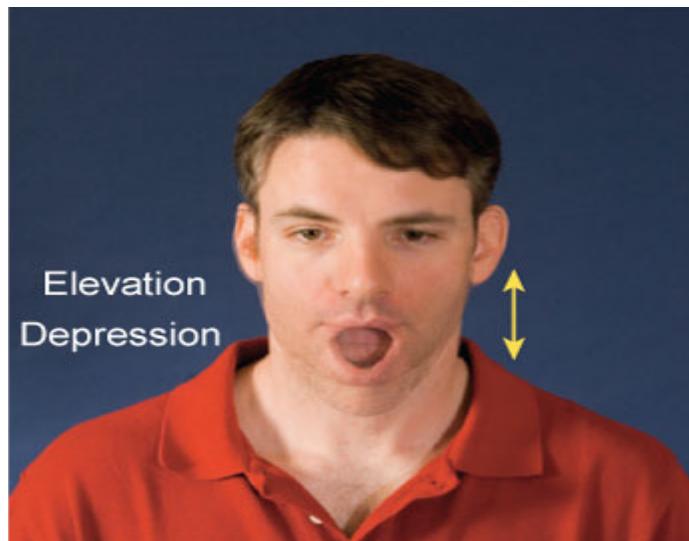Upward and downward rotation Rotation of the scapula so that the glenoid fossa faces either upward or downward.



Actions and Articulations

Elevation Raising or lifting a body part, moving superiorly.

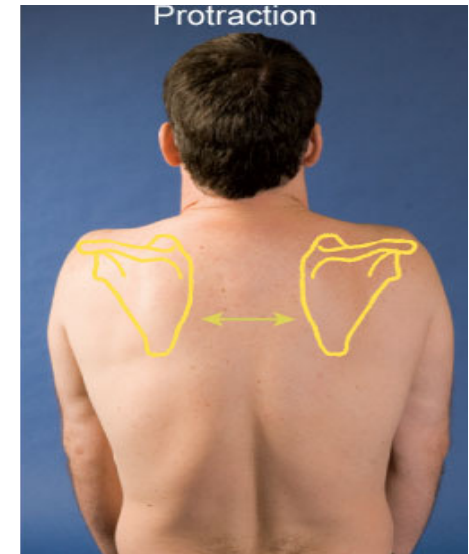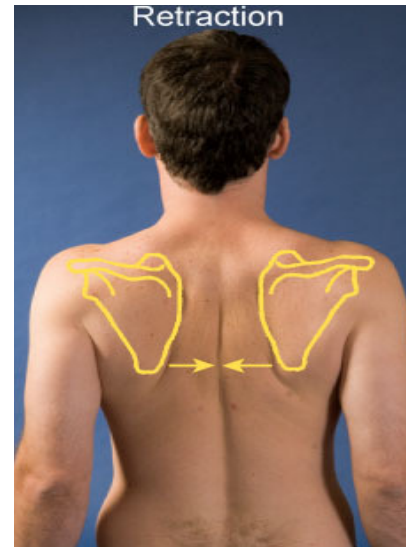
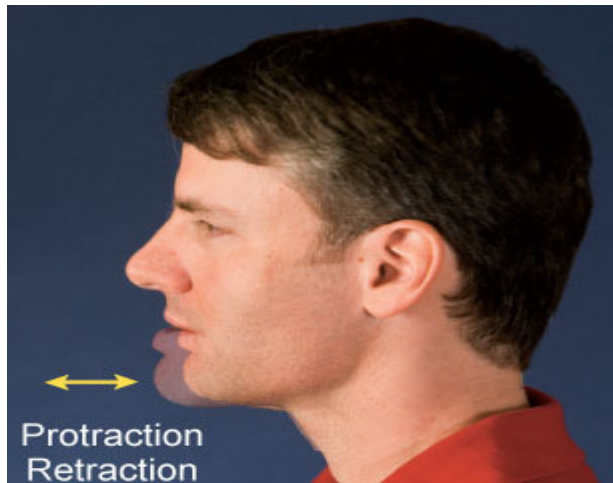
Depression Lowering or dropping a body part, moving inferiorly.



Actions and Articulations

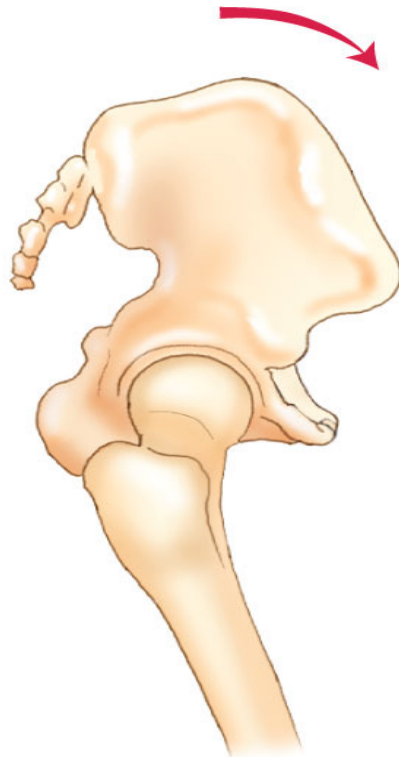Protraction Movement forward or anteriorly.

Retraction Movement backward or posteriorly.

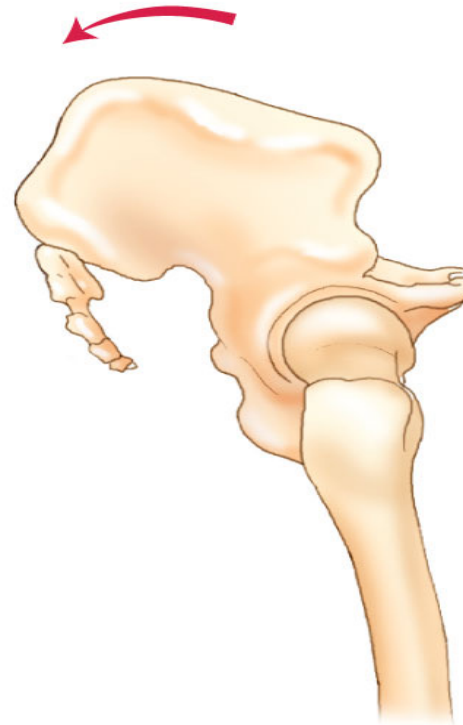

Actions and Articulations

Anterior pelvic tilt Entire pelvis tilted forward in the frontal plane.

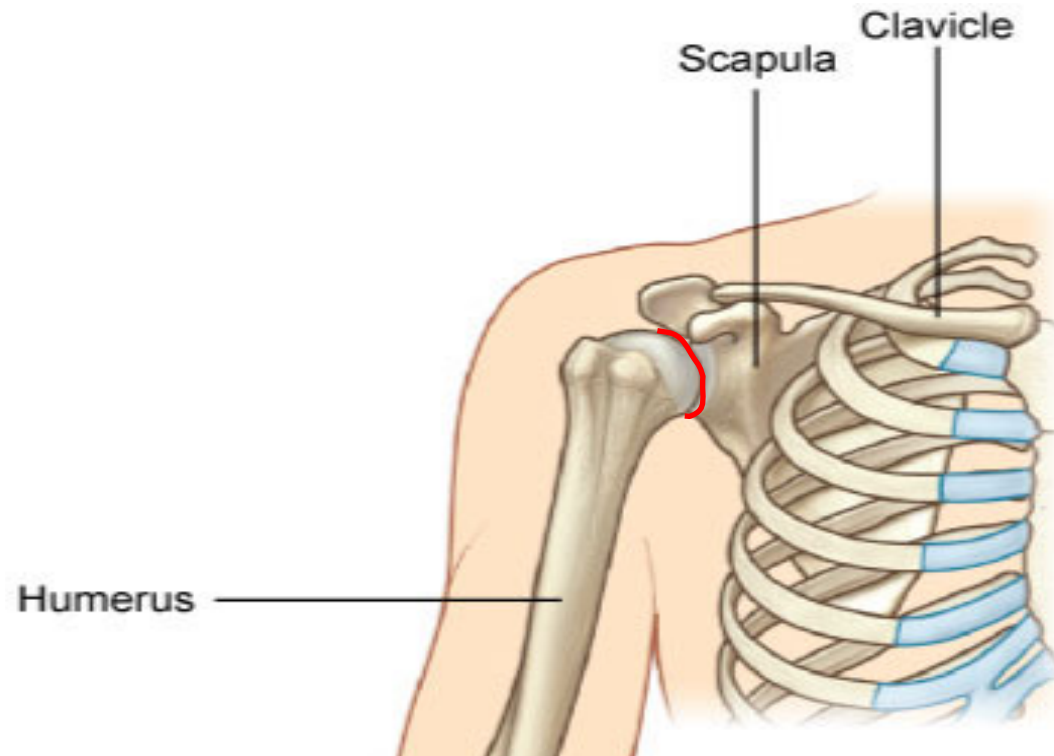


Posterior pelvic tilt Entire pelvis tilted backward in the frontal plane.



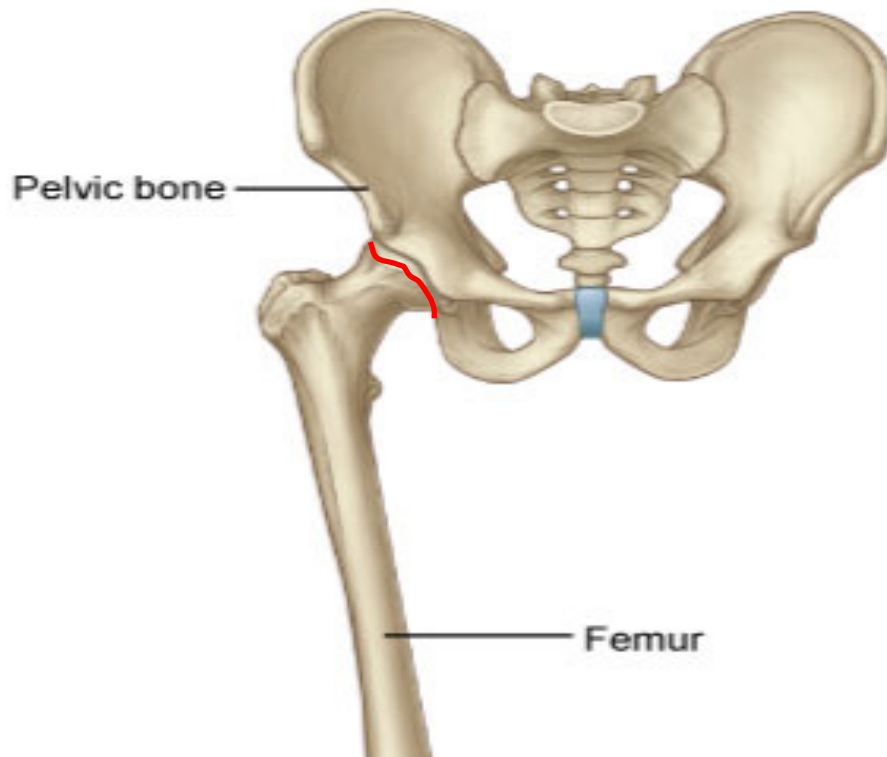
Synovial Joints: Ball and Socket

Glenohumeral Shoulder joint.



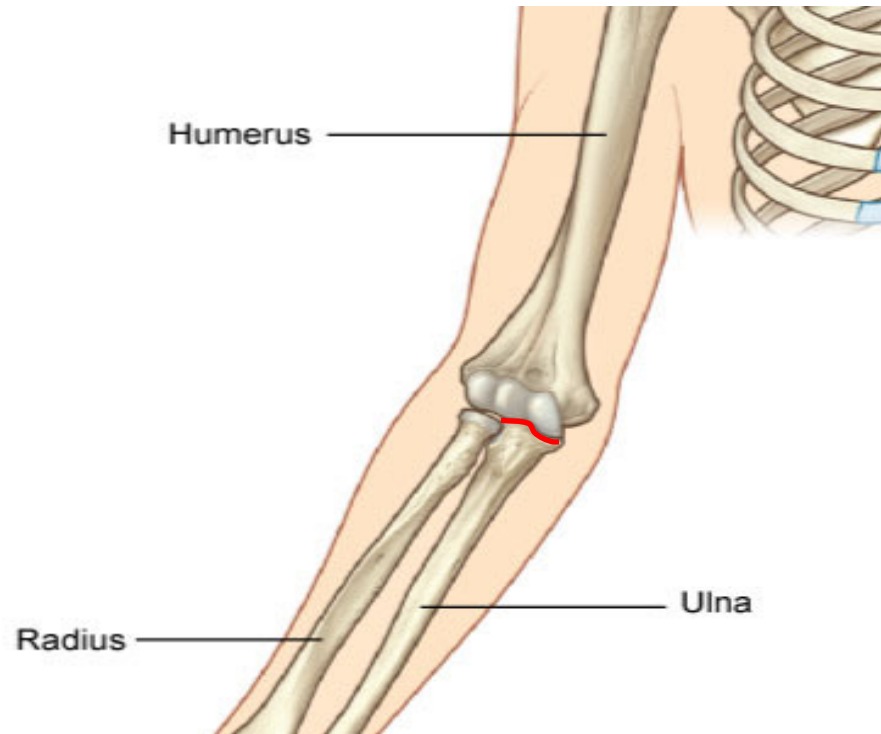
Synovial Joints: Ball and Socket

Coxal / Iliofemoral Hip joint.



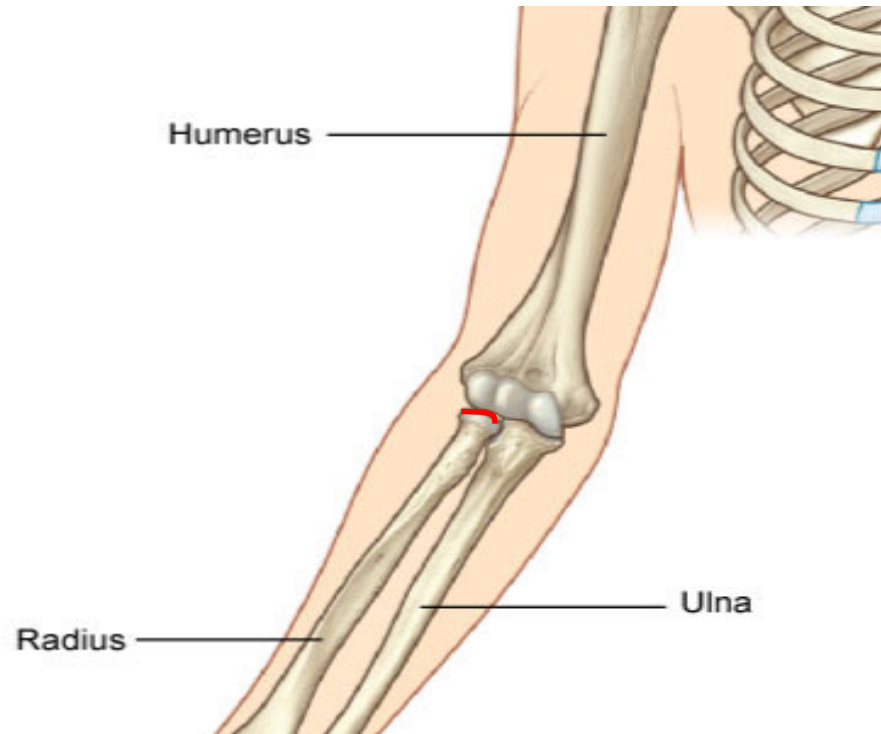
Synovial Joints: Hinge

Humeroulnar Elbow joint.



Synovial Joints: Hinge

Humeroradial Elbow joint.

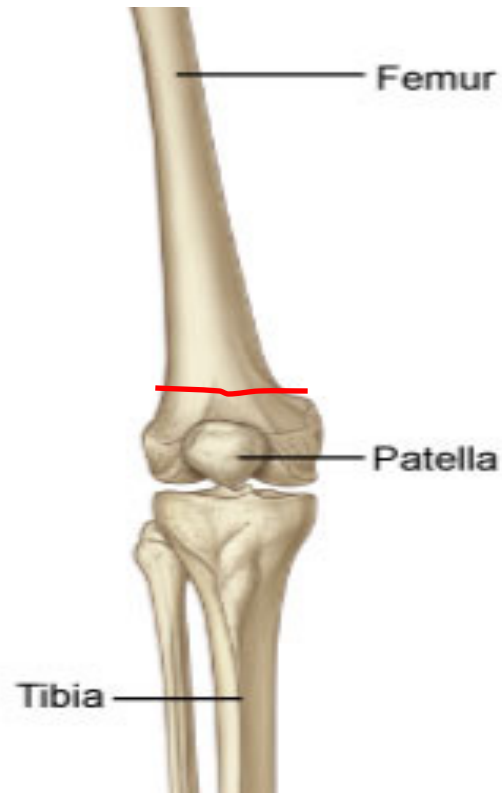

Synovial Joints: Hinge

Tibiofemoral Knee joint.

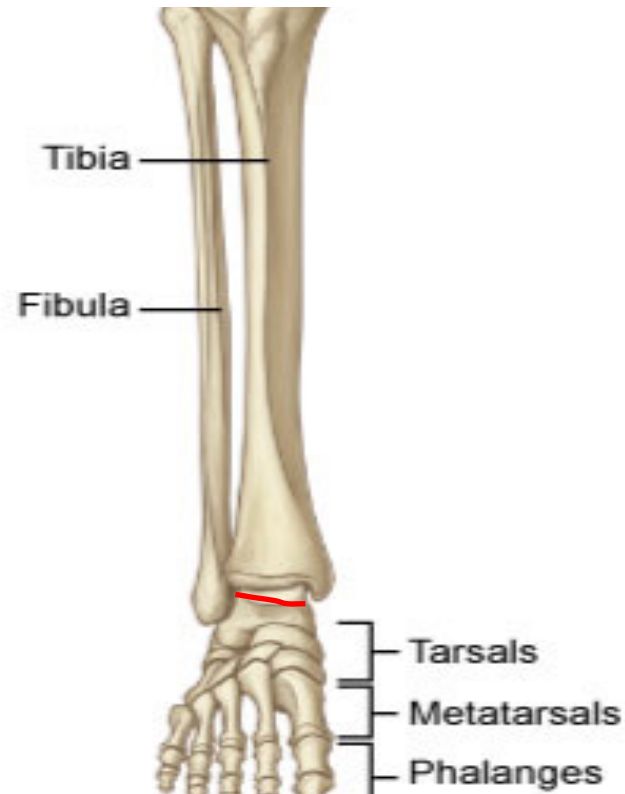
Primary action is flexion and extension.

When the knee is flexed, there can be slight rotation with the help from the hamstrings. Classification remains as a modified hinge joint.



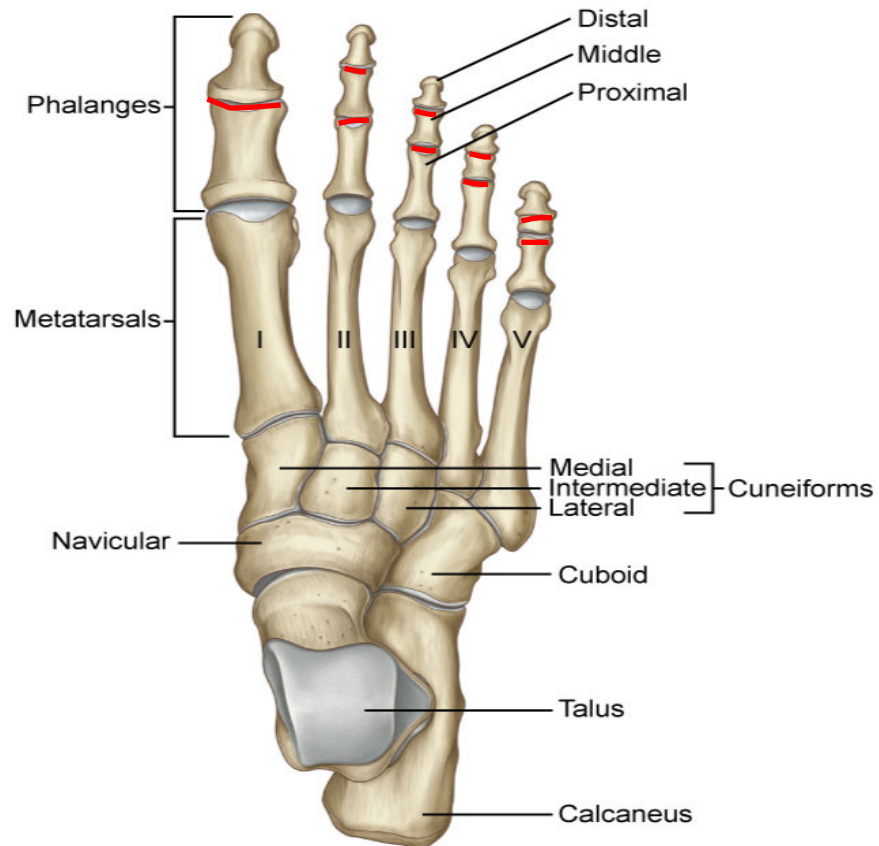
Synovial Joints: Hinge

Talocrural Ankle joint.



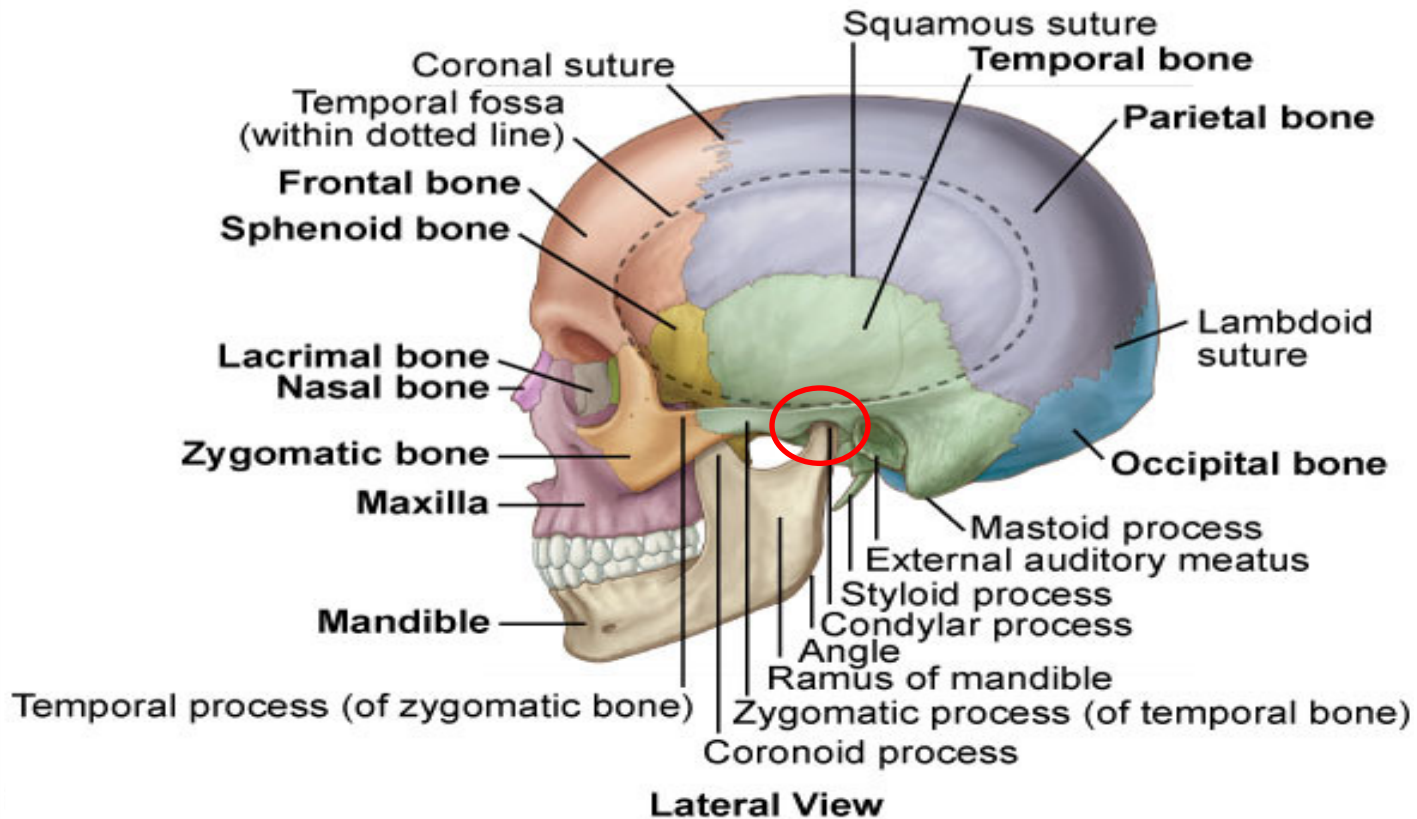
Synovial Joints: Hinge

Interphalangeal IP joint.



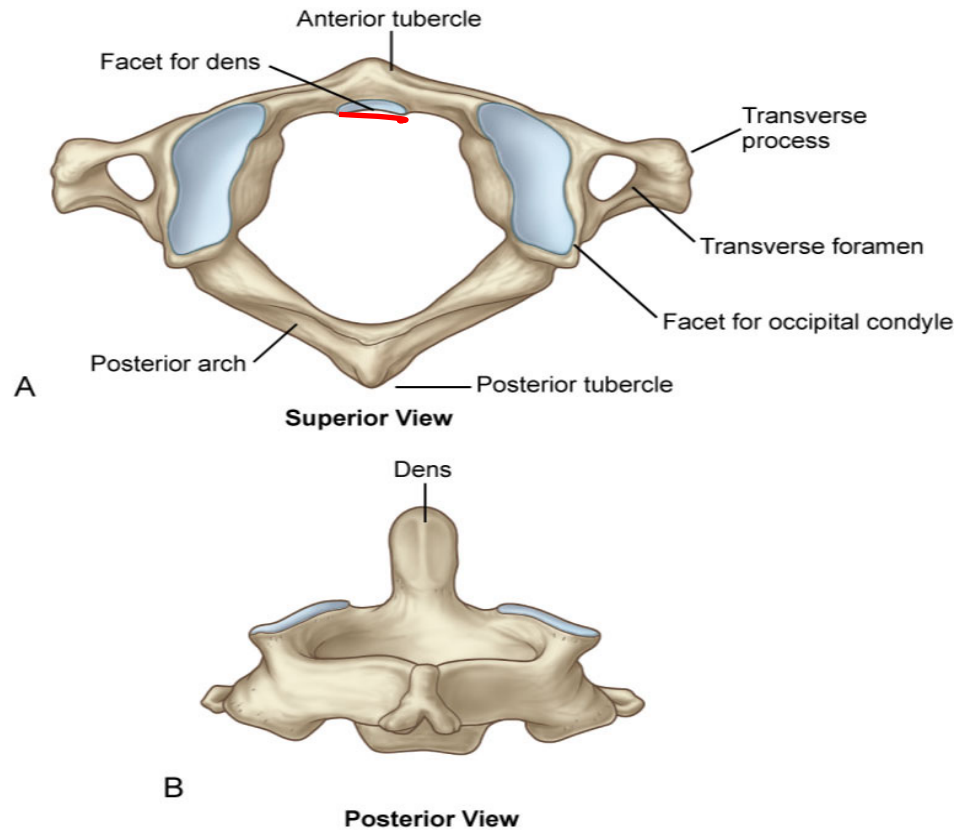
Synovial Joints: Hinge

Temporomandibular TMJ, jaw joint.



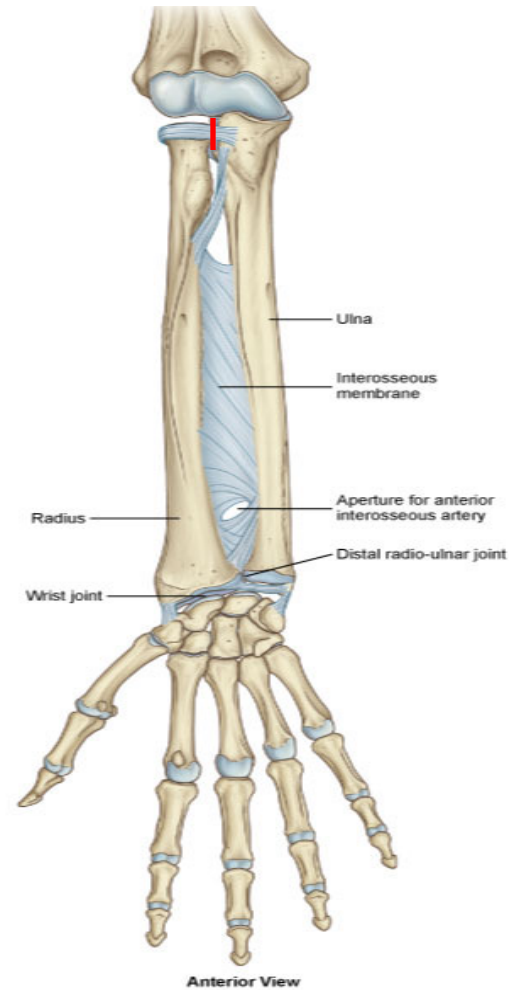
Synovial Joints: Pivot

Atlantoaxial “No-no” joint.



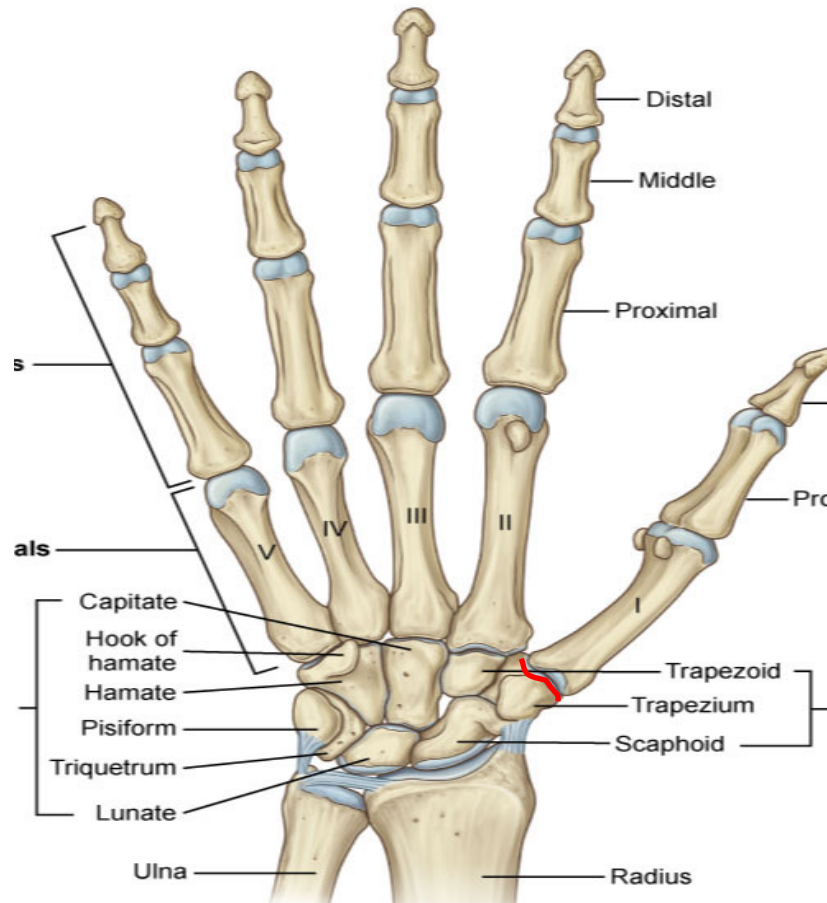
Synovial Joints: Pivot

Radioulnar (proximal) Joint between the radius and the ulna.



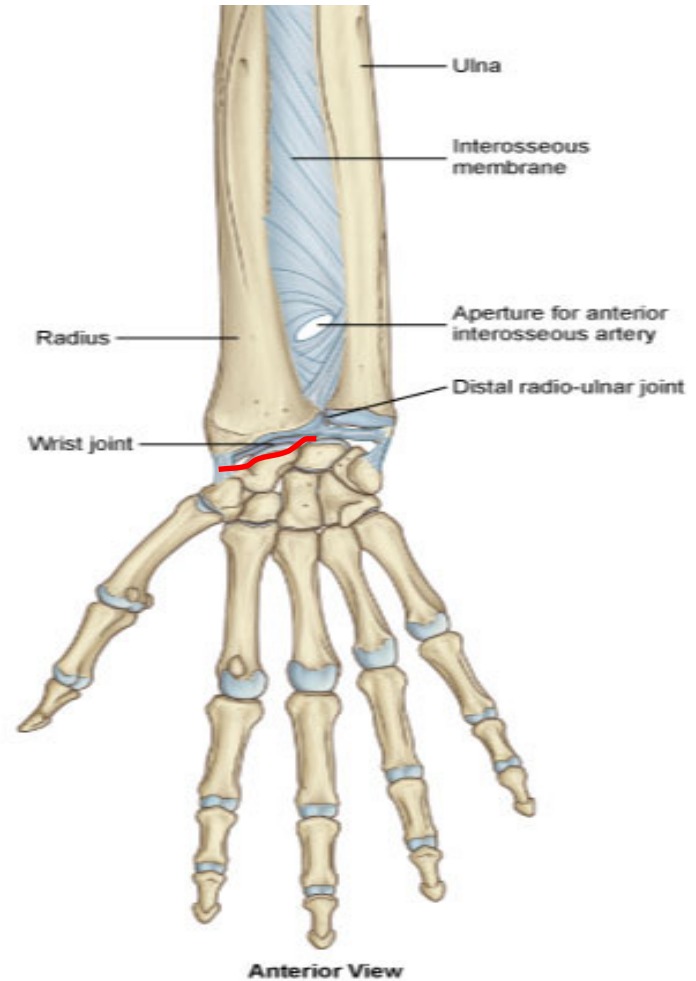
Synovial Joints: Saddle

Carpometacarpal of the thumb



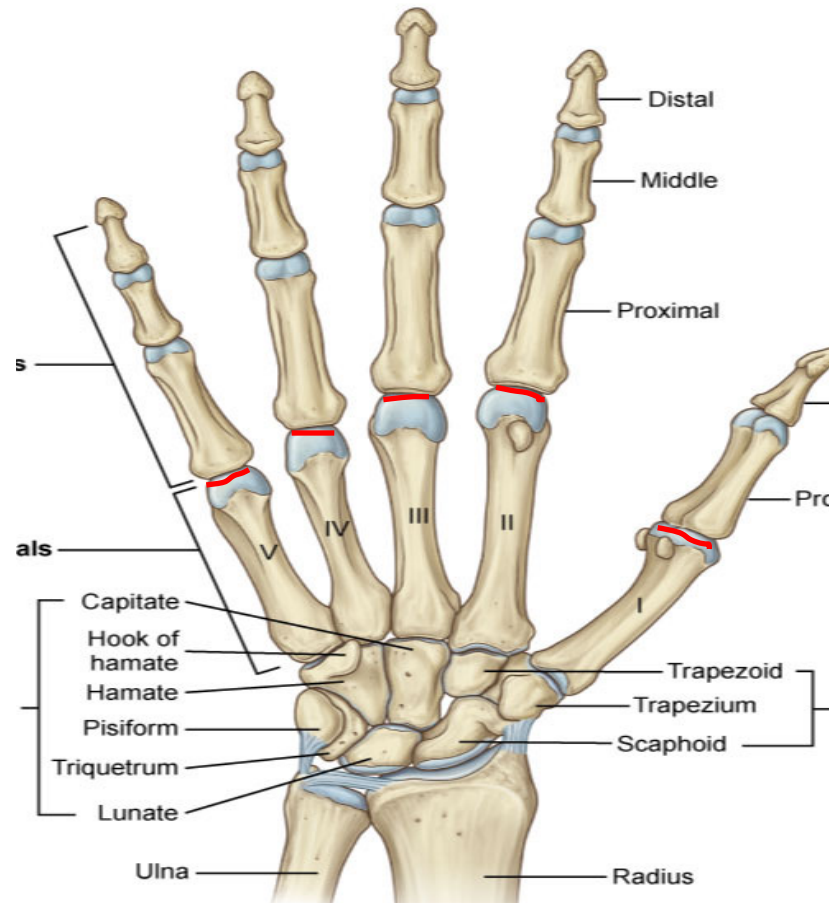
Synovial Joints: Ellipsoidal

Radiocarpal Wrist joint.



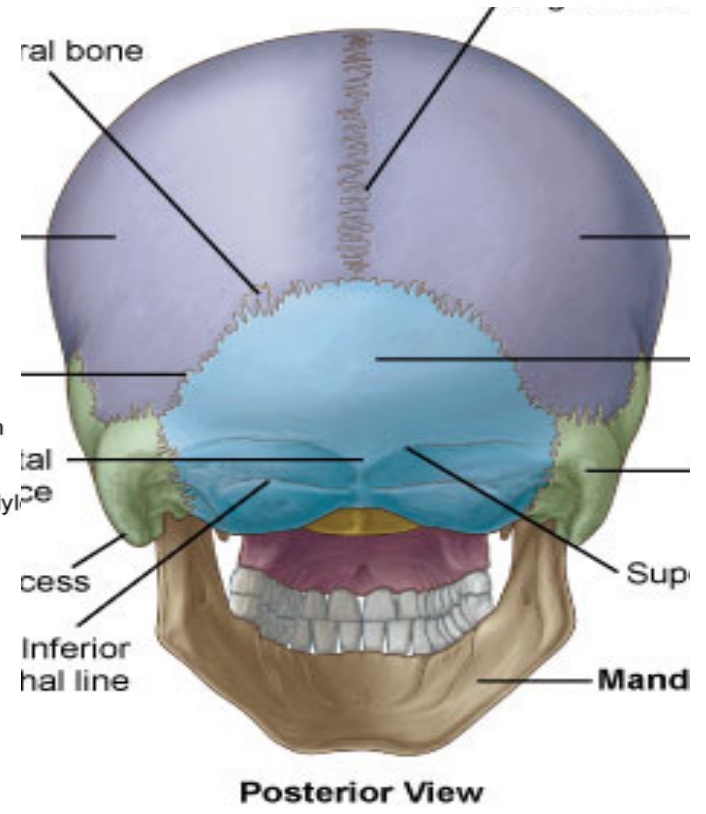
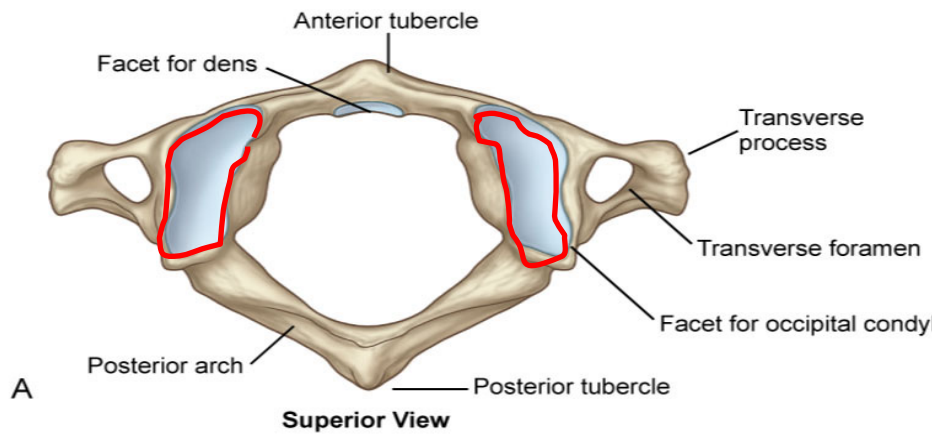
Synovial Joints: Ellipsoidal

Metacarpophalangeal Large knuckle joints of the hand.



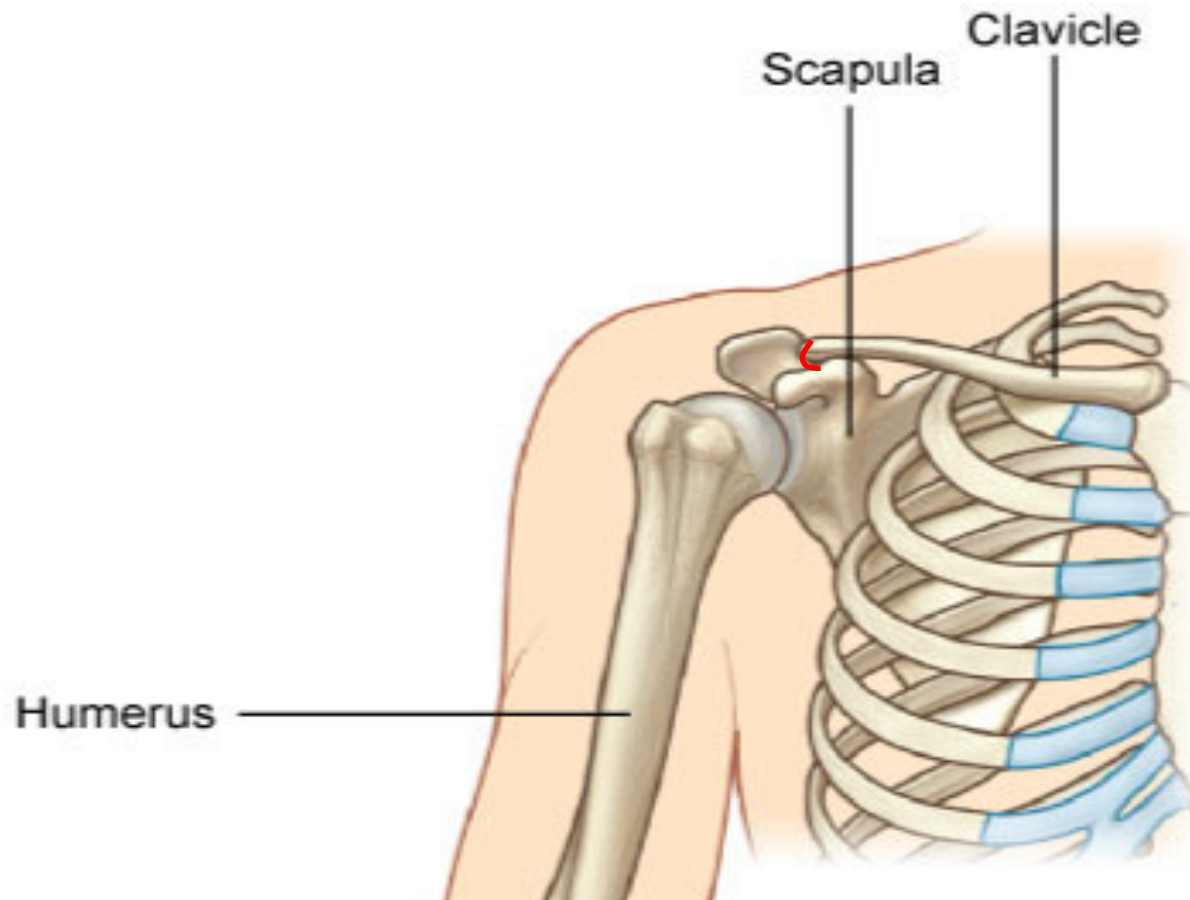
Synovial Joints: Ellipsoidal and Gliding

Atlantooccipital Joint between atlas (C1) and occiput. "Yes-yes" joint.



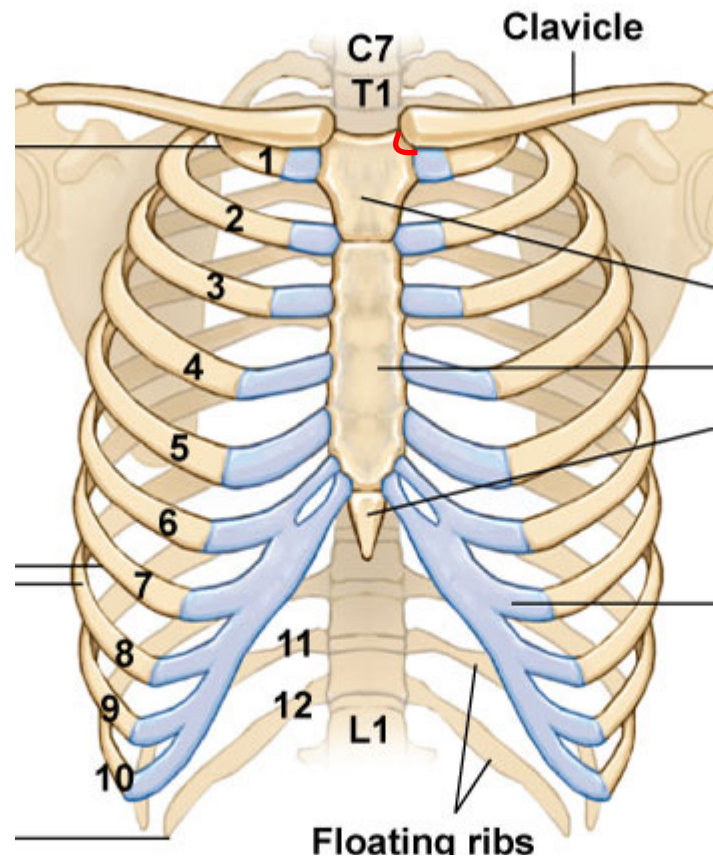
Synovial Joints: Gliding

Acromioclavicular



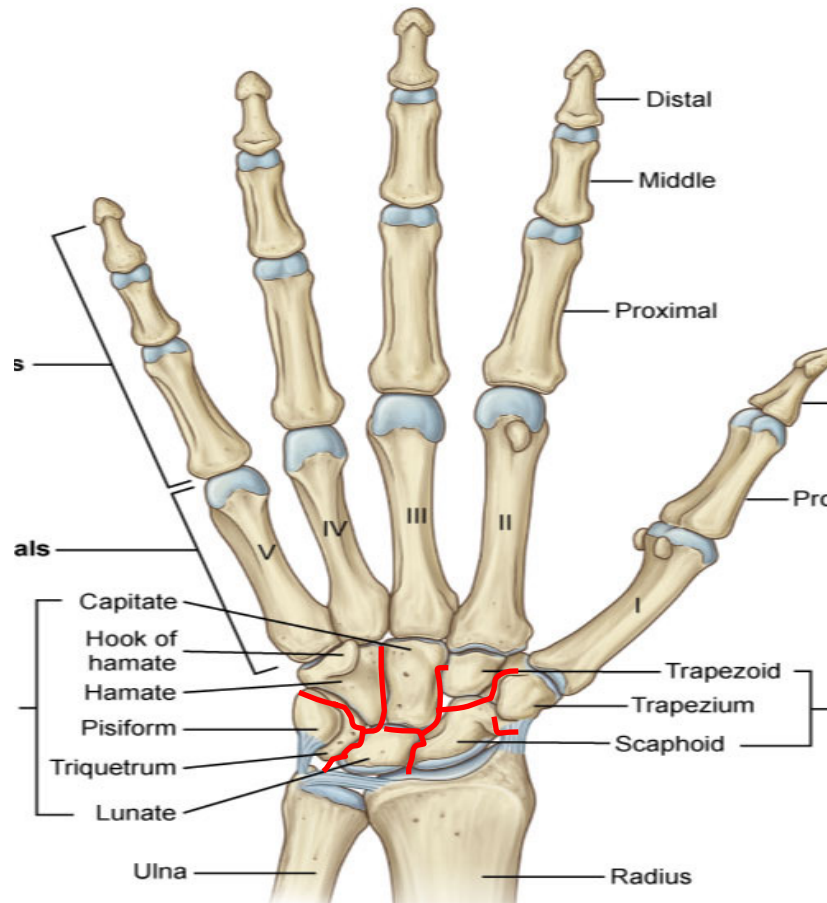
Synovial Joints: Gliding

Sternoclavicular



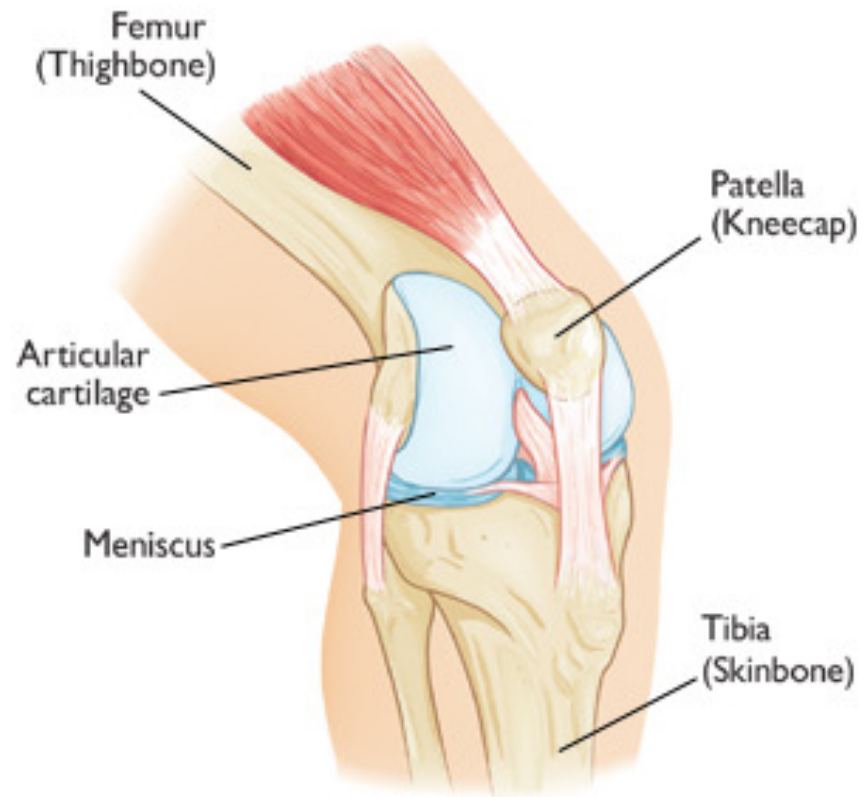
Synovial Joints: Gliding

Intercarpal Joints between carpals.



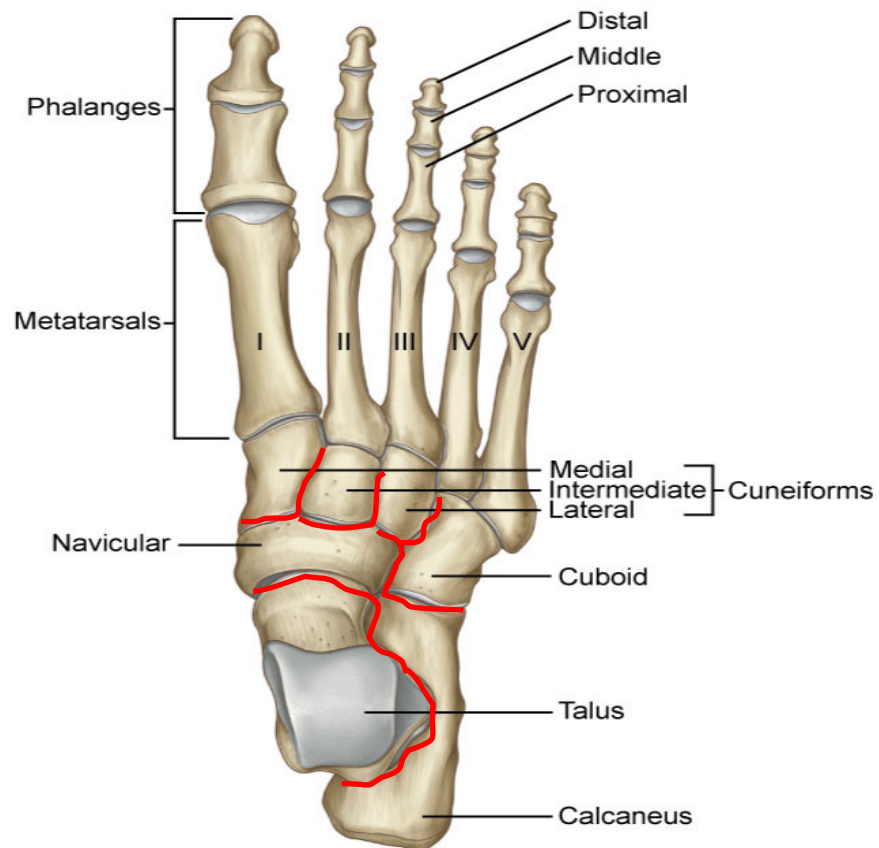
Synovial Joints: Gliding

Patellofemoral Patella – Femur.



Synovial Joints: Gliding

Intertarsal Joints between tarsals.





17a A&P:

Skeletal System - Joint Actions and Articulations and Quiz