



22a A&P: Skeletal System - Appendicular and Axial Divisions



22a A&P:

Skeletal System - Appendicular and Axial Divisions Class Outline

5 minutes	Attendance, Breath of Arrival, and Reminders
10 minutes	Lecture:
25 minutes	Lecture:
20 minutes	Active study skills:
60 minutes	Total

22a A&P:

Skeletal System - Appendicular and Axial Divisions Class Reminders

In Class 22b:

- Internship evaluated full SOAP notes with date, first and last names. Signatures and dates on intake form

Exams:

- 22b Swedish Touch Assessment
 - Packet A: 81-84
 - Bring your grading sheet for evaluation A: 83
 - Be prepared to make up missing assignments and retake tests
 - Bring laptop, tablet, or phone to watch class videos, Quizlet or Exam Coach

Assignments:

- **24a Hydro Review Questions (A: 145-148)**

Preparation for upcoming classes:

- 23a Pathology: Medications
 - Packet E: 27-36
 - Packet A-150
- 23b Swedish: Practical Exam
 - Packet A: 91-94
 - **Bring your grading sheet for evaluation A: 93**



Classroom Rules

Punctuality - everybody's time is precious

- Be ready to learn at the start of class; we'll have you out of here on time
- Tardiness: arriving late, returning late after breaks, leaving during class, leaving early

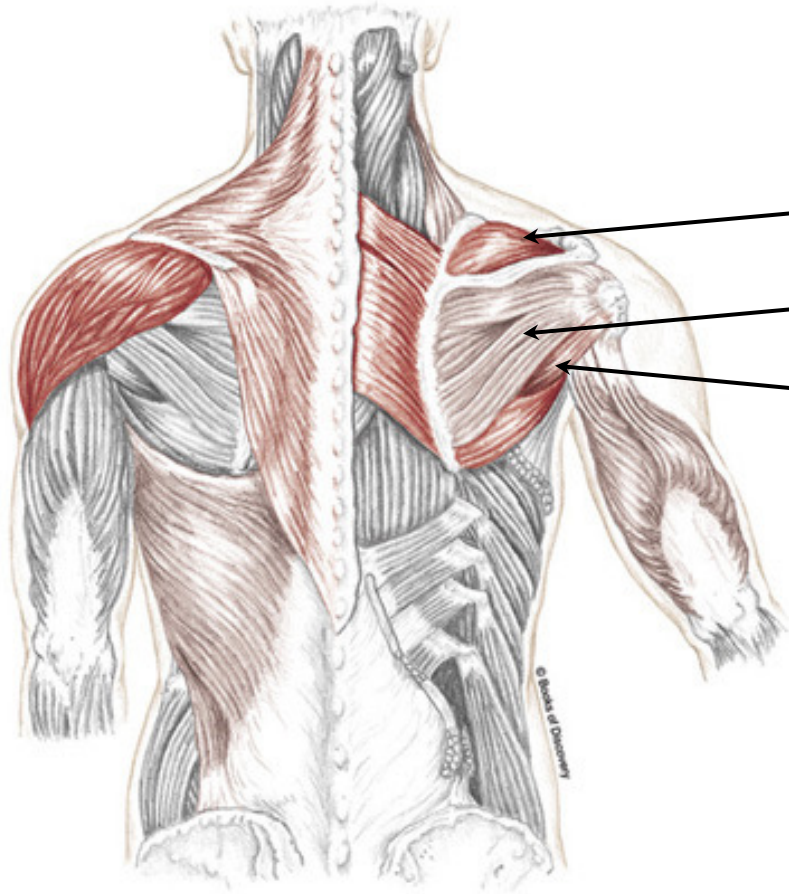
The following are not allowed:

- Bare feet
- Side talking
- Lying down
- Inappropriate clothing
- Food or drink except water
- Phones that are visible in the classroom, bathrooms, or internship

You will receive one verbal warning, then you'll have to leave the room.

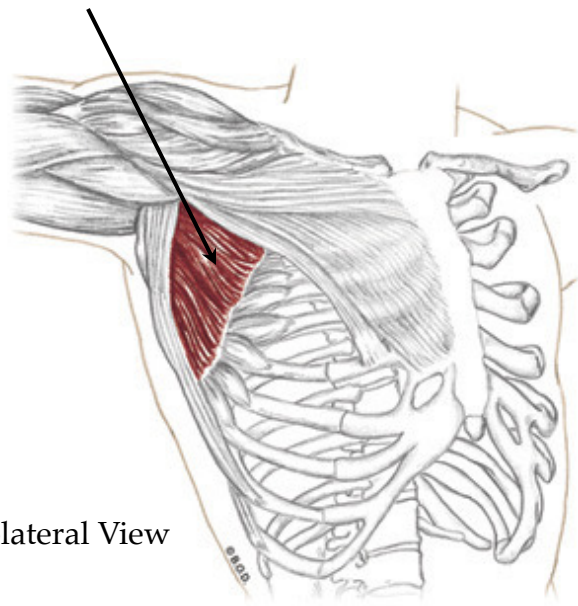
The Rotator Cuff

Trail Guide, Page 74



Posterior View

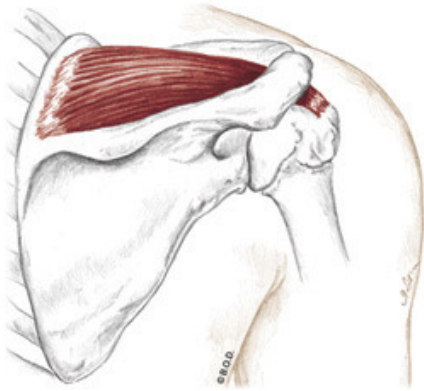
- Supraspinatus S
- Infraspinatus I
- Teres Minor T
- Subscapularis S



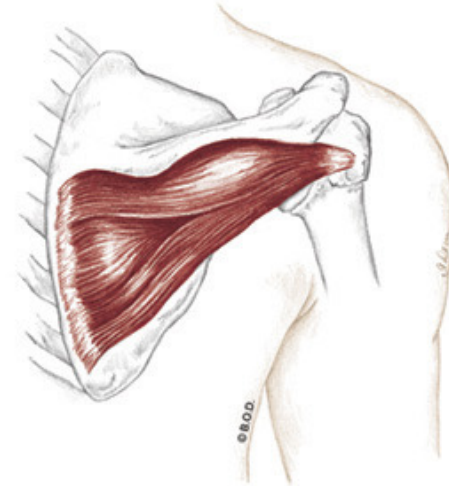
Anterolateral View

The Rotator Cuff

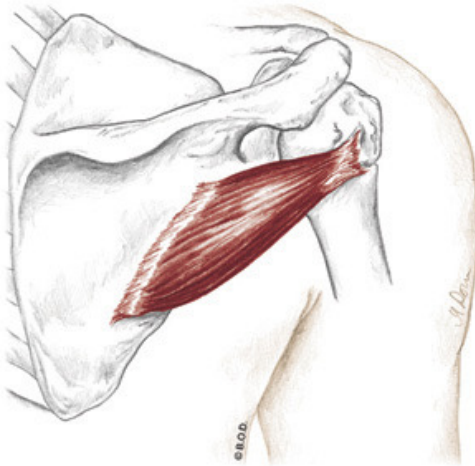
Trail Guide, Page 74



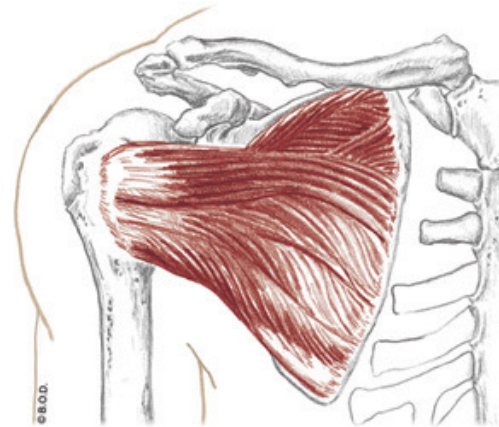
Supraspinatus
Posterior View



Infraspinatus
Posterior View



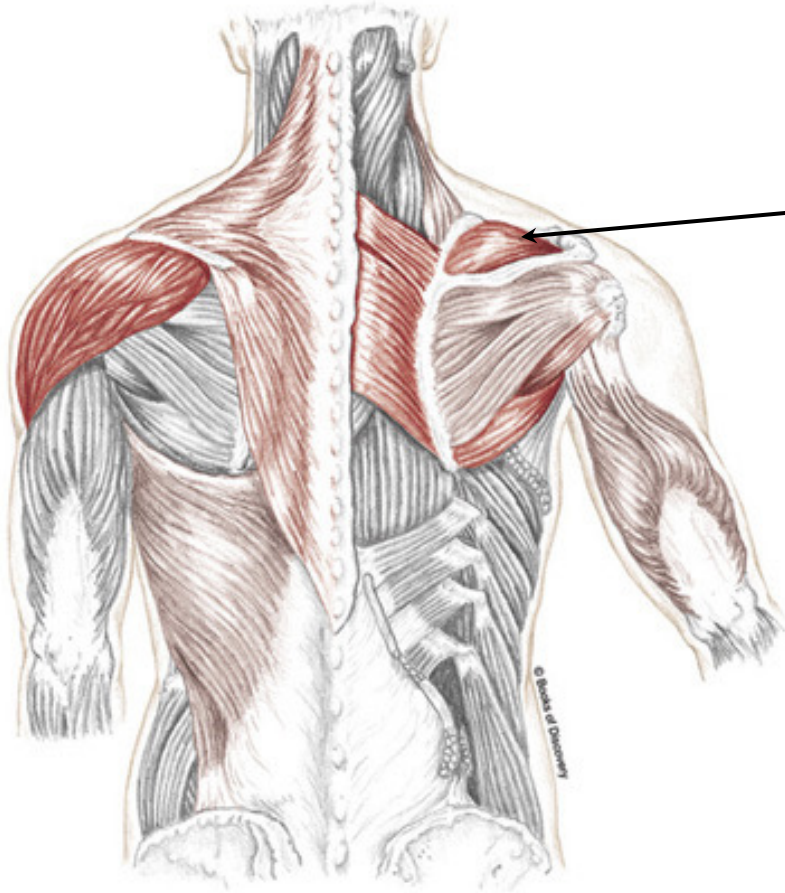
Teres Minor
Posterior View



Subscapularis
Anterior View

Supraspinatus

Trail Guide, Page 75



Supraspinatus is located in the supraspinous fossa, deep to the trapezius' middle fibers.

Its belly runs underneath the acromion and attaches to the humerus.

Supraspinatus is the only rotator cuff muscle that is not involved in shoulder rotation.

What do you use supraspinatus for?

Posterior View

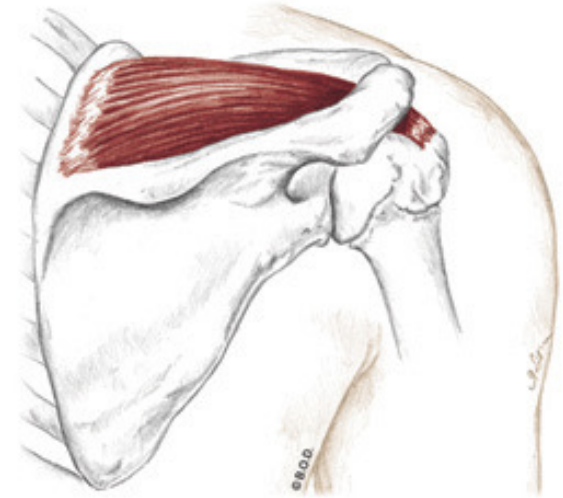
Supraspinatus, page 75

A Abduct the shoulder joint (glenohumeral joint)

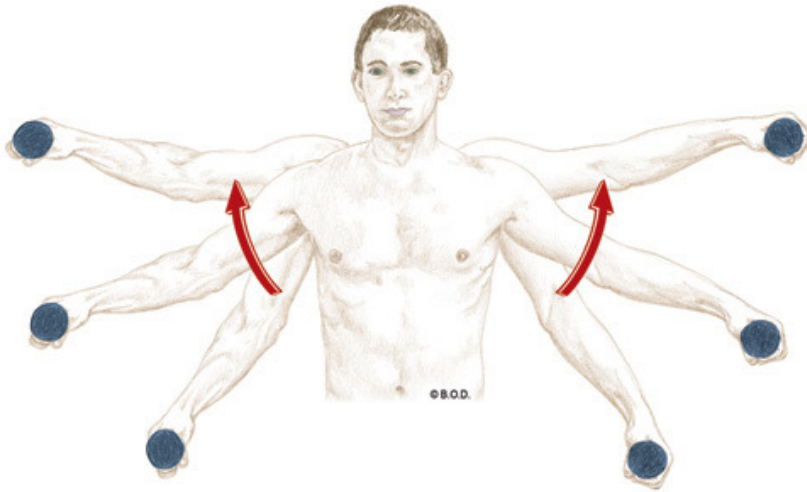
Stabilize the head of the humerus in glenoid cavity

O Supraspinous fossa of the scapula

I Greater tubercle of the humerus



Posterior View



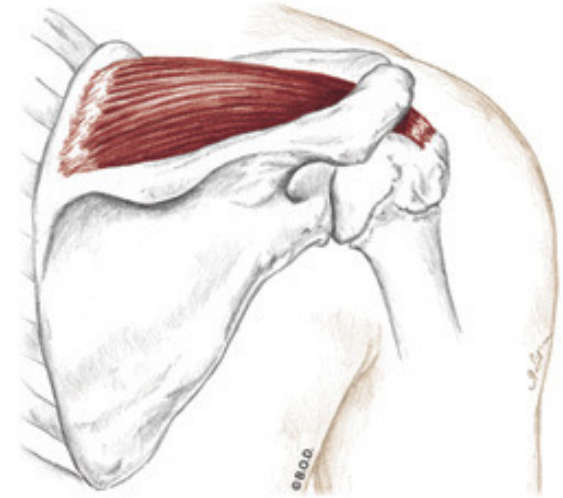
Supraspinatus, page 75

A **Abduct** the shoulder joint (glenohumeral joint)

Stabilize the head of the humerus in glenoid cavity

O Supraspinous fossa of the scapula

I Greater tubercle of the humerus



Posterior View

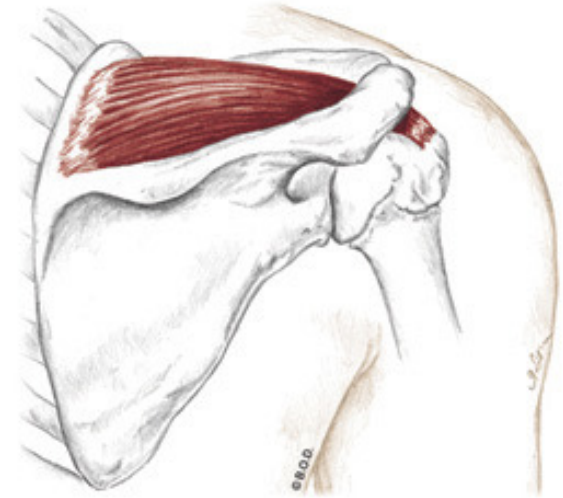
Supraspinatus, page 75

A **Abduct** the shoulder joint (glenohumeral joint)

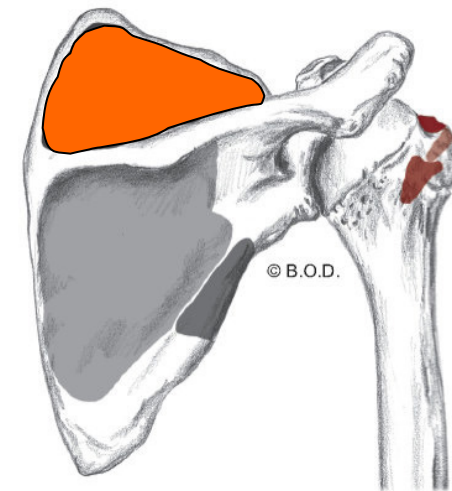
Stabilize the head of the humerus in glenoid cavity

O Supraspinous fossa of the scapula

I Greater tubercle of the humerus



Posterior View



© B.O.D.

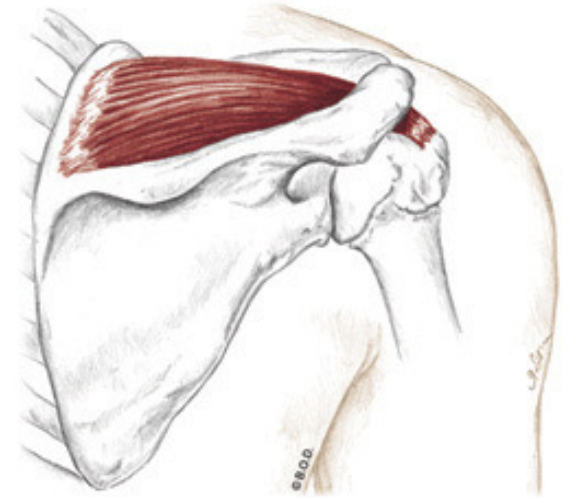
Supraspinatus, page 75

A **Abduct** the shoulder joint (glenohumeral joint)

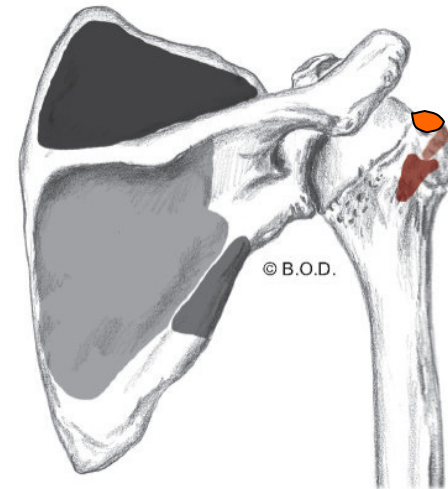
Stabilize the head of the humerus in glenoid cavity

O Supraspinous fossa of the scapula

I Greater tubercle of the humerus



Posterior View





22a A&P:

Skeletal System - Appendicular and Axial Divisions

E-17



Divisions of the Skeletal System



Divisions of the Skeletal System

Adult Human 206 bones total

Axial Skeleton 80 bones

Appendicular Skeleton 126 bones



Divisions of the Skeletal System

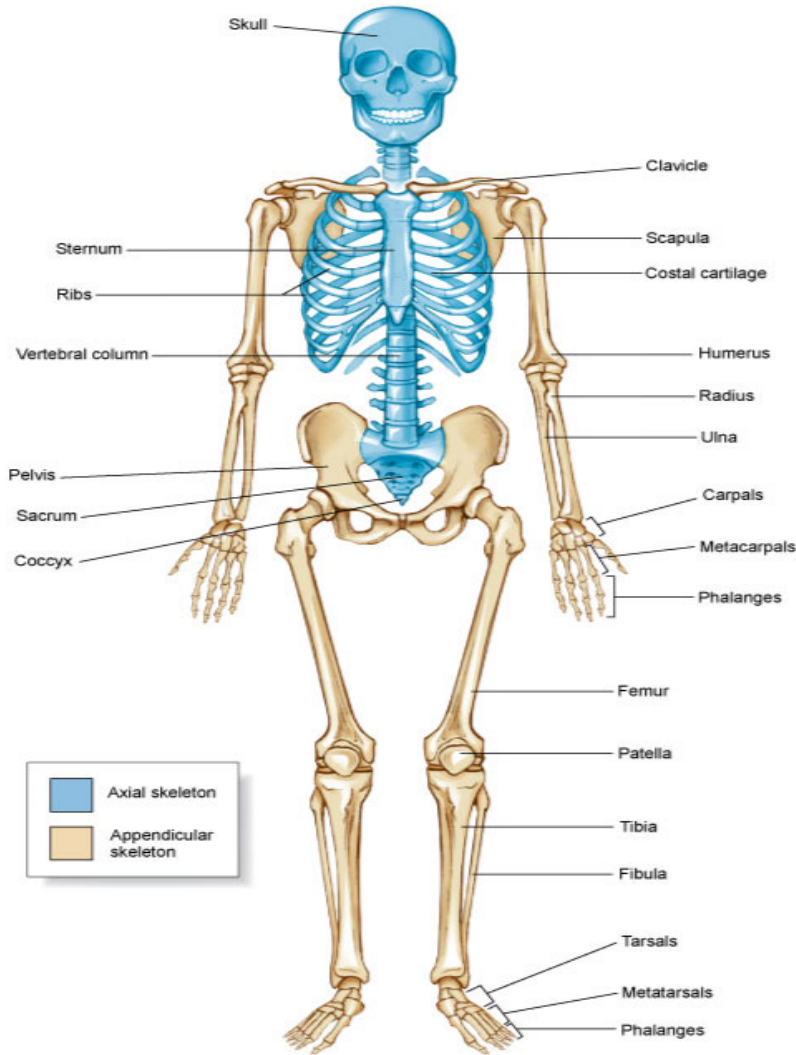
80 Axial Skeleton

- The skeleton that a snake would have
- No arms or legs

126 Appendicular Skeleton

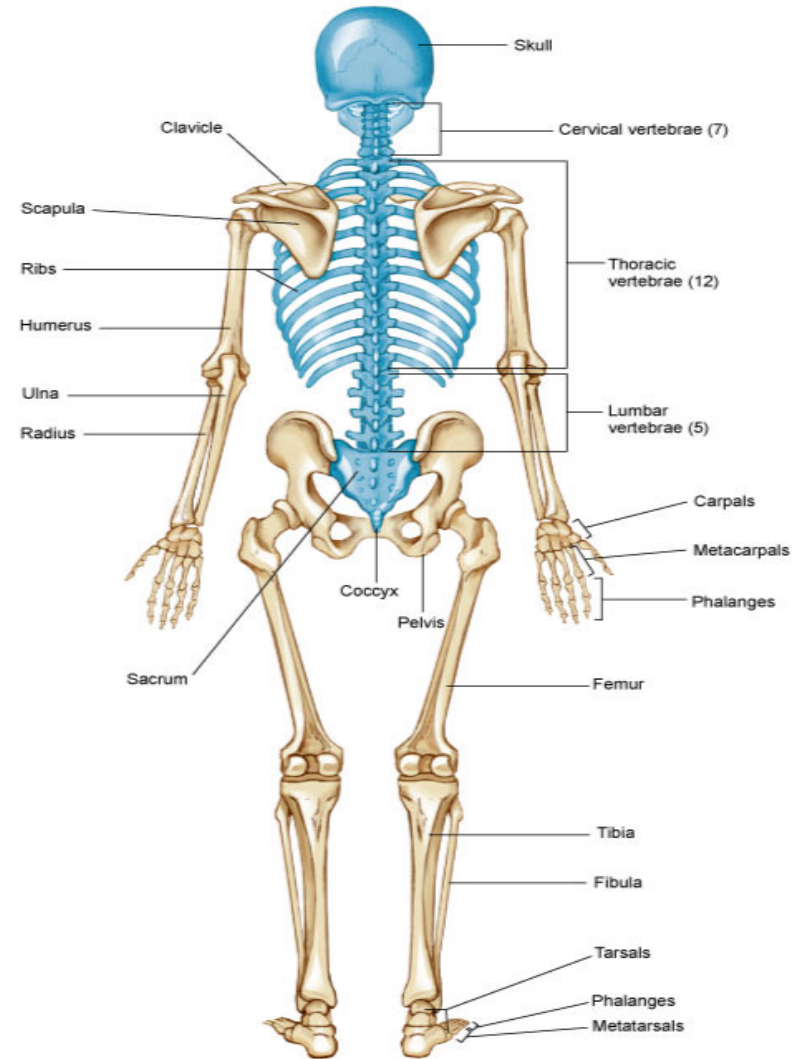
- The shoulder girdle and arms
- The pelvic girdle and legs

Axial Skelton in BLUE (80 bones)



A

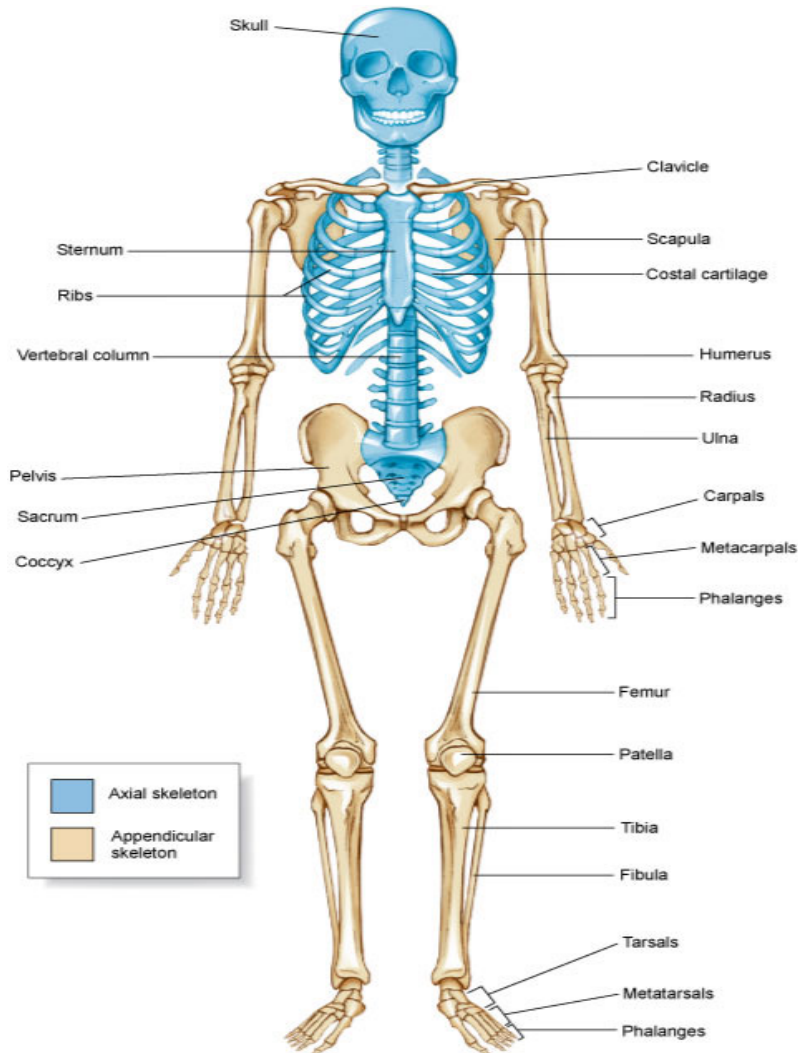
ANTERIOR VIEW



B

POSTERIOR VIEW

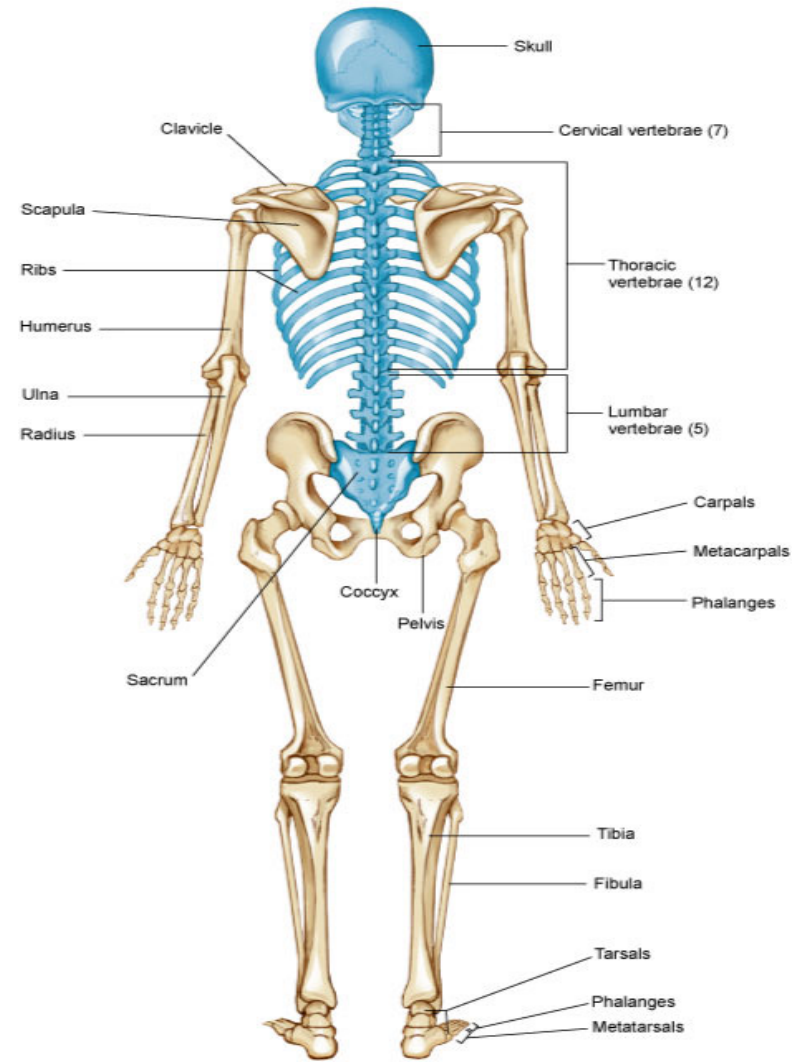
Appendicular Skeleton in WHITE (126 bones)



- Axial skeleton
- Appendicular skeleton

A

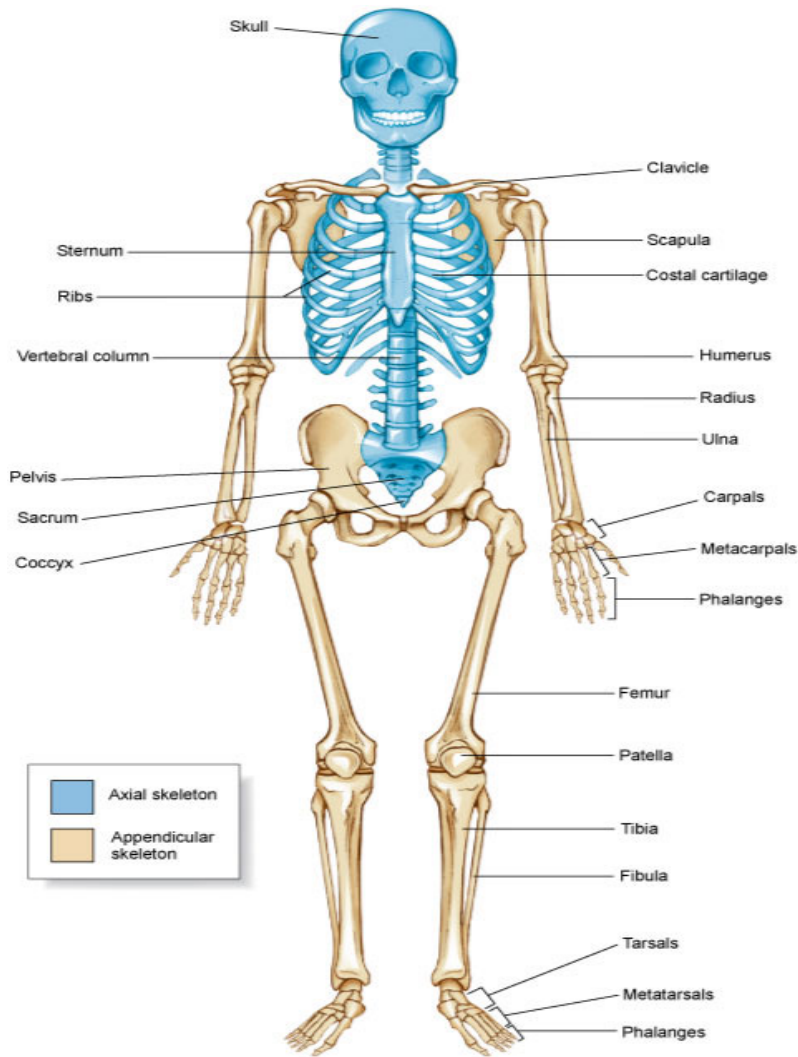
ANTERIOR VIEW



B

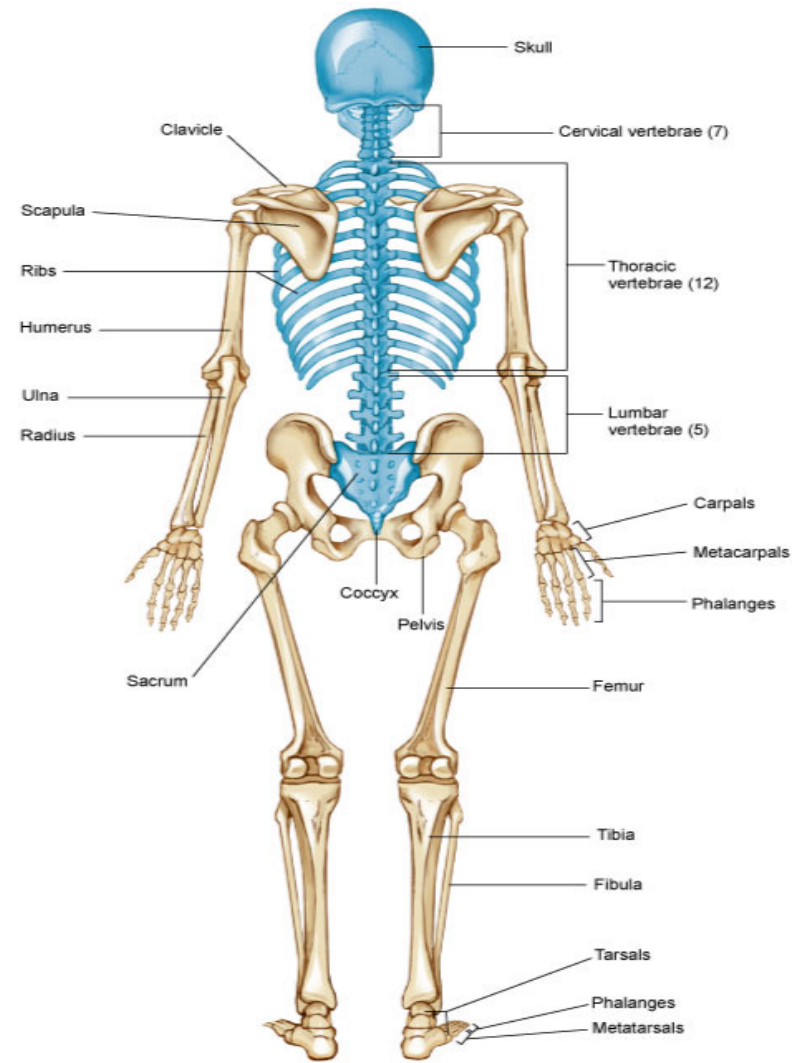
POSTERIOR VIEW

Human Skeleton (206 bones)




A

ANTERIOR VIEW



B

POSTERIOR VIEW



80 Axial Skeleton

80 Axial Skeleton

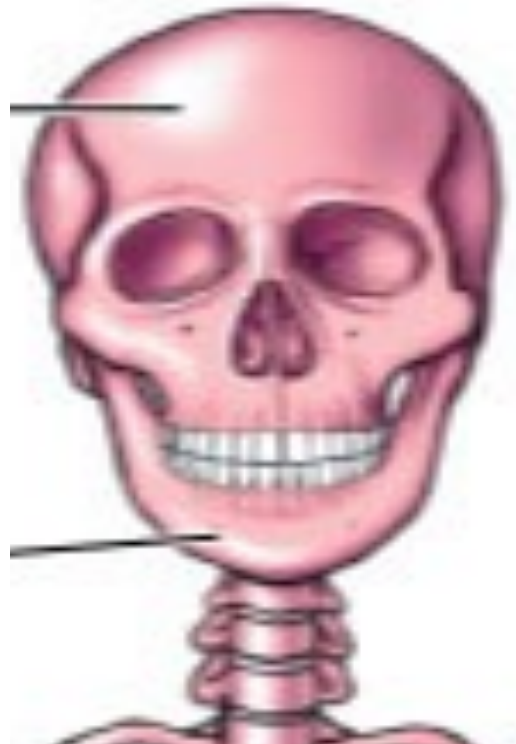29 Skull

8 Cranium

14 Face

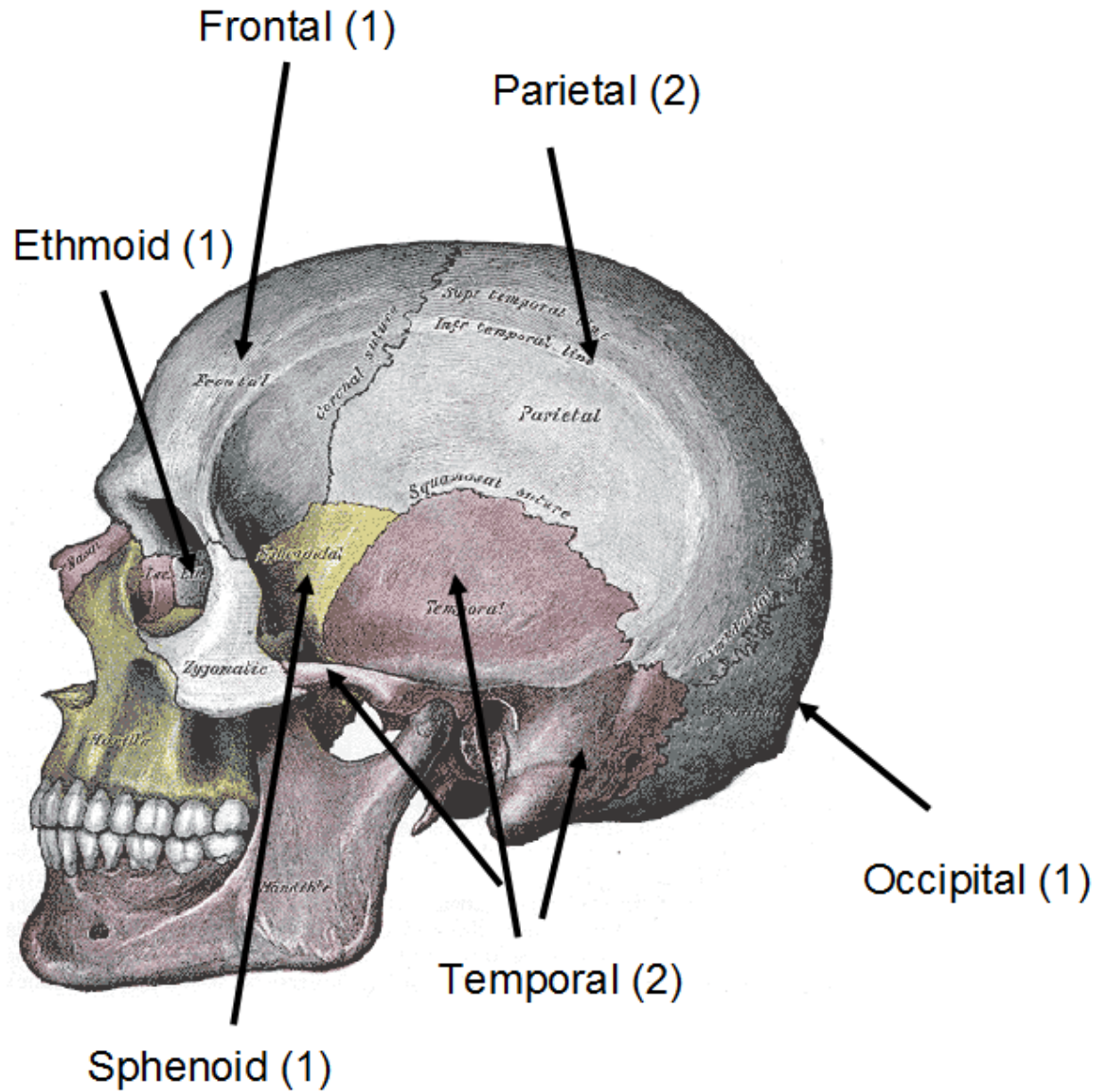
6 Ear

1 Hyoid



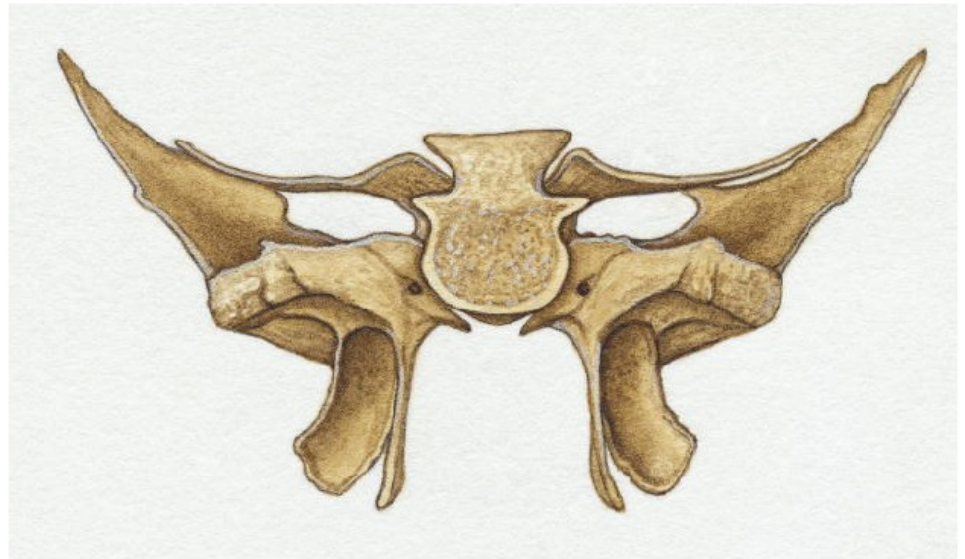
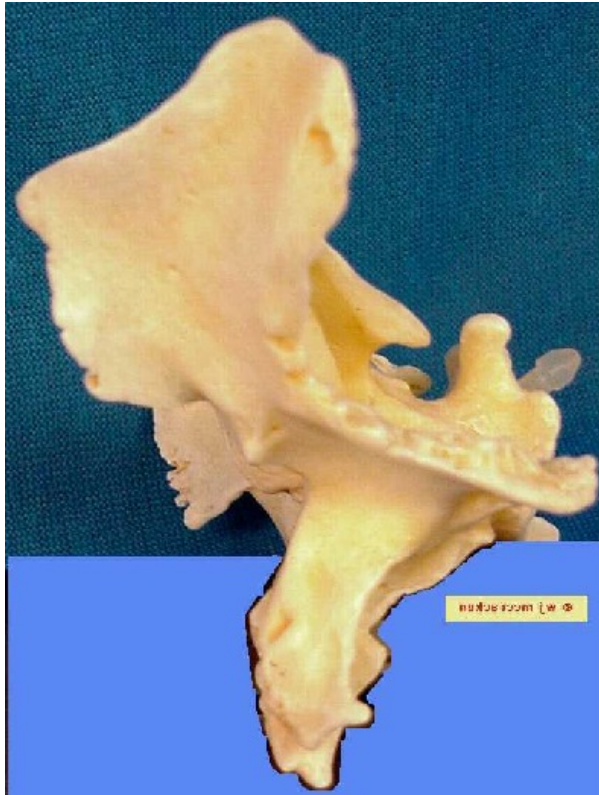80 Axial Skeleton

8 Cranium



80 Axial Skeleton

1 Sphenoid

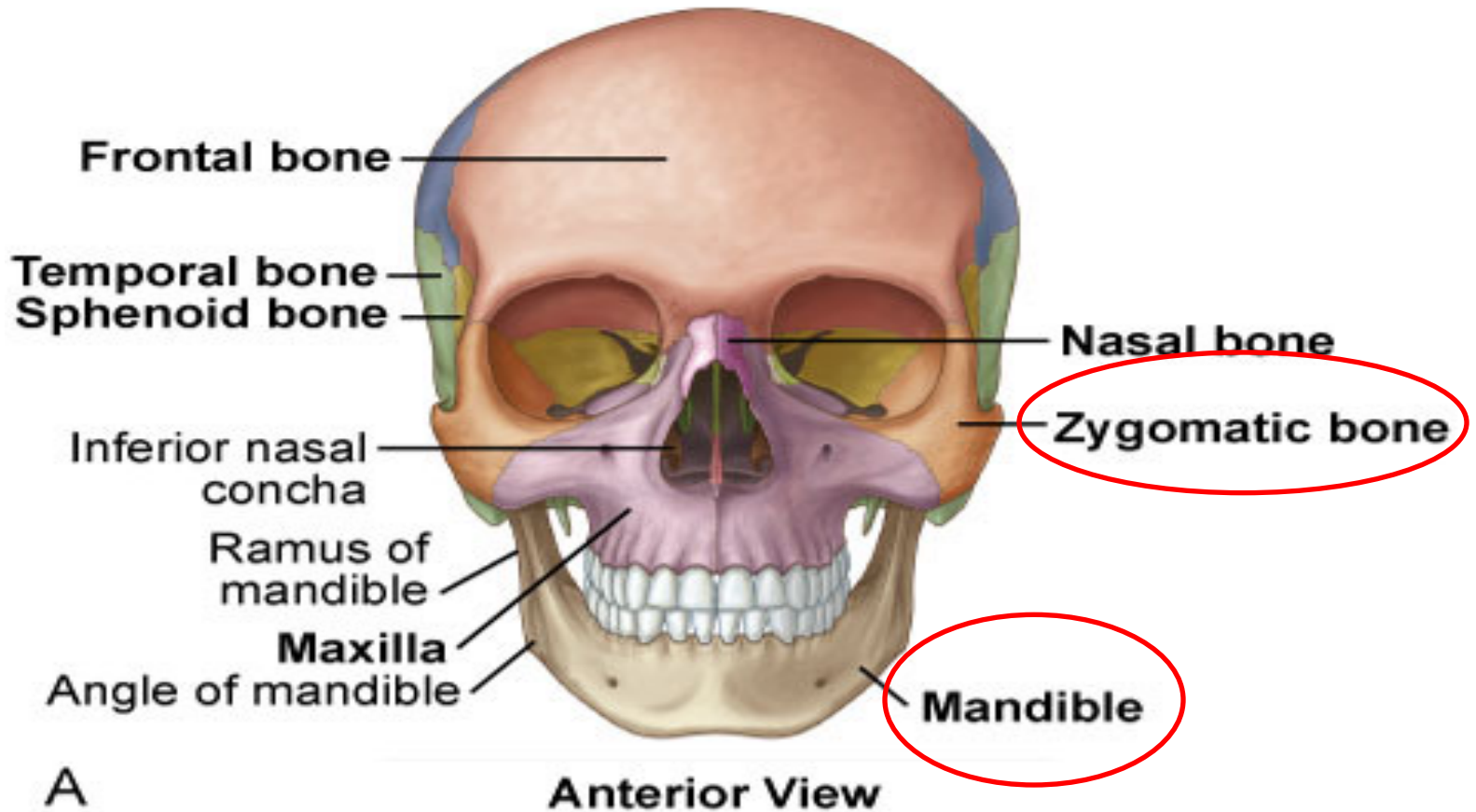


80 Axial Skeleton

14 Face

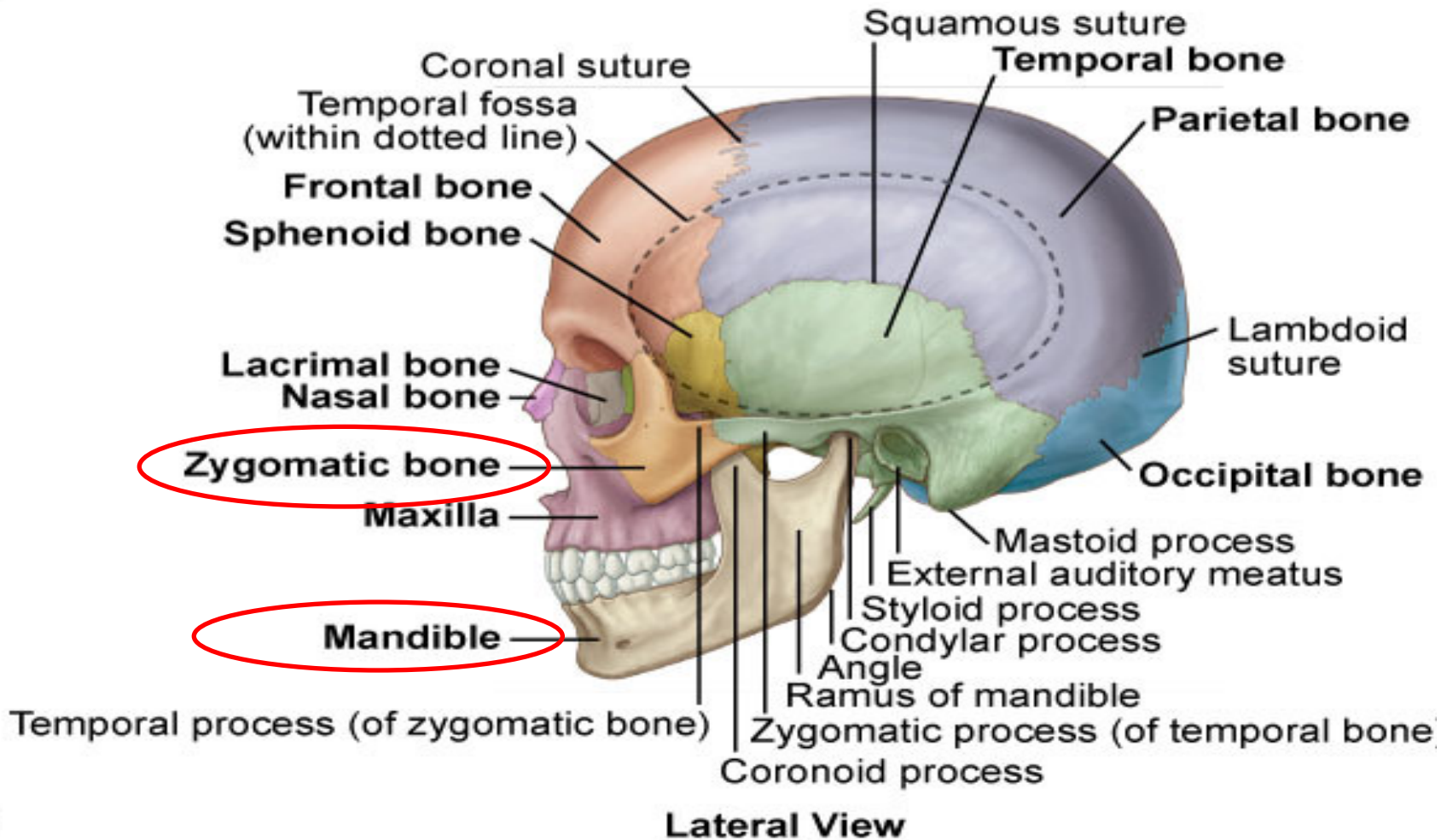
zygomatic 2

mandible 1



80 Axial Skeleton

14 Face



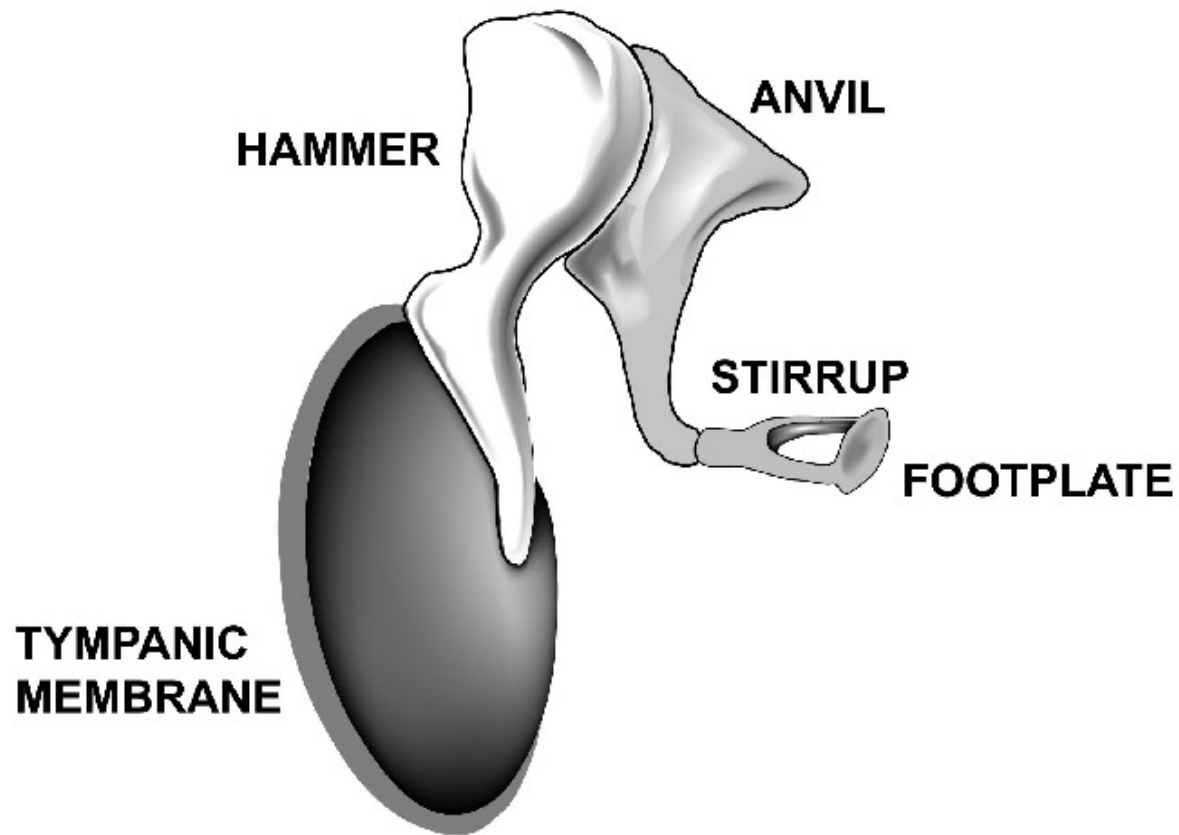
80 Axial Skeleton

6 Ear

2 malleus (hammer)

2 incus (anvil)

2 stapes (stirrup)



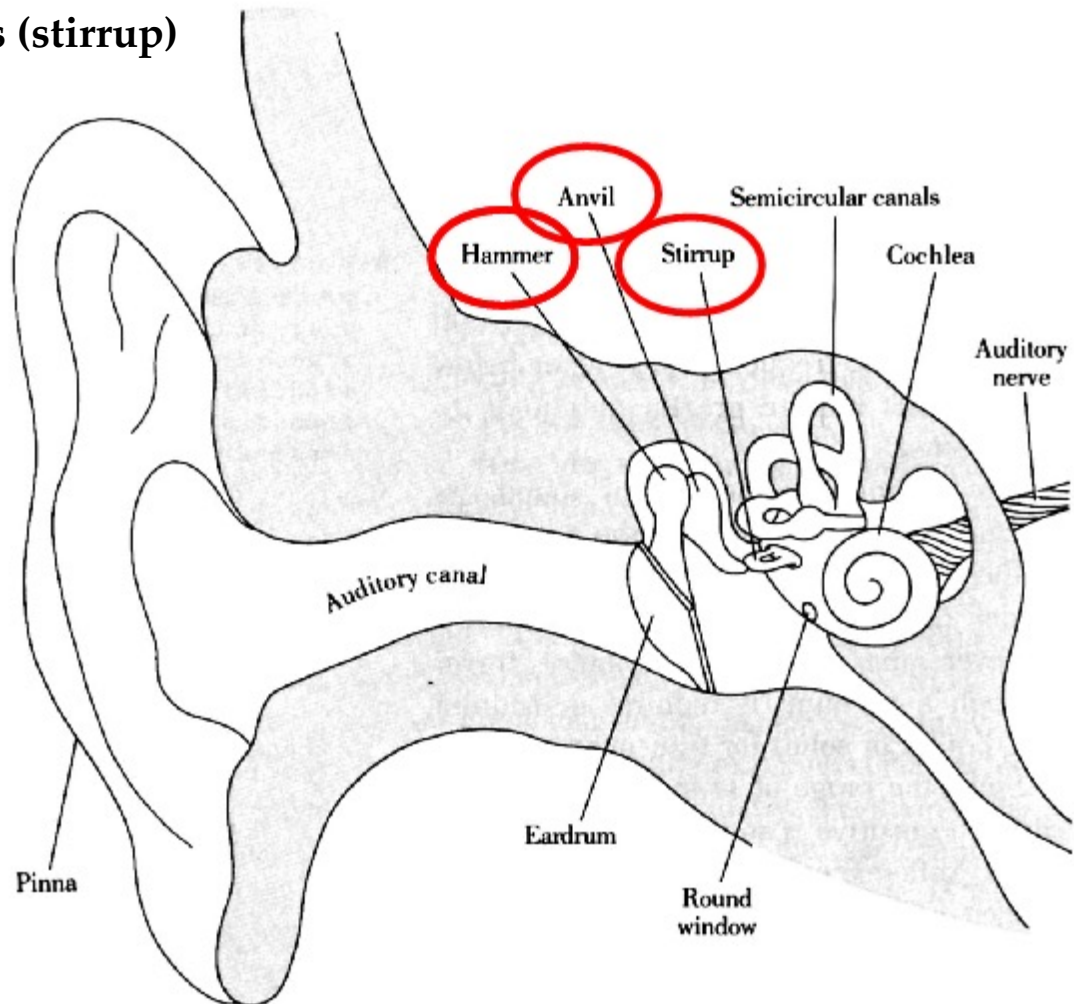
80 Axial Skeleton

6 Ear

2 malleus (hammer)

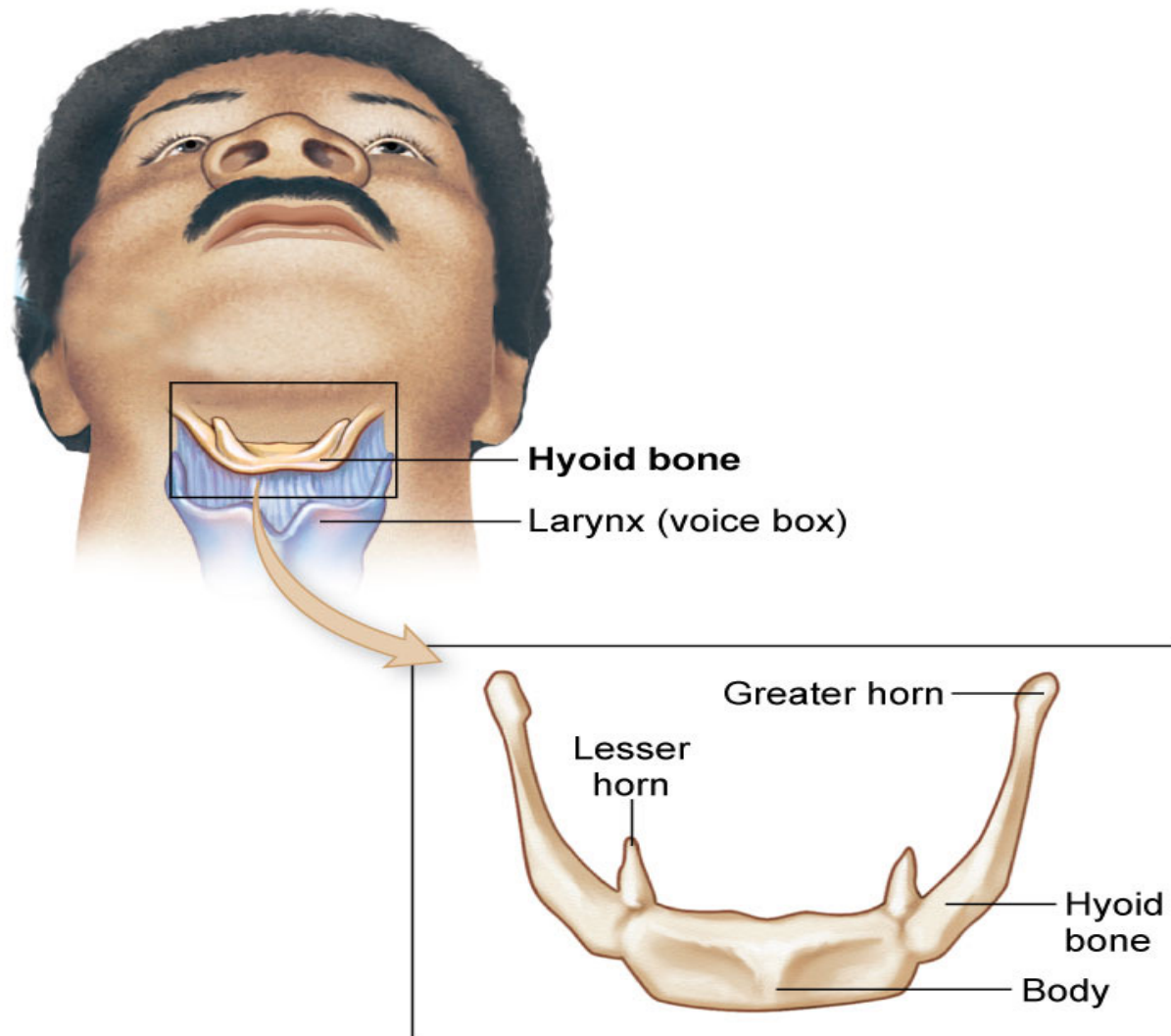
2 incus (anvil)

2 stapes (stirrup)



80 Axial Skeleton

1 Hyoid



From Patton KT, Thibodeau GA: *Anatomy & physiology*, ed 7, St. Louis, 2010, Mosby.

Fig. 21-19. Hyoid bone, anterior view.

80 Axial Skeleton

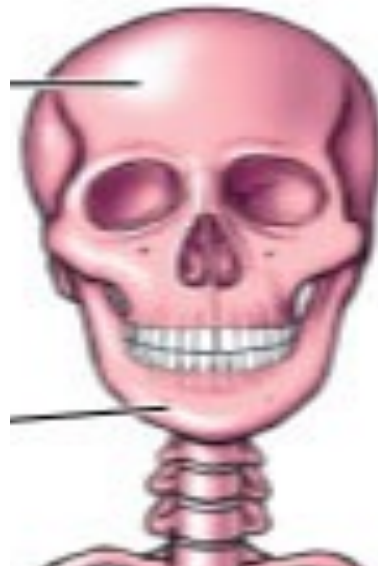29 Skull

8 Cranium

14 Face

6 Ear

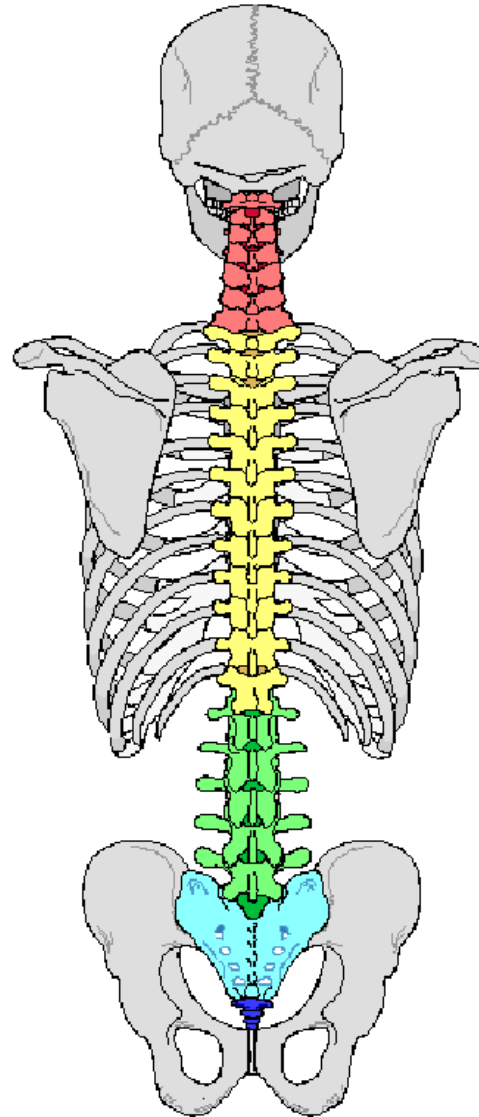
1 Hyoid



80 Axial Skeleton

26 Vertebral Column

7 Cervical
12 Thoracic
5 Lumbar
1 Sacrum
1 Coccyx



80 Axial Skeleton

26 Vertebral Column

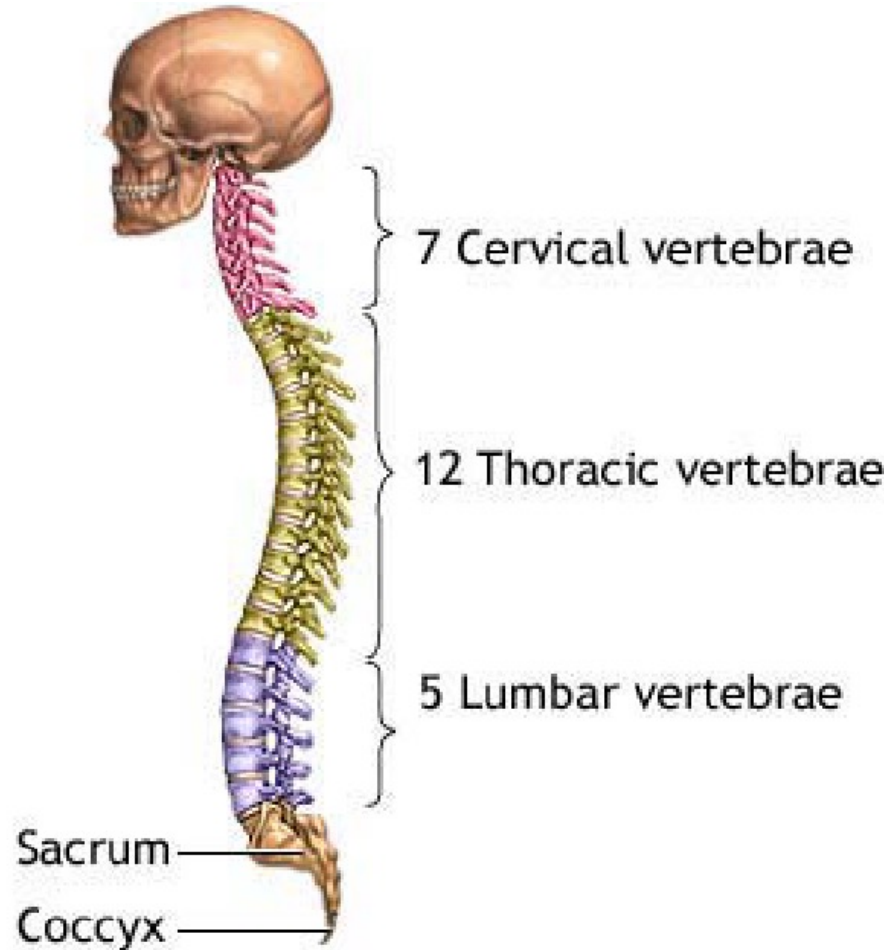
7 Cervical

12 Thoracic

5 Lumbar

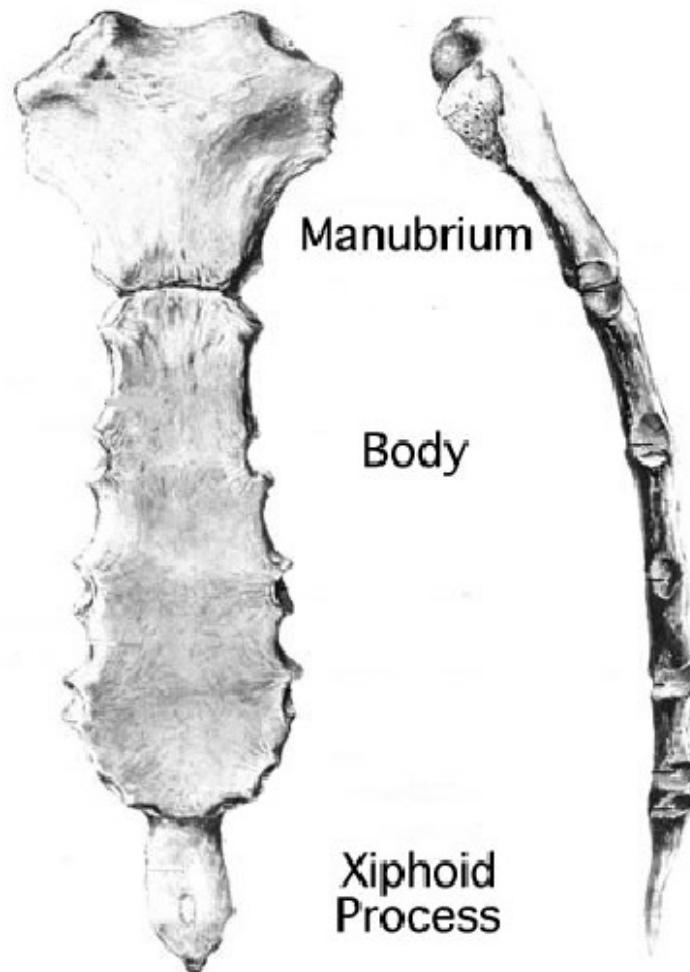
1 Sacrum

1 Coccyx



80 Axial Skeleton

1 Sternum



80 Axial Skeleton

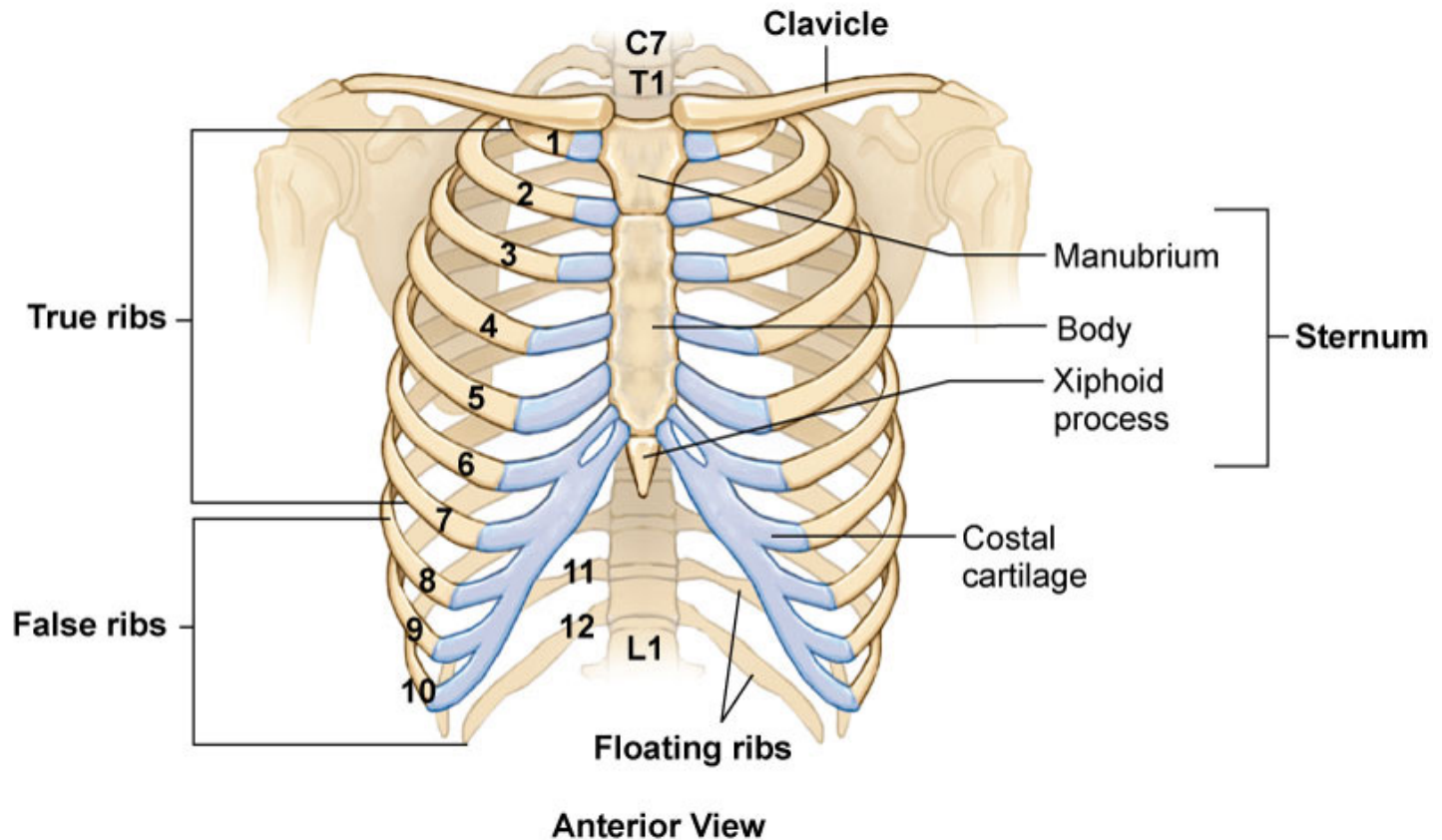
24 Ribs

14 True ribs

Directly attaching to the sternum by way of cartilage.

10 False ribs

Not *directly* attached to the sternum. Ribs 8, 9, and 10 share an attachment. Ribs 11 and 12 are floating.

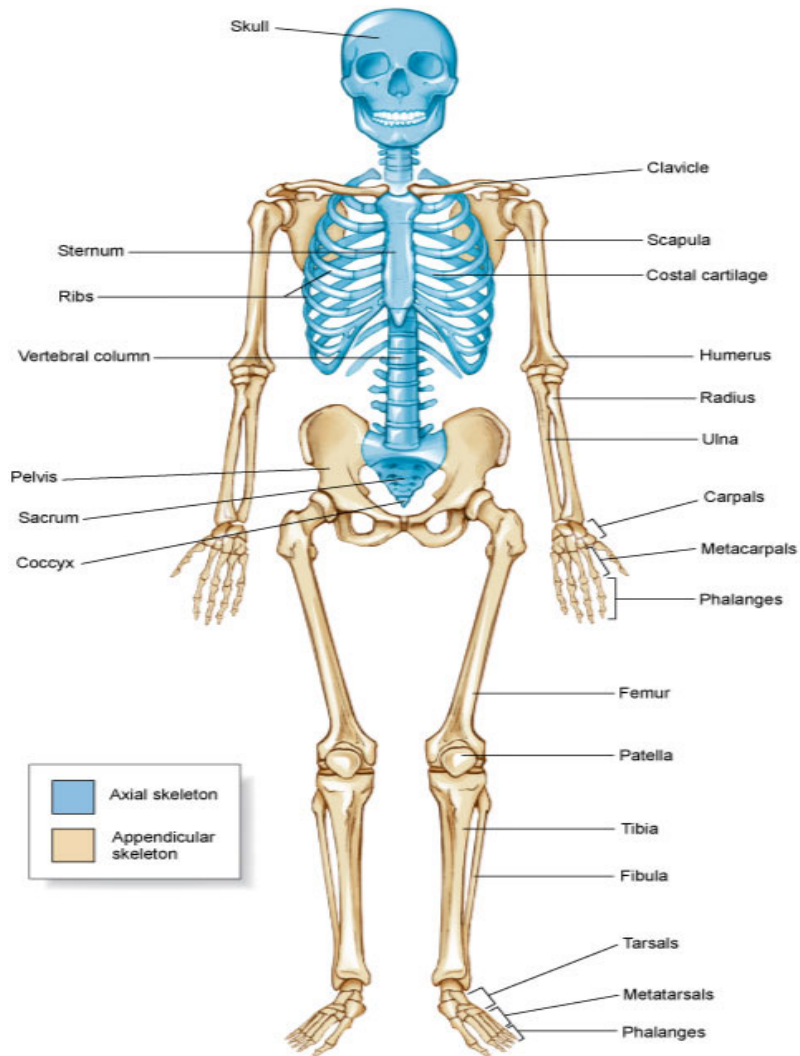




126 Appendicular Skeleton

126 Appendicular Skeleton

- 4 Shoulder Girdle
- 60 Upper Extremity
- 2 Pelvic Girdle
- 60 Lower Extremity



A

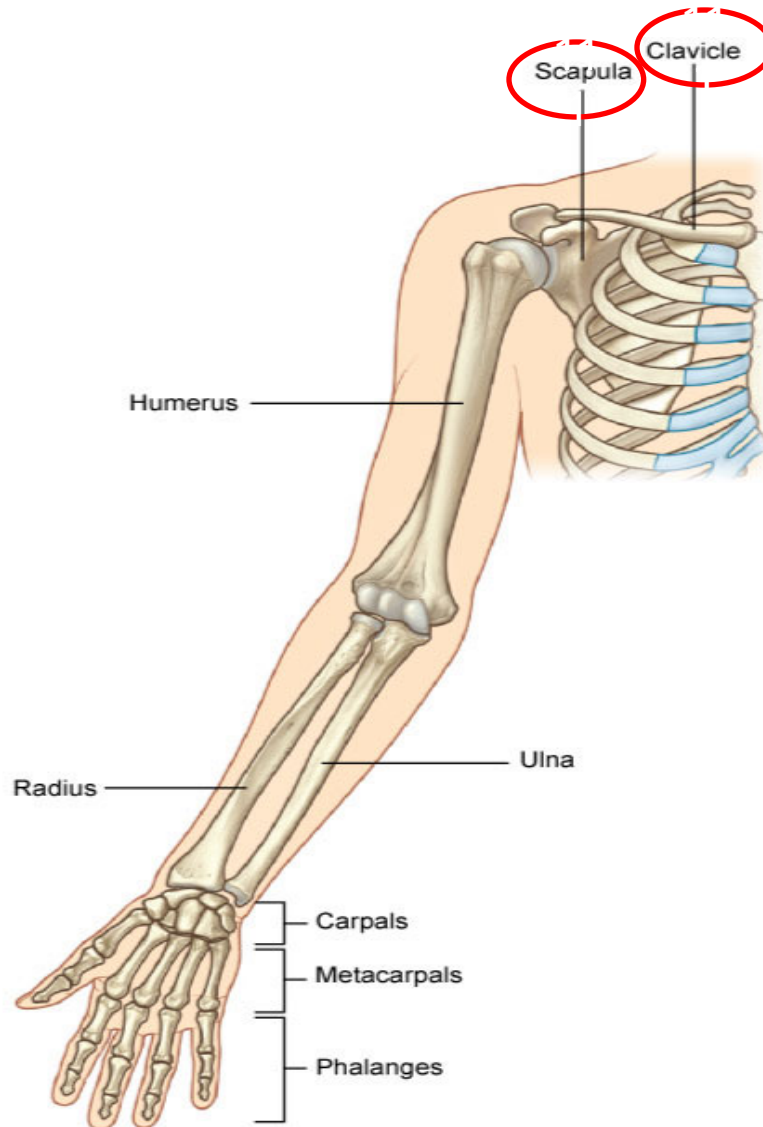
ANTERIOR VIEW

126 Appendicular Skeleton

4 Shoulder Girdle

clavicle 2

scapula 2



Anterior View

126 Appendicular Skeleton

60 Upper Extremity

humerus 2

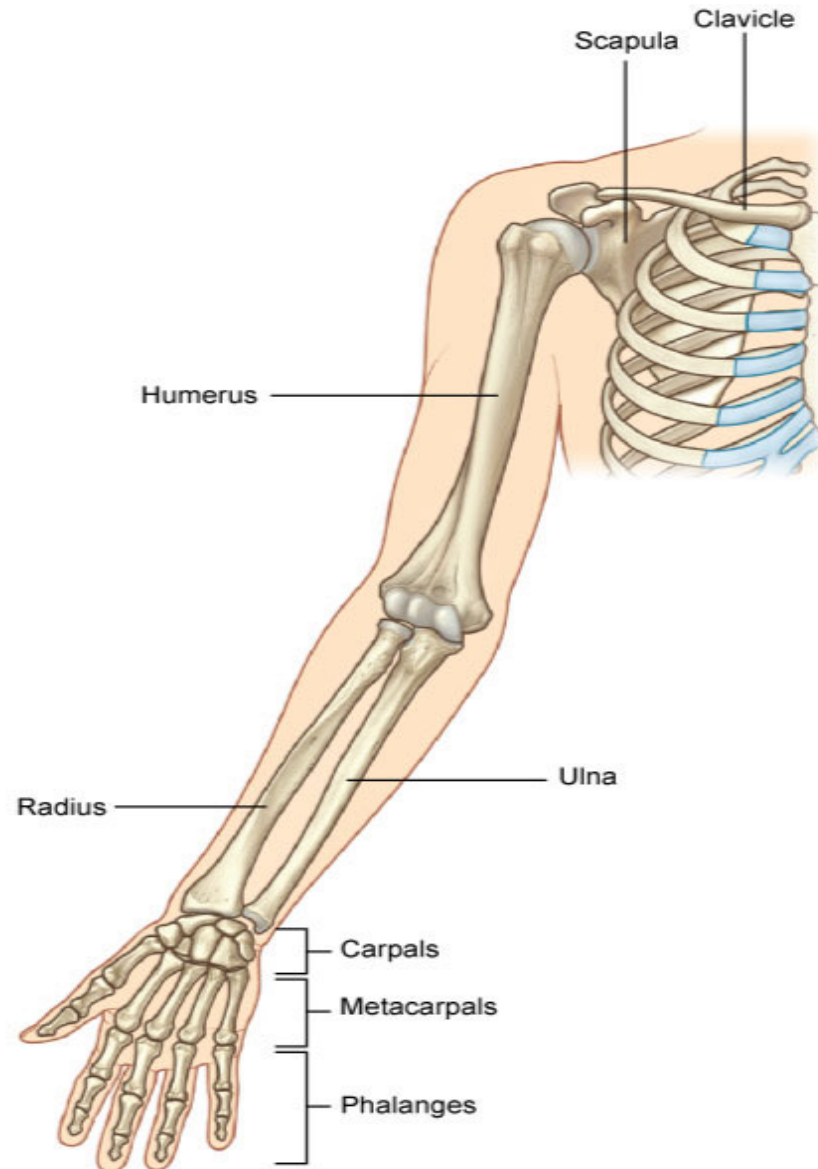
radius 2

ulna 2

carpals 16

metacarpals 10

phalanges 28



Anterior View

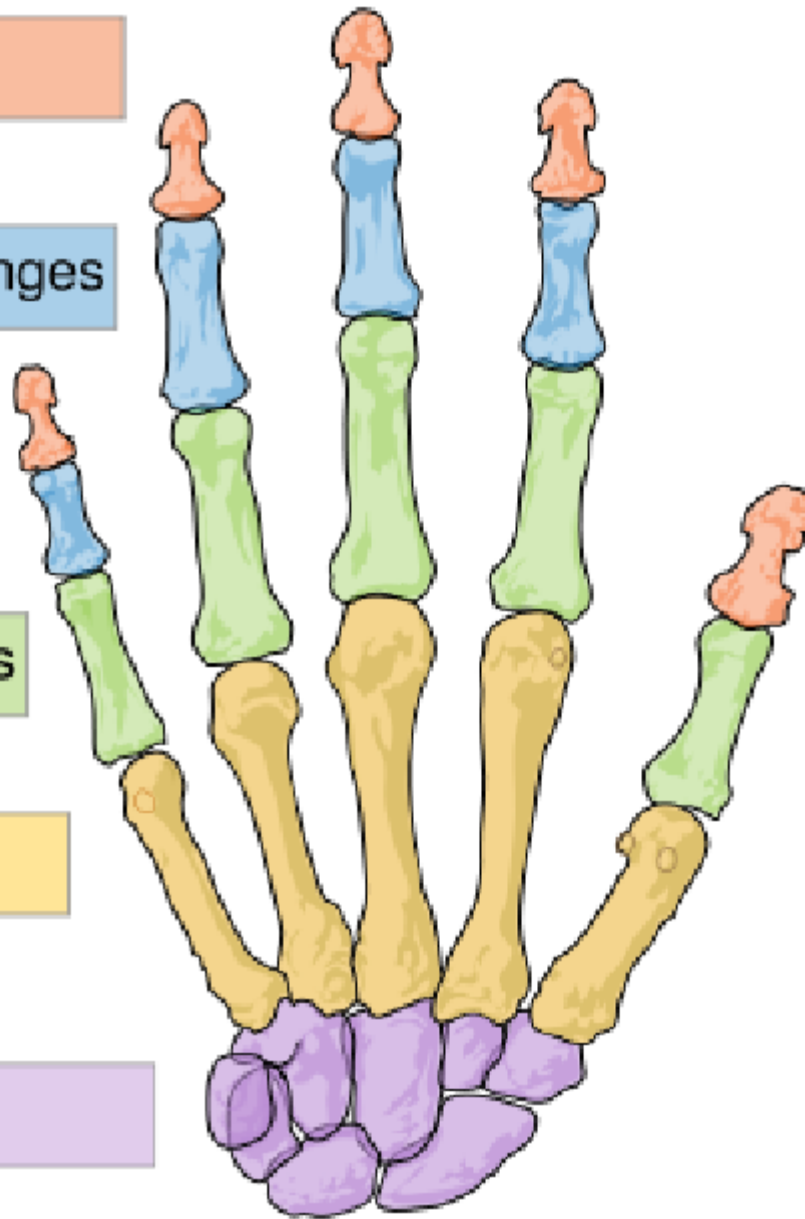
Distal phalanges

Intermediate phalanges

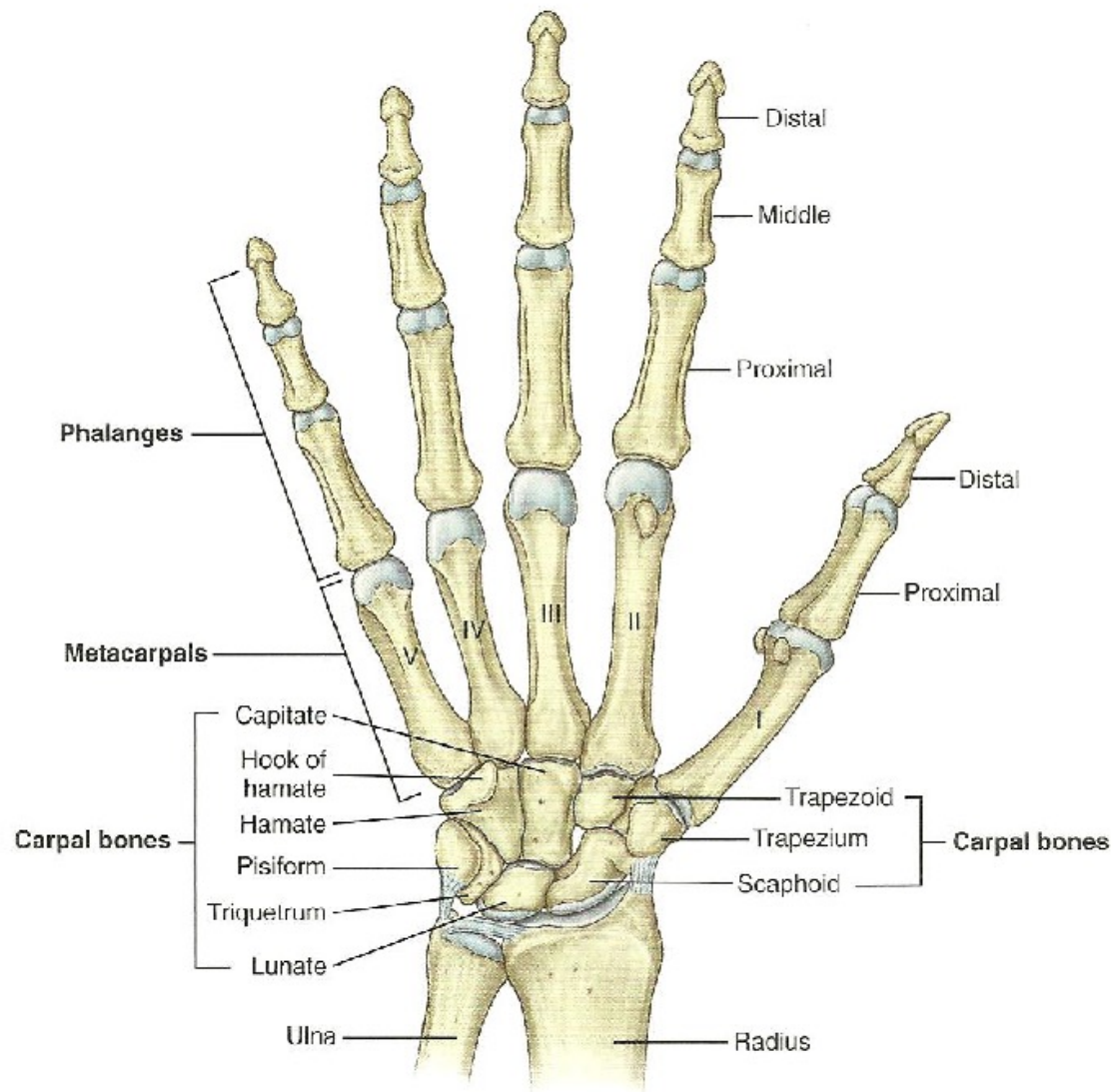
Proximal phalanges

Metacarpals

Carpals



126 Appendicular Skeleton



Anterior/Palmar View of Right Hand

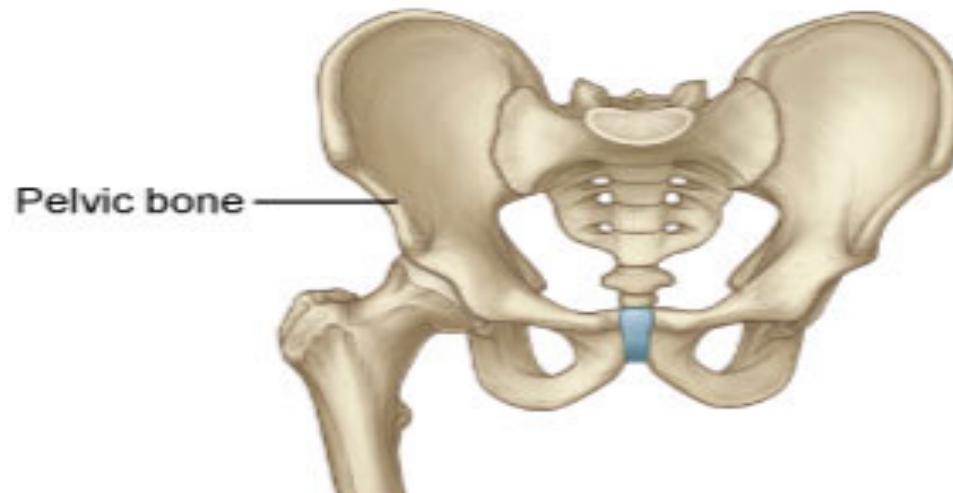
126 Appendicular Skeleton

2 Pelvic Girdle

pelvic bone

AKA: innominate bone

AKA: os coxae or coxal bone



126 Appendicular Skeleton

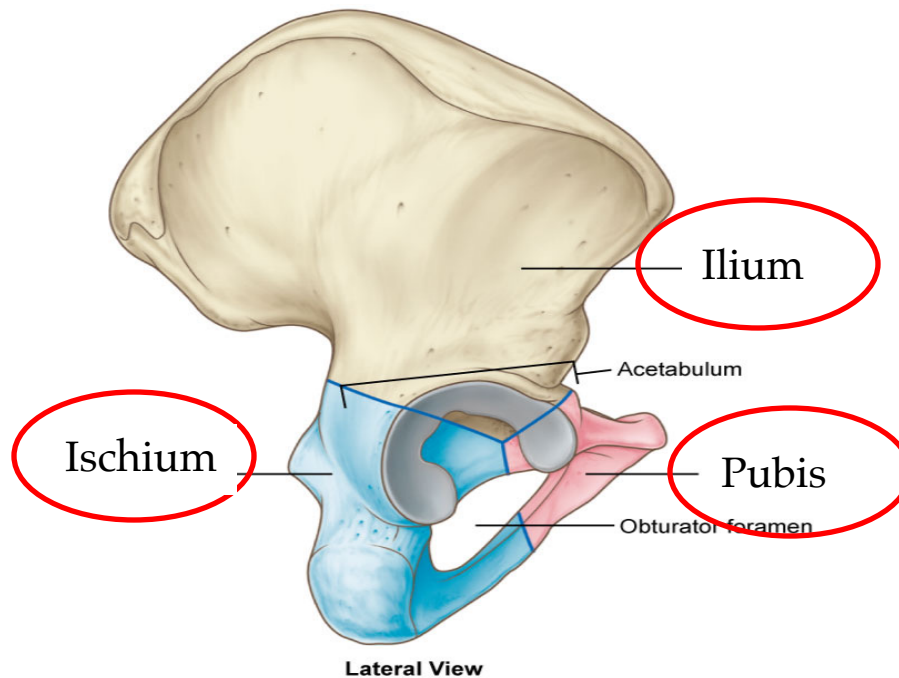
2 Pelvic Girdle

pelvic bone

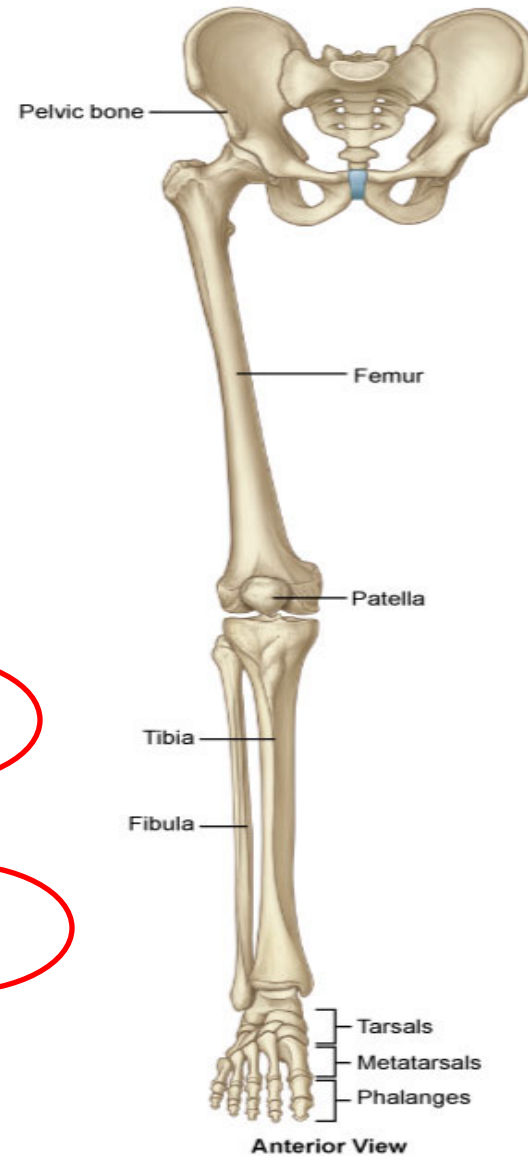
ilium

ischium

pubis



Lateral View



Anterior View

126 Appendicular Skeleton

60 Lower Extremity

femur 2

patella 2

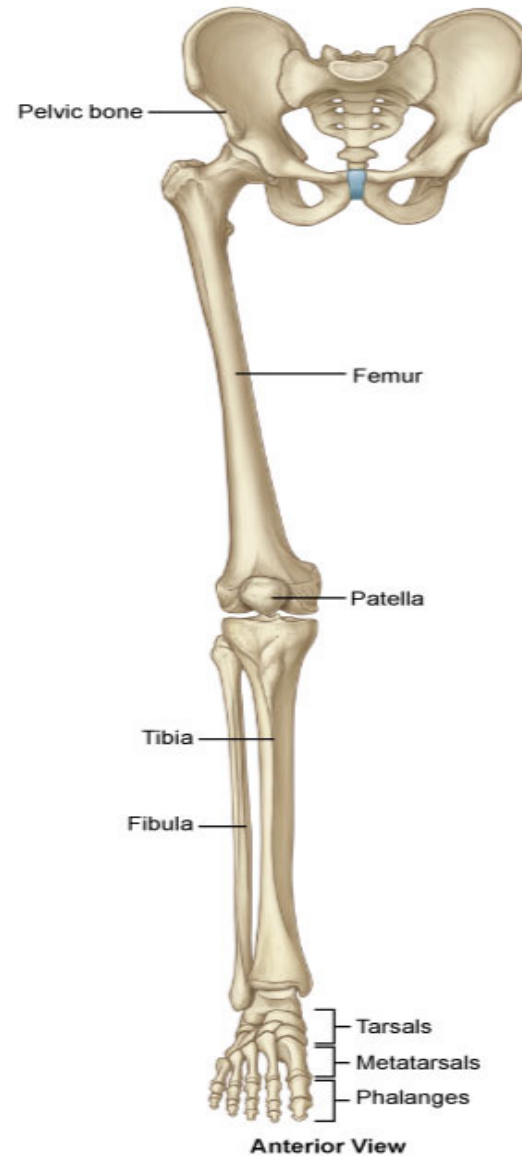
tibia 2

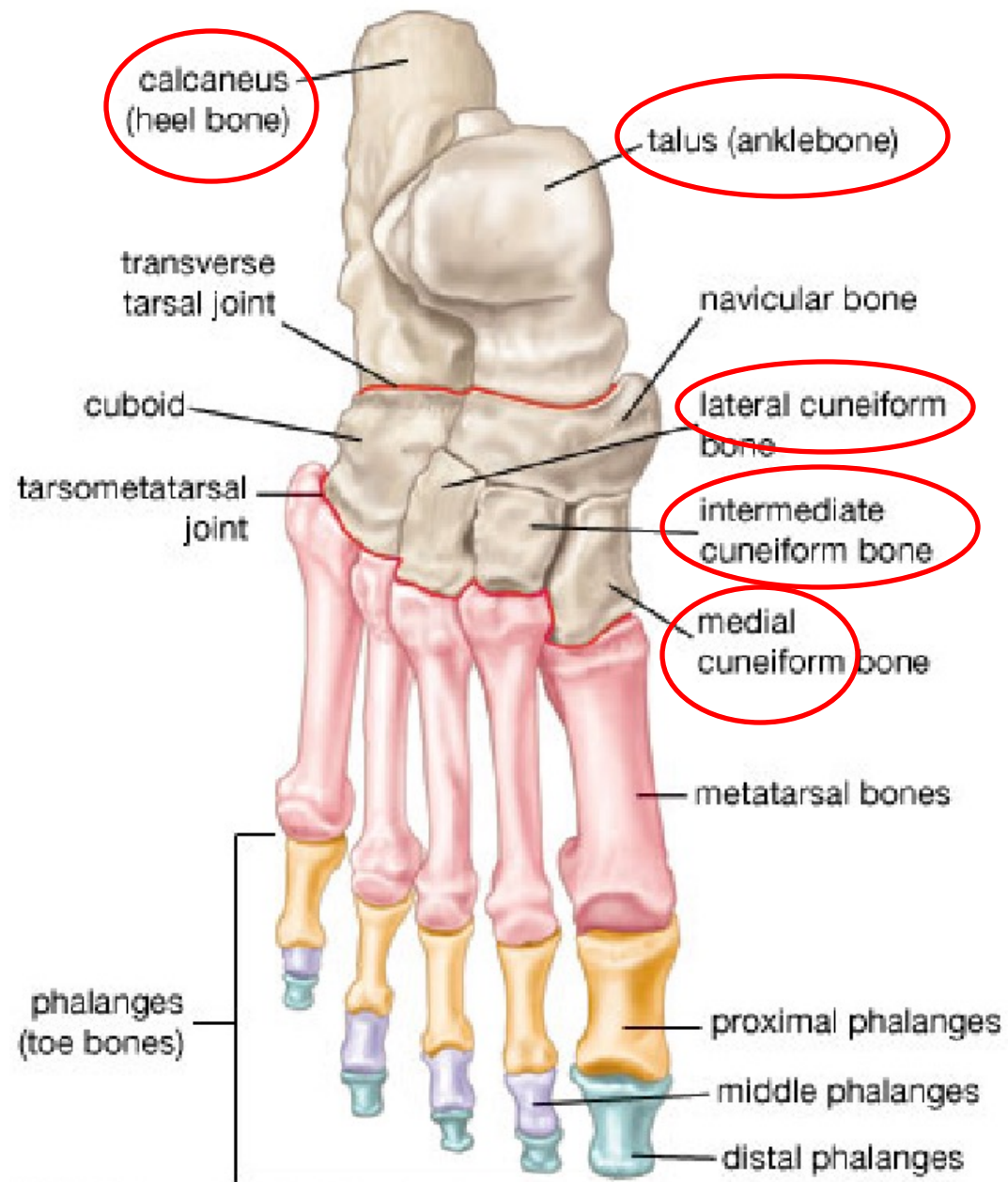
fibula 2

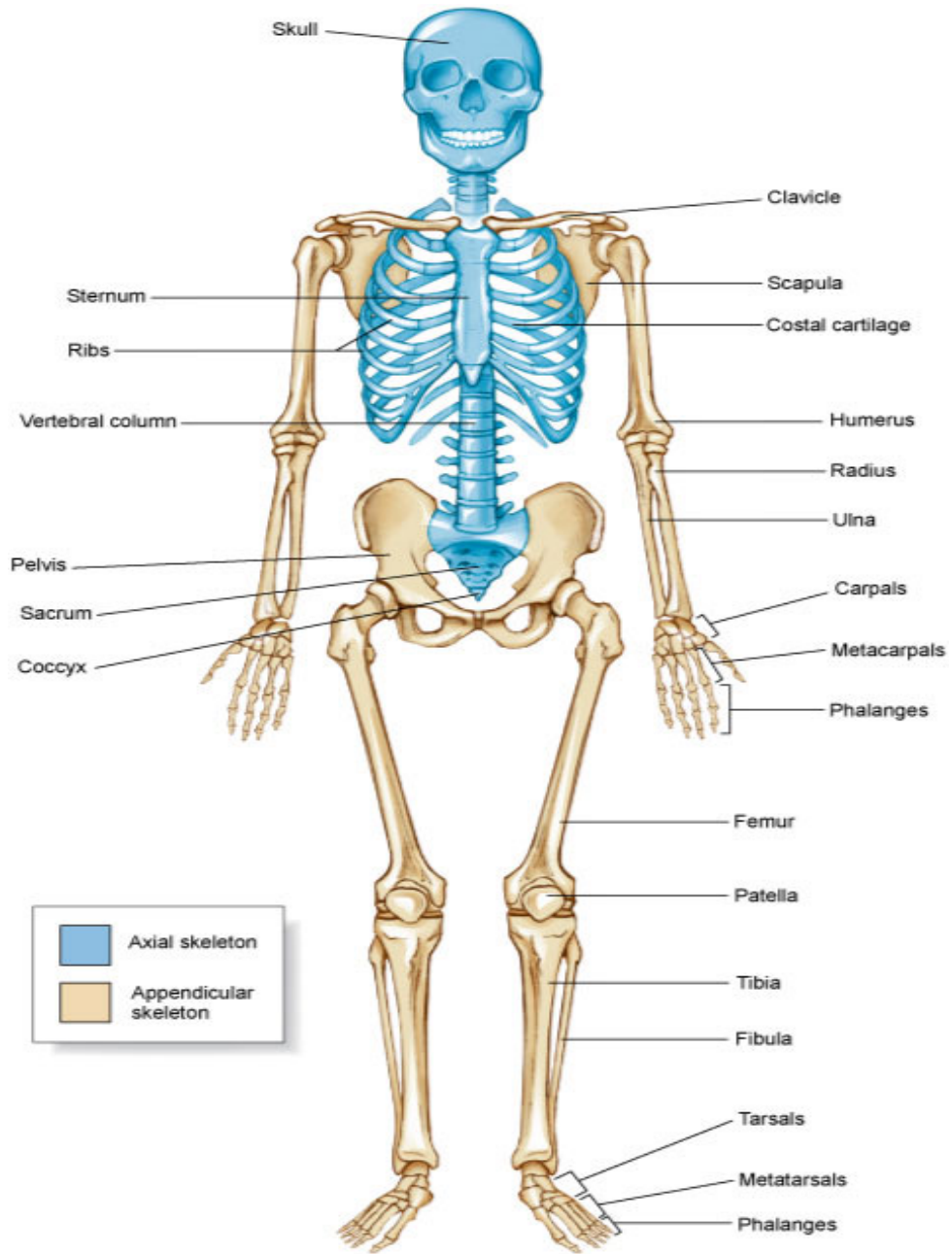
tarsals 14

metatarsals 10

phalanges 28







A

ANTERIOR VIEW



22a A&P: Skeletal System - Appendicular and Axial Divisions